

## TECHNICAL NOTE

## Foam Sclerotherapy Augmented Phlebectomy (SAP) Procedure for Varicose Veins: Report of a Novel Technique

Raghu Kolluri <sup>a,\*</sup>, Katherine U. Hays <sup>a</sup>, Manjit S. Gohel <sup>b</sup>

<sup>a</sup> OhioHealth Vascular Institute, Columbus, Ohio, USA

<sup>b</sup> Cambridge University Hospitals and Imperial College, London, UK

**Introduction:** While traditional ambulatory phlebectomy (AP) is a safe and effective procedure, few adverse effects such as hematoma, bleeding, bruising and nerve injury have been reported. To improve AP and to reduce some of these adverse events, herein we report a novel technique — Foam Sclerotherapy Assisted Phlebectomy (SAP).

**Report:** The details of the above technique, along with the potential advantages and limitations will be discussed.

**Discussion:** Foam sclerotherapy and DUS act as valuable adjuncts to traditional AP. SAP increases precision and creates additional venospasm leading to reduced bruising, reduced nerve injury and sclerosis of residual vein segments.

© 2018 The Author(s). Published by Elsevier Ltd on behalf of European Society for Vascular Surgery. This is an open access article under the CC BY-NC-ND license (<http://creativecommons.org/licenses/by-nc-nd/4.0/>).

Article history: Received 10 August 2018, Revised 17 October 2018, Accepted 19 October 2018,

**Keywords:** Varicose veins, Sclerotherapy, Foam sclerotherapy, Phlebectomy, Venous insufficiency

### INTRODUCTION

There have been significant advances in the treatment of superficial venous reflux in recent years, with endovenous modalities replacing traditional stripping operations in many countries.<sup>1</sup> However, the management of tortuous varicosities has remained largely unchanged for decades. Ambulatory phlebectomy (AP) using a vein hook to remove varicose veins through micro-incisions was pioneered by Robert Muller in 1956.<sup>2</sup> This technique requires pre-operative marking and removal of the bulging varicose veins through micro-incisions.

This procedure has been practiced successfully for the past several decades. However, several limitations and complications have been recognised. Large patient body habitus can result in displacement of target veins away from the pre-operative surface skin marking, once the patient is placed in horizontal position for the procedure.<sup>3</sup> This may result in an inability to exteriorise the varicosity or multiple hooking attempts leading to unintended local trauma. Cutaneous complications reported after AP include skin blisters, infections, keloids, and tattooing from the marking pen. Vascular complications include haematomas, severe bruising, post-operative haemorrhage, superficial

thrombophlebitis, and deep vein thrombosis. Inadvertent hooking of a cutaneous nerve can result in severe pain and post-procedural neuralgia and potential transient sensory defect.<sup>4–6</sup> Although the goal of phlebectomy is complete removal, some varicose veins may be friable and difficult to excise completely, resulting in a suboptimal clinical outcome.

This technical note describes a refined sclerotherapy augmented phlebectomy technique (hereafter described as SAP) using duplex ultrasound guidance, tumescent anaesthesia, and augmentation with foam sclerotherapy.

### SURGICAL TECHNIQUE

This procedure can be performed in an outpatient setting with local anaesthesia, but may also be used for procedures performed under general anaesthesia. Important considerations and steps of the procedure are described below.

### Indications

Indications and selection for SAP are no different from those for traditional AP. The procedure may be offered to patients requiring isolated treatment of varicosities, or as an adjuvant treatment for patients undergoing ablation of truncal saphenous reflux. However, patients who have contraindications to sclerotherapy are ineligible.

### Pre-operative procedure planning

Ultrasound is used to identify the pathological target veins and one to three access sites are identified 10 cm apart for

\* Corresponding author. Suite 514, 3545 Olentangy River Road, Columbus, Ohio, 43214, USA.

E-mail address: [kolluri.raghu@gmail.com](mailto:kolluri.raghu@gmail.com) (Raghu Kolluri).

2405-6553/© 2018 The Author(s). Published by Elsevier Ltd on behalf of European Society for Vascular Surgery. This is an open access article under the CC BY-NC-ND license (<http://creativecommons.org/licenses/by-nc-nd/4.0/>).

<https://doi.org/10.1016/j.ejvssr.2018.10.007>

intravenous access. The vein is accessed under ultrasound guidance with a micropuncture needle or butterfly. A small volume (<5 mL) of 0.25–0.5% foam sclerosant (polidocanol or sodium tetradecyl sulphate) prepared in a 1:4 ratio using room air (Tessari technique)<sup>7</sup> is injected into the vein and dispersed throughout the network of target varices using the ultrasound probe.

### Local (tumescient) anaesthesia infiltration

Tumescence solution (a combination of normal saline, epinephrine, and bicarbonate as per local policy) is injected into the perivenous space under ultrasound guidance until the hyperechoic veins are surrounded by the tumescent solution.

### DUS-guided micro-incision and “hooking”

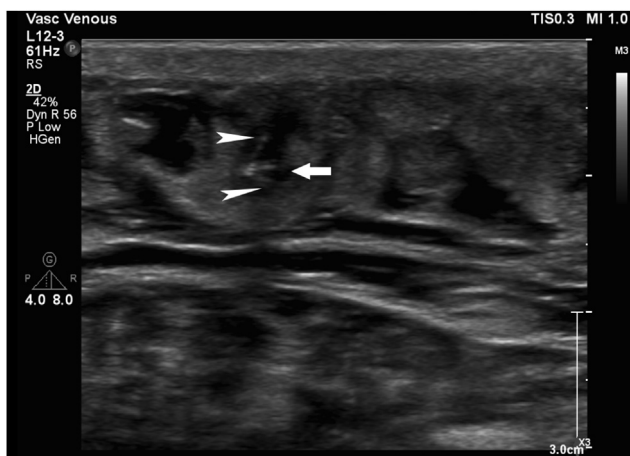
No surface marking is required. Ideal access sites are localised using ultrasound and sterile gel. A #11 blade is used to make a small incision directly overlying the hyperechoic vein. The vein hook is then inserted into the incision. The “hooking” of the hyperechoic vein (Fig. 1) and exteriorisation of the vein is clearly visualised under ultrasound and once the vein is exteriorised, the remainder of the procedure is similar to traditional AP. Each further step of incision and hooking the vein is done under ultrasound guidance, until the entire target vein (or as much as possible) is exteriorised. Bleeding and bruising is minimised by venous spasm induced by a combination of foam sclerosant injection and tumescent anaesthesia (containing epinephrine).

### Adjunctive sclerotherapy

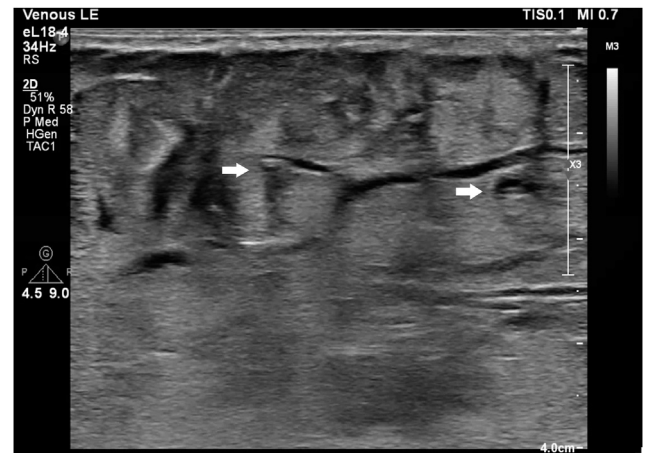Smaller target veins are treated by ultrasound guided foam sclerotherapy in the same session.

### Post-procedural care

Incisions may be covered with wound glue or steri strips, if needed. Primary suturing is not usually necessary as incisions are 1–3 mm and blood loss is minimal because of



**Figure 1.** Hyperechoic vein (arrow heads) hooked by the phlebectomy hook (arrow).

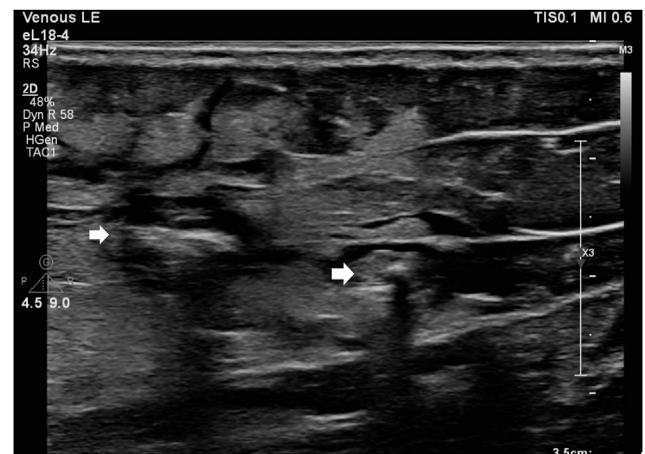


**Figure 2.** Veins without foam sclerosant after tumescent anaesthesia (arrows).

venospasm. A compression dressing or bandage is applied to include all the micro-incisions.

### DISCUSSION

This technical paper describes the adjunctive use of foam sclerotherapy and ultrasound guidance to the traditional AP technique. The addition of sclerotherapy and DUS guidance provides several potential benefits. The foam sclerosant turns the veins hyperechoic making them easier to visualise under DUS and increases the precision of tumescence infusion (Figs. 2 and 3). As the hyperechoic vein is clearly visualised on DUS, micro-incisions are placed accurately over target veins and hooking and exteriorisation of the varicose vein may be more effective. This may reduce the associated complications related to this trauma and the risk of inadvertent iatrogenic nerve injury, which may be significant and is a major cause of litigation after varicose vein interventions.<sup>8,9</sup> Another potential benefit of the sclerosing agent is decreased blood loss and bruising, because of expulsion of blood and additional venospasm in the target veins. Any remaining vein segments that may not have been removed during phlebectomy are also sclerosed from the adjunctive sclerotherapy, optimizing



**Figure 3.** Hyperechoic veins after foam sclerotherapy clearly demarcated (arrows) from surrounding tissues despite the tumescent anaesthesia.

treatment benefit. No increase was found in overall procedure times. It may be hypothesised that the additional time for administering sclerotherapy could be compensated for by more efficient exteriorisation of the target veins and quicker haemostasis. Despite past reports of complications,<sup>5,10,11</sup> contemporary phlebectomy is generally a safe procedure in experienced hands. The adjuvant techniques described in this note may offer a refinement to improve outcomes in some patients.

An incremental increase in deep vein thrombosis risk is a theoretical concern with the addition of foam sclerosant. However, to minimise this risk, low volumes of low concentration sclerosant are used. The risk of bruising and haematoma is likely to be reduced using this technique compared with conventional phlebectomy, potentially leading to improved recovery and quicker return to normal activity.

In conclusion, it is proposed that addition of foam sclerotherapy, tumescent anaesthesia, and duplex ultrasound guidance to traditional phlebectomy may provide additional benefits of increased precision, reduced complications, and quicker recovery. Larger studies are warranted to confirm or refute this statement and to assess long-term outcomes.

#### CONFLICT OF INTEREST

None.

#### FUNDING

None.

#### REFERENCES

- 1 Gloviczki P, Comerota AJ, Dalsing MC, Eklof BG, Gillespie DL, Gloviczki ML, et al. The care of patients with varicose veins and associated chronic venous diseases: clinical practice guidelines of the Society for Vascular Surgery and the American Venous Forum. *J Vasc Surg* 2011;**53**(5 Suppl):2S–48S.
- 2 Muller R. Histoire de la phlebectomie ambulatoire. *Médecine Bien-être* 1989;9–16.
- 3 Weiss RA, Goldman MP. Transillumination mapping prior to ambulatory phlebectomy. *Dermatol Surg* 1998;**24**:447–50.
- 4 Aremu M, Mahendran B, Butcher W, Khan Z, Colgan M, Moore D, et al. Prospective randomized controlled trial: conventional versus powered phlebectomy. *J Vasc Surg* 2004;**39**:88–93.
- 5 Olivencia J. Complications of ambulatory phlebectomy: review of 1000 consecutive cases. *Dermatol Surg* 1997;**23**:51–4.
- 6 Ramelet AA. Complications of ambulatory phlebectomy. *Dermatol Surg* 1997;**23**:947–54.
- 7 Tessari L, Cavezzi A, Frullini A. Preliminary experience with a new sclerosing foam in the treatment of varicose veins. *Dermatol Surg* 2001;**27**:58–60.
- 8 Dickhoff C, Cremers JE, Legemate DA, Koelemay MJ. Medical liability insurance claims after treatment of varicose veins. *Phlebology* 2014;**29**:293–7.
- 9 Otters EF, van Neer PA. Drop foot, a rare complication following Muller's phlebectomy. *Phlebology* 2012;**27**:303–4.
- 10 Olivencia JA. Pitfalls in ambulatory phlebectomy. *Dermatol Surg* 1999;**25**:722–5.
- 11 Ramelet AA. Müller phlebectomy: a new phlebectomy hook. *J Dermatol Surg Oncol* 1991;**17**:814–6.