

## ORIGINAL RESEARCH

# Prospective study on complications using different techniques for parotidectomy for benign tumors

Rubens Thölken MD<sup>1</sup>  | Monika Jering MD<sup>1</sup>  | Marcel Mayer MD<sup>1</sup>  |  
Stefan Schiele MSc<sup>2</sup> | Gernot Müller MD<sup>2</sup> | Johannes Zenk MD<sup>1</sup>

<sup>1</sup>Department of Otorhinolaryngology and Head and Neck Surgery, University Hospital Augsburg, Augsburg, Germany

<sup>2</sup>Institute of Mathematics, Augsburg University, Augsburg, Germany

## Correspondence

Rubens Thölken, MD, Department of Otolaryngology, Head and Neck Surgery, University Hospital Augsburg, Sauerbruchstraße 6, Augsburg 86179, Germany.  
Email: rubens.thoelken@gmail.com

## Abstract

**Objectives:** Long-term prospective studies on procedure-related complications after parotid surgery for benign neoplasms (BNs) are scarce. This is the first prospective study on the use of extracapsular dissection (ECD) for BNs, and it aimed to examine the incidence of postoperative complications after parotid surgery for BN.

**Methods:** We collected data obtained in a prospective study of parotidectomy for BN at a university hospital and analyzed the transient and long-term complications.

**Results:** The incidence rates of transient facial palsy immediately and 18 months after surgery were 15.0% and 3.7%, respectively. The rates of immediate postoperative facial palsy in patients who underwent ECD, partial superficial, superficial, and total parotidectomy were 5.8%, 29.3%, 20.0%, and 44.1%, respectively. Significant risk factors for facial palsy included multiple and larger lesions as well as surgery duration and extension.

**Conclusions:** Postoperative facial palsy remains a common complication after parotidectomy for BN and is associated with the extent of parotidectomy, presence of multiple neoplasms, and operative duration. The results of this study showed that ECD could be a safe technique for avoiding facial palsy.

**Level of Evidence:** 2.

## KEYWORDS

complication after parotidectomy, extracapsular dissection, facial palsy, Frey's syndrome, parotidectomy for benign neoplasms

## 1 | INTRODUCTION

Parotid gland neoplasms cause approximately 3% of head and neck tumors, of which up to 75% are benign.<sup>1,2</sup> Despite developments in operative techniques, surgery for benign parotid tumors remains associated with a relatively high rate of postoperative sequelae, with facial nerve palsy being the most significant.<sup>3,4</sup> Although complications and morbidity after parotidectomy for benign tumors have been

investigated,<sup>4-7</sup> most were retrospective studies with limited sample sizes. Additionally, most studies were conducted before adopting newer surgical techniques, such as extracapsular dissection (ECD), or in centers not routinely applying this technique.<sup>8,9</sup>

Previously reported rates for temporary and permanent postoperative facial palsy are 8.5% to 65% and 0% to 19.6%, respectively.<sup>4-7</sup> These variations could be attributed to different surgical techniques, time of first postoperative evaluation, extent of disease, and surgeon's experience.

This is an open access article under the terms of the Creative Commons Attribution-NonCommercial-NoDerivs License, which permits use and distribution in any medium, provided the original work is properly cited, the use is non-commercial and no modifications or adaptations are made.

© 2021 The Authors. *Laryngoscope Investigative Otolaryngology* published by Wiley Periodicals LLC on behalf of The Triological Society.

Other common complications after benign parotid surgery include sensation loss in the area supplied by the great auricular nerve, Frey's syndrome, salivary fistula, sialocele, postoperative infection, and hematoma or hemorrhage.<sup>3,4</sup>

Great auricular nerve dysfunction is highly susceptible to bias because, during the immediate postoperative period, patients experience discomfort from surgical wounds, dressings, and sutures; moreover, they may be less aware of facial numbness. Moreover, Frey's syndrome often has a delayed onset. In both cases, remission spontaneously occurs after numerous months, with varying severities and different descriptions by patients, who may report interference with quality of life (QoL) and activities of daily living.

This study aimed to determine and record the immediate and late postoperative complications after parotidectomy using different approaches for benign lesions of the parotid gland. This work is relevant because of the increase in less invasive surgical techniques such as the ECD. The prospective nature of this study as well as the large number of patients treated with ECD makes it a valuable addition to current literature.

## 2 | MATERIALS AND METHODS

All surgical data were obtained in a tertiary center. We prospectively collected the data from all parotidectomies performed from March 2014 to July 2018. All procedures performed in this study were in accordance with the ethical standards and were approved by the local research ethics board (BKF 2018/15). All surgeries were performed by seven experienced surgeons from the department. All surgeons follow the same standards for choosing the surgery technique as well as performing surgeries so there is no bias in the indication and surgery procedure itself. Appmed consent was obtained from all individual participants included in this study. The exclusion criteria were malignancy and patients with incomplete 18-month follow-up for various reasons, age was not an exclusion criteria.

A broad range of data were preoperatively collected during the first 4 postoperative days, including age, sex, surgery side, histological reports, surgical technique, surgeon's experience, surgical margin, surgery duration, neoplasm quantity and size, bleeding, salivary fistula occurrence, sialocele, hematoma or hemorrhage, and postoperative infection (wound erythema, pain or tenderness around the incision site, swelling, or purulent drainage).

A senior pathologist performed histopathological examinations. In case of nontypical findings, another pathologist performed a second review. ECD was defined as tumor resection through the parotid tissue within a 2- to 3-mm normal tissue margin, without identifying the facial nerve trunk.<sup>9</sup> In all other techniques, the facial nerve (FN) trunk was identified. Partial parotidectomy (PP) involved partial exposition of the facial nerve and partial excision of the superficial lobe. Superficial parotidectomy (SP) involved the total removal of the superficial lobe of the parotid gland. Total parotidectomy (TP) involved the total removal of the superficial and deep lobes of the parotid gland.

All surgical procedures were performed using intraoperative facial nerve monitoring. All experienced surgeons used cold steel with bipolar dissection. The great auricular nerve are identified and gently displaced posteriorly to avoid manipulation. Within the first 4 postoperative days, daily clinical examinations of the facial nerve branches and operative wound were performed. The indication of the surgical technique followed the current standardized criteria in the literature.<sup>9</sup> Abridgment: EDC are typically indicated for small tumors (until 2 cm), peripherally located or even large lesions of the caudal parotid pol. PP is mainly indicated in large tumors of the caudal part of the parotid with contact to the cervicofacial division of the FN. SP represents a universal technique in parotid surgery and should be the first technique to learn. TP has only few but important indications in benign parotid surgery, for example lesions in the deep lobe or multiple lesions. Even minimal facial function impairment was considered as palsy and classified based on the House-Brackmann (HB) Facial Nerve Grading System.<sup>10</sup> Facial weakness that fully recovered during the follow-up period was defined as temporary. Permanent facial paralysis was defined as facial weakness that persisted after the 18-month follow-up. Patients were re-evaluated after 1 and 2 weeks and, if necessary, after 3 months and at subsequent 6-month intervals. The incidence of complications (lobule and antitragus numbness, facial paralysis, Frey's syndrome, infections, hemorrhage, salivary fistula, and sialocele) was monitored until the 18-month follow-up visit. The last evaluation was conducted through telephone interviews, and postoperative complaints were recorded. The patients were asked in detail regarding all studied variables, mainly regarding great auricular nerve dysfunction and Frey's syndrome, based on a fix scheme to avoid bias. Evaluation of patients' complaints was performed using an analog scale that classified possible complaints between 0 (no complaints) and 10 (worst possible).

Statistical analyses were performed using the R software version 4.0.2 (The R Project, Vienna, Austria). Variables underwent descriptive statistics. Comparison between surgery techniques for continuous and categorical variables was performed using analysis of variance or the Kruskal-Wallis test and the chi-Square test or Fisher's exact test, respectively. A separate univariate logistic regression was conducted for each variable as well as a multivariate logistic regression for transient and permanent facial palsy. To adjust for possible confounders, we conducted a multivariate logistic regression with the surgical technique. Odds ratios (ORs) with 95% confidence intervals (CIs) for relevant risk factors were reported. Two-tailed *P* values  $\leq .05$  were considered significant.

## 3 | RESULTS

From March 2014 to July 2018, 579 patients underwent parotid surgery in our department; among them, we included 300 patients who met the 18-month follow-up criteria. A total of 127 patients with malignancy and 152 patients with incomplete 18-month follow-up for various reasons (unknown current phone number, address change,

**TABLE 1** Patient characteristics and factors related to surgery

Feature	Descriptive statistics	N (%)
Age (years), mean $\pm$ SD (range)	58.0 $\pm$ 14.0 (7-93)	
$\leq$ 45 years		42 (14.0)
45 to 65 years		161 (53.7)
$>$ 65 years		97 (32.3)
Sex		
Male		181 (60.3)
Female		119 (39.7)
Side		
Left		153 (51.0)
Right		147 (49.0)
No. of lesions, median (IQR)	1 (1-1)	
1		277 (92.3)
$\geq$ 2		23 (7.7)
Lesion size (mm), median (IQR)	25.0 (20.0-35.0)	
$<$ 28		163 (54.3)
$\geq$ 28		137 (45.7)
Average time of surgery (min), median (IQR)	99.0 (69.8-134.3)	
$\leq$ 120		201 (67.0)
$>$ 120		99 (33.0)
Operation		
ECD		190 (63.3)
PP		41 (13.7)
SP		35 (11.7)
TP		34 (11.3)
Transient facial palsy		
Yes		45 (15.0)
No		255 (85.0)
Permanent facial palsy		
Yes		11 (3.7)
No		289 (96.3)

Abbreviations: ECD, extracapsular dissection; IQR, interquartile range; PP, partial parotidectomy; SP, superficial parotidectomy; SD, standard deviation; TP, total parotidectomy.

refused to answer questions) were excluded. Table 1 summarizes the patients' characteristics and surgery-related factors.

The overall rate of transitory postoperative facial paralysis up to four postoperative days was 15.0% (45 patients). Among these 45 patients, 38 (12.7%) patients, 3 (1.0%) patients, 3 (1.0%) patients, and 1 (0.3%) patient had HB II, HB III, HB IV, and HB V grades, respectively. The patient with HB V underwent TP with two histologically representative lesions (30 and 40 mm) and  $>$ 40 very small lesions distributed throughout the parotid tissue.

Permanent facial palsy occurred in 11 (3.7%) patients; among them, 8 (2.7%) cases had minimal facial function impairment

represented by a slight drop in the mouth angle. The remaining three (1.0%) patients with permanent paralysis showed HB III, and each had undergone PP, SP, and TP.

The most common final pathological diagnosis was adenolymphoma (Warthin tumor; 47.7%,  $n = 143$ ), followed by pleomorphic adenoma (31.3%,  $n = 94$ ), non-neoplastic cyst (6.0%,  $n = 17$ ), lymphoepithelial cyst (3.0%,  $n = 9$ ), and basal cell adenoma (2.33%,  $n = 7$ ). The other diagnoses included five oncocytomas, five patients with oncocytic metaplasia, four lipomas, and four patients with combination of adenolymphoma and oncocytic metaplasia. We also observed two patients with hemangioma, two with myoepithelioma, and two with combination of adenolymphoma and cystic lesion. Cystadenoma and mucocele were observed in one patient each, and histological combinations of adenolymphoma and basal cell adenoma, adenolymphoma and pleomorphic adenoma, and at least lymphoepithelial cyst and adenomatous hyperplasia were observed in one patient each.

In the ECD, PP, SP, and TP subgroups, the median surgery durations were 87.0 (quartiles: 59.0-107.0), 102.0 (quartiles: 79.0-136.0), 145.0 (quartiles: 121.0-163.5), and 212.5 (quartiles: 178.8-272.0) min, respectively, with a significant difference in surgery duration among techniques ( $P < .001$ ). There was no significant difference among subgroups in terms of age ( $P = .102$ ), sex ( $P = .820$ ), or side ( $P = .919$ ). There were among-subgroup differences in the lesion number, with ECD and TP showing the lowest and highest proportions of  $>$ 1 lesions, respectively ( $P < .001$ ). Similarly, there was a higher proportion of lesions  $>$ 28 mm in SP and TP ( $P = .002$ ), as shown in Table 2.

The immediate risk of transient postoperative palsy differed among surgery types (ECD, 5.8%; PP, 29.2%; SP, 20.0%; and TP, 44.1%;  $P < .001$ ; Figure 1). Post hoc tests with adjusted P-values according to Benjamini-Hochberg showed that the risk of transient postoperative palsy was lower after ECD compared with each other surgery type. Comparisons between PP and SP, between PP and TP, and between SP and TP were not significant (Figure 1). After 18 months, the risk of facial nerve palsy differed according to the type of surgery (ECD, 0.5%; PP, 12.2%; SP, 11.5%; TP, 2.9%;  $P < .001$ ). The ECD group had a significantly lower rate of facial nerve palsy than the PP and SP groups in post hoc tests (Figure 2).

Regarding analysis of risk factors for transient and permanent facial palsy, we evaluated the age, surgery duration and extent, and tumor number and size (histopathological measurements). To assess the effect of different variables, we conducted univariate logistic regression models (Table 3). Comparisons among age groups revealed no differences in temporary facial palsy ( $\leq$ 45 years, 14.3%; 46-65 years, 16.8%;  $>$ 65 years, 11.3%); however, there was a trend for a higher risk of permanent palsy with older age ( $P = .078$ ). Furthermore, a higher risk of temporary facial palsy was associated with  $>$ 1 lesion (OR = 2.8, 95% CI: 1.1-7.1,  $P = .037$ ), surgery duration  $>$ 120 minutes (OR = 3.8, 95% CI: 2.0-7.3,  $P < .001$ ), and a lesion with a histopathological diameter  $>$ 28 mm (OR = 2.0, 95% CI: 1.0-3.8,  $P = .039$ ). A higher risk of permanent facial palsy was associated with a lesion size  $>$ 28 mm (OR = 5.7, 95% CI: 1.2-26.7,  $P = .028$ ), but not  $>$ 1 lesion ( $P = .857$ ) or surgery duration  $>$ 120 minutes ( $P = .134$ ).

**TABLE 2** Facial palsy according to operation, HB grade, and time after surgery

Variable	ECD patients <sup>a</sup> (n = 190) N (%)	PP patients <sup>b</sup> (n = 41) N (%)	SP patients <sup>c</sup> (n = 35) N (%)	TP patients <sup>d</sup> (n = 34) N (%)	P-value
Transient facial palsy					<.001
No	179 (94.2)	29 (70.7)	28 (80.0)	19 (55.9)	
Yes	11 (5.8)	12 (29.3)	7 (20.0)	15 (44.1)	
Permanent facial palsy					<.001
No	189 (99.5)	36 (87.8)	31 (88.6)	33 (97.1)	
Yes	1 (0.5)	5 (12.2)	4 (11.4)	1 (2.9)	
Age (years), mean ± SD	58.3 ± 12.6	61.0 ± 14.2	57.5 ± 10.7	53.12 ± 21.4	.102
≤45 years	24 (12.6)	4 (9.8)	4 (11.4)	10 (29.4)	.123
45 to 65 years	102 (53.7)	22 (53.7)	23 (65.7)	14 (41.2)	
>65 years	64 (33.7)	15 (36.6)	8 (22.9)	10 (29.4)	
No. of lesions					<.001
1	183 (96.3)	37 (90.2)	31 (88.6)	26 (76.5)	
≥2	7 (3.7)	4 (9.8)	4 (11.4)	8 (23.5)	
Lesion size (mm)					.002
<28	117 (61.6)	22 (53.7)	12 (34.3)	12 (35.3)	
≥28	73 (38.4)	19 (46.3)	23 (65.7)	22 (64.7)	
Av. time of surgery (min)					<.001
≤120	165 (86.8)	26 (63.4)	8 (22.9)	2 (5.9)	
>120	25 (13.2)	15 (36.6)	27 (77.2)	32 (94.1)	

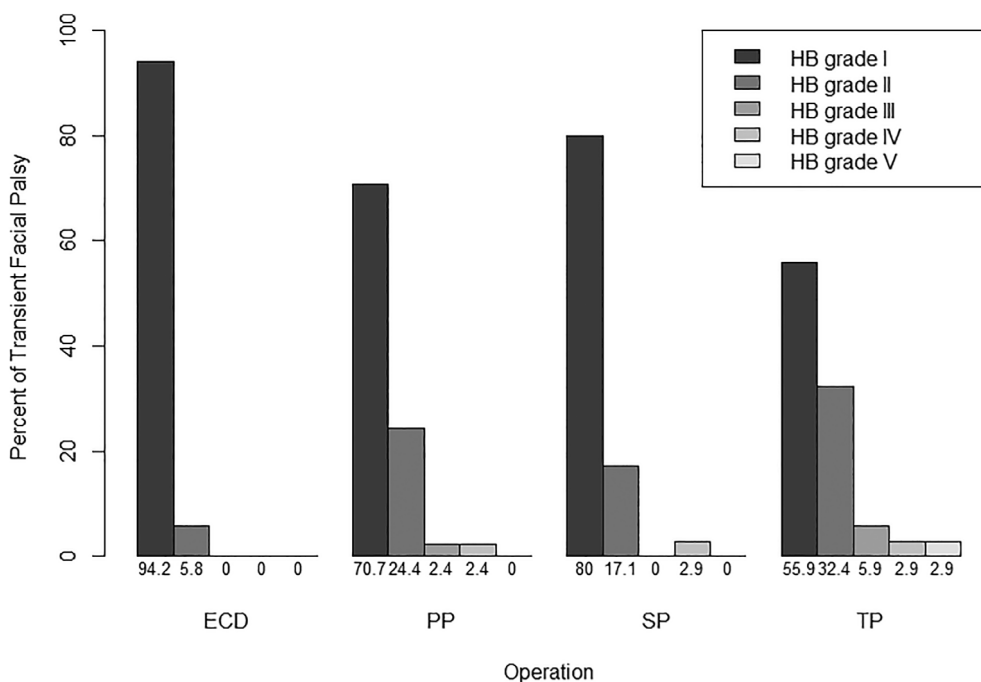
Abbreviations: ECD, extracapsular dissection; HB, House-Brackmann Facial Nerve Grading System; PP, partial parotidectomy; SD, standard deviation; SP, superficial parotidectomy; TP, total parotidectomy.

<sup>a</sup>Extracapsular dissection.

<sup>b</sup>Partial parotidectomy.

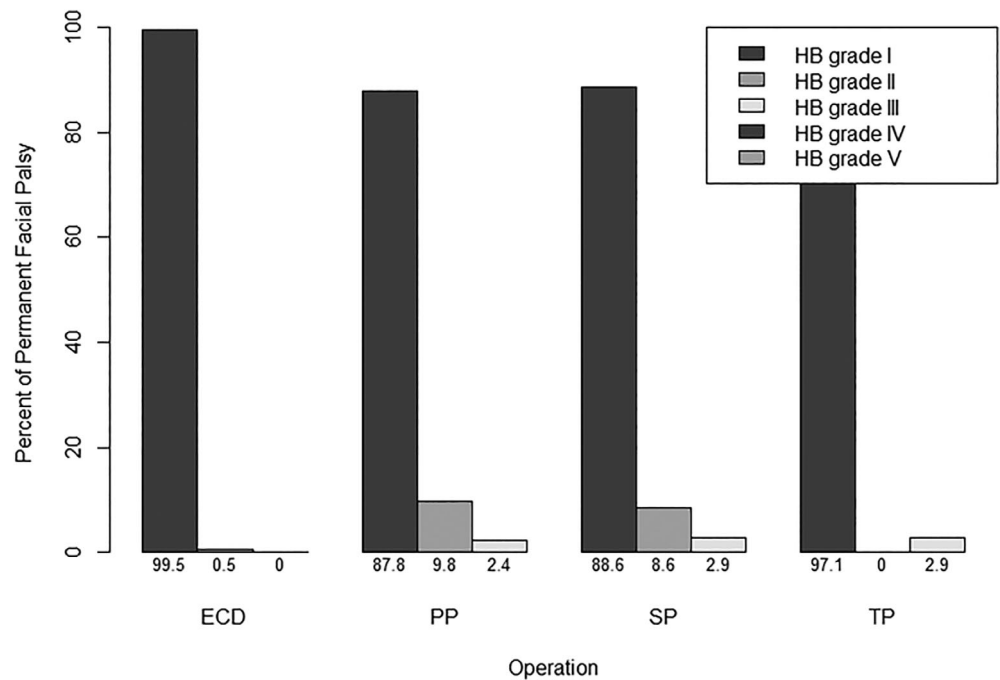
<sup>c</sup>Superficial parotidectomy.

<sup>d</sup>Total parotidectomy.



**FIGURE 1** The immediate risk of transient postoperative palsy differed between the surgery types

**FIGURE 2** The extracapsular dissection (ECD) group had a significantly lower rate of facial nerve palsy than partial parotidectomy (PP) and superficial parotidectomy (SP) in post-hoc tests



Multivariate logistic regression revealed that surgery duration was an independent risk factor for transient facial palsy (OR = 3.3, 95% CI: 1.7-6.6,  $P < .001$ ). Permanent facial palsy was associated with greater tumor (OR = 5.3, 95% CI: 1.1-25.5,  $P = .039$ ), whereas age showed a slightly nonsignificant trend ( $P = .065$ ).

To adjust the impact of the surgery technique for age, surgery duration, and lesion number and size, we conducted a separate multivariable logistic regression model for transient facial palsy incorporating the surgery technique and potential confounders. None of the factors, except for surgery type, were significant. The ORs for the reference ECD were 6.2 (95% CI: 2.4-15.9,  $P < .001$ ) for PP, 2.8 (95% CI: 0.8-9.3,  $P = .096$ ) for SP, and 9.9 (95% CI: 3.0-33.1,  $P < .001$ ) for TP (Table 4).

Additionally, we evaluated the patient's self-assessment regarding facial palsy 18 months after parotidectomy. This was conducted based on complaints from patients with palsy impressions using a questionnaire rating possible complaints between 0 (no complaints) and 10 (worst possible).

The second most common immediate complication was seroma/sialocele (11.0%), followed by hemorrhage (10.0%) and infection (8.0%). However, except for transient facial palsy, no other immediate complications were associated with surgery type (all  $P > .05$ ). Regarding long-term complications within the 18-month follow-up period, 9.3% and 5.3% of the patients showed greater auricular nerve dysfunction and Frey's syndrome, respectively. The surgery technique showed a significant association with Frey's syndrome occurrence ( $P = .002$ ) and a slightly nonsignificant association with greater auricular nerve dysfunction ( $P = .051$ ; Table 5).

All patients with Frey's syndrome underwent reevaluation for possible treatment; however, the patients reported a very low impact on QoL that did not require further treatment. Our findings revealed

that greater auricular nerve dysfunction is a common permanent side effect of parotidectomy during the late postoperative period; however, it had a low impact on overall QoL, with patients only mentioning this change after explicit inquiry.

## 4 | DISCUSSION

This prospective study analyzed the postoperative complications of 300 patients with benign parotid tumors who underwent parotidectomy in our institution. We analyzed the incidence of complications and risk factors for postoperative transient and permanent facial palsy. The evaluation followed standardized methods; specifically, it was performed by doctors experienced in assisting and evaluating patients with facial nerve pathology during the postoperative period. Additionally, we investigated other complications that occurred immediately and within 18 months after surgery.

In this study, facial nerve palsy was observed in 15.0% of the patients within the first 4 postoperative days and 3.7% after 18 months. Moreover, within the first 4 postoperative days, ECD showed a lower incidence of complications. This could be due to the effect that the surgery time was significantly shorter than that of other surgery and that this intervention is less invasive. Surgery duration, lesion size  $>28$  mm, and multiple lesions were independent risk factors for short-term complications. Other observed late complications included hypoesthesia (44.3%), dysfunction of the great auricular nerve (9.3%), and Frey's syndrome (5.3%). There were significant differences in the incidence of these complications among the surgical techniques used, with the ECD subgroup showing the lowest incidence of Frey's syndrome and a trend of lower great auricular nerve dysfunction ( $P = .002$  and  $P = .051$ , respectively). Additionally,

TABLE 3 Logistic regression analysis with facial paralysis as dependent variables

Feature	With paralysis only					
	Up to 4 days after surgery			18 months after surgery		
	Facial palsy	Univariate regression OR (95% CI)	P-value	Facial palsy	Univariate regression OR (95% CI)	P-value
Age						
≤45 years	6 (14.3%)	Reference		0 (0.0%)	Continuous <sup>a</sup>	Continuous <sup>a</sup>
45 to 65 years	27 (16.8%)	1.3 (0.5, 3.3)	.632	5 (3.1%)	1.1 (.99, 1.1)	1.05 (0.997, 1.1)
>65 years	11 (11.3%)	0.8 (0.3, 2.2)	.627	5 (5.2%)		
No. of lesions						
1	37 (13.4%)	Reference		9 (3.2%)	Reference	Reference
≥2	7 (30.4%)	2.8 (1.1, 7.1)	.037	1 (4.3%)	1.2 (2, 9.9)	1.1 (0.1, 9.9)
Duration of surgery						
≤120 minutes	18 (9.0%)	Reference		5 (2.5%)	Reference	Reference
> 120 minutes	26 (26.3%)	3.8 (2.0, 7.4)	<.001	5 (5.1%)	2.5 (.8, 8.5)	1.9 (0.5, 6.8)
Lesion size						
<28 mm	18 (11.0%)	Reference		2 (1.2%)	Reference	Reference
≥28 mm	26 (19.0%)	2.0 (1.0, 3.8)	.039	8 (5.8%)	5.7 (1.2, 26.7)	5.3 (1.1, 25.5)

<sup>a</sup>Age was continuous since permanent facial palsy is not observed in patients aged ≤45 years.

**TABLE 4** With paralysis only up to 4 days after surgery

Feature	OR (95% CI)	P-value
<b>Operation</b>		
ECD	Reference	
PP	6.2 (2.4, 15.9)	<.001
SP	2.8 (0.8, 9.3)	.096
TP	9.9 (3.0, 33.1)	<.001
<b>Age</b>		
≤45 years	Reference	
45 to 65 years	2.0 (0.7, 5.9)	.213
>65 years	1.1 (0.3, 3.6)	.887
<b>No. of lesions</b>		
1	Reference	
≥2	1.3 (0.5, 3.9)	.606
<b>Duration of surgery</b>		
≤ 120 minutes	Reference	
> 120 minutes	1.4 (0.5, 3.5)	.500
<b>Lesion size</b>		
<28 mm	Reference	
≥28 mm	1.4 (0.7, 3.0)	.316

Abbreviations: CI, confidence interval; ECD, extracapsular dissection; OR, odds ratio; PP, partial parotidectomy; SP, superficial parotidectomy; TP, total parotidectomy.

patients with slight lesions showed a lower proportion of permanent facial nerve palsy ( $P = .039$ ).

The reported incidence of temporary facial nerve dysfunction after parotidectomy for benign lesions varies from 10.5% to 64.6%.<sup>4,6,11,12</sup> The study population comprised a considerable number

of patients who underwent the newer parotidectomy technique of ECD.<sup>13,14</sup> The overall rate of temporary facial palsy was 15.0%, with previously reported values ranging from 9.2% to 66%. Contrastingly, the incidence rates of permanent palsy (3.7%) and Frey's syndrome (5.6%) were slightly lower than previously reported values of 0%-9% and 0%-35%, respectively.<sup>3,5,13-15</sup>

A strength of our study is the inclusion of a large number of patients within a short period. Given that parotidectomy techniques have changed from total and superficial parotidectomies to more conservative approaches as well as the wide availability of intraoperative electromyographic monitoring and improved preoperative imaging methods, caution should be applied when comparing different populations and complication rates.

Previous prospective studies on facial paralysis after benign parotid surgery did not employ our method of daily observation of postoperative facial dynamics within the first 4 postoperative days. Since the surgeries included in this study were routinely conducted within 4 years in a center, they are comparable with respect to technical details.

An extended surgery duration occurred in more invasive surgery such as TP with dissection of several branches of the facial nerve. Surgery time was prolonged in more invasive surgery as TP; therefore, longer duration and older age were recognized as risk factors for temporary and permanent postoperative facial palsy, respectively, after parotid surgery for benign neoplasm, which is consistent with previous reports.<sup>3,5,16,17</sup>

In the recent past, there has been a trend toward less invasive procedures in parotid gland surgery.<sup>13,18</sup> Our findings confirm that greater extent of surgery and longer duration were risk factors for developing postoperative facial dysfunction. Additionally, we observed that patients with multiple and large-sized lesions had a higher number of complications. Previous studies have reported no

**TABLE 5** Other immediate or permanent complications

Complication	All patients (n = 300)	ECD patients <sup>a</sup> (n = 190)	PP patients <sup>b</sup> (n = 41)	SP patients <sup>c</sup> (n = 35)	TP patients <sup>d</sup> (n = 34)	P-value
<i>Up to 4 days after surgery</i>						
Seroma/Sialocele	33 (11.0)	18 (9.4)	5 (12.2)	5 (14.2)	5 (14.7)	.612
Hemorrhage	30 (10.0)	20 (10.5)	4 (9.7)	2 (5.7)	4 (11.7)	.994
Infection	24 (8.0)	13 (6.8)	4 (9.7)	4 (11.4)	3 (8.8)	.639
Salivary fistula	6 (2.0)	4 (2.1)	1 (2.4)	0 (0.0)	1 (2.9)	.838
<i>18 months after surgery</i>						
N. greater auricular dysfunction						.051
Mild hypoesthesia	133 (44.3)	74 (38.9)	18 (43.9)	21 (60.0)	20 (58.8)	
Complete numbness	28 (9.3)	16 (8.4)	7 (17.0)	2 (5.7)	3 (8.8)	
Frey's syndrome	16 (5.3)	5 (2.6)	2 (4.8)	2 (5.7)	7 (20.5)	.002

Abbreviations: ECD, extracapsular dissection; PP, partial parotidectomy; SP, superficial parotidectomy; TP, total parotidectomy.

<sup>a</sup>Extracapsular dissection.

<sup>b</sup>Partial parotidectomy.

<sup>c</sup>Superficial parotidectomy.

<sup>d</sup>Total parotidectomy.

positive correlation between age and facial injury risk<sup>3,5</sup>; contrastingly, our findings indicated a trend of a higher risk of permanent palsy with older age ( $P = .078$ ).

However, EDC is a delicate procedure with a low margin of error, as the facial nerve is not exposed. Low-volume or inexperienced surgeons may have higher rates of permanent facial nerve dysfunction and/or higher recurrence rates without adequate training prior to performing this procedure.

Furthermore, dysfunction of the great auricular nerve was routinely assessed, which showed a high incidence rate (44.3%). We performed post-parotidectomy evaluation of hypoesthesia in the lobule and antitragus based on clinical complaints and a rating scale ranging from 0 (no complaints) to 10 (worst possible). Despite a high incidence of these complaints, they did not change the QoL. This finding could inform future preoperative discussions between surgeons and patients regarding this common side effect.

Previously reported values for Frey's syndrome occurrence have widely varied from 0% to 63% and are mainly dependent on methodological factors and diagnostic tests.<sup>7</sup> In this study, Frey's syndrome was diagnosed based on spontaneous clinical complaints as well as direct questions regarding the syndrome and hypoesthesia evaluation. In our study, the incidence rate of Frey's syndrome was 5.3%, which is consistent with previous findings.<sup>3,19-21</sup> Frey's syndrome could be caused by aberrant reinnervation between damaged auriculotemporal nerve branches, which stimulate parotid secretion, and the sympathetic nervous branches of the eccrine cutaneous sweat.

After 18 months of follow-up, only a few patients had ongoing symptoms (3.7%), which could be partly attributed to the large number of included cases undergoing ECD, which involves dissection of fewer nerve branches. During the ECD, less glandular parenchyma is dissected and the skin flap is smaller than in more invasive technique. Other rates of postoperative complications, including sialocele (11.0%,  $n = 33$ ), salivary fistula (2.0%,  $n = 6$ ), infection (8.0%,  $n = 24$ ), and hemorrhage (10.0%,  $n = 30$ ), in this study were comparable to those previously reported.<sup>12</sup>

All physicians received detailed instructions regarding the methodology to ensure high-standard evaluation. Additionally, to emphasize the importance of objective facial function evaluation, we agreed to register even the slightest dysfunction as a complication. This study has some limitations. First, the number of physicians who evaluated the patients could be considered a limitation. Second, we did not find any difference in the location or size of the lesion, surgeon's experience, or any other variable that could explain the nonstatistical difference between ECD and TP for permanent palsy. In our observation, there was no difference between surgeons with more experience and other surgeons. We assume that the best explanation may be the small number of complications as a whole and that, with the progress of this study and more cases being included, a clear answer can be presented. The final limitation of this study is the lack of lesion recurrence; however, after tumor excision, recurrence exceptionally occurs in the first few months.<sup>15,18</sup> We plan to reevaluate all patients with a longer follow-up duration.

## 5 | CONCLUSION

The findings of this large prospective study on benign parotid tumor surgery showed that ECD is a reasonable method for benign neoplasms. Complications of surgery increased significantly with the extent of the procedures applied, but ECD had the lowest complication rate and the risk of recurrence was not higher, according to known literature. As the facial nerve is not exposed, even with recurrence, more extensive surgery can be performed easily. The number and size of tumors and surgery duration were independent risk factors of postoperative facial dysfunction.

## ACKNOWLEDGMENTS

The authors would like to thank Professor Dr. M. Boyd Gillespie, Chair of the Department of Otolaryngology at University of Tennessee, Memphis, for supporting this research project. This study was performed in (partial) fulfillment of the requirements for obtaining the degree "Dr. med" at the Friedrich-Alexander-Universität Erlangen-Nürnberg (FAU), Erlangen, Germany.

## CONFLICT OF INTEREST

The authors declare that they have no conflict of interest to disclose.

## ORCID

Rubens Thölken  <https://orcid.org/0000-0001-9290-8427>

Monika Jering  <https://orcid.org/0000-0001-5418-0797>

Marcel Mayer  <https://orcid.org/0000-0001-9963-1109>

## BIBLIOGRAPHY

1. Chung SW, Kwon SY, Jung KY, Woo JS. Synchronous double primary cancers of the unilateral parotid gland. *Acta Otolaryngol.* 2007;127(2):209-212.
2. Barnes L, Eveson JW, Sidransky D, Reichart P. *Pathology and Genetics of Head and Neck Tumours.* 3rd ed. Lyon, France: IARC; 2005:209-281.
3. Guntinas-Lichius O, Klussmann JP, Wittekindt C, Stennert E. Parotidectomy for benign parotid disease at a university teaching hospital: outcome of 963 operations. *Laryngoscope.* 2006;116(4):534-540.
4. Witt RL. Facial nerve function after partial superficial parotidectomy: an 11-year review (1987-1997). *Otolaryngol Head Neck Surg.* 1999;121(3):210-213.
5. Dulguerov P, Marchal F, Lehmann W. Postparotidectomy facial nerve paralysis: possible etiologic factors and results with routine facial nerve monitoring. *Laryngoscope.* 1999;109(5):754-762.
6. Jin H, Kim BY, Kim H, et al. Incidence of postoperative facial weakness in parotid tumor surgery: a tumor subsite analysis of 794 parotidectomies. *BMC Surg.* 2019;19(1):199.
7. Koch M, Zenk J, Iro H. Long-term results of morbidity after parotid gland surgery in benign disease. *Laryngoscope.* 2010;120(4):724-730.
8. Psychogios G, Rueger H, Jering M, Tsoures E, Künzel J, Zenk J. Ultrasound can help to indirectly predict contact of parotid tumors to the facial nerve, correct intraglandular localization, and appropriate surgical technique. *Head Neck.* 2019;41:3211-3218.
9. Psychogios G, Bohr C, Constantinidis J, et al. Review of surgical techniques and guide for decision making in the treatment of benign parotid tumors. *Eur Arch Otorhinolaryngol.* 2021;278:15-29.



10. House JW, Brackmann DE. Facial nerve grading system. *Otolaryngol Head Neck Surg*. 1985;93(2):146-147.
11. O'Brien CJ. Current management of benign parotid tumors—the role of limited superficial parotidectomy. *Head Neck*. 2003;25(11):946-952.
12. Laccourreye H, Laccourreye O, Cauchois R, Jouffre V, Menard M, Brasnu D. Total conservative parotidectomy for primary benign pleomorphic adenoma of the parotid gland: a 25-year experience with 229 infors. *Laryngoscope*. 1994;104(12):1487-1494.
13. Mantsopoulos K, Koch M, Klintworth N, Zenk J, Iro H. Evolution and changing trends in surgery for benign parotid tumors. *Laryngoscope*. 2015;125(1):122-127.
14. Borumandi F, George KS, Cascarini L. Parotid surgery for benign tumours. *Oral Maxillofac Surg*. 2012;16(3):285-290.
15. Albergotti WG, Nguyen SA, Zenk J, Gillespie MB. Extracapsular dissection for benign parotid tumors: a meta-analysis. *Laryngoscope*. 2012;122(9):1954-1960.
16. Zheng CY, Cao R, Gao MH, Huang ZQ, Sheng MC, Hu YJ. Comparison of surgical techniques for benign parotid tumours: a multicentre retrospective study. *Int J Oral Maxillofac Surg*. 2019;48(2):187-192.
17. Mantsopoulos K, Koch M, Goncalves M, Iro H. Investigation of the surgical strategies for unilateral multifocal cystadenolymphomas of the parotid gland. *Oral Oncol*. 2018;82:176-180.
18. Bär B, Mantsopoulos K, Iro H. Paradigm shift in surgery for benign parotid tumors: 19 years of experience with almost 3000 cases. *Laryngoscope*. 2020;130:1941-1946.
19. Ruohoalho J, Makitie AA, Aro K, et al. Complications after surgery for benign parotid gland neoplasms: a prospective cohort study. *Head Neck*. 2017;39(1):170-176.
20. Upton DC, McNamar JP, Connor NP, Harari PM, Hartig GK. Parotidectomy: ten-year review of 237 cases at a single institution. *Otolaryngol Head Neck Surg*. 2007;136(5):788-792.
21. Lee CC, Chan RC, Chan JY. Predictors for Frey syndrome development after parotidectomy. *Ann Plast Surg*. 2017;79(1):39-41.

**How to cite this article:** Thölken R, Jering M, Mayer M, Schiele S, Müller G, Zenk J. Prospective study on complications using different techniques for parotidectomy for benign tumors. *Laryngoscope Investigative Otolaryngology*. 2021;6(6):1367-1375. doi:10.1002/lio2.694