




Technical Notes

Skin erosion in deep brain stimulation procedures: Using the temporalis muscle to treat this complication – A technical note

João Pedro Einsfeld Britz¹, Paulo Roberto Franceschini², Miguel Bertelli Ramos¹, Pedro Henrique Pires de Aguiar³, Jibril Osman Farah⁴, Paulo Henrique Pires de Aguiar⁵

¹Department of Health Science, Medical School, University of Caxias do Sul, ²Department of Neurology and Neurosurgery, University of Caxias do Sul, Caxias do Sul, Rio Grande do Sul, ³Department of Medical Science, Medical School, Catholic Pontifical University of Sao Paulo, Sao Paulo, Brazil, ⁴Department of Neurosurgery, The Walton Centre, Liverpool, United Kingdom, ⁵Department of Neurology, Division of Neurology, Catholic Pontifical University of Sorocaba, Sorocaba, Brazil.

E-mail: *João Pedro Einsfeld Britz - joapedrobritz@hotmail.com; Paulo Roberto Franceschini - prfrance@yahoo.com.br; Miguel Bertelli Ramos - mbramos1@ucs.br; Pedro Henrique Pires de Aguiar - phtrabalhos10@gmail.com; Jibril Osman Farah - jibril.farah@thewaltoncentre.nhs.uk; Paulo Henrique Pires de Aguiar - phpaneurocir@gmail.com



***Corresponding author:**
João Pedro Einsfeld Britz,
Medical School, University of
Caxias do Sul, Caxias do Sul,
Rio Grande do Sul, Brazil.
joapedrobritz@hotmail.com

Received : 16 April 2021
Accepted : 12 June 2021
Published : 19 July 2021

DOI
10.25259/SNI_372_2021

Quick Response Code:



ABSTRACT

Background: Skin erosion is a common complication after deep brain stimulator procedures. Despite being a relatively common event, there is no standard surgical technique or a widely accepted guideline for managing this kind of complication.

Methods: We describe a case of cutaneous erosion in the connector's site of deep brain stimulation case, surgically managed with anterior displacement of the connectors and overlapping and wrapping the connections within the temporal muscle.

Results: Postoperatively, the patient did well and achieved complete resolution of the skin erosion, with no signs of infection or new skin lesions.

Conclusion: This technique demonstrated to be effective in this case in the long-term follow-up.

Keywords: Complications, Deep brain stimulation, Functional neurosurgery, Parkinson's disease, Skin erosion

INTRODUCTION

Deep brain stimulation (DBS) has become increasingly common for patients with disabling symptoms due to movement disorders such as Parkinson's disease, dystonia, and tremor.^[5,9] Thus, the number of adverse events related to the surgical procedure has also increased.^[7] Despite being an increasingly performed procedure, some adverse events are still not fully understood, once clinical trials are typically conducted for a short time, and serious adverse events are relatively infrequent.^[24]

Skin erosion is the loss of epidermis over the implants (leads, internal pulse generator, wires, or extensions), exposing hardware and predisposing to local infections. Skin complications are the most common hardware-related complications, ranging from 1% to 15%.^[11,21,23,28] Erosions occur most commonly at the connector site, particularly when it is located over the mastoid region.^[14,16]

This is an open-access article distributed under the terms of the Creative Commons Attribution-Non Commercial-Share Alike 4.0 License, which allows others to remix, tweak, and build upon the work non-commercially, as long as the author is credited and the new creations are licensed under the identical terms.

©2021 Published by Scientific Scholar on behalf of Surgical Neurology International

Therefore, the authors describe a case of cutaneous erosion in DBS implants that were managed using a technique not yet described in the literature.

CASE REPORT

We present the case of a 62-year-old female diagnosed with Parkinson's disease with 10 years of the onset of the first symptoms. A 5 years of the initial diagnosis she developed on and off motor fluctuations, which responded initially to the optimized clinical treatment. About 2 years after, she was still experiencing frequent on and off periods associated with dyskinesias. This patient was assessed again by a movement disorders neurologist and was referred to the DBS surgical counseling. She underwent a full subthalamic nucleus DBS implant procedure in November 2018. In January 2019, during her recovery, she fell and sustained a minor head trauma, with abrasions on the lateral incision located close to the connector's site without wound dehiscence. In March 2019, an erosion of the connectors site [Figure 1] without evident associated infection or discharge was promptly identified when patient came for normal follow-up (FU) appointment. The surgical treatment was promptly performed on the same day, with careful debridement and release of the electrodes, connectors, and extensions to mobilize them anteriorly below the temporalis muscle that was incised to allow creating a space underneath it. By producing this space, the DBS connectors were inserted here being involved and wrapped by the most anterior part of the temporal muscle [Figures 2 and 3] to minimize the risk of further erosions. Unabsorbable sutures with Nylon were used to keep the muscle over the implants. We felt at the time of the procedure that by trying to cover the implants with local soft tissue without using a skin flap would be a reasonable choice minimizing a more extensive procedure. 500 mg of vancomycin powder (VP) was used on the surgical site, followed by 4 weeks of oral antibiotics (ceftriaxone). Follow-up of this case was unremarkable, without evidence of new erosions or infection of the neurostimulation hardware until the submission of this manuscript. No microorganisms were identified following swabs collected from the intraoperative procedure.

DISCUSSION

DBS is an effective and established treatment for movement disorders.^[2,12,18-20,27] Any surgical procedure with implants carries a risk of complications derived from the foreign body inserted in the patients. DBS procedures introduced a new series of possible complications related to its hardware. Infection, malfunction, lead migration, or system fracture can increase patient morbidity and should be considered when assessing and also consenting patients with regard to risks/benefits of this therapy.^[7,10,14] The use of DBS for less frequent indications or conditions, such as Tourette's

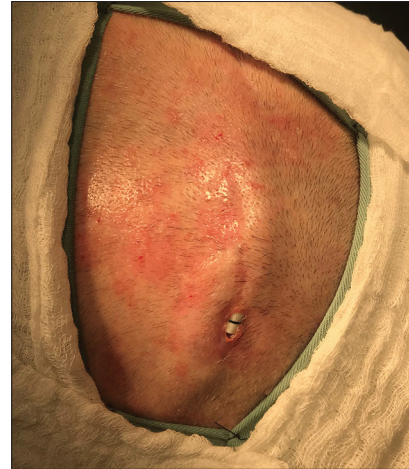

Figure 1: Skin erosion at the connector's site.

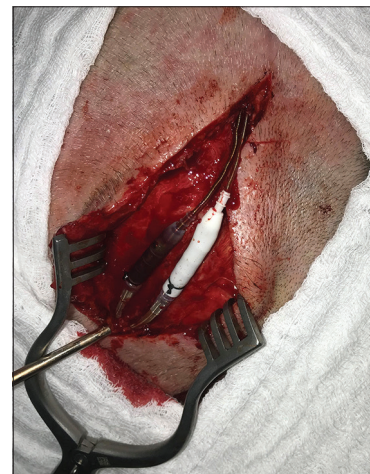

Figure 2: Exposure of the leads and connectors. Debridement and release of adhesions.

syndrome, cluster headache, and refractory partial epilepsy, was found to bear a higher incidence of hardware-related infections than the most usual and established indications such as Parkinson's disease and other movement disorders.^[16]

Several techniques were described in the literature for the management of scalp erosions related to brain stimulation implants. The most commonly used treatments are debridement and simple skin closure followed by antibiotics, as well as removal and/or replacement of parts of the system.^[8,14] Simple skin closure after surgical debridement is often performed by many centers as an attempt to save the implants in patients that are having benefits provided by the therapy. Also trying to save and keep these costly implants can be an effective and potentially less expensive option. Some centers, on the other hand, precede with removal of parts of the system or in some cases all the hardware.

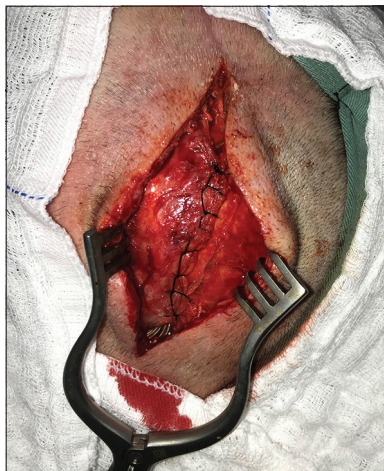

Figure 3: Anteriorization of connectors and the extensions and placement underneath the splitted temporal muscle. Implants involved and wrapped by the temporal muscle with topical vancomycin powder and secured with unabsorbable nylon sutures.

In a prospective analysis of 144 patients who underwent DBS, Constantoyannis *et al.* reported that straight incisions on the scalp increased the risk of infection compared with curvilinear incisions.^[8] Zhou *et al.* also proposed a modified skin incision to reduce skin-related complications. The double C-shaped incision was compared with the traditional incision and was shown to successfully reduce the incidence of skin complications.^[28]

In another study with 161 DBS patients, 24 had hardware-related complications. Only one patient had system infection, which occurred in the implanted battery (IPG). Skin erosion occurred in two patients (1.24%), one at the IPG site and one at the connector extension in the retromastoid region. For management of retromastoid erosion, the connector was moved medially to a new occipital bone groove. Skin erosion healed over time without removing the leads and extensions.^[15] Staudt *et al.* presented five cases of scalp erosion at the burr hole site. The average age of the patients was 67 years (53–77 years) and none of them presented signs of systemic infection. Two patients underwent local debridement and primary closure because the scalp defect was <1 cm. However, both had erosion recurrence and were eventually treated with a rotational flap. The remaining three patients underwent debridement and rotational flap as initial treatment. Thus, these five patients underwent a vascularized, tension-free rotational scalp flap with preservation of the electrodes under the pericranium. All patients had healthy flaps, the DBS hardware was functional, and there was no evidence of infection or local pain.^[26]

Another case was reported by Lanotte *et al.*, in which one patient presented with a small scalp erosion (2 cm²) after a

head trauma, and after excluding the presence of infection, surgical reconstruction was performed. With a portable Doppler, the frontal branch of the right temporal artery was located. The skin covering the device was completely excised and the flap was designed and harvested from the right half of the forehead to the innominate fascia. Another skin triangle was excised to allow flap rotation without tunneling. The donor area was grafted with the skin from the retroauricular region. Three months later, the flap was healthy and without signs of infection.^[17]

To prevent hardware erosion, Barrett *et al.* used an acellular dermal matrix that was surgically placed under the skin of 20 patients who had imminent signs of erosion. None of the patients treated with this technique required new hardware revision or removal surgery.^[4] Spiotta *et al.* presented two different approaches for managing hardware complications. The first technique was used in a 54-year-old patient who presented with erosion and infection at the burr hole site after a minor trauma. For this case, a temporoparietal occipital flap based on the superficial temporal artery with or without scalp expansion was used. In the second approach, in a 65-year-old patient, a scalp fasciocutaneous flap with or without cranioplasty was used, circumventing the prominence of the electrode to prevent future erosion. At the FU appointment 2 weeks later, the wounds were well healed.^[25] In a series of 21 patients with skin erosion after placement of DBS, Gómez and Hontanilla also used flaps to cover the skin defect, originating from the scalp itself (rotation flap), latissimus, thigh, or forearm.^[13] According to some authors, using VP on the wounds seems to be safe and reduce the incidence of surgical site infections after DBS procedures.^[1,22] In one long retrospective study with 242 patients who undergone 245 DBS implantations, the authors showed that the surgical site infection in the group that received intrawound topical VP was 68% lower despite some limitations of this work.^[1] Other authors have not shown that the use of VP is beneficial.^[6] In our practice, we recommend the use of intrawound VP since it increases the antibiotic concentrations locally^[3] without further risks, thus decreasing the incidence of infection.

CONCLUSION

There is no standardized technique for managing scalp erosions in the literature. All methods described for managing this type of complication are valid and have satisfactory results. Many high-volume DBS centers have their own experience and way of resolving hardware complications and especially skin erosions. Despite the lack of a unique or single surgical technique suitable for all cases of skin complications, the most important fact is that each case will probably have a more suitable and personalized treatment option. Surgical flaps demonstrated to be efficient resolving skin erosions and also skin retractions as well. For some cases creating

grooves on the skull bone can also be performed to bury the connections. In this particular case report, we demonstrated that mobilizing the connectors anteriorly to be overlapped and wrapped by the temporal muscle was effective in this case without the use of a skin flap. Also using VP seems to be efficient and prevents infection.

Statement of ethics

The authors have no ethical conflicts to disclose. Written informed consent was obtained from the patient for publication of this case report and any accompanying images.

Declaration of patient consent

Patient's consent not required as patients identity is not disclosed or compromised.

Financial support and sponsorship

Nil.

Conflicts of interest

There are no conflicts of interest.

REFERENCES

- Abode-Iyamah KO, Chiang HY, Woodroffe RW, Park B, Jarczcek FJ, Nagahama Y, et al. Deep brain stimulation hardware-related infections: 10-year experience at a single institution. *J Neurosurg* 2018;129:1-10.
- Aum DJ, Tierney TS. Deep brain stimulation: Foundations and future trends. *Front Biosci (Landmark Ed)* 2018;23:162-82.
- Bakhsheshian J, Dahdaleh NS, Lam SK, Savage JW, Smith ZA. The use of vancomycin powder in modern spine surgery: Systematic review and meta-analysis of the clinical evidence. *World Neurosurg* 2015;83:816-23.
- Barrett TF, Rasouli JJ, Taub P, Kopell BH. Technical note: Preemptive surgical revision of impending deep brain stimulation hardware erosion. *World Neurosurg* 2018;111:41-6.
- Beitz JM. Parkinson's disease: A review. *Front Biosci* 2014;6:65-74.
- Bernstein JE, Kashyap S, Ray K, Ananda A. Infections in deep brain stimulator surgery. *Cureus* 2019;11:e5440.
- Boviatsis EJ, Stavrinou LC, Themistocleous M, Kouyialis AT, Sakas DE. Surgical and hardware complications of deep brain stimulation. A seven-year experience and review of the literature. *Acta Neurochir (Wien)* 2010;152:2053-62.
- Constantoyannis C, Berk C, Honey CR, Mendez I, Brownstone RM. Reducing hardware-related complications of deep brain stimulation. *Can J Neurol Sci* 2005;32:194-200.
- Crowell JL, Shah BB. Surgery for dystonia and tremor. *Curr Neurol Neurosci Rep* 2016;16:22.
- Doshi PK. Long-term surgical and hardware-related complications of deep brain stimulation. *Stereotact Funct Neurosurg* 2011;89:89-95.
- Doshi PK, Rai N, Das D. Surgical and hardware complications of deep brain stimulation-a single surgeon experience of 519 cases over 20 years. *Neuromodulation* 2021.
- Franceschini PH, Bhargava D, Eldridge PR. Outcomes following deep brain stimulation for Parkinson's disease: A single centre experience. *Arq Bras Neurocir Braz Neurosurg* 2018;37.
- Gomez R, Hontanilla B. The reconstructive management of hardware-related scalp erosion in deep brain stimulation for Parkinson disease. *Ann Plast Surg* 2014;73:291-4.
- Hamani C, Lozano AM. Hardware-related complications of deep brain stimulation: A review of the published literature. *Stereotact Funct Neurosurg* 2006;84:248-51.
- Hu X, Jiang X, Zhou X, Liang J, Wang L, Cao Y, et al. Avoidance and management of surgical and hardware-related complications of deep brain stimulation. *Stereotact Funct Neurosurg* 2010;88:296-303.
- Jitkrisadakul O, Bhidayasiri R, Kalia SK, Hodaie M, Lozano AM, Fasano A. Systematic review of hardware-related complications of deep brain stimulation: Do new indications pose an increased risk? *Brain Stimul* 2017;10:967-76.
- Lanotte M, Verna G, Panciani PP, Taveggia A, Zibetti M, Lopiano L, et al. Management of skin erosion following deep brain stimulation. *Neurosurg Rev* 2009;32:111-4; discussion 114-5.
- Lozano AM, Lipsman N, Bergman H, Brown P, Chabardes S, Chang JW, et al. Deep brain stimulation: Current challenges and future directions. *Nat Rev Neurol* 2019;15:148-60.
- McKinnon C, Gros P, Lee DJ, Hamani C, Lozano AM, Kalia LV, et al. Deep brain stimulation: Potential for neuroprotection. *Ann Clin Transl Neurol* 2019;6:174-85.
- Obeso JA, Stamelou M, Goetz CG, Poewe W, Lang AE, Weintraub D, et al. Past, present, and future of Parkinson's disease: A special essay on the 200th Anniversary of the Shaking Palsy. *Mov Disord* 2017;32:1264-310.
- Patel DM, Walker HC, Brooks R, Omar N, Ditty B, Guthrie BL. Adverse events associated with deep brain stimulation for movement disorders: Analysis of 510 consecutive cases. *Neurosurgery* 2015;11 Suppl 2:190-9.
- Rasouli JJ, Kopell BH. The adjunctive use of vancomycin powder appears safe and may reduce the incidence of surgical-site infections after deep brain stimulation surgery. *World Neurosurg* 2016;95:9-13.
- Sixel-Doring F, Trenkwalder C, Kappus C, Hellwig D. Skin complications in deep brain stimulation for Parkinson's disease: Frequency, time course, and risk factors. *Acta Neurochir (Wien)* 2010;152:195-200.
- Sorar M, Hanalioglu S, Kocer B, Eser MT, Comoglu SS, Kertmen H. Experience reduces surgical and hardware-related complications of deep brain stimulation surgery: A single-center study of 181 patients operated in six years. *Parkinsons Dis* 2018;2018:3056018.
- Spiotta AM, Bain MD, Deogaonkar M, Boulis NM, Rezai AR, Hammert W, et al. Methods of scalp revision for deep brain stimulator hardware: Case report. *Neurosurgery* 2008;62 Suppl 1:249-50; discussion 250.
- Staudt MD, Pourtaheri N, Lakin GE, Soltanian HT, Miller JP. Surgical management of deep brain stimulator scalp erosion without hardware removal. *Stereotact Funct Neurosurg*

- 2017;95:385-91.
27. Sui Y, Tian Y, Ko WK, Wang Z, Jia F, Horn A, *et al.* Deep brain stimulation initiative: Toward innovative technology, new disease indications, and approaches to current and future clinical challenges in neuromodulation therapy. *Front Neurol* 2021;11:597451.
28. Zhou R, Ma Y, Liu W, Miao S, Zhang Y. Long-term effect of

modified incision to prevent related complications in deep brain stimulation. *World Neurosurg* 2018;117:280-3.

How to cite this article: Britz JP, Franceschini PR, Ramos MB, de Aguiar PH, Farah JO, Aguiar PH. Skin erosion in deep brain stimulation procedures: Using the temporalis muscle to treat this complication – A technical note. *Surg Neurol Int* 2021;12:355.