

## A rare cause of excruciating chest pain mimicking acute coronary syndrome

L. Hobohm<sup>1</sup> · D. Krompiec<sup>1</sup> · R. Michel<sup>1</sup> · Y. Yang<sup>2</sup> · F. Schmidt<sup>1</sup> · C. Düber<sup>2</sup> · T. Münzel<sup>1</sup> · P. Wenzel<sup>1</sup>

Published online: 26 October 2016

© The Author(s) 2016. This article is available at SpringerLink with Open Access.

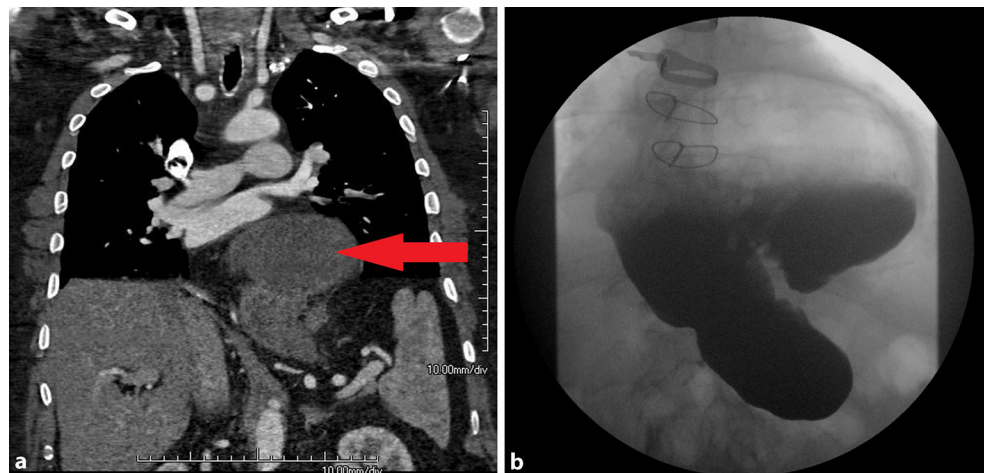
A 62 year-old male presented to the chest pain unit with chest pain and nausea, reporting that the symptoms occurred one hour after dinner. His medical history included a foudroyant event of pulmonary embolism with embolectomy in 2012.

Due to clinical deterioration and the history of pulmonary embolism, we decided to perform a contrast computed tomography angiography (CT). We could rule out aortic dissection and pulmonary embolism, However, CT

revealed a mixed axial para-oesophageal upside-down stomach (UDS) compressing the left ventricle (Fig. 1).

UDS is the rarest type of hiatal hernia and can manifest clinically in a wide variety of symptoms as demonstrated in this case [1]. As causes of chest pain, gastrointestinal disease other than peptic ulcer or reflux-related diseases which might include UDS were reported to be below 1 % [2]. In UDS patients, complications such as incarceration, volvulus development as well as acute gastric bleeding can lead to a life-threatening emergency with prevalence of 30.4 % and can require immediate surgery [3, 4].

**Fig. 1** Computed tomography (a) and gastrointestinal contrast series (b) show a mixed axial and para-oesophageal upside-down stomach (red arrow) compressing the left ventricle, without any incarcerated portions of the stomach



✉ L. Hobohm  
lukas.hobohm@unimedizin-mainz.de

<sup>1</sup> Center of Cardiology, Cardiology I, Johannes Gutenberg University Medical Center Mainz, Mainz, Germany

<sup>2</sup> Department of Diagnostic and Interventional Radiology, Johannes Gutenberg University Medical Center Mainz, Mainz, Germany

**Conflict of interest** L. Hobohm, D. Krompiec, R. Michel, Y. Yang, F. Schmidt, C. Düber, T. Münzel and P. Wenzel declare that they have no competing interest.

**Open Access** This article is distributed under the terms of the Creative Commons Attribution 4.0 International License (<http://creativecommons.org/licenses/by/4.0/>), which permits unrestricted use, distribution, and reproduction in any medium, provided you give appropriate credit to the original author(s) and the source, provide a link to the Creative Commons license, and indicate if changes were made.

## References

1. Hill LD, Tobias JA. Paraesophageal hernia. *Arch Surg.* 1968;96:735–44.
2. Verdon F, Herzig L, Burnand B, et al. Chest pain in daily practice: occurrence, causes and management. *Swiss Med Wkly.* 2008;138:340–7.
3. Hill LD. Incarcerated paraesophageal hernia. A surgical emergency. *Am J Surg.* 1973;126:286–91.
4. Trainor D, Duffy M, Kennedy A, Glover P, Mullan B. Gastric perforation secondary to incarcerated hiatus hernia: an important differential in the diagnosis of central crushing chest pain. *Emerg Med J.* 2007;24:603–4.

