

# A Collet–Sicard syndrome due to internal carotid artery dissection associated with cerebral amyloid angiopathy–related inflammation

SAGE Open Medical Case Reports  
Volume 6: 1–4  
© The Author(s) 2018  
Reprints and permissions:  
sagepub.co.uk/journalsPermissions.nav  
DOI: 10.1177/2050313X18777176  
journals.sagepub.com/home/sco



Vanessa Saliou<sup>1</sup>, Douraied Ben Salem<sup>2,3</sup>, Julien Ognard<sup>2</sup>, Dewi Guellec<sup>4</sup>, Pascale Marcorelles<sup>5,6</sup>, François Rouhart<sup>1</sup>, Fabien Zagnoli<sup>1</sup> and Serge Timsit<sup>1,7</sup>

## Abstract

**Background:** Cerebral amyloid angiopathy–related inflammation is a rare condition with approximately 100 reported cases. Its clinical manifestations are varied. We report here a novel presentation of this disease.

**Case presentation:** A 61-year-old Caucasian man presented with rapidly progressive paralysis of the IX, X, XI and XII right cranial nerves associated with right central facial nerve palsy. Brain computed tomography angiography and cerebral catheter angiography found a focal fusiform enlargement of the distal cervical portion of the right internal carotid artery, related to a pseudo-aneurysm suggesting an evolution of a dissection and intra-cranial vessel dysplasia. Brain magnetic resonance imaging showed multiple asymmetrical subcortical regions of hyperintensity on T2 fluid-attenuated inversion recovery sequences. Punctiform cortical hyposequences on T2-weighted gradient echo magnetic resonance imaging sequences were mostly congruent with the white matter hyperintensities. There was a decreased cerebral perfusion at the frontal hyperintense fluid-attenuated inversion recovery region. Spectrometry identified a lactate–lipid peak. A brain biopsy showed intravascular amyloid deposits. Corticosteroid therapy was initiated, leading to a dramatic improvement of both clinical condition and magnetic resonance imaging brain lesions.

**Conclusion:** This case report suggests that extra-cranial vasculitis and dysplasia can exceptionally be found in patients satisfying cerebral amyloid angiopathy–related inflammation criteria.

## Keywords

Cerebral amyloid angiopathy, cerebral amyloid angiopathy–related inflammation, vasculitis, dissection, Collet–Sicard syndrome

Date received: 27 May 2017; accepted: 18 April 2018

## Background

The term “cerebral amyloid angiopathy–related inflammation” (CAA-ri) was introduced to refer to inflammatory phenomena in relation to amyloid  $\beta$  protein deposits on cortical cerebral and meningeal vessel walls.<sup>1</sup> Collet–Sicard syndrome, on the other hand, consists of unilateral IX–XII cranial nerve lesions.<sup>2</sup> Both of these entities are extremely rare, with less than 100 cases described for each.<sup>1,2</sup> We report a unique presentation of CAA-ri associated with Collet–Sicard syndrome.

## Case presentation

A 61-year-old right-handed man without particular history, or risk factors presented for otorhinolaryngology consultation

<sup>1</sup>Service de Neurologie, Hôpital de la Cavale Blanche, CHRU de Brest, Brest, France

<sup>2</sup>Service de Neuro-Radiologie, Hôpital de la Cavale Blanche, CHRU de Brest, Brest, France

<sup>3</sup>LaTIM – INSERM UMR 1101, Université de Bretagne Occidentale (UBO), Brest, France

<sup>4</sup>Service de Rhumatologie, Hôpital de la Cavale Blanche, CHRU de Brest, Brest, France

<sup>5</sup>Service d'Anatomopathologie, Hôpital Morvan, CHRU de Brest, Brest, France

<sup>6</sup>LNBEA 4685, Université de Bretagne Occidentale (UBO), Brest, France

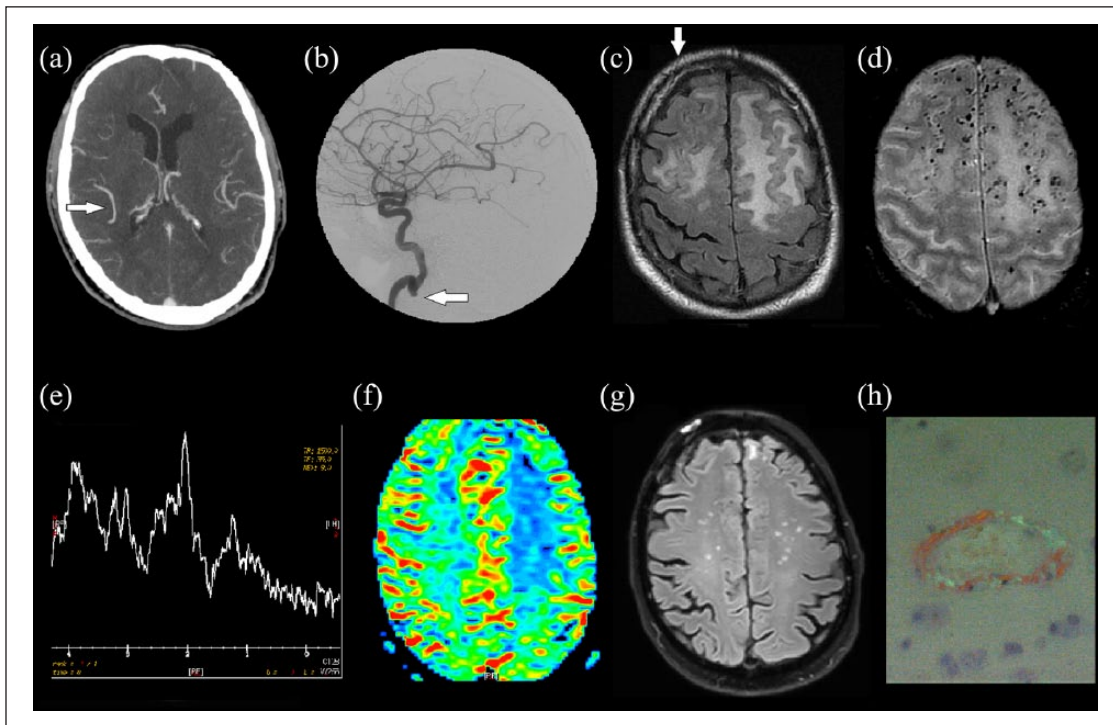
<sup>7</sup>INSERM-1078, Université de Bretagne Occidentale (UBO), Brest, France

## Corresponding Author:

Serge Timsit, Service de Neurologie, Hôpital de la Cavale Blanche, CHRU de Brest, Boulevard Tanguy Prigent, 29200 Brest, France.

Email: serge.timsit@chu-brest.fr





**Figure 1.** Complementary examinations: Brain CT angiography (a) and brain arteriography (b): On brain CT angiography, there was an ectatic aspect of the distal branch of the right middle cerebral artery (arrow on (a)). Cerebral catheter angiography found a focal fusiform enlargement of the distal cervical portion of the right internal carotid artery, related to a pseudo-aneurysm suggesting an evolution of a dissection, above which a string of beads suggesting a dysplastic artery (arrow on (b)). Brain MRI: (c) T2-weighted FLAIR sequence, axonal slice: bilateral frontal lobe hypersignal. Moderate mass effect. (d) T2-weighted gradient echo sequence: numerous punctiform cortical hyposignals adjacent to white matter infiltration regions. (e) Spectrometry, TE (echo time) 35 ms: normal NAA/Cr and Cho/Cr ratios, slight lipid–lactate peak at 1.33 ppm. (f) Color map, perfusion-weighted sequence: reduced rCBV in FLAIR hypersignal region. (g) Control MRI after 3 months of corticotherapy: T2-weighted FLAIR sequence, axonal slice, showing clear regression of white matter hypersignal, compared to initial images. Right frontal cerebral biopsy (arrow on (c)): (h) arachnoid and cortical vessels stained by Congo red. Polarized light: green birefringence of amyloid deposits.

after 48 h cervicgia, dysphonia, swallowing and cognitive disorders. Examination found a right central facial palsy, a nasal voice, a rightward deviation of the tongue on protraction, an asymmetric soft palate and hanging curtain sign affecting the right side. Nasal endoscopy found right hemipharyngeal and hemilaryngeal paresis and right pyriform sinus stasis. No headache was reported. The patient showed slowed ideomotor response without detectable cognitive impairment, on usual cognitive battery (MMSE=29/30, normal Batterie Rapide d'Efficiency Frontale (BREF), Dubois and clock-drawing tests).

Brain computed tomography (CT) scan found frontal and left temporal cortical and subcortical edema. On brain CT angiography, there was an ectatic aspect of the distal branch of the right middle cerebral artery (Figure 1(a)). Cerebral catheter angiography found a focal fusiform enlargement of the distal cervical portion of the right internal carotid artery, related to a pseudo-aneurysm suggesting an evolution of a dissection, above which a string of beads suggesting a dysplastic artery (Figure 1(b)). Brain magnetic resonance imaging (MRI) found frontal (left predominant) and left temporal

hyperintensities on T2-weighted fluid-attenuated inversion recovery (FLAIR) sequences accompanied with hypointensities on T1, high intensity signal on diffusion-weighted sequences and increased apparent diffusion coefficient (ADC). It also showed numerous punctiform cortical hyposignals adjacent to areas of white-matter infiltration on T2-weighted gradient echo sequences. There was no contrast uptake and moderate mass effect (Figure 1(c) and (d)). On spectroscopy, NAA/Cr and Cho/Cr ratios were normal. There was however a slight lipid–lactate peak at 1.33 ppm (Figure 1(e)). On perfusion sequences, relative cerebral blood volume (rCBV) was low (Figure 1(f)). Standard biological assessment was normal except for CRP at 20 mg/L (normal value <5 mg/L). HIV, HBV, HCV and syphilis serology and immune assessment were normal. Cryoglobulinemia was negative. Cerebrospinal fluid (CSF) analysis was normal with no intrathecal immunoglobulin secretion, and normal angiotensin conversion enzyme (ACE) level. Tau and phospho-tau-181 protein levels were normal, at 335 ng/L (Alzheimer's threshold, >350 ng/L) and 44 ng/L (Alzheimer's threshold, >60 ng/L), respectively.  $\beta$ -amyloid 1-40 was

normal at 10.05 ng/L.  $\beta$ -amyloid 1-42 was low at 436 ng/L (Alzheimer's threshold, >700 ng/L) and  $\beta$ -amyloid 1-42/1-40 ratio was 0.043 (Alzheimer's threshold, >0.075), in favor of amyloid deposits. Thoraco-abdomino-pelvic CT was normal. A positron emission tomography (PET)-scan was performed and was normal with no arguments for aortitis and vasculitis.

Right frontal cerebral biopsy (arrow on Figure 1(c)) found thick-walled arachnoid and cortical vessels, without perivascular inflammatory infiltrate, granuloma or giant cells. Specific staining revealed congophilic amyloid deposits (Figure 1(h)). Genotype analysis showed that the patient was homozygous for the  $\epsilon 4$  variant of apolipoprotein E.

The patient received 1 g intravenous methylprednisolone, after cerebral biopsy was made, for 3 consecutive days, then 1 mg/kg corticosteroids daily, progressively tapered over 6 months. At 3-month follow-up, the facial palsy had regressed, the conversational voice was of good quality, swallowing was restored and there was no more cognitive disorders. After 6-month treatment, CSF analysis was normal, tau protein levels had decreased to 241 ng/L, and  $\beta$ -amyloid 1-40 and 1-42 levels were stable, respectively, 10.37 and 443 ng/L. Control brain MRI showed clear regression of FLAIR hyper-signals (Figure 1(g)).

## Conclusion

Our patient presented a peripheral right palsy of the last four cranial nerves (IX, X, XI, XII), constituting Collet–Sicard syndrome.<sup>2</sup> This syndrome, also named syndrome of the Foramen Lacerum, could be explained here by the aspect of carotid dissection of the skull base level.<sup>3,4</sup> Our patient also had central neurological involvement, including right central facial palsy and slowed ideomotor response which could be consistent with CAA-ri.

MRI showed white matter abnormalities with multiple micro-bleeding, immediately suggestive of CAA-ri.<sup>1,5</sup> CAA-ri was also based on behavioral disorder,  $\epsilon 4$  homozygosity and amyloid deposits in vessels on pathologic examination.<sup>1,5</sup>

According to CAA-ri diagnostic criteria, the diagnosis of this patient is probable as all clinical and radiological criteria are met, but not certain as no perivascular or parietal inflammation was found together with amyloid deposits.<sup>5,6</sup> The absence of inflammatory infiltrate in this case can be explained by the right site of the biopsy, which was not performed in predominant left brain MRI inflammatory area. Since infectious and other causes were ruled out, patient was treated with immunosuppressive therapy as recommended.<sup>5</sup>

CAA-ri is divided into two subtypes: inflammatory cerebral amyloid angiopathy (ICAA) and amyloid- $\beta$ -related angiitis (ABRA), according to histopathology.<sup>7</sup> ICAA is characterized by perivascular inflammation and ABRA by a vasculitic transmural and intramural infiltration. ICAA and ABRA are considered by some authors as subsets of primary

angiitis of the central nervous system (PACNS).<sup>8</sup> The diagnosis of ICAA is more likely for our case due to the dramatic response to corticosteroids alone, the absence of enhancement of lesions on MRI and the ApoE genotype  $\epsilon 4/\epsilon 4$ .<sup>7,8</sup> In 2011, Di Francesco's et al. hypothesized that inflammation in CAA-ri is an autoimmune response specific to amyloid protein deposits and showed an intrathecal synthesis of anti- $\beta$ -amyloid antibodies reduced after corticosteroids therapy. Similarly, it was also described that  $\beta$ -amyloid 1-40, 1-42, tau and phospho-tau-181 proteins rates in the CSF decrease after immunosuppressive treatment, as we observed in this case.<sup>9</sup>

Spectroscopy found a lipid–lactate peak compatible with cell hypoxia. There was hypoperfusion in the inflammatory region, which was compatible with vasculitis. The literature contains little description of CNS vasculitis aspects on spectroscopy or perfusion: case reports show diminished rCBV on perfusion and elevated glutamate–glutamine and/or lactate–lipid peaks on spectrometry in PACNS.<sup>10</sup> To our knowledge, there are no published descriptions of CAA-ri profiles in MRI perfusion. We suggest here the interest of spectrometry and perfusion profiles for the study of CAA-ri.

To our knowledge, the present paper is the first description of dissection or dysplasia aspect associated with CAA-ri. It is unlikely that these two rare events are unrelated in the present case, given the chronology of clinical central and peripheral presentation associated with concomitant brain and vessels imaging abnormalities.

Carotid dissection is a very rare complication of vasculitis and was reported in only few case reports.<sup>11</sup> To our knowledge, only one observation of carotid dissection during the course of PACNS has been previously reported.<sup>12</sup> In the present case, it can be hypothesized that carotid dissection was caused by extensive inflammation of the arterial wall, secondary to deposition of amyloid protein in the wall of cortical and meningeal vessels. A study to determine factors associated with dissection in giant cell arteritis found a higher frequency of active aortitis in patients with dissection, suggesting the role of active inflammation in the occurrence of dissection in patients with vasculitis.<sup>13</sup>

This case report suggests that extra-cranial vasculitis and dysplasia can exceptionally be found in patients satisfying CAA-ri criteria. In future observational studies of CAA-ri patients, dedicated angiography could be performed to determine the frequency, characteristics and clinical significance of arterial abnormalities.

## Acknowledgements

Thanks to Jean-Baptiste Noury, Philippe Codron and Gwenael Conq for their precious advice and contributions. V.S., F.R., D.B.S., S.T. conceived the manuscript, carried out the acquisition, analysis and interpretation of data. V.S., D.B.S., J.O., D.G., P.M., F.Z. and S.T. have been involved in drafting the manuscript and revising it critically for important intellectual content. All authors read and approved the final manuscript.

### Availability of data and materials

The datasets supporting the conclusions of this article are included within the article and its additional files.

### Declaration of conflicting interests

The author(s) declared no potential conflicts of interest with respect to the research, authorship and/or publication of this article.

### Ethics and consent to participate

Written informed consent for publication of their clinical details and clinical images was obtained from the patient. A copy of the consent form is available for review by the editor of this journal.

### Ethics approval

Our institution does not require ethical approval for reporting individual cases or case series.

### Funding

The author(s) received no financial support for the research, authorship and/or publication of this article.

### Informed consent

Written informed consent was obtained from the patient(s) for their anonymized information to be published in this article.

### References

1. Eng JA, Frosch MP, Choi K, et al. Clinical manifestations of cerebral amyloid angiopathy-related inflammation. *Ann Neurol* 2004; 55(2): 250–256.
2. Collet FJ. Sur un nouveau syndrome paralytique pharyngolaryngé par blessure de guerre (hémiplégie glosso-laryngoscapulo-pharyngée). *Lyon Méd* 1915; 124: 121–129.
3. Sicard J. Syndrome de carrefour condylo-dechire posterieur (type pur de paralysie laryngée associée). *Marseille Med* 1917; 53: 383.
4. Smith R, Tassone P and Saada J. Collet-Sicard syndrome as a result of unilateral carotid artery dissection. *BMJ Case Rep* 2013; 2013: bcr2013200358.
5. Chung KK, Anderson NE, Hutchinson D, et al. Cerebral amyloid angiopathy related inflammation: three case reports and a review. *J Neurol Neurosurg Psychiatry* 2011; 82(1): 20–26.
6. Auriel E, Charimidou A, Gurol ME, et al. Validation of clinico-radiological criteria for the diagnosis of cerebral amyloid angiopathy-related inflammation. *JAMA Neurol* 2016; 73(2): 197–202.
7. Chu S, Xu F, Su Y, et al. Cerebral amyloid angiopathy (CAA)-related inflammation: comparison of inflammatory CAA and amyloid- $\beta$ -related angiitis. *J Alzheimers Dis* 2016; 51(2): 525–532.
8. Salvarani C, Hunder GG, Morris JM, et al. A $\beta$ -related angiitis: comparison with CAA without inflammation and primary CNS vasculitis. *Neurology* 2013; 81(18): 1596–1603.
9. Piazza F, Greenberg SM, Savoirdo M, et al. Anti-amyloid  $\beta$  autoantibodies in cerebral amyloid angiopathy-related inflammation: implications for amyloid-modifying therapies. *Ann Neurol* 2013; 73(4): 449–458.
10. Muccio CF, Di Blasi A, Esposito G, et al. Perfusion and spectroscopy magnetic resonance imaging in a case of lymphocytic vasculitis mimicking brain tumor. *Pol J Radiol* 2013; 78(3): 66–69.
11. Herath HMMTB, Pahalagamage SP, Withana D, et al. Complete ophthalmoplegia, complete ptosis and dilated pupil due to internal carotid artery dissection: as the first manifestation of Takayasu arteritis. *BMC Cardiovasc Disord* 2017; 17(1): 201.
12. Jamil O, Tausky P, Schmidt RH, et al. Fulminant vasculitis associated with extracranial dissections and occlusion, ischemic strokes, and aneurysm rupture: case report and review of the literature. *World Neurosurg* 2016; 91: 674.e7–674.e11.
13. Kermani TA, Warrington KJ, Crowson CS, et al. Predictors of dissection in aortic aneurysms from giant cell arteritis. *J Clin Rheumatol* 2016; 22(4): 184–187.