

Case report

First report of a very rare complication in a case of nonsmall cell lung carcinoma

A 45-year-old male patient presented with scarcely productive cough with 3 months of evolution without other respiratory complaints, no chest pain and no constitutional symptoms, including no weight loss.

Overall, the patient was in good health. He was a car driver, an active smoker of 60 pack-years and had a medical history of dyslipidaemia and chronic laryngitis. The patient had undergone a splenectomy when he was 25 years old due to abdominal trauma. Additionally, he had a family medical history of breast cancer.

The patient first consulted his primary care physician due to these symptoms. On examination, decreased breath sounds were auscultated in the left upper lobe and oxygen saturation was 96%.

The chest radiograph showed enlargement of the left mediastinum and hypotransparency of the left just-hilar parenchyma. Consequently, a thoracic computed tomography (CT) scan (figure 1) was requested to better characterise the findings. It showed a solid pulmonary nodule in the left upper lobe of 26×24 mm, a pre-vascular adenopathy of 20 mm and small adenopathies in the left hilum.

Due to the suspicion of lung cancer, the patient was referred to a pulmonology appointment.

He underwent a positron emission tomography (PET) scan (figure 2) that showed uptake with high metabolism at the level of the left upper lobe lesion and in the left pre-vascular and ipsilateral hilar ganglia. No other alterations were found in other locations.

To obtain the histological diagnosis, he underwent a bronchofibroscopy. In the left bronchial tree, at the level of division B1/B2, a small polypoid formation was identified. At this level, bronchoalveolar lavage, bronchial brushing, bronchial biopsies and transbronchial biopsies were performed. The cytology of all samples was negative.

Given the negative result of the cytology, an endobronchial echo-endoscopy was performed to obtain a histological diagnosis and to determine mediastinal staging. Systemic exploration of ganglion stations was carried out, with ganglion identification

Cite as: Moreira I, Vilarica AS, Alves P. First report of a very rare complication in a case of nonsmall cell lung carcinoma. *Breathe* 2021; 17: 210107.

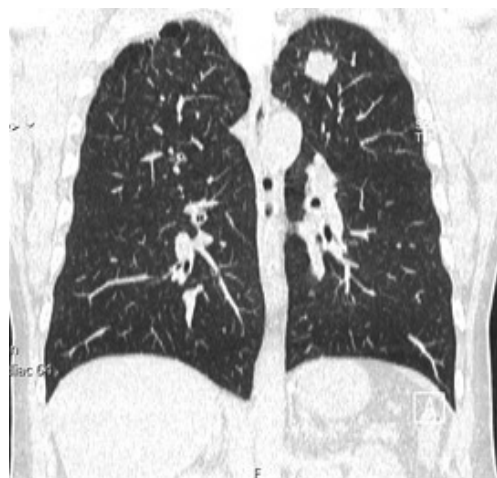

Figure 1 Thoracic CT scan.

 @ERSpublications

While immune checkpoint inhibitors like pembrolizumab are promising agents for nonsmall cell lung carcinoma treatment, increased use is leading to increased immune-related adverse events, including endocrinopathies such as adrenal insufficiency. <https://bit.ly/3iMfhUk>



CrossMark



© ERS 2022

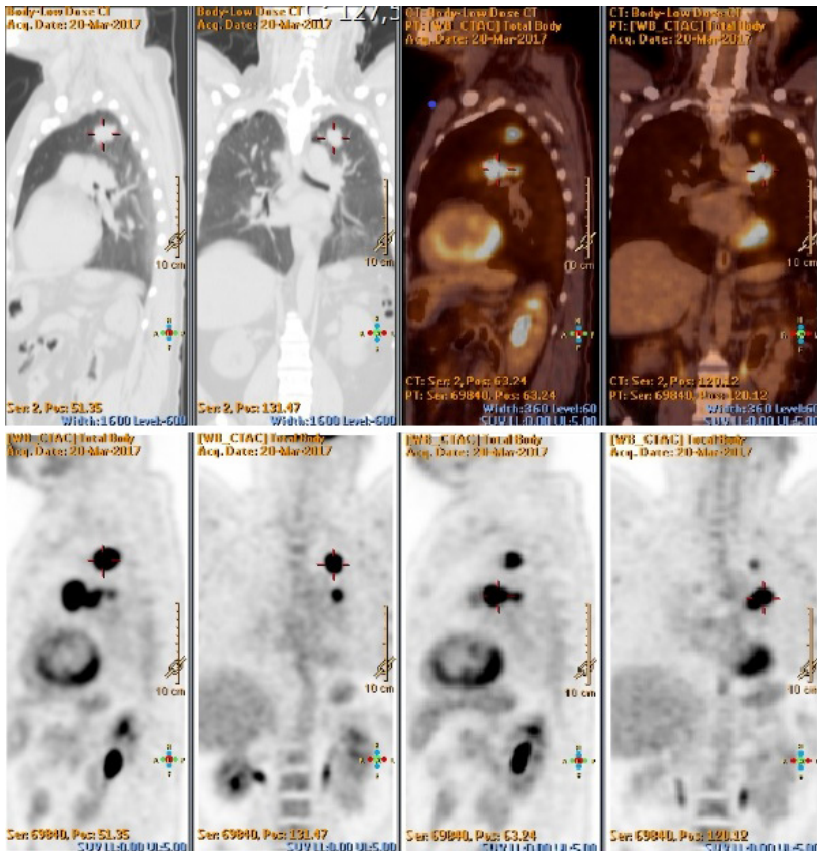


Figure 2 PET scan.

at station level 4 L (lower paratracheal), 10 L (pulmonary) and 11 L (pulmonary). Due to technical impossibility, 10 L punctures were not performed; in stations 4 L and 11 L, immunohistochemistry was positive for CK7 and TTF-1 and negative for CK20 and p40. These findings favoured the diagnosis of lung adenocarcinoma.

The patient had positive expression (>50%) of the programmed cell death ligand 1 (PD-L1). Epidermal growth factor receptor mutations, anaplastic lymphoma kinase rearrangements and c-ros oncogene 1 rearrangements were not detected.

It should be noted that there was no evidence of metastases in the brain CT scan, and only a chronic inflammatory component in the right mastoid and slight inflammatory changes in the sinuses were observed.

Task 1

According to the American Joint Committee on Cancer (AJCC), tumour, nodes and metastases (TNM) classification for nonsmall lung cancer (8th edition), which is the staging in this case?

- cT2bN3M0 (stage IIIB)
- cT1bN1M0 (stage IIB)
- cT1cN2M0 (stage IIIA)
- cT2aN2M0 (stage IIIA)

Go to Answers >>

Task 2

According to the data we have so far, which treatment would you consider?

- Neoadjuvant chemotherapy
- Video-assisted thoracic surgery (VATS) left upper lobectomy with systematic lymphadenectomy
- First-line immunotherapy with pembrolizumab
- Combination of pembrolizumab and chemotherapy

Go to Answers >>

The patient completed three cycles with good tolerance and without complications. He was also successfully referred to a smoking cessation consultation.

Reassessment CT was performed after chemotherapy. A reduction of the left upper lobe nodule and of hilar adenopathies was observed. However, superior mediastinal lymph nodes (2R - right upper paratracheal) were enlarged.

The case was discussed again in a thoracic oncology multidisciplinary meeting. Given the adenopathy in the aorto-pulmonary window with pathological imaging criteria, it was decided to perform a video-assisted mediastinoscopic lymphadenectomy (VAMLA). Thus, after the three cycles of neoadjuvant chemotherapy, the VAMLA-extracted 4L-lymph nodes (as well as 2R, 4R and 7-lymph nodes) showed complete pathological regression.

As the patient had Eastern Cooperative Oncology Group (ECOG) Performance Status 0 and no respiratory function contraindication for lung surgical resection, a left upper lobectomy with systematic mediastinal lymph node resection by posterior thoracotomy was performed with curative intent, without any major complications.

After surgical resection the pathological (p)TNM was pT2aN2. The World Health Organization (WHO) subtype of adenocarcinoma was solid-predominant adenocarcinoma of the lung. Additional molecular testing was performed on the resected operating piece and showed no epidermal growth factor receptor mutations, anaplastic lymphoma kinase rearrangements and c-ros oncogene 1 rearrangements.

Afterwards, the patient underwent sequential adjuvant chemotherapy and radiotherapy. He completed four cycles of adjuvant chemotherapy with cisplatin and vinorelbine, with good tolerance and without complications. He completed adjuvant radiotherapy, completing the total dose of 50 Gy-25 Fr⁻¹, with good tolerance and with no associated toxicity.

Follow-up of the patient was conducted by performing thoracoabdominal CT scan and analytical studies, which evaluated tumour markers. 4 months after completing sequential

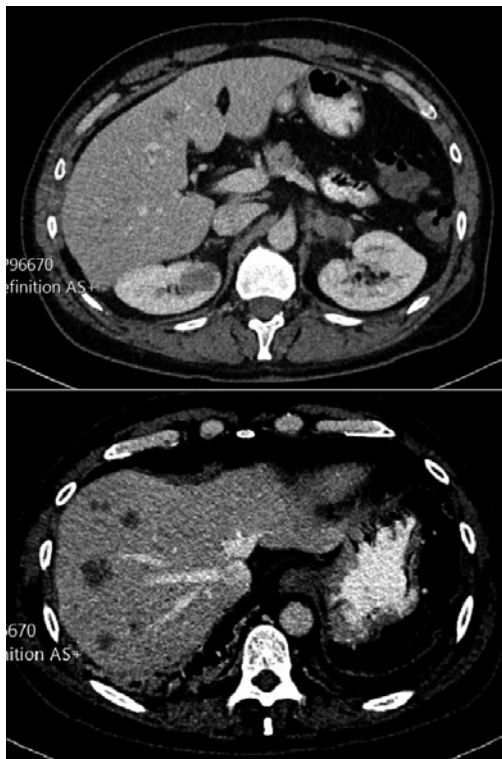


Figure 3 Abdominal CT scan.

adjuvant chemotherapy and radiotherapy, the CT scan showed disease recurrence, with suspicion of hepatic, renal, and adrenal metastasis as well as intra-abdominal and retroperitoneal adenopathies (figure 3).

Task 3

In this case, what is the indicated treatment for lung cancer recurrence, now staging IVB?

- Liquid biopsy to search for next-generation sequencing (NGS) gene panel
- First-line immunotherapy with pembrolizumab
- Combination of pembrolizumab and chemotherapy
- Second-line chemotherapy

[Go to Answers >>](#)

Tissue biopsy of the metastatic sites or liquid biopsy were not performed, since there was such a recent anatomopathological study of the operating piece with molecular testing and the patient was a heavy smoker, so it was considered by the multidisciplinary team that the risk of delaying the start of treatment would outweigh its benefit.

Up to the 10th cycle of treatment, he showed a partial response. Subsequently he maintained stable disease until the 26th cycle of treatment.

In the appointment scheduled for the 26th cycle of pembrolizumab treatment, the patient reported asthenia, dizziness, mental confusion,

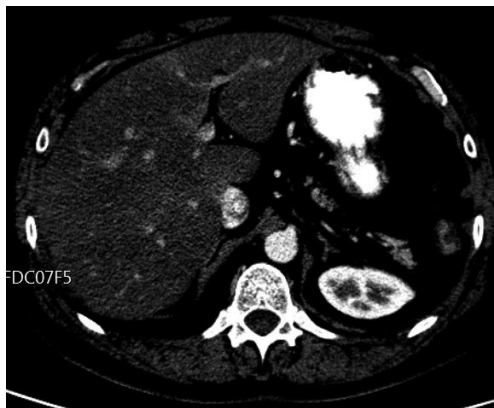

Figure 4 Abdominal CT scan.

and back pain with progressive worsening. The patient had recently undergone antibiotic therapy with ciprofloxacin for a urinary infection and the analytical study found no increase in inflammatory parameters and a normal urinalysis. However, it indicated a new onset of thyroid dysfunction (increased thyroid-stimulating hormone levels, $7.48 \text{ mIU}\cdot\text{L}^{-1}$, and decreased free T4 levels, $0.46 \text{ ng}\cdot\text{dL}^{-1}$). In the last thoracoabdominal CT scan (figure 4) a partial response (with disappearance of the hepatic nodules) was observed.

At this point, the patient started medication with levothyroxine $50 \mu\text{g}$. A cranioencephalic CT scan was requested to study the neurological condition and treatment with pembrolizumab was maintained.

However, the patient resorted to an unscheduled appointment with complaints of anorexia as he had lost 10 kg in the previous month. The patient failed to attend the cranioencephalic CT scan appointment.

An urgent analytical study was requested, which revealed worsening of thyroid dysfunction despite supplementation (increased thyroid-stimulating hormone levels, $21.8 \text{ mIU}\cdot\text{L}^{-1}$ (normal range: $0.35\text{--}4.94 \text{ mIU}\cdot\text{L}^{-1}$), and decreased free T4 levels, $0.46 \text{ ng}\cdot\text{dL}^{-1}$ ($0.70\text{--}1.48 \text{ ng}\cdot\text{dL}^{-1}$)) and a new onset of hyponatraemia ($\text{Na}^+ 129 \text{ mEq}\cdot\text{L}^{-1}$).

Task 4

Which step would you take next?

- Decrease the dose of levothyroxine
- Discontinue pembrolizumab treatment
- Change for second-line treatment with chemotherapy
- Screen for hidden neoplasia

[Go to Answers >>](#)

At the appointment scheduled for the 31st cycle of treatment, the patient maintained the same clinical condition and had suspended levothyroxine on his own initiative. The analytical study revealed worsened hypothyroidism (increased

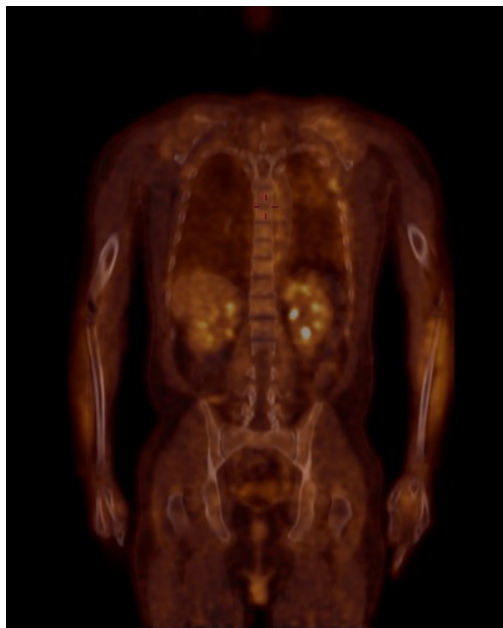


Figure 5 PET scan.

thyroid-stimulating hormone levels ($88.3 \text{ mIU}\cdot\text{L}^{-1}$) and decreased free T4 levels ($0.05 \text{ ng}\cdot\text{dL}^{-1}$) and hyponatraemia ($\text{Na}^+ 124 \text{ mEq}\cdot\text{L}^{-1}$). The PET-CT did not show evidence of metabolically active disease (figure 5). So, there was complete response with the disappearance of the hepatic, renal and adrenal metastases as well as intra-abdominal and retroperitoneal adenopathies. Given these results, the patient was referred to the endocrinology emergency department. However, the patient did not attend this specialised consultation. At this time, the patient underwent the last cycle of treatment with pembrolizumab.

In the following scheduled appointment, the patient was asthenic, presenting with mental confusion and arterial hypotension. The analytical study showed hypothyroidism improvement (thyroid-stimulating hormone $32.2 \text{ mIU}\cdot\text{L}^{-1}$ and free T4 $0.52 \text{ ng}\cdot\text{dL}^{-1}$), but severe hyponatraemia ($\text{Na}^+ 115 \text{ mEq}\cdot\text{L}^{-1}$). He was hospitalised for metabolic compensation and an aetiological study was conducted.

Task 5

Which aetiology would you most suspect?

- Central nervous system metastatisation
- Syndrome of inappropriate antidiuretic hormone secretion
- Iatrogenic adrenocorticotrophic hormone (ACTH) deficiency caused by pembrolizumab
- Tertiary hypothyroidism

[Go to Answers >>](#)

The patient was treated with corticosteroid therapy, initially in higher doses and intravenously,

with progressive weaning, and was discharged under levothyroxine $100 \mu\text{g}$ and prednisolone 7.5 mg and referred for an endocrinology consultation.

Currently, the patient maintains the treatment suspended, not only due to the immune-mediated toxicity, but also to the fact that he has completed more than 2 years of treatment. The patient maintains follow-up, with no locoregional relapse or distant metastases.

Discussion

Lung cancer is a leading cause of cancer-related mortality, with the majority of cases being classified as nonsmall cell lung carcinoma (NSCLC).

Programmed cell death 1 (PD-1), PD-L1 and cytotoxic T-lymphocyte-associated antigen 4 (CTLA-4) are targets for immune checkpoint inhibition. This inhibition, explored in cancer immunotherapy used to treat NSCLC, results in enhanced peripheral T-cell immunity [1].

Pembrolizumab, an anti-PD-1 IgG4 monoclonal antibody, has been recommended as first-line monotherapy for advanced NSCLC with high PD-L1 expression and without targetable driver gene mutations, due to superiority over conventional platinum-based chemotherapy for both progression-free and overall survival [2, 3].

While immune checkpoint inhibitors are promising agents for cancer treatment, their increased use is leading to the increase of the number of irAEs cases, including endocrinopathies (*i.e.* thyroid dysfunction, autoimmune diabetes, hypophysitis, hypopituitarism, anterior pituitary insufficiency, primary or secondary adrenal insufficiency) [3–5].

Usually, irAEs develop within a period that can span from a few weeks to months after the first administration of immune checkpoint inhibitors. Up to 29% of patients who have been treated with immune checkpoint inhibitors show signs of endocrine disorder after the sixth or seventh week, with a median onset time of 7–20 weeks [6, 7]. The incidence of endocrine disorders is low for anti-PD-1 monotherapy [8]. The likelihood of irAEs is said to be higher in patients with autoimmune disease, organ or haematopoietic stem cell transplants, chronic viral infection, organ dysfunction or advanced age [9].

Adrenal insufficiency is a very rare irAE, with an incidence $<4.3\%$ [10, 11]. There are only two previous reports showing isolated ACTH deficiency caused by pembrolizumab, one for squamous cell lung carcinoma and the other for metastatic colon cancer [12, 13].

Clinical characteristics and mechanisms of secondary adrenal insufficiency specifically associated with pembrolizumab treatment remain unclear because of the rarity of this adverse effect [13].

Adrenal insufficiency presents with nonspecific symptoms, such as fatigue (the most common

symptom, reported by 16–24% of patients), nausea, vomiting, weakness, anorexia, hypotension, headache, weight loss, abdominal pain or fever [12].

Hypophysitis is a possible aetiology. Hypophysitis is a well-known endocrine irAE, but its incidence varies with the immune checkpoint inhibitor agent employed. A recent systematic review and meta-analysis reported that hypophysitis was rarely observed in patients treated with PD-1 or PD-L1 inhibitors. However, hypophysitis occurs more frequently in patients under combination therapy of CTLA-4 and PD-1 inhibitors and in patients treated with CTLA-4 inhibitors alone [13].

There are two types of adrenal insufficiency: primary and secondary. If adrenal insufficiency due to immune checkpoint inhibitors is suspected, it is important to confirm serum cortisol, ACTH, aldosterone and renin levels. Early morning serum cortisone levels $<3 \mu\text{g}\cdot\text{dL}^{-1}$ are indicative of adrenal insufficiency [14]. Other hormone levels, such as thyroid-stimulating hormone, free thyroxine, free triiodothyronine, gonadotrophins and testosterone should be checked for an accurate diagnosis [13]. A retrospective cohort study indicated that eosinophilia is an early indicator of ACTH deficiency

during PD-1 inhibitor treatment [13]. MRI with gadolinium contrast is very useful to diagnose the main differential diagnosis of primary cause, brain metastasis [15].

Early recognition of hypophysitis and subsequent ACTH deficiency is mandatory because it is potentially life-threatening, in case of an adrenal crisis, but remediable by systemic corticosteroids. An initial dose of corticosteroid of $12 \text{ mg}\cdot\text{kg}^{-1}\cdot\text{day}^{-1}$ for 3 days could be administered, and then tapered gradually over a period of at least 1 month [16]. In case of persistence, immunosuppressive drugs such as anti-tumour necrosis factor- α , mycophenolate mofetil and antithymocyte immunoglobulins can be used. Since endocrine-related adverse events are irreversible, patients with adrenal insufficiency are treated with long-term corticosteroids. Additional complications should be carefully sought and treated, such as cushingoid features, osteoporosis, glaucoma, muscle weakness and opportunist infections [12].

Further cases need to be documented to fully comprehend the characteristics of the disease and clinical course, in order to optimise the follow-up of these patients.

Answers

Answer 1

c. The correct staging is cT1cN2M0. T1c since the extent of the primary tumour was $>2 \text{ cm}$ but $<3 \text{ cm}$, it did not involve the main bronchus, the carina, the visceral pleura or other mediastinal structures and it was not associated with atelectasis or post-obstructive pneumonitis; N2 because it affected ipsilateral mediastinal nodules; and M0 because the staging exams didn't find distant metastasis.

[<< Go to Task 1](#)

Answer 2

a. The case was presented and discussed in a multidisciplinary meeting of thoracic oncology. Since the patient had an adenocarcinoma of the upper left lobe, with clinical staging IIIA (T1cN2M0), with positive expression of PD-L1 ($>50\%$) and without other mutations, the decision was to perform three cycles of neoadjuvant chemotherapy (with cisplatin and vinorelbine) and then to repeat the imaging evaluation.

[<< Go to Task 2](#)

Answer 3

b. The patient was proposed for first-line immunotherapy with pembrolizumab, as the (neo) adjuvant chemotherapy was not counted as first line.

[<< Go to Task 3](#)

Answer 4

d. As indicated by the endocrinology specialist, the levothyroxine dose was increased to $75 \mu\text{g}$. The patient maintained pembrolizumab treatment. To screen for hidden neoplasia a PET-CT scan, an upper digestive endoscopy and a colonoscopy were requested.

[<< Go to Task 4](#)

Answer 5

c. Laboratory data revealed a low level of cortisol ($0.1 \mu\text{g}\cdot\text{dL}^{-1}$) accompanied by an inappropriately low ACTH ($<1 \text{ pg}\cdot\text{mL}^{-1}$). Pituitary magnetic resonance imaging (MRI) showed diffuse substantial gadolinium enhancement, T2 hyperintensity, loss of pituitary bright spot, but no pituitary enlargement. Serum cortisone and ACTH levels were low throughout the day and urinary free cortisol excretion fell below the lower limit of normal. There was no ACTH and cortisol response in the corticotrophin-releasing hormone test. Therefore, isolated ACTH deficiency was diagnosed and hypophysitis was the suspected aetiology, although there was no pituitary enlargement in the pituitary MRI. Given the presence of another altered pituitary series in addition to the thyroid one, although less frequent, the hypothesis of hypothyroidism secondary to hypophysitis could also be considered. An immune-related adverse event (irAE) induced by pembrolizumab was the most likely cause of this condition.

<< Go to Task 5

Affiliations

Inês Moreira¹, Ana Sofia Vilarica², Paula Alves²

¹Pulmonology Dept, Hospital Santa Marta, Centro Hospitalar Universitário Lisboa Central (CHULC), Lisbon, Portugal.

²Pulmonology Dept, Hospital Pulido Valente, Centro Hospitalar Universitário Lisboa Norte (CHULN), Lisbon, Portugal.

Conflict of interest

None declared.

References

1. Topalian SL, Hodi FS, Brahmer JR, *et al.* Safety, activity, and immune correlates of anti-PD-1 antibody in cancer. *N Engl J Med* 2012; 366: 2443–2454.
2. Reck M, Rodriguez-Abreu D, Robinson AG, *et al.* Pembrolizumab versus chemotherapy for PD-L1-positive non-small-cell lung cancer. *N Engl J Med* 2016; 375: 1823–1833.
3. Reck M, Rodriguez-Abreu D, Robinson AG, *et al.* Updated analysis of KEYNOTE-024: pembrolizumab versus platinum-based chemotherapy for advanced non-small-cell lung cancer with PD-L1 tumor proportion score of 50% or greater. *J Clin Oncol* 2019; 37: 537–546.
4. Barroso-Sousa R, Barry WT, Garrido-Castro AC, *et al.* Incidence of endocrine dysfunction following the use of different immune checkpoint inhibitor regimens: a systematic review and meta-analysis. *JAMA Oncol* 2018; 4: 173–182.
5. Tan MH, Iyengar R, Mizokami-Stout K, *et al.* Spectrum of immune checkpoint inhibitors-induced endocrinopathies in cancer patients: a scoping review of case reports. *Clin Diabetes Endocrinol* 2019; 5: 1.
6. González-Rodríguez E, Rodríguez-Abreu D. Spanish Group for Cancer Immuno-Biotherapy (GETICA). Immune checkpoint inhibitors: review and management of endocrine adverse events. *Oncologist* 2016; 21: 804–816.
7. Weber JS, Dummer R, de Pril V, *et al.* Patterns of onset and resolution of immune-related adverse events of special interest with ipilimumab: detailed safety analysis from a phase 3 trial in patients with advanced melanoma. *Cancer* 2013; 119: 1675–1682.
8. Robert C, Schachter J, Long GV, *et al.* Pembrolizumab versus ipilimumab in advanced melanoma. *N Engl J Med* 2015; 372: 2521–2532.
9. Johnson DB, Sullivan RJ, Menzies AM. Immune checkpoint inhibitors in challenging populations. *Cancer* 2017; 123: 1904–1911.
10. Doi T, Piha-Paul SA, Jalal SI, *et al.* Pembrolizumab (MK-3475) for patients (pts) with advanced esophageal carcinoma: preliminary results from KEYNOTE-028. *J Clin Oncol* 2015; 33: Suppl. 15, 4010.
11. Ribas A, Puzanov I, Dummer R, *et al.* Pembrolizumab versus investigator-choice chemotherapy for ipilimumab-refractory melanoma (KEYNOTE-002): a randomised, controlled, phase 2 trial. *Lancet Oncol* 2015; 16: 908–918.
12. Bekki T, Takakura Y, Kochi M, *et al.* A case of isolated adrenocorticotrophic hormone deficiency caused by pembrolizumab. *Case Rep Oncol* 2020; 13: 200–206.
13. Tanaka S, Kushimoto M, Nishizawa T, *et al.* Isolated ACTH deficiency during single-agent pembrolizumab for squamous cell lung carcinoma: a case report. *Clin Diabetes Endocrinol* 2020; 6: 1.
14. Hägg E, Asplund K, Lithner F. Value of basal plasma cortisol assays in the assessment of pituitary-adrenal insufficiency. *Clin Endocrinol (Oxf)* 1987; 26: 221–226.
15. Moses AM, Clayton B, Hochhauser L. Use of T1-weighted MR imaging to differentiate between primary polydipsia and central diabetes insipidus. *AJNR Am J Neuroradiol* 1992; 13: 1273–1277.
16. Champiat S, Lambotte O, Barreau E, *et al.* Management of immune checkpoint blockade dysimmune toxicities: a collaborative position paper. *Ann Oncol* 2015; 27: 559–574.