

# Assessment of foot alignment and function for ambulatory children with cerebral palsy: Results of a modified Delphi technique consensus study

Jon R Davids<sup>1,2</sup>, Jeff Shilt<sup>3,4</sup>, Robert Kay<sup>5,6</sup>, Thomas Dreher<sup>7</sup>, Benjamin J Shore<sup>8,9</sup>, James McCarthy<sup>10</sup>, Wade Shrader<sup>11</sup>, Kerr Graham<sup>12</sup>, Matthew Veerkamp<sup>10</sup>, Unni Narayanan<sup>13</sup>, Hank Chambers<sup>14</sup>, Tom Novacheck<sup>15</sup>, Jason Rhodes<sup>16</sup>, Anja Van Campenhout<sup>17</sup>, Kristan Pierz<sup>18</sup>, Tim Theologis<sup>19</sup>, and Erich Rutz<sup>12</sup>

## Abstract

**Purpose:** The purpose of this study was to establish consensus for the assessment of foot alignment and function in ambulatory children with cerebral palsy, using expert surgeon's opinion through a modified Delphi technique.

**Methods:** The panel used a five-level Likert-type scale to record agreement or disagreement with 33 statements regarding the assessment of foot alignment and function. Consensus was defined as at least 80% of responses being in the highest or lowest of two of the five Likert-type ratings. General agreement was defined as 60%–79% falling into the highest or lowest two ratings. There was no agreement if neither threshold was reached.

**Results:** Consensus was achieved for 25 (76%) statements, general agreement for 4 (12%) statements, and lack of consensus for 4 (12%) of the statements. There was consensus that the functional anatomy of the foot is best understood by dividing the foot into three segments and two columns. Consensus was achieved concerning descriptors of foot segmental alignment for both static and dynamic assessment. There was consensus that radiographs of the foot should be weight-bearing. There was general agreement that foot deformity in children with cerebral palsy can be classified into three levels based on soft tissue imbalance and skeletal malalignment.

**Conclusion:** The practices identified in this study can be used to establish best care guidelines, and the format used will be a template for future Delphi technique studies on clinical decision-making for the management of specific foot segmental malalignment patterns commonly seen in children with cerebral palsy.

**Level of Evidence:** V

**Keywords:** Cerebral palsy, foot alignment and function, Delphi methodology, Likert-type scale, anatomy, diagnosis, consensus

<sup>1</sup>Shriners Children's Northern California, Sacramento, CA, USA

<sup>2</sup>Orthopaedic Surgery, University of California, Davis, Sacramento, CA, USA

<sup>3</sup>Texas Children's Hospital, Houston, TX, USA

<sup>4</sup>Baylor College of Medicine, Houston, TX, USA

<sup>5</sup>Children's Hospital Los Angeles, Los Angeles, CA, USA

<sup>6</sup>Orthopaedic Surgery, Keck School of Medicine, University of Southern California, Los Angeles, CA, USA

<sup>7</sup>Universitäts-Kinderspital, Zürich, Switzerland

<sup>8</sup>Boston Children's Hospital, Boston, MA, USA

<sup>9</sup>Orthopedic Surgery, Harvard Medical School, Boston, MA, USA

<sup>10</sup>Cincinnati Children's Hospital Medical Center, Cincinnati, OH, USA

<sup>11</sup>Nemours/Alfred I. DuPont Hospital for Children, Wilmington, DE, USA

<sup>12</sup>The Royal Children's Hospital, Melbourne, VIC, Australia

<sup>13</sup>The Hospital for Sick Children, Toronto, ON, Canada

<sup>14</sup>Rady Children's Hospital, San Diego, CA, USA

<sup>15</sup>Gillette Children's Specialty Healthcare, Saint Paul, MN, USA

<sup>16</sup>Children's Hospital Colorado, Aurora, CO, USA

<sup>17</sup>UZ Leuven, Leuven, Belgium

<sup>18</sup>Connecticut Children's Medical Center, Hartford, CT, USA

<sup>19</sup>Nuffield Orthopaedic Centre, Oxford University Hospitals NHS Foundation Trust, Oxford, UK

Date received: 14 December 2021; accepted: 1 February 2022

## Corresponding Author:

Jon R Davids, Shriners Children's Northern California, 2425 Stockton Blvd., Sacramento, CA 95817, USA.

Email: [jdavids@shrinenet.org](mailto:jdavids@shrinenet.org)



Clinical decision-making for the management of foot deformities in children with cerebral palsy (CP) requires a comprehensive assessment of static foot alignment and dynamic foot function. This assessment is built on the knowledge of typical foot anatomy and biomechanics, and typical foot function during gait.<sup>1</sup> Best practice guidelines for the assessment of foot and alignment and function, when considering orthotic management or surgical interventions to improve foot function during gait in children with CP, would ideally be derived from objective, quantitative clinical research studies. Such studies, to our knowledge, have not been performed, and most likely will not be performed due to limited health system resources and perceived lack of clinical equipoise by a range of clinician providers.

In such circumstances, available evidence is limited to expert opinion, which is usually provided by a single clinician expert, frequently in a textbook chapter or review article.<sup>2,3</sup> Recently, modified versions of the Delphi technique have been used to pool expert opinion through consensus building, based on the rationale that “two heads are better than one.”<sup>4</sup> In 2017, an international group of pediatric orthopedic surgeons came together to identify practice variations and improve the quality of care providing to children with CP by seeking consensus (and identifying areas lacking in consensus) on indications and techniques of surgical procedures commonly selected to improve gait function. Previous work by this group has focused on the indications for hamstring lengthening, rectus femoris transfer, femoral derotation osteotomy, and gastrocnemius lengthening.<sup>5-7</sup>

Recently, the group directed its attention to the management of foot deformities in children with CP who are able to walk. The purpose of this study was to use expert's opinion, solicited through a modified e-Delphi technique, to establish consensus for the assessment of static foot alignment and dynamic foot function in children with CP. Such consensus could be used to establish best practice guidelines and provide a foundation for future analysis of the management of specific foot deformity patterns seen in children with CP.

## Methods

### Creation of expert panel

A 16-member panel of fellowship-trained pediatric orthopedic surgeons, with expertise in three-dimensional gait analysis (3DGA) and musculoskeletal surgery for children with CP, participated in the consensus-seeking process. This panel has worked together on several other consensus projects identifying the indications for common surgical procedures used in single event multilevel surgery (SEMLS).<sup>5-7</sup> Panel members had a mean of over 20 years of experience (range: 10–41 years) in the orthopedic care of children with

CP and a mean of 19.8 years (range: 7–31 years) of experience using 3DGA for clinical decision-making in children with CP. No members of the panel withdrew during the course of the consensus-seeking process.

### Modified e-Delphi process

The consensus process incorporated a modified e-Delphi methodology, which took place between August 2020 and January 2021. Institutional review board approval for the study and from each participating member was obtained. All communications were electronic (email and virtual conferencing), due to the COVID-19 pandemic and for the convenience of the panel members. The modified Delphi method is an iterative process that uses a systematic progression of repeated rounds of discussion and voting and is an effective process for determining expert group consensus where there is limited definitive evidence and where opinion based on clinical experience is important.<sup>4,8</sup> There were three stages for statement generation, in which the facilitator, with input from a subset of the expert panel, created a structured format for categorizing the elements of a comprehensive assessment of foot alignment and function in children with CP. The domains identified were Functional Anatomy and Terminology, Observational Gait Analysis of the Foot, Physical Examination of the Foot, Radiographic Assessment, Quantitative Assessment of Foot Function, and Classification of Foot Deformity. A structured series of statements, which could be assessed using a 5-point Likert-type scale, was created for the six domains noted above. Panelists were encouraged to share comments with the facilitator for all Likert-type levels of response, particularly when *disagree* or *strongly disagree* were selected.

The next stage consisted of an electronic survey which was created in Research Electronic Data Capture (REDCap, Vanderbilt University, Nashville, Tennessee, Version 9.1.0) and sent to all panel members. “Consensus for agreement” occurred when at least 80% of experts selected one of the highest two responses on the 5-point Likert-type scale (*strongly agree* or *agree*). “Consensus for disagreement” occurred when at least 80% of the panel selected one of the lowest two responses (*strongly disagree* or *disagree*). “General agreement” occurred when 60%–79% of the respondents chose one of the highest two responses, and “general disagreement” if 60%–79% chose one of the lowest two responses. There was “no consensus” if fewer than 60% of the responses were in either the highest or lowest two categories for a given statement. The thresholds for these levels of consensus were based on the historical standards recommended in the literature and were used in previous consensus-seeking projects by the expert panel participating in this study.<sup>5-7</sup> Opportunity for comments was provided for all statements. Panel members were blinded to the responses of each other. No questions

were dropped, regardless of the presence or lack of consensus achieved. The iterative process was continued at the discretion of the facilitator. All panel members were apprised of the final results of the survey and had the opportunity to review and edit the resulting article prior to the submission for publication.

## Results

A total of 33 statements were surveyed; there were five items in Functional Anatomy and Terminology, five items in Observational Gait Analysis of the Foot, eight items in Physical Examination of the Foot, eight items in Radiographic Assessment, five items in Quantitative Assessment of Foot Function, and two items in Classification of Foot Deformity. Consensus was achieved for 25 (76%) statements, general agreement for 4 (12%) statements, and lack of consensus for the remaining 4 (12%) of the statements. The 33 statements, and the Likert-type scale responses, are presented in Table 1.

### *Functional anatomy and terminology*

There was consensus among the panel that the functional anatomy of the foot is best understood by dividing the foot into three segments and two columns (Figure 1). Several respondents noted that the use of both segments and columns is required to best understand the foot segmental malalignments, perform surgical decision-making, assess technical domain outcomes assessment, and to guide orthotic management. One respondent noted that a deficiency of the three-segment two-column model is that it does not include toe alignment. There was consensus among the panel that static standing foot segmental alignment is best described by the following conventions proposed by Ponseti and colleagues (Figure 2).<sup>9–11</sup> This terminology supports a verbal descriptor paradigm of static foot segmental alignment patterns where the alignment for each of the three segments is noted (e.g. the flat foot, proceeding from hindfoot to midfoot to forefoot, is described as equinopronovalgus).

### *Observational gait analysis of the foot*

There was consensus among the panel that when performing observational gait analysis, the foot is best observed from the front, back, and side while walking barefoot, as described by Kulkarni and colleagues.<sup>12</sup> There was also consensus that the key visual landmarks when performing observational gait analysis of the foot are which part of the foot hits the ground first at initial contact in stance phase (i.e. heel strike, flatfoot contact, or forefoot/toe strike), the foot progression angle (described relative to the line of gait progression in midstance), the status of the medial arch (e.g. absent, present, increased) in midstance, and the

clearance of the foot in swing phase. Several respondents were concerned that a pure sagittal plane visual analysis is too simplistic, noting that the absence of an arch on observational gait analysis does not imply a “midfoot break,” which is a multiplane deformity that is defined by a combination of data from the physical examination, quantitative gait analysis, and radiographic evaluation of the foot.

### *Physical examination of the foot*

There was consensus among the panel that the physical examination of the foot should include assessment of static standing foot alignment, flexibility of the segments of the foot, passive range of motion, muscle strength, and selective voluntary motor control. There was consensus that the range of motion should be measured with a goniometer, muscle strength tested manually, and selective voluntary motor control using a validated tool.<sup>13,14</sup> Respondents clarified that the “target” for assessing foot flexibility and “correct-ability” on manual testing should be subtalar neutral, where the hindfoot is manipulated so that the calcaneus is aligned below the talus, and the navicular is reduced on the head of the talus. The challenge of determining muscle strength in subjects with poor selective voluntary motor control was also raised. It was suggested that anti-gravity muscle strength of a muscle group can frequently be inferred by the observational assessment of joint motion during gait.

### *Radiographic assessment*

There was consensus among the panel that all radiographs of the foot should be weight-bearing for GMFCS I–III subjects or assisted/simulated weight-bearing for GMFCS IV and V subjects. Non-weight-bearing radiographs are not reliable indicators of foot segmental alignment. The standard radiographic views should include standing anteroposterior and lateral of the foot, and standing anteroposterior of the ankle. Consensus was achieved for only one (coronal lower extremity alignment that includes the hips, knees, and ankles) of four possible additional radiographic views that might be helpful in certain cases. There was consensus that the most common radiographic foot segmental malalignment patterns in children with CP are equinus, equinopronovalgus, and equinosupovarus (Figure 3).

### *Quantitative assessment of foot function*

There was general agreement among the panel that kinematic assessment of foot function using either a single segment foot model or a multisegmental foot model should be performed routinely prior to foot surgery in children with CP.<sup>15</sup> Several respondents commented that a multisegment foot model is only required in the presence of midfoot instability (midfoot break), and that such models are not

**Table 1.** Foot Assessment Statements and Likert-type Scores.

Domain	Likert scale scores				
	N (%)				
	Strongly agree	Agree	Neutral	Disagree	Strongly disagree
<b>Functional anatomy and terminology</b>					
• The functional anatomy of the foot is best understood by dividing the foot into three segments	11 (68.8)	5 (31.3)	0 (0)	0 (0)	0 (0)
• The functional anatomy of the foot is best understood by dividing the foot into two columns	7 (43.8)	6 (37.5)	0 (0)	2 (12.5)	1 (6.3)
• The functional anatomy of the foot is best understood by dividing the foot into three columns	2 (12.5)	1 (6.3)	5 (31.3)	7 (43.8)	1 (6.3)
• Static standing foot segmental alignment is best described following conventions of Ponseti and colleagues <sup>9-11</sup>	10 (62.5)	6 (37.5)	0 (0)	0 (0)	0 (0)
• Using this paradigm, the most common static (standing) foot segmental alignments in children with CP are equinus, equinopronovalgus, and equinosupovarus.	8 (50)	6 (37.5)	2 (12.5)	0 (0)	0 (0)
<b>Observational gait analysis of the foot</b>					
• When performing observational gait analysis, the foot is best observed from the front, back, and side while walking barefoot.	12 (75)	4 (25)	0 (0)	0 (0)	0 (0)
• The important visual landmarks when performing observational gait analysis of the foot include: Which part of the foot hits the ground first	9 (56)	4 (25.0)	4 (25.0)	1 (6.3)	1 (6.3)
• The important visual landmarks when performing observational gait analysis of the foot include: The foot progression angle (relative to line of gait progression)	15 (93.8)	1 (6.3)	0 (0)	0 (0)	0 (0)
• The important visual landmarks when performing observational gait analysis of the foot include: The status of the medial arch in midstance	8 (50)	7 (43.8)	0 (0)	1 (6.3)	0 (0)
• The important visual landmarks when performing observational gait analysis of the foot include: Clearance in swing phase	9 (56.3)	4 (25.0)	1 (6.3)	1 (6.3)	1 (6.3)
<b>Physical examination of the foot</b>					
• Alignment should be assessed with the child standing and the foot viewed from behind, front, and each side	9 (56.3)	7 (43.8)	0 (0)	0 (0)	0 (0)
• Alignment should also be assessed with the child supine and/or prone, with manual manipulation, to determine the following: Ability to manipulate the forefoot to align it with the hindfoot	11 (68.8)	5 (31.3)	0 (0)	0 (0)	0 (0)
• Alignment should also be assessed with the child supine and/or prone, with manual manipulation, to determine the following: the relationship between the thigh and the long axis of the foot when the foot is held in a corrected position	12 (75)	3 (18.8)	1 (6.3)	0 (0)	0 (0)
• Flexibility should be assessed by the standing heel-rise test	12 (75)	3 (18.8)	1 (6.3)	0 (0)	0 (0)
• In subjects unable to do the heel-rise test, foot flexibility may be assessed by comparing static standing foot alignment to fully unloaded foot alignment in the seated position (with foot hanging from examination table)	8 (50)	7 (43.8)	0 (0)	0 (0)	1 (6.3)
• Range of motion should be assessed, with the child supine and/or prone, with manual manipulation using a goniometer.	6 (37.5)	8 (50)	2 (12.5)	0 (0)	0 (0)
• Muscle strength should be assessed with the child seated, with manual testing.	6 (37.5)	9 (56.3)	1 (6.3)	0 (0)	0 (0)
• Selective voluntary motor control should be assessed in a standardized manner.	8 (50)	7 (43.8)	1 (6.3)	0 (0)	0 (0)
<b>Radiographic examination of the foot</b>					
• All radiographs should be weight-bearing for GMFCS I-III subjects or assisted/simulated weight-bearing for GMFCS IV and V subjects.	12 (75)	3 (18.8)	0 (0)	1 (6.3)	0 (0)
• Radiographic assessment of foot alignment should include AP foot	10 (62.5)	4 (25)	2 (12.5)	0 (0)	0 (0)
• Radiographic assessment of foot alignment should include LAT foot	9 (56.3)	5 (31.3)	2 (12.5)	0 (0)	0 (0)
• Radiographic assessment of ankle alignment should include AP ankle	7 (43.8)	7 (43.8)	2 (12.5)	0 (0)	0 (0)

(Continued)

**Table 1.** (Continued)

Domain	Likert scale scores				
	N (%)				
	Strongly agree	Agree	Neutral	Disagree	Strongly disagree
• Additional radiographic views that may be helpful in selected cases, include Obliques (internal/medial, external/lateral)	4 (25)	3 (18.8)	7 (43.8)	2 (12.5)	0 (0)
• Additional radiographic views that may be helpful in selected cases, include axial of the hindfoot	4 (25)	5 (31.3)	6 (37.5)	1 (6.3)	0 (0)
• Additional radiographic views that may be helpful in selected cases, include coronal lower extremity alignment (hips/knees/ankles)	7 (43.8)	8 (50)	1 (6.3)	0 (0)	0 (0)
• The most common radiographic foot segmental malalignment patterns in children with CP are equinus, equinopronovalgus, and equinosupovarus	9 (56.3)	7 (43.8)	0 (0)	0 (0)	0 (0)
<b>Quantitative assessment of foot function</b>					
• Kinematic assessment of foot function using a single segment foot model should be performed routinely prior to foot surgery in children with CP.	3 (18.8)	8 (50)	2 (12.5)	3 (18.8)	0 (0)
• Kinematic assessment of foot function using a multisegment segment foot model should be performed routinely prior to foot surgery in children with CP.	5 (31.3)	5 (31.3)	4 (25)	2 (12.5)	0 (0)
• Dynamic electromyography assessment of foot function should be performed routinely prior to surgery for the varus foot in children with CP.	6 (37.5)	8 (50)	1 (6.3)	1 (6.3)	0 (0)
• Dynamic electromyography assessment of foot function should be performed routinely prior to surgery for the valgus foot in children with CP.	1 (6.3)	4 (25)	5 (31.3)	4 (25)	2 (12.5)
• Dynamic pedobarography should be performed routinely prior to foot surgery in children with CP.	9 (56.3)	3 (18.8)	3 (18.8)	1 (6.3)	0 (0)
<b>Classification of foot deformity</b>					
• Classification of foot deformity in children with CP into three levels can be based on soft tissue imbalance and skeletal malalignment.	5 (31.3)	7 (43.8)	3 (18.8)	1 (6.3)	0 (0)
• Classification of foot deformity may require assessment under anesthesia and intra-operative assessment during/following sequential soft tissue and skeletal surgeries.	6 (37.5)	8 (50)	2 (12.5)	0 (0)	0 (0)

Statements that achieved consensus are indicated in green. Those that achieved general agreement are indicated in yellow. Questions for which no consensus was achieved are indicated in red. GMFCS: gross motor function classification system; AP: anteroposterior; LAT: lateral; CP: cerebral palsy.

yet fully validated and widely available.<sup>16</sup> There was consensus among the panel that dynamic electromyography (dEMG) assessment of foot function should be performed routinely prior to surgery for the varus foot in children with CP.<sup>17</sup> There was lack of consensus concerning the role of dEMG for the assessment of the valgus foot in children with CP. There was general agreement among the panel that dynamic pedobarography should be performed routinely, when available, prior to foot surgery in children with CP.<sup>18</sup>

**Classification of foot deformity**

There was general agreement among the panel that the classification of foot deformity in children with CP into three levels can be based on soft tissue imbalance and skeletal malalignment (Table 2). General treatment recommendations (not identified through the current Delphi method consensus study) are included to illustrate the utility of such a classification scheme. There was consensus that the classification of foot deformity may require assessment

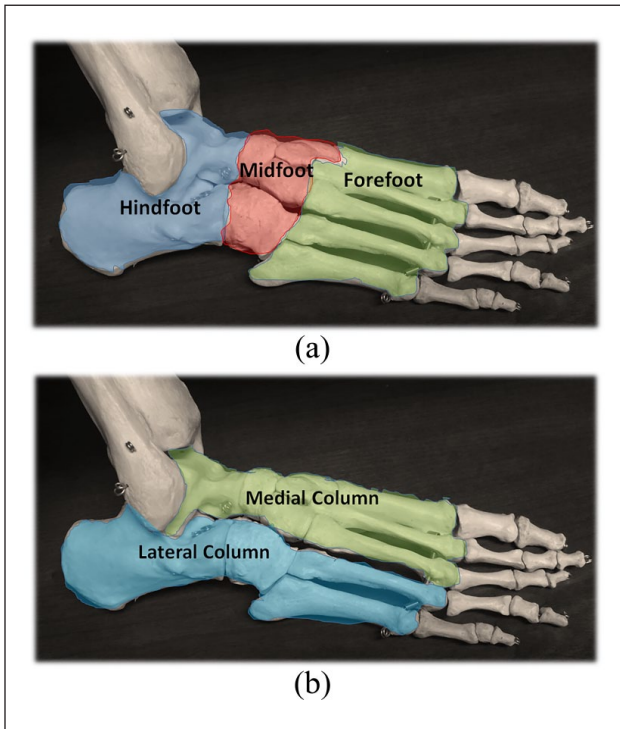
under anesthesia and intraoperative assessment during/ following sequential soft tissue and skeletal surgeries.

**Discussion**

Clinical decision-making for the management of the individual patient with CP involves the integration of data from multiple domains, which may include knowledge from the medical and scientific literature; understanding of disease process pathoanatomy and pathophysiology; the patient’s age, motor impairment level, and cognitive status; determination of soft tissue contractures and skeletal alignment; subjective and quantitative assessments of patient-specific function; and appreciation of patient’s goals, desires, and preferences. The goal is the development of a patient-specific, individualized care plan, which has recently been termed “precision medicine.”<sup>2,19</sup>

Over the last 20 years, the utilization of medical and scientific knowledge to inform clinical decision-making has been guided by the paradigm of evidence-based medicine (EBM). This approach seeks to improve the outcomes of

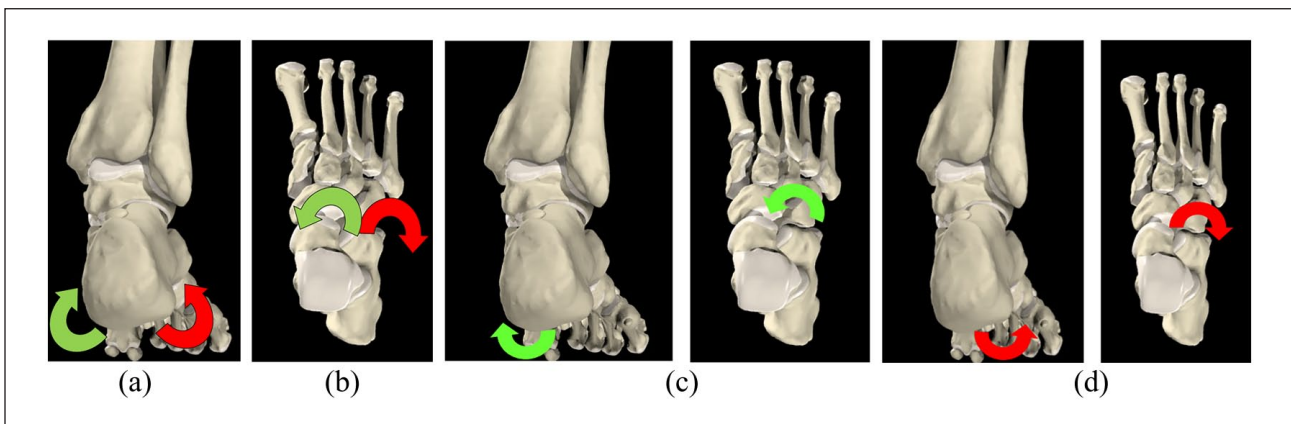
diagnosis and treatment by enhancing the evidence on which medicine is practiced, relying on up-to-date published research, and proposes that the value and reliability of



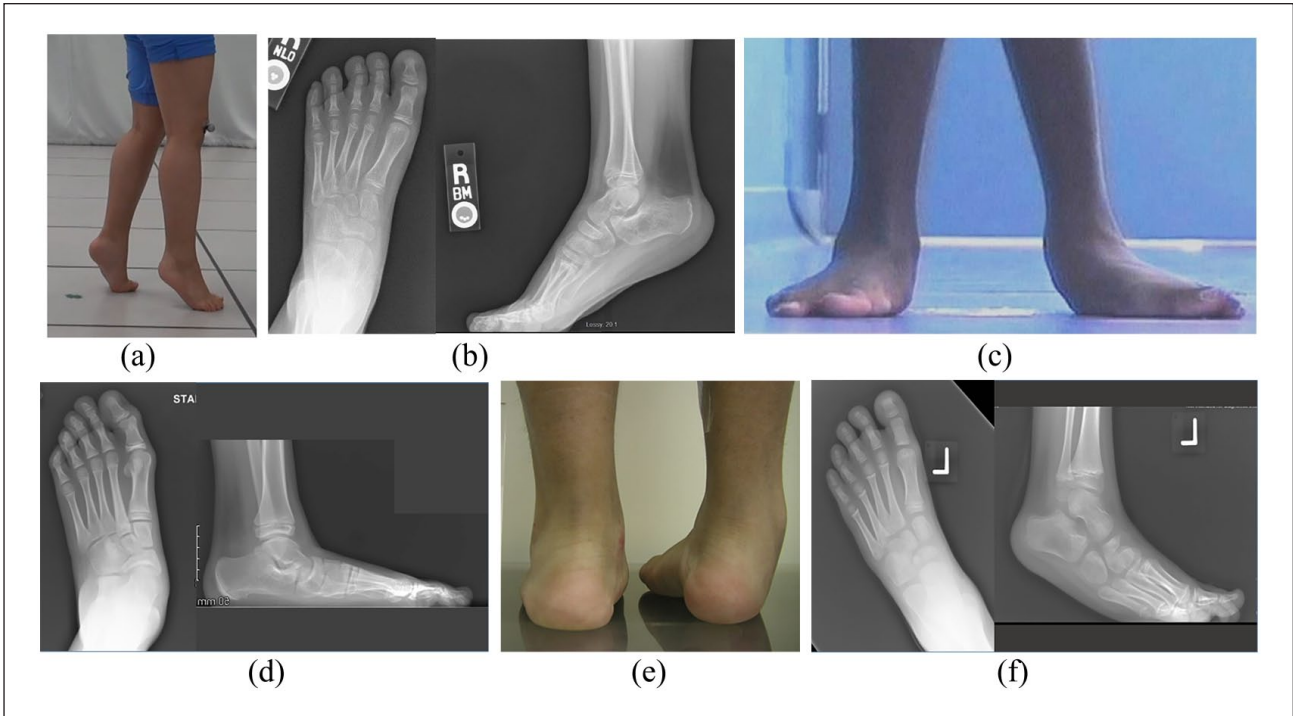
**Figure 1.** Diagram illustrating the three segments of the foot. (a) The hindfoot (talus and calcaneus) is blue, the midfoot (navicular, cuneiform, and cuboid) is red, and the forefoot (metatarsals) is green. (b) The medial column (talus, navicular, cuneiform, and first to third metatarsals) is green, and the lateral column (calcaneus, cuboid, and fourth and fifth metatarsals) is blue.

evidence should be considered in a hierarchy that prioritizes clinical trial data and meta-analyses, relegating mechanistic reasoning, clinical judgment, and authoritative opinion to a lower position.<sup>20,21</sup> This approach seeks to standardize (as opposed to individualize) care and is best applied to disease processes that are common and easily identified quantitatively, with a narrow range of clinical symptoms; with standardized, consistently applied treatment options; and outcomes that can be determined objectively.<sup>22</sup> These data are best used to support decision-making for treating populations, but not necessarily individual patients.

The EBM paradigm has been less valuable when applied to uncommon diseases, those with a wide ranging clinical spectrum (making identification and/or classification challenging), with difficult to standardize treatment and intervention options, and outcomes that are hard to assess objectively or quantitatively. The paradigm also does not account for interventions designed to avoid problems that may develop in the future. In these situations, there is generally a paucity of published research clinical trial data, and guidance for clinical decision-making is more dependent on mechanistic reasoning, clinical judgment, and authoritative opinion. The quality of these types of evidence can be enhanced through the use of the Delphi technique. This approach has been used to obtain input from a group of experts and was developed by the Rand Corporation in the 1960s during the Cold War for use in determining the impact of technology on warfare, where pure model-based statistical methods were not practical or possible because of the lack of appropriate historical/economic/technical data.<sup>23-26</sup> The ancient Greek Delphic Oracle was an institutionalized process to guide and justify personal and societal decision-making. The linkage of this ancient practice to a



**Figure 2.** Alignment of segments of the foot, using the hindfoot (HF) as example. (a) When the plantar aspect of the HF is deviated toward the subject's midline (green arrow), it is described as varus/inversion. When the plantar aspect of the HF is deviated away from the subject's midline (red arrow), it is described as valgus/eversion. (b) When the distal aspect of the HF is deviated toward the subject's midline (green arrow), it is described as adduction. When the distal aspect of the HF is deviated away from the subject's midline (red arrow), it is described as abduction. (c) Supination of the HF segment is the combination of varus/inversion and adduction (green arrows). (d) Pronation of the HF segment is the combination of valgus/eversion and abduction (red arrows).



**Figure 3.** Clinical and radiographic examples of common foot segmental malalignment patterns in children with CP. (a) Clinical photograph of equinus foot segmental malalignment. (b) Standing radiographs of equinus foot segmental malalignment (AP view to the left, LAT to the right). (c) Clinical photograph of equinopronovalgus foot segment malalignment. (d) Standing radiographs of equinopronovalgus foot segmental malalignment (AP view to the left, LAT to the right). (e) Clinical photograph of equinosupovarus foot segmental malalignment (right foot, seen from behind). (f) Standing radiographs of equinosupovarus foot segmental malalignment (AP view to the left, LAT to the right).

modern technique for expert-based futures analysis is limited, and the original rationale for this nomenclature was never explicitly stated by its developers.<sup>23,24</sup> The Delphi technique continues to be modified over time, in efforts to improve both efficiency and quality.

This study used a modified e-Delphi methodology to establish consensus for the assessment of static foot alignment and dynamic foot function in children with CP who are able to walk. Sufficient consensus was achieved following a single round of statement evaluation by the panel of experts for agreement/disagreement, reflecting the relative lack of equipoise (uncertainty, difference of opinion) surrounding this topic. Some of these best practices can also be applied to children who are non-ambulatory but require correction of foot deformities to facilitate orthotic and shoe wear and promote therapeutic standing and assisted transfers. The process determined that the *functional anatomy of the foot and terminology to describe alignment* are best accomplished by considering the foot to consist of three segments and two columns. This approach facilitates the understanding of pathoanatomy and pathomechanics of foot segmental malalignment and can be used to describe deformity, assess alignment intraoperatively, guide orthotic management, and determine the outcomes following a variety of interventions. The alignment

of each segment can be described with respect to a global reference frame, using standardized, consistent terminology. *Observational gait analysis* should be performed in a standardized manner, focusing on particular points in the gait cycle. Smartphone videography and standardized visual gait scoring systems can be used to improve the quality and utility of observational gait analysis.<sup>12</sup> The *physical examination of the foot* should include assessment of static standing foot alignment, flexibility of the segments of the foot, passive range of motion, muscle strength, and selective voluntary motor control. Further work is required to standardize these elements, particularly objective assessment of foot flexibility and selective motor control. *Radiographic assessment* should include standardized views of the foot and ankle taken with the subject weight-bearing, and when proximal malalignment necessitates, add a standing joint survey that includes the hips and knees. If foot segmental malalignment results in incorrect rotational alignment of the ankle on the standing lateral radiograph of the foot, then an additional standing lateral radiograph of the ankle would be required. Quantitative angular measurements are used more for outcomes assessment than to guide clinical decision-making.<sup>27</sup> The panel recognized that the three most common foot segmental malalignment patterns seen in children with CP

**Table 2.** Classification of foot deformity in children with CP into three levels can be based on soft tissue imbalance and skeletal malalignment.

Level of deformity	General treatment options		
	Pharmacologic/neurosurgery	Muscle tendon surgeries	Skeletal surgeries
I: Dynamic soft tissue imbalance, no fixed skeletal malalignments	<ul style="list-style-type: none"> <li>● Botulinum toxin injection</li> <li>● Selective dorsal rhizotomy</li> <li>● Intrathecal baclofen</li> </ul>	<ul style="list-style-type: none"> <li>● Partial/complete tendon transfers (multiple possible techniques)</li> </ul>	<ul style="list-style-type: none"> <li>● Not appropriate</li> </ul>
II: Fixed soft tissue imbalance, no fixed skeletal malalignments	<ul style="list-style-type: none"> <li>● Not appropriate as isolated intervention</li> </ul>	<ul style="list-style-type: none"> <li>● Serial stretch casting</li> <li>● Lengthening (multiple possible techniques)</li> </ul>	<ul style="list-style-type: none"> <li>● Not appropriate</li> </ul>
III: Fixed soft tissue imbalance, with fixed skeletal malalignments	<ul style="list-style-type: none"> <li>● Not appropriate as isolated intervention</li> </ul>	<ul style="list-style-type: none"> <li>● Appropriate in conjunction with skeletal surgery</li> </ul>	<ul style="list-style-type: none"> <li>● Osteotomy (multiple possible techniques)</li> <li>● Arthrodesis</li> </ul>

are equinus, equinopronovalgus, and equinosupovarus. The members of the panel all used *quantitative gait analysis* in their clinical practices caring for children with CP. Foot kinematics (with a single segment foot model in the absence of midfoot instability, or a multisegment foot model when midfoot instability is present), dEMG for assessment of the varus foot, and dynamic pedobarography were judged to be of the greatest value when assessing foot function in children with CP.<sup>16-18</sup> The expert panel felt that the *classification of foot deformity* in children with CP into three levels, based on soft tissue imbalance and skeletal malalignment, was the most useful for guiding clinical decision-making. This classification system, based on current understanding of musculoskeletal pathoanatomy and pathophysiology in subjects with CP, uses a similar paradigm to a recently developed overall gait musculoskeletal pathology classification system.<sup>28</sup> It was recognized that clinical decision-making for the surgical management of foot deformity may require evaluation under anesthesia, in addition to the pre-operative assessments outlined above, during/following sequential soft tissue and skeletal surgeries. The general treatment options noted in Table 2 were not identified through the current Delphi method consensus study but were included to show the utility of such a classification scheme and should be considered to reflect the opinion and experience of the senior author (J.R.D.). Future work using this classification scheme will establish consensus (or lack thereof) for specific surgical interventions for specific foot segmental malalignment patterns in children with CP.

The strengths and limitations of this study are related to the modified e-Delphi methodology that was used. Methods for grading the quality of a study using Delphi methodology have been recently proposed.<sup>25,29</sup> These rubrics consider the size and composition of the expert panel; the methodology of the Delphi process; and how the results were determined and expressed. *Panel Size and Composition:* This study scored well in this category, as the panelists were all recognized experts in the field of neuro-orthopedics, included experts from North America,

Europe, and Australasia, with a combined total of over 330 years of experience. Inclusion of 16 members is within the recommended range for a study using the Delphi methodology. *Delphi Methodology:* This study exhibited good quality in this category. The goal of the study was to present results reflecting the consensus of the group, as opposed to merely quantifying the level of agreement. None of the experts on the panel dropped out of the study. Panel member anonymity was maintained by the use of an electronic survey based on an online data collection and management system, where only the facilitator had access to (if needed) the votes and comments of specific members of the panel. Feedback was provided to all panel members at each stage, and at the end, of the iterative process. *Results:* This study had good quality, with opportunity for improvement, in this category. Consensus, or lack thereof, was clearly defined, based on the review of the literature and previous Delphi surveys performed by this group. The number of rounds of the process was at the discretion of the facilitator, and criteria for dropping an item were not established (even though none of the items was dropped). The distribution of responses for each items scored by the panelists has been presented in the article. All panelists had the opportunity to review and edit the article prior to submission for publication. Employing the criteria to evaluate the quality of 98 Delphi method studies used by a recent study, the current study would rank in the top third of studies analyzed.<sup>25</sup>

Future work using Delphi methodology by our group will seek to improve the structural elements of the method, by formalizing criteria for dropping items and determining endpoints for iterative rounds of questioning. This is, to our knowledge, the first study to seek consensus concerning the assessment of static foot alignment and dynamic foot function in children with CP. Experience and improved understanding of the modified Delphi technique should facilitate its application to other areas in pediatric orthopedics. The format developed in this study (i.e. considering the categories of Functional Anatomy and Terminology, Observational Gait Analysis of the Foot, Physical Examination of the



Foot, Radiographic Assessment, Quantitative Assessment of Foot Function, and Classification of Foot Deformity) will be used as a template for future Delphi technique studies to seek consensus (and identify lack of consensus) on clinical decision-making for the management of specific foot segmental malalignment patterns commonly seen in children with CP.

### Author contributions

J.R.D. contributed to conception and design; data acquisition; analysis and interpretation of data; drafting, critical revision, and final approval of the submitted manuscript. J.S. contributed to conception and design; drafting, critical revision, and final approval of the submitted manuscript. R.K. contributed to conception and design; drafting, critical revision, and final approval of the submitted manuscript. T.D. contributed to conception and design; drafting, critical revision, and final approval of the submitted manuscript. B.J.S. contributed to conception and design; drafting, critical revision, and final approval of the submitted manuscript. J.M. contributed to conception and design; data acquisition; analysis and interpretation of data; drafting, critical revision, and final approval of the submitted manuscript. W.S. contributed to conception and design; data acquisition; drafting, critical revision, and final approval of the submitted manuscript. K.G. contributed to conception and design; drafting, critical revision, and final approval of the submitted manuscript. M.V. contributed to conception and design; data acquisition; analysis and interpretation of data; drafting, critical revision, and final approval of the submitted manuscript. U.N. contributed to conception and design; drafting, critical revision, and final approval of the submitted manuscript. H.C. contributed to conception and design; drafting, critical revision, and final approval of the submitted manuscript. T.N. contributed to conception and design; drafting, critical revision, and final approval of the submitted manuscript. J.R. contributed to conception and design; drafting, critical revision, and final approval of the submitted manuscript. A.V.C. contributed to conception and design; drafting, critical revision, and final approval of the submitted manuscript. K.P. contributed to conception and design; drafting, critical revision, and final approval of the submitted manuscript. T.T. contributed to conception and design; drafting, critical revision, and final approval of the submitted manuscript. E.R. contributed to conception and design; drafting, critical revision, and final approval of the submitted manuscript.

### Declaration of conflicting interests

The author(s) declared the following potential conflicts of interest with respect to the research, authorship, and/or publication of this article: J.M. has received research support in royalties and as a consultant for Nuvasive. W.S. is a member of the Editorial Board of the Journal of the Pediatric Orthopaedic Society of North America, is a member of the National Advisory Board (NIH) on Medical Rehabilitation Research, and the Eunice Kennedy Shriver National Institute of Child Health and Human Development (NICHD), all outside the scope of the submitted work. H.C. has received personal fees from OrthoPediatrics Corp. and Allergan Corp., outside the scope of the submitted work. J.R.D. is a consultant and board member of OrthoPediatrics Corp., outside the scope of the submitted work. R.K. owns stock

in Zimmer/Biomet, Medtronic, Pfizer, and Johnson and Johnson, is on the Editorial Board of the Journal of Pediatric Orthopaedics and his son works for Intrinsic Therapeutics, outside the scope of the submitted work. J.R. has received personal fees from OrthoPediatrics Corp., outside the scope of the submitted work and research support Smith Nephew Corp and is on Editorial Board of Gait and Posture. K.G. has received research support from NHMRC-CRE CP-Achieve and is on the Surgeon's Advisory Board of OrthoPediatrics Corp. E.R. is supported by the Bob Dicken's Fellowship in Paediatric Orthopaedics. The other authors declare no conflict of interest.

### Ethical approval

All procedures performed in the studies involving human participants were in accordance with the ethical standards of the institutional and/or national research committee and with the 1964 Helsinki declaration and its later amendments or comparable ethical standards. This article does not contain any studies with animals performed by any of the authors.

### Funding

The author(s) received no financial support for the research, authorship, and/or publication of this article.

### Informed consent

No patients or clinical subjects were used in this study, so informed consent was not required.

### ORCID iDs

Jon R Davids  <https://orcid.org/0000-0002-1639-6519>

Robert Kay  <https://orcid.org/0000-0002-4498-6815>

### References

1. Davids JR. Biomechanically based clinical decision making in pediatric foot and ankle surgery. In: Sabharwal S (ed.) *Pediatric lower limb deformities*. Cham: Springer, 2016, pp. 153–162.
2. Davids JR, Ounpuu S, DeLuca PA, et al. Optimization of walking ability of children with cerebral palsy. *Instr Course Lect* 2004; 53: 511–522.
3. Davids JR, Rowan F, Davis RB. Indications for orthoses to improve gait in children with cerebral palsy. *J Am Acad Orthop Surg* 2007; 15(3): 178–188.
4. Trevelyan EG, Robinson N. Delphi methodology in health research: how to do it? *Eur J Integ Med* 2015; 7: 423–428.
5. Kay RM, Pierz K, McCarthy J, et al. Distal rectus femoris surgery in children with cerebral palsy: results of a Delphi consensus project. *J Child Orthop* 2021; 15(3): 270–278.
6. McCarthy J, Wade Shrader M, Graham K, et al. Establishing surgical indications for hamstring lengthening and femoral derotational osteotomy in ambulatory children with cerebral palsy. *J Child Orthop* 2020; 14(1): 50–57.
7. Rutz E, McCarthy J, Shore BJ, et al. Indications for gastrosoleus lengthening in ambulatory children with cerebral palsy: a Delphi consensus study. *J Child Orthop* 2020; 14(5): 405–414.

8. Veugelers R, Gaakeer MI, Patka P, et al. Improving design choices in Delphi studies in medicine: the case of an exemplary physician multi-round panel study with 100% response. *BMC Med Res Methodol* 2020; 20(1): 156.
9. Ponseti IV, Campos J. Observations on pathogenesis and treatment of congenital clubfoot. *Clin Orthop Relat Res* 1972; 84: 50–60.
10. Ponseti IV, El-Khoury GY, Ippolito E, et al. A radiographic study of skeletal deformities in treated clubfeet. *Clin Orthop Relat Res* 1981(160): 30–42.
11. Van Langelaan EJ. A kinematical analysis of the tarsal joints: an X-ray photogrammetric study. *Acta Orthop Scand Suppl* 1983; 204: 1–269.
12. Kulkarni VA, Kephart DT, Davids JR. Enhancing observational gait analysis: techniques and tips for analyzing gait without a gait lab. *JPOSNA* 2020; 2(3): 1–9.
13. Eek MN, Beckung E. Walking ability is related to muscle strength in children with cerebral palsy. *Gait Posture* 2008; 28(3): 366–371.
14. Fowler EG, Goldberg EJ. The effect of lower extremity selective voluntary motor control on interjoint coordination during gait in children with spastic diplegic cerebral palsy. *Gait Posture* 2009; 29(1): 102–107.
15. Saraswat P, MacWilliams BA, Davis RB, et al. A multi-segment foot model based on anatomically registered technical coordinate systems: method repeatability and sensitivity in pediatric planovalgus feet. *Gait Posture* 2013; 37(1): 121–125.
16. Saraswat P, MacWilliams BA, Davis RB, et al. Kinematics and kinetics of normal and planovalgus feet during walking. *Gait Posture* 2014; 39(1): 339–345.
17. Hoffer MM, Perry J. Pathodynamics of gait alterations in cerebral palsy and the significance of kinetic electromyography in evaluating foot and ankle problems. *Foot Ankle* 1983; 4(3): 128–134.
18. Jameson EG, Davids JR, Anderson JP, et al. Dynamic pedobarography for children: use of the center of pressure progression. *J Pediatr Orthop* 2008; 28(2): 254–258.
19. Beckmann JS, Lew D. Reconciling evidence-based medicine and precision medicine in the era of big data: challenges and opportunities. *Gen Med* 2016; 8(1): 134.
20. Accad M, Francis D. Does evidence based medicine adversely affect clinical judgment? *BMJ* 2018; 362: k2799.
21. Sheridan DJ, Julian DG. Achievements and limitations of evidence-based medicine. *J Am Coll Cardiol* 2016; 68(2): 204–213.
22. Sturmberg JP. Evidence-based medicine-not a panacea for the problems of a complex adaptive world. *J Eval Clin Pract* 2019; 25(5): 706–716.
23. Dalkey N, Helmer O. An experimental application of the Delphi method to the use of experts. *Manag Sci* 1963; 9(3): 458–467.
24. Dalkey NC. *The Delphi method: an experimental study of group opinion*. Santa Monica, CA: Rand Corporation, 1969.
25. Diamond IR, Grant RC, Feldman BM, et al. Defining consensus: a systematic review recommends methodologic criteria for reporting of Delphi studies. *J Clin Epidemiol* 2014; 67(4): 401–409.
26. Marchais-Roubelat A, Roubelat F. The Delphi method as a ritual: inquiring the Delphic Oracle. *Technol Forecast Soc Change* 2011; 78: 1491–1499.
27. Davids JR, Gibson TW, Pugh LI. Quantitative segmental analysis of weight-bearing radiographs of the foot and ankle for children: normal alignment. *J Pediatr Orthop* 2005; 25(6): 769–776.
28. Graham HK, Thomason P, Willoughby K, et al. Musculoskeletal pathology in cerebral palsy: a classification system and reliability study. *Children* 2021; 8(3): 252.
29. Sinha IP, Smyth RL, Williamson PR. Using the Delphi technique to determine which outcomes to measure in clinical trials: recommendations for the future based on a systematic review of existing studies. *Plos Med* 2011; 8(1): e1000393.