



Absence of Meckel's Cave with Trigeminal Neuralgia: A Case Report

Asma AlHatmi¹ Ahmed Al-Qassabi² Sameer Bhimjibhai Raniga³ Eiman Al Ajmi³

¹Department of Radiology, Ibri Hospital, Ibri, Oman

²Division of Neurology, Department of Medicine, Sultan Qaboos University Hospital, Muscat, Al-Khoudh, Oman

³Department of Radiology and Molecular Imaging, Sultan Qaboos University Hospital, Muscat, Al-Khoudh, Oman

Address for correspondence Eiman Al Ajmi, MD, FRCPC, FRCR, Department of Radiology and Molecular Imaging, Sultan Qaboos University Hospital, College of Medicine and Health Sciences, Sultan Qaboos University, Muscat, Al-Khoudh 123, Oman (e-mail: ealajmi@squ.edu.om).

Indian J Radiol Imaging 2023;33:124–128.

Abstract

Trigeminal neuralgia (TN) is a disabling painful condition along the course of the sensory distribution of the trigeminal nerve that most commonly occurs due to vascular compression or conflict at the root entry zone of the trigeminal nerve. We report a 27-year-old female patient who presented with pain and an electric shock-like sensation on the right side of her face that started three years ago. Magnetic resonance imaging of the brain was done and revealed no neurovascular conflict along the course of the trigeminal nerve. The absence of Meckel's cave with atrophy of the cisternal segment of the trigeminal nerve on the affected side was reported. The absence of Meckel's cave is an exceedingly rare cause of TN, and only a handful of reported cases in the literature suggest the association between them.

Keywords

- ▶ trigeminal neuralgia
- ▶ neurovascular conflict
- ▶ root entry zone
- ▶ Meckel's cave

Introduction

Trigeminal neuralgia (TN) is a debilitating disease that is characterized by frequent shooting severe and painful attacks along the divisions of the trigeminal nerve.^{1,2} It is usually provoked by different daily activities like drinking, eating, or brushing teeth.^{2,3} It occurs suddenly, lasts for a short time, and is spontaneously terminated. The estimated prevalence is 0.07% of the population with gender predilection toward females.⁴ The classic TN is caused by a neurovascular conflict of the trigeminal nerve, commonly at the root entry zone by a loop of the superior cerebellar artery.⁵ However, any compressive lesion along the course of the trigeminal nerve may cause similar symptoms of TN.^{4,5} One of the rarest reported causes of TN is the absence of Meckel's cave.^{1,2} The management plan of TN depends on the causative factor. Surgical decompression, stereotactic radiosurgery, and percutaneous balloon compression are the most common surgical methods used in such

cases.^{1,6} Medications are also used for symptomatic relief of neuralgia.² We presented a case of TN with the absence of Meckel's cave with its clinical profile and radiological findings. Imaging features, differential diagnosis, and treatment options are discussed. To the best of our knowledge, this is the first case of an absent Meckel's cave presenting with TN to be reported in Oman.

Case Report

A 27-year-old woman with no previous significant medical background presented to the neurology outpatient clinic with a 3-year history of pain and electric-shock like sensation on the right side of her face that had exaggerated in the previous three months. She described it as an electrical sensation that starts around the right angle of her mouth and spreads to the whole face. She had around 10 attacks per day, each episode lasting only seconds and aborting

article published online
December 7, 2022

DOI <https://doi.org/10.1055/s-0042-1759638>.
ISSN 0971-3026.

© 2022. Indian Radiological Association. All rights reserved.
This is an open access article published by Thieme under the terms of the Creative Commons Attribution-NonDerivative-NonCommercial-License, permitting copying and reproduction so long as the original work is given appropriate credit. Contents may not be used for commercial purposes, or adapted, remixed, transformed or built upon. (<https://creativecommons.org/licenses/by-nc-nd/4.0/>)
Thieme Medical and Scientific Publishers Pvt. Ltd., A-12, 2nd Floor, Sector 2, Noida-201301 UP, India

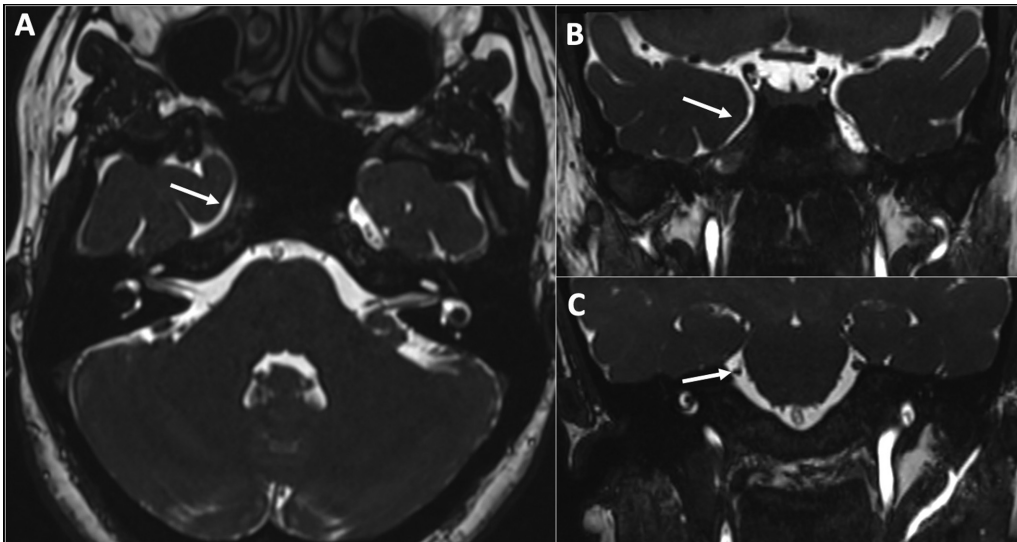


Fig. 1 CISS images show the absence of right Meckel's cave (arrow) in the axial plane (A) and coronal plane (B). Hypoplastic cisternal segment of the right trigeminal nerve is seen in the coronal plane (arrow) (C).

spontaneously. The pain is sometimes triggered by cold air. She reported no history of other cranial nerve involvement, limb weakness, ataxia, or sensory loss. She was started on carbamazepine 200 mg twice daily in another hospital before presentation to us, and she reported modest benefit. Her clinical examination was normal, including a sensory exam of all trigeminal nerve branches bilaterally. The rest of the cranial nerves' exam was also unremarkable. There was no focal weakness, cerebellar signs, or sensory deficit in the rest of her neurological exam. Magnetic resonance imaging (MRI) of the brain was done to look for neurovascular conflict. MRI revealed no neurovascular conflict or compressive lesion in the course of the trigeminal nerve. The absence of Meckel's cave with atrophy of the cisternal segment of the trigeminal nerve on the affected side was reported (► **Figs. 1** and **2**). The diagnosis of TN secondary to the absence of Meckel's cave was made based on clinical and radiological findings. The patient was managed conservatively and switched from carbamazepine to pregabalin; however, she could not tolerate the sedative side effects. She was intolerant of gabapentin

as well. At the last follow-up, she was put back on carbamazepine regular release form, 400 mg three times daily, with adequate control of her symptoms.

Discussion

Trigeminal neuralgia is a debilitating disease compromising the quality of life. It is diagnosed clinically and defined as frequent paroxysmal shooting severe painful attacks along the divisions of the trigeminal nerves according to the International Association for the Study of Pain (IASP) and the International Headache Society (IHS) diagnostic criteria and definition.^{1,2} The estimated prevalence of TN is 0.07% of the general population, with female predominance.³ TN is usually triggered by daily activities such as drinking, eating, or brushing one's teeth.^{3,4} Our patient presented with typical TN with no specific triggering factors except for cold air.

The classic TN is caused by a vascular compression of the trigeminal nerve, commonly at the root entry zone by a loop of the superior cerebellar artery.⁵ However, any compressive

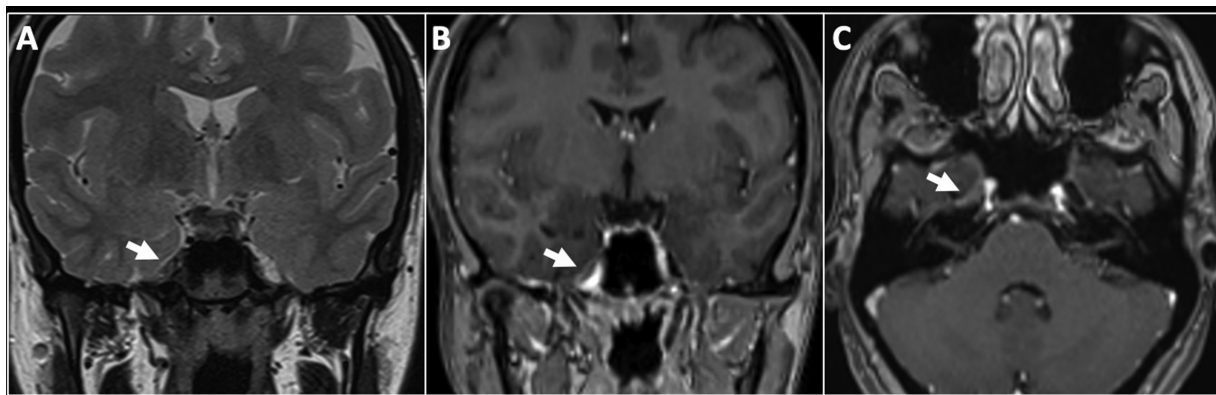


Fig. 2 (A) A coronal T2 weighted image demonstrates the absence of Meckel's cave on the right side (arrow). Coronal (B) and axial (C) reformats of 3D contrast enhanced T1 magnetization-prepared rapid gradient-echo (MPRAGE) show the absence of the right Meckel cave with collapsed enhancing dura without an underlying lesion (arrow).

Table 1 Summary of findings in our patient and comparison with reported cases of absent or hypoplastic Meckel's cave presenting with trigeminal neuralgia in the literature

Authors	Number of patients	Age at presentation	Gender	MR imaging findings	Affected side	Medical management	Surgical management of TN	Prognosis after surgical intervention
Al Hatmi et al (2022)	1	27	Female	- Ipsilateral absence of Meckel cave and trigeminal nerve atrophy. -No neurovascular conflict	Right	Higher dose Carbamazepine with some benefit. Pregabalin and gabapentin trials limited by side effect	No	-
Jain et al (2021)	7	Mean: 46.6 years Range: 36–80 years	All females	- Ipsilateral absence of Meckel cave and trigeminal nerve atrophy. -No neurovascular conflict.	5 on the right side and 2 on the left side	Carbamazepine or gabapentin. -4/6 patients had improvement in the first 6 months. -Later 3/4 patients had recurrence of symptoms	-2 patients underwent microvascular decompression - One patient underwent rhizotomy -2 patients underwent stereotactic radiosurgery - One patient underwent balloon compression	-Failed microvascular decompression -Positive response after balloon surgery. -Adequate response after stereotactic radiosurgery
Cleary et al (2019)	3	Mean 44 years Range (41–46 years)	all Females	-Ipsilateral absence of Meckel cave with no trigeminal nerve atrophy -No neurovascular conflict	2 on the right side and 1 on left side	Carbamazepine with initial response.	All underwent stereotactic radiosurgery	Significant response
Shandani et al (2020)	1	35	Female	- Ipsilateral absence of Meckel's cave with no trigeminal nerve atrophy - No neurovascular conflict.	Right	refractory to medical therapy (no specific name of medication was mentioned).	No	-
Sundararajan et al (2018)	1	42	Female	- Ipsilateral absence of Meckel's cave and trigeminal nerve ganglion atrophy. -No neurovascular conflict	Right	Gabapentin and low dose of ibuprofen with improvement after 1 month	No	-

lesion along the course of the trigeminal nerve may cause similar symptoms of TN.^{5,7,8} Some cases of TN may not show any evidence of compressive lesions and are labeled as idiopathic.^{9,10} MRI of the brain plays a cardinal role in detecting any neurovascular conflict or compressive lesion in Meckel's cave with a sensitivity of 97% and a specificity of 50%.² One of the rarest reported causes of TN is the absence of Meckel's cave.^{1,2} MRI of our patient did not reveal any neurovascular conflict or compressive lesion along the trigeminal nerve course. However, aplasia of Meckel's cave with atrophy of the cisternal segment of the trigeminal nerve was seen on the affected side. The association between TN and the absence of Meckel's cave was described and suggested in the literature.¹

Meckel's cave is a potential space filled with cerebrospinal fluid (CSF) in the middle cranial fossa and acts as a channel for the trigeminal nerve and Gasserian ganglion.^{2,10} It measures ~15 mm in length and 9 mm in width.¹ Although it is a small space, it can be affected by different entities such as congenital, vascular, infectious, inflammatory, and neoplastic processes, leading to secondary trigeminal neuropathy.^{6,11} Absence of Meckel's cave is a rare finding, and early radiological diagnosis of this abnormality is essential for management.² The pathophysiology behind the absence of Meckel's cave is still not clearly understood. However, it could be congenital or acquired.^{1,2} Regarding the primary aplastic or hypoplastic Meckel's cave, TN may occur later with age due to progressive compression of the ganglion.^{8,10} The presence of CSF surrounding the ganglia in the Meckel's cave is crucial for the normal functioning of the sensory ganglia.¹ Loss of CSF leads to peripheral myelin and endothelial injury of ganglia.^{2,10} Flattening of Meckel's cave can be seen in spontaneous intracranial hypotension secondary to CSF volume loss.¹ Many patients with spontaneous intracranial hypotension may suffer from facial pain and headache.²

There are only a handful of reported cases in the literature of patients with absent Meckel's cave presenting with TN.^{1,2,7,8} All reported patients were females with an age range from 35 to 80 years, with a mean of 44.6 years and a median of 41.5 years. Some of those patients started to have symptoms at a younger age before having the diagnosis on imaging. Among all reported cases of absent/hypoplastic Meckel's cave, most patients presented with classical TN. The right side is commonly affected, which is similar to our patient presentation. On imaging, most of the reported cases showed an ipsilateral absence of or hypoplastic Meckel's cave associated with trigeminal nerve atrophy. Cleary et al and Shandani et al reported two cases of ipsilateral absence of Meckel's cave with no trigeminal nerve atrophy.^{2,7} Hypoplastic Meckel's cave has been also reported without trigeminal neuralgia. Milane et al reported a case of hypoplastic Meckel's cave and hypoplastic trigeminal nerve presented with corneal ulcer in the ophthalmic division of trigeminal nerve.⁹

The management plan for TN depends on the causative factor.¹² Surgical decompression, stereotactic radiosurgery, and percutaneous balloon compression are the most com-

mon surgical methods in practice.^{1,8,12} Medications are also used for symptomatic relief of neuralgia.² The majority of TN cases due to the absence of Meckel's cave are refractory to medical treatment.^{1,7} Some patients may show improvement after balloon compression or stereotactic radiosurgery, which leads to the reestablishment of the CSF space.^{1,2} Jain et al and Cleary et al showed significant positive responses and improvement in TN symptoms after balloon surgery and stereotactic radiosurgery.^{1,2} Our patient was managed conservatively. We started by switching carbamazepine to pregabalin and then gabapentin, with limited effect due to sedative side effects. Later, she was started on a regular form of carbamazepine 400 mg three times daily, which offered her the best control for pain compared with the continuous release formulation. ► **Table 1** summarizes the findings of our patients and compares them with those of the reported cases in the literature.

Conclusion

The absence of Meckel's cave is an uncommon entity associated with TN. The exact cause is still unclear. Neuroimaging has a key role in diagnosing such conditions. The majority of trigeminal neuralgia cases associated with the absence of Meckel's cave are refractory to medical treatment. Some patients with absent Meckel's cave may show improvement after balloon compression or stereotactic radiosurgery. However, further research data on this rare entity is needed for better understanding and management.

Informed Consent

Informed patient consent of publication was obtained.

Conflict of Interest

None declared.

References

- Jain A, Muneer MS, Okromelidze L, et al. Absence of Meckel cave: a rare cause of trigeminal neuralgia. *Am J Neuroradiol* 2021;42(09):1610–1614
- Cleary DR, Handwerker J, Ansari H, Ben-Haim S. Three cases of trigeminal neuralgia with radiographic absence of Meckel's cave. *Stereotact Funct Neurosurg* 2019;97(04):249–254
- Katusic S, Beard CM, Bergstralh E, Kurland LT. Incidence and clinical features of trigeminal neuralgia, Rochester, Minnesota, 1945–1984. *Ann Neurol* 1990;27(01):89–95
- Maarbjerg S, Gozalov A, Olesen J, Bendtsen L. Trigeminal neuralgia—a prospective systematic study of clinical characteristics in 158 patients. *Headache* 2014;54(10):1574–1582
- Lee A, McCartney S, Burbidge C, Raslan AM, Burchiel KJ. Trigeminal neuralgia occurs and recurs in the absence of neurovascular compression. *J Neurosurg* 2014;120(05):1048–1054
- Marinković S, Todorović V, Gibo H, et al. The trigeminal vasculature pathology in patients with neuralgia. *Headache* 2007;47(09):1334–1339
- Shadani K, Kumar A, Rehan B, Banhwar IA. Absent Meckel's cave in MRI, in a clinically diagnosed case of trigeminal neuralgia. A very rare case report. *PJR* 2020;30(04):293–295
- Sundararajan S, Loevner LA, Mohan S. Mandibular myalgia and miniscule Meckel's caves. *ORL J Otorhinolaryngol Relat Spec* 2018;80(02):103–107

- 9 Milne AD, Chui L, Mishra AV, Maxner CE. Unilateral hypoplasia of the trigeminal ganglion. *Can J Ophthalmol* 2005;40(06): 772-774
- 10 Lin J, Zhang Y, Li W, Yan J, Ke Y. Flatness of the Meckel cave may cause primary trigeminal neuralgia: a radiomics-based study. *J Headache Pain* 2021;22(01):104
- 11 Malhotra A, Tu L, Kalra VB, et al. Neuroimaging of Meckel's cave in normal and disease conditions. *Insights Imaging* 2018;9(04): 499-510
- 12 Adams CB, Kaye AH, Teddy PJ. The treatment of trigeminal neuralgia by posterior fossa microsurgery. *J Neurol Neurosurg Psychiatry* 1982;45(11):1020-1026