

Video Article

# Deficient Pms2, ERCC1, Ku86, CcOI in Field Defects During Progression to Colon Cancer

Huy Nguyen<sup>1</sup>, Cristy Loustaunau<sup>1</sup>, Alexander Facista<sup>1</sup>, Lois Ramsey<sup>1</sup>, Nadia Hassounah<sup>1</sup>, Hilary Taylor<sup>1</sup>, Robert Krouse<sup>2,3</sup>, Claire M. Payne<sup>1,4</sup>, V. Liana Tsikitis<sup>3</sup>, Steve Goldschmid<sup>5</sup>, Bhaskar Banerjee<sup>5</sup>, Rafael F. Perini<sup>5</sup>, Carol Bernstein<sup>1</sup>

<sup>1</sup>Department of Cell Biology and Anatomy, College of Medicine, University of Arizona, Tucson

<sup>2</sup>Southern Arizona Veterans Affairs Health Care System, Tucson, AZ

<sup>3</sup>Department of Surgery, College of Medicine, University of Arizona, Tucson

<sup>4</sup>Biomedical Diagnostics and Research, Tucson, AZ

<sup>5</sup>Department of Medicine, College of Medicine, University of Arizona, Tucson

Correspondence to: Carol Bernstein at [bernstein3@earthlink.net](mailto:bernstein3@earthlink.net)

URL: <http://www.jove.com/video/1931>

DOI: [doi:10.3791/1931](https://doi.org/10.3791/1931)

Keywords: Cellular Biology, Issue 41, DNA Repair, Apoptosis, Field Defect, Colon Cancer, Pms2, ERCC1, Cytochrome c Oxidase Subunit I, Ku86, Immunohistochemistry, Cancer Resection

Date Published: 7/28/2010

Citation: Nguyen, H., Loustaunau, C., Facista, A., Ramsey, L., Hassounah, N., Taylor, H., Krouse, R., Payne, C.M., Tsikitis, V.L., Goldschmid, S., Banerjee, B., Perini, R.F., Bernstein, C. Deficient Pms2, ERCC1, Ku86, CcOI in Field Defects During Progression to Colon Cancer. *J. Vis. Exp.* (41), e1931, doi:10.3791/1931 (2010).

## Abstract

In carcinogenesis, the "field defect" is recognized clinically because of the high propensity of survivors of certain cancers to develop other malignancies of the same tissue type, often in a nearby location. Such field defects have been indicated in colon cancer. The molecular abnormalities that are responsible for a field defect in the colon should be detectable at high frequency in the histologically normal tissue surrounding a colonic adenocarcinoma or surrounding an adenoma with advanced neoplasia (well on the way to a colon cancer), but at low frequency in the colonic mucosa from patients without colonic neoplasia.

Using immunohistochemistry, entire crypts within 10 cm on each side of colonic adenocarcinomas or advanced colonic neoplasias were found to be frequently reduced or absent in expression for two DNA repair proteins, Pms2 and/or ERCC1. Pms2 is a dual role protein, active in DNA mismatch repair as well as needed in apoptosis of cells with excess DNA damage. ERCC1 is active in DNA nucleotide excision repair. The reduced or absent expression of both ERCC1 and Pms2 would create cells with both increased ability to survive (apoptosis resistance) and increased level of mutability. The reduced or absent expression of both ERCC1 and Pms2 is likely an early step in progression to colon cancer.

DNA repair gene Ku86 (active in DNA non-homologous end joining) and Cytochrome c Oxidase Subunit I (involved in apoptosis) had each been reported to be decreased in expression in mucosal areas close to colon cancers. However, immunohistochemical evaluation of their levels of expression showed only low to modest frequencies of crypts to be deficient in their expression in a field defect surrounding colon cancer or surrounding advanced colonic neoplasia.

We show, here, our method of evaluation of crypts for expression of ERCC1, Pms2, Ku86 and CcOI. We show that frequency of entire crypts deficient for Pms2 and ERCC1 is often as great as 70% to 95% in 20 cm long areas surrounding a colonic neoplasia, while frequency of crypts deficient in Ku86 has a median value of 2% and frequency of crypts deficient in CcOI has a median value of 16% in these areas. The entire colon is 150 cm long (about 5 feet) and has about 10 million crypts in its mucosal layer. The defect in Pms2 and ERCC1 surrounding a colon cancer thus may include 1 million crypts. It is from a defective crypt that colon cancer arises.

## Video Link

The video component of this article can be found at <http://www.jove.com/video/1931/>

## Protocol

### Preparing tissues to be viewed on slides

1. A colonoscope can be passed into the colon through the rectum. A colonoscope is a long tube that has illumination and a video camera at the head, the ability to pass air into the colon to blow it up like a long balloon to allow better visualization of the colon, and has a passage for biopsy forceps that can extend beyond the video camera to pinch off a 3-5 millimeter area of the inner surface "skin" or mucosal layer of the colon to give us a biopsy specimen. The biopsy forceps can also be used to remove potentially pre-cancerous polyps found in the colon.
2. We obtained biopsies of normal colonic mucosal tissues from patients, with informed consent. These patients were undergoing a screening colonoscopy in a gastrointestinal clinic. Our biopsies were placed in jars of formalin. After 4 hours, the formalin was replaced by 70% alcohol.

3. Similar samples of tissue were taken from areas of colon resections, removed during surgery, that were 1 cm and 10 cm away from colon cancers or adenomas with advanced neoplasia. These tissue samples were also placed in formalin, and if the tissue samples were large, some were kept in formalin for a longer period before being placed in 70% alcohol.
4. The tissue samples are taken to a histology laboratory for being processed and placed in paraffin blocks.
5. Paraffin blocks are chilled in a refrigerator to make them more easily cut by a microtome.
6. Tissue sections of 4 micron thickness are cut from the tissue blocks, using a microtome, and floated on water.
7. For comparing expression of two proteins, for instance ERCC1 and Pms2, alternate tissue sections can be picked up onto two slides, until there are three tissue sections on each of two slides. For instance, sections 1, 3, and 5 can be placed on one slide labeled ERCC1 and sections 2, 4 and 6 can be placed on one slide labeled Pms2. Having three tissue sections immunostained for one protein on a single slide can allow you to see if an unusual staining pattern of a crypt is an artifact or is real, since artifacts would not be repeated in more than one tissue section on a slide. Colon crypts are about 60 microns in diameter, so that about 15 tissue sections could be cut through one crypt, and the same crypt could be viewed on multiple tissue sections per slide.

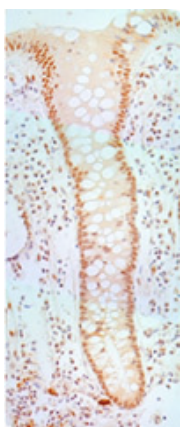
## Immunostaining tissue sections

1. The slides are then put through the immunohistochemical labeling procedure. This is an 8 hour procedure, and is fairly standard. The parts of the procedure that we use, that are not standard, are use of Sequenza containers for staining, and use of a solution to reduce background staining called "Sniper". The "Sniper" solution is sold as a proprietary formula by Biocare Medical, Concord CA.
2. Some of the steps of our procedures are shown here.
3. As an example, for Pms2 immunohistochemistry, slides are first deparaffinized by placing in 3 changes of xylene (3 minutes each), followed by 2 changes in 100% ethanol (2 minutes each), followed by 2 changes in 95% ethanol (2 minutes each), followed by 2 changes of distilled water (2 minutes each). These procedures are carried out under a chemical hood with negative air pressure so that the experimenter is not exposed to the vapors.
4. When formalin was initially used to fix the tissue, parts of the proteins in the tissue sample became cross-linked. Now we need to break the cross-links so that an antibody can recognize the protein of interest. The slides are placed in a buffer solution which is brought to a boil in a microwave oven. This is followed by 10 minutes on the medium setting, followed by cooling for 20 minutes on ice. This step needs to be tested and adjusted for different microwaves, until good results are achieved. Note that for immunostaining CcOI or Ku86 we used a sodium citrate buffer made with 9mL citric acid + 41mL sodium citrate + 450mL H<sub>2</sub>O (a buffer including sodium ions) which had a pH of about 6.0, for ERCC1 we used a citrate buffer made with 2.1g citric acid + 1 liter H<sub>2</sub>O + ~5mL sodium hydroxide to bring pH to 6.1 (a buffer with minimal added sodium ions), and for Pms2 we used a solution made with 5mL Antigen Unmasking solution (by VECTOR) + 533mL H<sub>2</sub>O. Different buffers are needed to increase antibody interaction with particular protein epitopes.
5. The slides are then put into 3% hydrogen peroxide (diluted in methanol) for 20 minutes followed by a rinse in distilled water for 3 minutes, and washed in phosphate-buffered saline (called PBS) for 5 minutes.
6. Slides are then placed into flat narrow staining racks called Sequenza (Shandon Sequenza Immunostaining System from Thermo Scientific) and rinsed with PBS.
7. The slides being immunostained for ERCC1 or Pms2 are then exposed to 10 minutes exposure to an added treatment of 3 drops of a proprietary solution, obtained from Biocare, called "Sniper" which acts to reduce non-specific staining of background proteins.
8. The slides are rinsed with a buffer "TBST" which is 1 ml Tween + 100 ml 10x Tris + 900 ml distilled water [where 10x Tris is 24.2 grams Trizma + 80 grams NaCl + 1,000 ml distilled and deionized water + concentrated HCl (approximately 15 ml) to bring the solution to pH 7.6].
9. Slides are then rinsed three times with buffer, and 100 microliters of DAKO biotinylated secondary antibody at 1:100 dilution (in 2% bovine serum albumin made up in buffer TBST) is added to the slides and incubated for 30 minutes at room temperature.
10. At this point, Vectastain ABC (Avidin Biotin Complex) (from Vector Laboratories) reagent is prepared, using 2.5 ml PBS, 1 drop solution A, 1 drop solution B, and the solution is allowed to stand for 30 minutes.
11. The slides are rinsed 3 times with TBST buffer.
12. Then 3 drops of Vectastain ABC reagent is added and the slides are incubated at room temperature for 30 minutes, followed by rinsing 2 times with TBST.
13. Slides are then immersed in DAB (diamino-benzamide) (2.9 ml DAB + 400 microliters PBS + 250 microliters hydrogen peroxide) for about 5 minutes.
14. Slides are then rinsed 2 times with distilled, deionized water.
15. Counterstaining is done with a dilute solution of hematoxylin for 10 seconds. Slides are rinsed thoroughly in tap water followed by deionized water.
16. Slides are then dehydrated 2 times for 2 minutes in 95% ethanol, 2 times for 2 minutes in 100% ethanol and 2 times for 2 minutes in xylene.
17. A couple of drops of CytoSeal XYL (Richard-Allan Scientific) are then added to the slides and a coverslip applied.
18. Immunohistochemical evaluation of ERCC1, Ku86 and CcOI are performed using the same protocol as for Pms2, but replacing the Pms2 antibody with antibodies for ERCC1, Ku86 and CcOI described in the table below.

## Evaluating tissue sections for crypts deficient in expression of ERCC1, Pms2, Ku86 and CcOI

1. We will look first at tissue sections under a Motic (DM-BA300) photomicroscope for expression of Pms2 and ERCC1 in crypts of the colonic mucosa.
2. Pms2 and ERCC1 are both DNA repair enzymes, and so they are located where the DNA is, in the nuclei of cells of the crypts. This is indicated in Figure 1, where the brown color representing staining for ERCC1, occurs in the nuclei of cells in a crypt. The normal crypt we show first in the microscope was stained for ERCC1, and the brown stain shows the location of ERCC1. We point out the types of cells in the crypts, where "goblet cells" are shaped somewhat like a wine glass, with nuclei at a small region at the base of the cells at the outer edge of the crypt, and a ballooning out section, filled with white mucin granules in the part of the cell on the inside of the crypt. The other two types of cells look somewhat alike in our stained sections, and they are the enterocytes and enteroendocrine cells, and their nuclei are also at the

- outer edge of the crypt, at the base of the cells. In biopsies taken from patients who never had a colonic neoplasia, or in biopsies far from any site of colon cancer, almost all of the nuclei in all crypts show normal high level of expression of ERCC1 as shown here.
- To orient our observations, tissue sections obtained from biopsies of patients with no colonic neoplasia are observed for levels of expression of Pms2, ERCC1, CcOI or Ku86 in normal colonic mucosa. We can observe all the crypts in a normal tissue section, with a 40x objective lens, as we slowly go through an entire tissue section and point out the crypts, the interstitial cells, any lymphoid nodules on the slide, and the muscularis (if present in the biopsy).
  - We also point out that there are just several cells at the base of the crypt which are the stem cells. These stem cells generate all of the about 2,000 cells of the complete crypt. A stem cell with a mutation or an epimutation can take over the whole stem cell niche. Then the whole crypt may have altered staining for an enzyme of interest (crypt conversion) as we show in this new slide where we see whole crypts deficient for CcOI next to crypts that have high expression of CcOI.
  - Then we show a slide from a patient with a colon cancer or an adenoma with advanced neoplasia. On this slide, some crypts have normal high level of expression for ERCC1 and some have lower levels of expression. All of the crypts within the tissue section are photographed at low resolution with a 10x objective lens, and the images are tiled so that the entire tissue section is seen in one image. The crypts are then numbered.
  - The crypts with high expression of the enzyme, typical of crypts in biopsies far from any cancer, are called level "4" staining. Other levels are "0" if there is no expression detectable, "1" if just barely detectable expression is evident, "2" if there is expression present, but at a much lower level than level 4, and "3" if expression is present at a level lower than 4, but fairly strong. We dot each slide on the low resolution image blue for 4, green for 3, yellow for 2, orange for 1 and red for 0. Here we show going through a section from a biopsy using a 40x objective lens. We dot the crypts on the low resolution image.



**Figure 1.** A colonic crypt showing high expression of ERCC1 in the nuclei of crypt cells. All colors in this image were equally enhanced in contrast and saturation, using Paint Shop Pro 5.

## Representative Results

- The alternate tissue sections on separate slides allow us to look at the same colonic crypts, with expression of two different proteins shown by immunohistochemistry. The image of one crypt stained for Pms2 and the same crypt stained for ERCC1 is shown on adjacent microscopes with adjacent computer monitors. This allows us to determine whether there is joint deficiency for two proteins or whether the deficiencies in each of the proteins, while each is frequent, occurs independently. We have three tissue sections per slide, so that any apparent deficiency in expression of a protein can be verified as being deficient on more than one section, and not due to an artifact. In tissues surrounding colon cancers, where there is a field defect giving rise to the cancer, there is a high frequency of crypts deficient for ERCC1 and Pms2.
- We have also used immunohistochemistry to find the frequency of crypts deficient for Ku86 and CcOI. On this slide, we go through an entire tissue section immunostained for Ku86, using a 40x objective lens, and we can see that few crypts are deficient for Ku86 in this tissue section.
- Similarly, on this slide, we go through an entire tissue section immunostained for CcOI, using a 40x objective lens, and we can see that only a moderate number of crypts are deficient for CcOI.

## Discussion

- It is very important to have 3 tissue sections per slide. Bubbles can occur when applying the media carrying the antibody, so that some crypts or portions of crypts may not be stained adequately just because a bubble prevented the antibody from reacting with the tissue section. Crypts are about 60 microns in diameter, and tissue sections are 4 microns thick, so there could be as many as 15 tissue sections through the same crypt. It is usually possible to find the same crypt, using morphology of the crypt as a guide, on multiple tissue sections placed on a slide.
- In our recent studies, for large tissue samples, staining in a Sequenza may not give good antibody coverage to the tissue. In these cases, one may prefer to use hand staining of the tissue, where a drop of media containing the antibody is hand-placed over each tissue sample.
- To clearly see the brown staining showing expression of the immunostained protein, and the blue staining showing nuclear DNA on the computer monitor, the Motic photomicroscope software is adjusted as follows: Gain 0, Offset 0, Enhance 0, 255, Gamma 1.00, 0, Sharpness 1, Color Correction 7, R, G, B Gain 1.00, and R, G, B Brightness 0. The resolution is set at 1024 x 768, and White Balance is enabled.
- Our method could be used with any proteins thought to be important in progression to colon cancer, to assess their frequency of deficiency, or possibly overexpression, in field defects surrounding colon cancers or adenomas with advanced neoplasia.

5. **Field defects are a part of progression to cancer**

The term "field cancerization" was first used by Slaughter *et al.* in 1953<sup>1</sup> to describe an area or "field" of epithelium that has been preconditioned by largely unknown processes (at the time) so as to predispose it towards development of cancer. The initial use was in the context of oral cancers. Since then, the terms "field cancerization" and "field defect" have been used more widely to describe any pre-malignant tissue in which new cancers are more likely to arise, and the concept of field cancerization in clinical oncology has received increasing attention<sup>2</sup>. We recently reviewed the evidence for field defects in gastrointestinal cancer<sup>3</sup>. Included in this review were the results of a dozen studies providing evidence of field defects in the colon.

Field defects in the colonic mucosa probably arise by natural selection of mutant cells or epigenetically altered cells among the stem cells of a crypt such that one stem cell survives niche succession<sup>4</sup>. Genetic instability or a mutator phenotype, perhaps due to reduction of DNA nucleotide excision repair or DNA mismatch repair, would accelerate this process (and a frequent defect in Pms2 was previously reported in areas surrounding colon cancers<sup>5</sup>). If, in a normal population of stem cells in the colonic mucosa, a cell acquires a selective advantage through a mutation or an epimutation, it will tend to expand clonally at the expense of neighboring stem cells. In the colonic mucosa, the stem cell niche is occupied by  $\leq 5$  cells<sup>6</sup> which then give rise to all (approximately 2,000) cells of the crypt. A take-over of the stem cell niche by a mutant or epigenetically altered cell type results in "crypt conversion"<sup>7</sup>.

The spread of mutated clones (converted crypts) in the colonic epithelium may most often occur by crypt fission<sup>8</sup>. An example of crypt fission is shown in Figure 2. In this way a patch of abnormal tissue arises. Within such a patch, a second such mutation may occur so that a given crypt acquires an advantage compared to other crypts within the patch, and this crypt will expand clonally forming a secondary patch within the original patch. Within this new patch, the process may be repeated several more time, perhaps over decades, until a malignant stem cell arises which clonally expands into a cancer. If this is the general process by which sporadic colonic adenocarcinomas arise, then colonic adenocarcinomas generally should be associated with, and be preceded by, fields of abnormality. Thus a patch of converted crypts might be expected to have detectable defects in the area surrounding an adenoma with advanced neoplasia, or surrounding a colon cancer.

From this model of pre-tumor progression, one would expect to find genetic or epigenetic alterations related to pre-tumor progression among tissue samples taken from the non-neoplastic colonic mucosa in areas surrounding neoplastic lesions of the colon that are likely to progress to cancer. In particular, defects in DNA repair enzymes, or in proteins necessary for apoptosis, would contribute to progression by enhancing genomic instability, and might be expected to be found in a defective field.

6. **Selection for deficiency in Pms2 when cells are deficient for ERCC1 and subjected to a DNA damaging agent**

Nara *et al.*<sup>9</sup> grew 25 cultures of Chinese hamster ovary cells 43-3B, all with a mutation inactivating the DNA repair gene ERCC1, and treated the cultures with a DNA damaging agent, MNNG. Among the cells surviving the DNA damage treatment, a single cell was isolated from each culture and allowed to form a clone. All the clones isolated were about 10-fold more resistant to killing by MNNG than the parental strain. Of the clones isolated, 22 were proven to be defective in DNA mismatch repair (MMR). Five of these 22 clones were tested by sequencing, and three of the five were deficient for Pms2. This selection for defect in Pms2 was presumably because Pms2 deficiency caused resistance to apoptosis, and therefore ability to survive the added DNA damage remaining in cells when ERCC1 was absent. (Normally, Pms2 senses DNA damage levels, and causes cells to undergo apoptosis when DNA damage is excessive.) Thus, a deficiency in Pms2 is selected for when ERCC1-deficient cells are subjected to DNA damage. Clones defective in both ERCC1 and Pms2 were shown to have about a 500 to 1000-fold greater mutation rate when irradiated with UV than parental cells.

7. **Bile acids cause oxidative stress, are DNA damaging agents and are important in progression to colon cancer**

Deoxycholic acid, a bile acid, increases oxidative stress through the generation of reactive oxygen species (ROS) by multiple processes, including damaging of mitochondria<sup>10</sup>. There is recent evidence that ROS cause epigenetic changes<sup>11</sup>, and at least 15 studies have shown that bile acids, at the increased concentrations accompanying a high fat diet, cause DNA damage<sup>12</sup>. As reviewed by Bernstein *et al.*<sup>12</sup>, there is a positive association between dietary fat consumption and colon cancer incidence. Bile acids are secreted into the intestinal tract in response to fat in the diet, and bile acids act as detergents to aid in the digestion of fat. Thus, a high fat diet is associated with increased bile acid secretion. Fecal bile acid concentrations are elevated in populations with a high incidence of colon cancer, and excessive exposure to bile acids is regarded as a major risk factor for colon carcinogenesis<sup>13</sup>. Bile acids may be a cause of field defects in the colon.

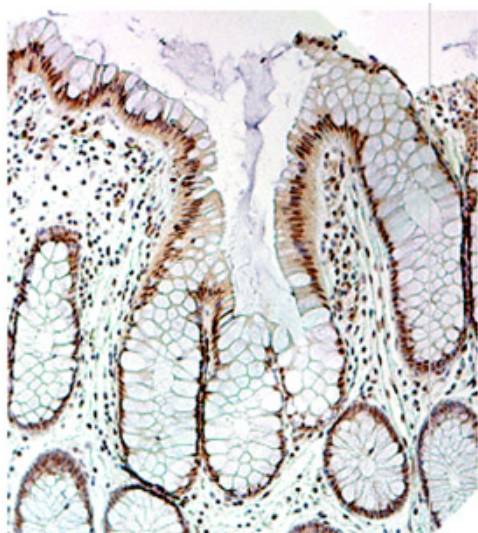


Figure 2. A colonic crypt fissioning into 3 crypts.

## Conclusion

We found a high frequency of crypts deficient in DNA repair genes ERCC1 and Pms2 (Pms2 is also required for apoptosis) in large field defects surrounding colon cancers. Deficiencies in ERCC1 and Pms2 (due to epigenetic changes or mutations) may be early steps in the genetic instability central to progression to colon cancer.

## Acknowledgements

Funding provided by the Southern Arizona Veterans Affairs Health Care System VA Merit Review grant 0142 and Arizona Biomedical Research Commission grant 0803.

## References

1. Slaughter, D.P., Southwick, H.W. & Smejkal, W. Field cancerization in oral stratified squamous epithelium; clinical implications of multicentric origin. *Cancer* 6, 963-968 (1953).
2. Vauthey, J.N. *et al.* Importance of field cancerisation in clinical oncology. *Lancet Oncol.* 1, 15-16 (2000).
3. Bernstein, C. *et al.* Field defects in progression to gastrointestinal tract cancers. *Cancer Lett.* 260, 1-10, (2008).
4. Calabrese, P. *et al.* Colorectal pretumor progression before and after loss of DNA mismatch repair. *Am J Pathol* 164, 1447-1453 (2004).
5. Bernstein, H. *et al.* Reduced Pms2 expression in non-neoplastic flat mucosa from patients with colon cancer correlates with reduced apoptosis competence. *Appl Immunohistochem Mol Morphol* 14, 166-172 (2006).
6. Huang, E.H. *et al.* Aldehyde dehydrogenase 1 is a marker for normal and malignant human colonic stem cells (SC) and tracks SC overpopulation during colon tumorigenesis. *Cancer Res* 69, 3382-3389 (2009).
7. Kim, K.M. & Shibata, D. Methylation reveals a niche: stem cell succession in human colon crypts. *Oncogene* 21, 5441-5449 (2002).
8. Greaves, L.C. *et al.* Mitochondrial DNA mutations are established in human colonic stem cells, and mutated clones expand by crypt fission. *Proc Natl Acad Sci USA* 103, 714-719 (2006).
9. Nara, K., Nagashima, F. & Yasui, A. Highly elevated ultraviolet-induced mutation frequency in isolated Chinese hamster cell lines defective in nucleotide excision repair and mismatch repair proteins. *Cancer Res* 61, 50-52 (2001).
10. Payne, C.M. *et al.* Deoxycholate induces mitochondrial oxidative stress and activates NF- $\kappa$ B through multiple mechanisms in HCT-116 colon epithelial cells. *Carcinogenesis* 28, 215-222 (2007).
11. Lim, S.O. *et al.* Epigenetic changes induced by reactive oxygen species in hepatocellular carcinoma: methylation of the E-cadherin promoter. *Gastroenterology* 135, 2128-2140, 2140.e1-8 (2008).
12. Bernstein, H. *et al.* Bile acids as carcinogens in human gastrointestinal cancers. *Mutat Res* 589, 47-65 (2005).
13. Payne, C.M. *et al.* hydrophobic bile acids, genomic instability, Darwinian selection, and colon carcinogenesis. *Clinical and Experimental Gastroenterology* 1, 19-47 (2008).