

Received: 2014.02.15  
Accepted: 2014.03.05  
Published: 2014.06.14

# TESTIN suppresses tumor growth and invasion via manipulating cell cycle progression in endometrial carcinoma

Authors' Contribution:  
Study Design A  
Data Collection B  
Statistical Analysis C  
Data Interpretation D  
Manuscript Preparation E  
Literature Search F  
Funds Collection G

C 1 **Zhenpeng Gu**  
CD 2 **Guofeng Ding**  
AEF 1 **Kuixiang Liang**  
BD 1 **Hongtao Zhang**  
ED 1 **Guanghong Guo**  
BC 1 **Lili Zhang**  
CDE 1 **Jinxu Cui**

1 Department of Obstetrics and Gynecology, Affiliated Hospital of Binzhou Medical College, Binzhou, Shandong Province, China  
2 Department of Infectious Diseases, Affiliated Hospital of Binzhou Medical College, Binzhou, Shandong Province, China

**Corresponding Author:** Kuixiang Liang, e-mail: binzhouliang@gmail.com  
**Source of support:** Departmental sources

**Background:** The TESTIN gene was demonstrated to be a tumor suppressor in prostate and breast cancer through inhibiting tumor growth and invasion. Herein, we aimed to investigate the detailed functions of TESTIN in the highly sexual hormone (estrogen)-dependent malignancy, endometrial carcinoma.


**Material/Methods:** TESTIN mRNA and protein expression were measured by qRT-PCR, Western blot and immunohistochemistry. Upregulation of TESTIN was achieved by transfecting the pcDNA3.1-TESTIN plasmids into AN3CA cells. Knockdown of TESTIN was achieved by transfecting the shRNA-TESTIN into Ishikawa cells. MTT assay, colony formation assay, and Transwell assay were used to investigate the effects of TESTIN on cellular proliferation and invasion. The apoptotic status and cell cycle were analyzed using flow cytometry. MMP2 secretion was determined by ELISA assay. The xenograft assay was used to investigate the functions of TESTIN in nude mice.

**Results:** Compared to the non-malignant adjacent endometrium, 54% of tumor samples presented downregulation of TESTIN ( $P < 0.001$ ). Loss of TESTIN protein was correlated with advanced tumor stage ( $P = 0.047$ ), high grade ( $P = 0.034$ ), and lymphatic vascular space invasion ( $P = 0.036$ ). *In vitro*, overexpression of TESTIN suppressed cell proliferation, induced dramatic G1 arrest, and inhibited tumor invasion through blocking the secretion of MMP2. Loss of TESTIN accelerated cellular proliferation, promoted cell cycle progression, and enhanced tumor invasion by increasing the secretion of MMP2. Consistently, TESTIN could significantly delay the growth of xenografts in nude mice.

**Conclusions:** TESTIN was commonly downregulated in human endometrial carcinoma and was associated with poor prognostic markers. Moreover, TESTIN significantly inhibited tumor growth and invasion via arresting cell cycle in *in vitro* and *in vivo* experiments. Therefore, we propose that TESTIN might be a prognostic marker and therapeutic target for endometrial carcinoma.

**MeSH Keywords:** **Endometrial Neoplasms – genetics • Endometrial Neoplasms – pathology • Neoplasm Invasiveness – genetics**

**Full-text PDF:** <http://www.medscimonit.com/download/index/idArt/890544>



2417



1



3



33

## Background

Globally, endometrial carcinoma is the leading malignancy of the female genital system [1]. In the United States, there are projected to be 49 500 new cases and 8200 deaths caused by endometrial carcinoma in this year [2]. Despite a high early diagnosis rate (>70%), more than 25% of patients with endometrial carcinoma finally present regional/distant metastasis [3,4]. To date, the main treatments for endometrial carcinoma are still surgery and/or radiation therapy, and chemotherapy is another choice for tumors at later stage or distant metastasis [5,6]. Unfortunately, these approaches can lead significant psychological/physical damage to patients and huge socio-economic burdens. As our current knowledge about the mechanisms involved in endometrial carcinoma is quite limited, further elucidation of its molecular processes is urgently required.

In the past decades, tumor suppressor genes (e.g., p53, p16, PTEN, EMX2, and APC) were demonstrated to be deeply involved in various human cancers [7–11]. Orthotopic expression of these genes was essential for embryogenesis and normal body development, which manipulated cellular proliferation, differentiation, migration, cell cycle progression, and programmed cell death (apoptosis and autophagy). When inactivated by genetic (e.g., mutations, loss of heterozygosity, and copy number variation) or epigenetic alterations (e.g., DNA methylation, histone acetylation, and chromosome remodeling), these tumor suppressors lose their suppressive functions on tumor growth, migration, invasion, and metastasis [12–16].

Recently, the TESTIN gene was characterized as a novel tumor suppressor gene [17]. This gene is located on human chromosome 7q31.2, containing 7 exons and encoding a protein of 421 amino acids [18]. It contains 3 zinc-binding domains that play important roles in focal adhesion [19]. TESTIN protein localizes along actin stress fibers at cell–cell junction areas and the focal adhesion plaques [20]. It interacts with a variety of cytoskeletal factors (e.g., zyxin, VASP, talin, and actin [20]). Moreover, TESTIN was also demonstrated to be able to inhibit the invasion of breast cancer cells through down-regulating miR-29 [21]. As MMP2 (an enzyme that degrades the basement matrix) is a direct target of miR-29, the negative regulation of TESTIN on miR-29 then suppressed the level of MMP2 and the cellular invasion [22]. It had been reported that TESTIN mRNA and/or protein expression was decreased or even totally lost by hypermethylation and loss of heterozygosity in human ovarian cancer, glioblastoma, and sexual hormone-related cancers (prostate cancer and breast cancer) [23–26]. Because it is highly associated with unopposed estrogen exposure, here, we investigated whether TESTIN affected biological behaviors of endometrial carcinoma in *in vitro* and *in vivo* experiments.

**Table 1.** Relationship between TESTIN expression and clinicopathological characteristics.

Variables	TESTIN expression		P value
	Negative	Positive	
Age			
<55	13	15	0.945
≥55	10	12	
Pathologic subtype			
Endometrioid	21	24	0.777
Non-endometrioid	2	3	
Stage			
I	11	22	0.047
II	4	5	
III	4	1	
IV	3	0	
Grade*			
I	13	24	0.034
II	7	2	
III	3	1	
Myometrial invasion			
<1/2	15	20	0.851
≥1/2	6	9	
Lympho node metastasis**			
Negative	8	10	0.741
Positive	3	5	
Lympho vascular space invasion			
Negative	15	28	0.036
Positive	11	6	

\* The grade system are only applicable for endometrioid endometrial cancer; \*\* twenty-three cases took the lymphadenectomy surgery were included in this analysis.

## Material and Methods

### Tissue samples collection

From December 2009 to January 2012, a panel of 50 endometrial carcinoma fresh tissues and their non-malignant adjacent endometrium were collected from patients at the Department of Obstetrics and Gynecology at the affiliated hospital of Binzhou Medical College. All participants provided written informed consent and this study was approved by the Ethical Committee of Binzhou Medical College. All these tumors were staged and graded according to FIGO criteria for endometrial cancer (FIGO 2009). The clinicopathologic parameters of patients are summarized in Table 1.

### Immunohistochemical staining

This experiment was performed strictly following the protocol previously described [21]. In brief, the 5- $\mu\text{m}$  slides were routinely deparaffinized and rehydrated, then antigen was retrieved in pH-9.0 retrieval buffer (Maixin Biotechnology, Fujian, China). Antibody staining was visualized using HISTOSTAIN-Plus IHC Kit (MingRui Biotechnology, Shanghai, China). The primary antibody for TESTIN was purchased from Abcam (ab57292, MA, USA). The results were scored based on the distribution and intensity of staining. The distribution was graded as: focal expression (<10% positive staining), regional expression (11–50% positive staining), and diffuse expression (>50% positive staining). The intensity was graded as: negative, weak, moderate, and intense. The final scores were classified as TESTIN-negative (focal distribution, or regional distribution and negative/weak staining) or TESTIN-positive (diffuse distribution, or regional distribution and moderate/intense staining).

### Cell lines culture

Five endometrial carcinoma cell lines (Ishikawa, KLE, AN3CA, ECC-1, and HEC-1A) were used in this study. All the cells were routinely cultured in DMEM/F12 medium (Gibco, CA, USA) supplemented with 10% fetal bovine serum (Gibco), supplemented with 5%  $\text{CO}_2$  at 37°C.

### Quantitative RT-PCR (qRT-PCR) analysis

Total RNA was collected using TRIzol reagents (Invitrogen, CA, USA) according to the instructions. Then the cDNA was transcribed from 500-ng RNA by the PrimerScript RT reagent (Takara, Dalian, China). qRT-PCR was performed on the StepOne System (Applied Biosystems, CA, USA). The primers and conditions were described in a previous report [26]. GAPDH was set as the endogenous control and relative expression of TESTIN was calculated using the  $2^{-\Delta\Delta\text{CT}}$  method. All the procedures were repeated in triplicate.

### Western blot

Total protein was extracted using RIPA lyses buffer and the protein concentration was measured by the BCA assay kit (Thermo Fisher, CA, USA). An equal amount of protein was loaded onto and separated by 12% SDS-PAGE and transferred to PVDF membrane, then incubated with primary antibody for TESTIN overnight at 4°C. On the second day, after 2-hour incubation with secondary antibody, the specific bands were developed with enhanced chemiluminescence (ECL buffer, Beyotime Biotechnology, Hangzhou, China). GAPDH was used as an endogenous control. Primary antibodies for cyclin D1 and CDK4 were purchased from Cell Signaling (MA, USA). The experiment was repeated in triplicate.

### Plasmid construction and transfection

Both the plasmid containing full-length TESTIN cDNA (pcDNA3.1-TESTIN) and the plasmid carrying shRNA-TESTIN (pGPU6-Neo-GFP-shRNA-TES) were established, as previously described [21]. Geneticin (G418, Sigma, CA, USA) was used to select cells stably overexpressing TESTIN. To establish the Ishikawa cell line with TESTIN knockdown, the pGPU6-Neo-GFP-shRNA-TES plasmids were transfected into Ishikawa cells using Lipofectamine 2000 (Invitrogen, Carlsbad, CA, USA), and Ishikawa cells transfected with empty vector were used as the negative control. The alterations of TESTIN mRNA and protein were confirmed by qRT-PCR and Western blot.

### Cell growth curve

MTT assay was used to determine the impacts of TESTIN on cellular growth. We seeded  $3 \times 10^3$  cells/well into 96-well plates and incubated them overnight. Five  $\mu\text{l}$  of MTT solution (Sigma, 5 mg/ml) was added into each well at the indicated time point. Two hours later, 100  $\mu\text{l}$  DMSO (Sigma) was added to dissolve the formazan. The absorbance value was measured on a microplate reader (BioRad, CA, USA) at 570 nm. The experiments were repeated in triplicate.

### Colony formation assay

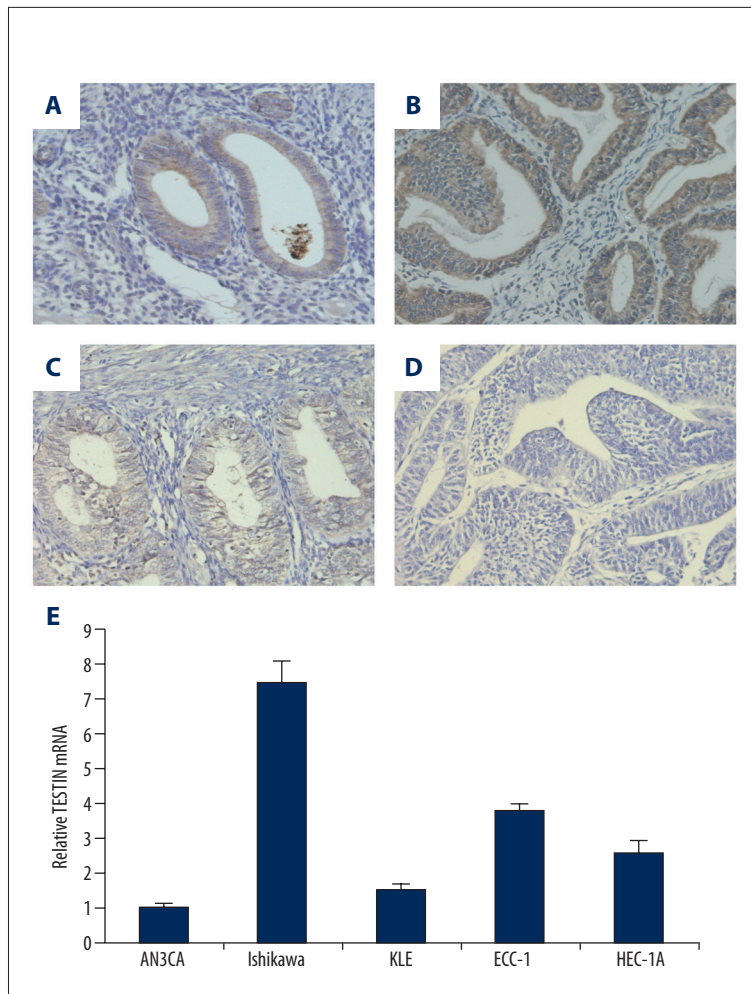
Two hundreds cells were plated into each well of the 6-well plates and routinely cultured. Two weeks later, colonies containing more than 50 cells were fixed with pre-chilled 10% methanol and stained with 0.1% crystal violet. The colony number was counted on an inverted microscope. The experiments were repeated in triplicate.

### Invasion assay

Transwell chambers (8- $\mu\text{m}$  diameter, Millipore, CA, USA) were used to detect the changes of cellular invasion. Briefly,  $1 \times 10^5$  cells were suspended in 300  $\mu\text{l}$  conditioning medium and were plated onto the upper chamber. Another 500  $\mu\text{l}$  DMEM/F12 medium with 10% FBS was put in the bottom chamber. After 24-h incubation, cells on the bottom membrane were fixed by methanol and stained with 0.1% crystal violet. Ten high-power fields (HPF) were randomly chosen to count the cells. The experiment was performed in triplicate.

### Measurement of the concentration of MMP2

We plated  $1 \times 10^5$  cells/well into the 24-well plates and incubated them overnight. The supernatant was collected at the indicated time point, and centrifuged at 200 g for 5 min. Then the MMP2 concentration was measured using the human MMP2 ELISA Kit (R&D Systems, MN, USA) according to instructions.



**Figure 1.** Expression of TESTIN protein in endometrial carcinoma and normal endometrium tissues: (A) TESTIN protein was highly expressed in normal endometrium; (B–D), TESTIN protein was lost gradually in stage I (B), stage II (C), and stage III (D); (E), in the 5 human endometrial carcinoma cell lines, AN3CA presented the lowest and Ishikawa had the highest mRNA expression of TESTIN.

Results were read on the microplate reader. This experiment was repeated in triplicate.

### Apoptosis assay

Apoptotic cells were detected using the PI/Annexin V staining kit (Thermo Fisher) on a FACS Calibur (BD Biosciences, CA, USA). Briefly,  $1.5 \times 10^6$  cells/well were seeded into 6-well plates and incubated 24 h, then the cells were harvested and washed with PBS, stained by PI (2 mg/ml) and Annexin V (100  $\mu$ g/ml), and incubated in the dark for 15 min. The experiments were repeated in triplicate.

### Cell cycle analysis

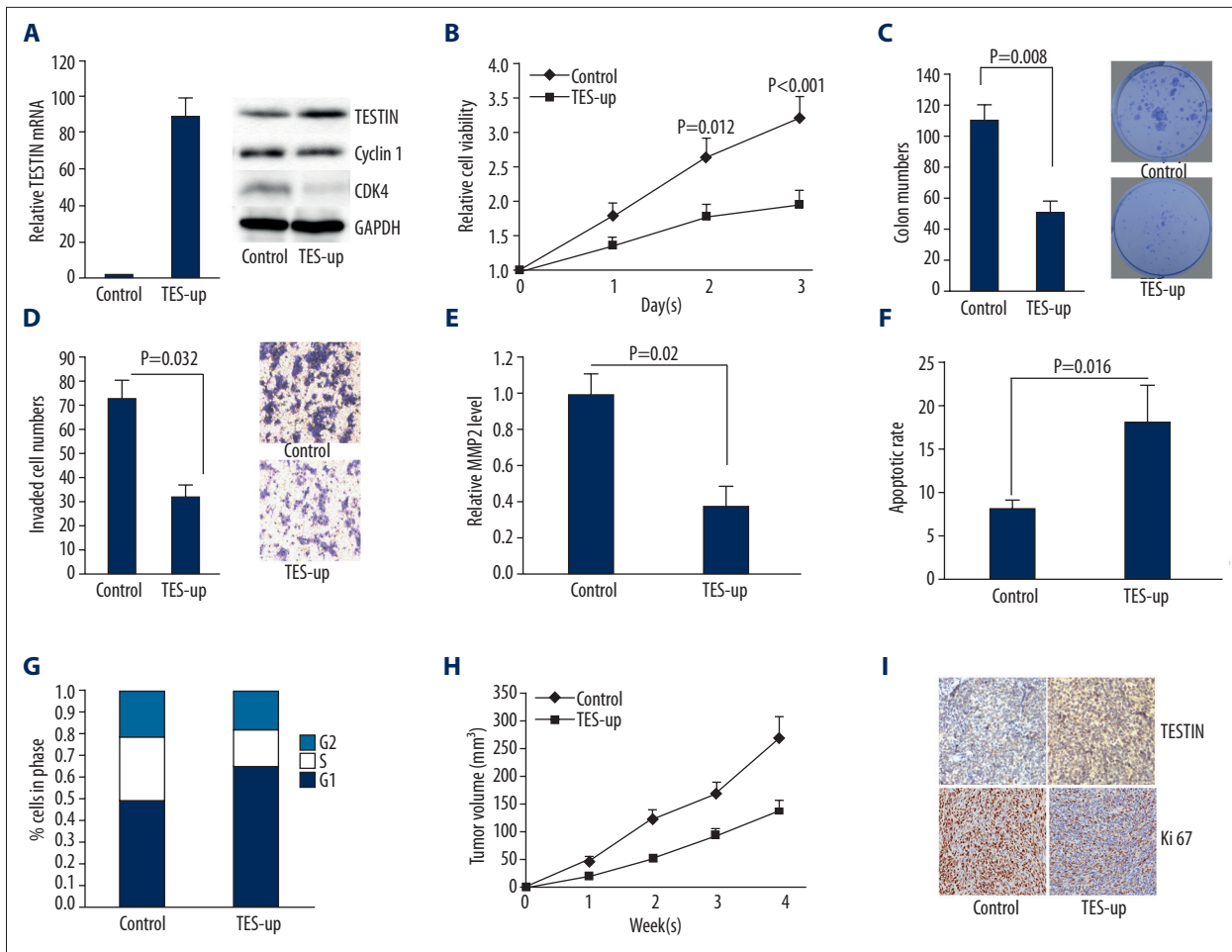
After being routinely cultured for 48 h,  $1 \times 10^6$  tumor cells were collected and fixed with 70% ethanol for at least 2 h at  $-20^\circ\text{C}$ . Then the cells were washed and stained with propidium iodide (PI, 25  $\mu$ g/ml, Sigma) for 15 min in the dark. The cell cycle status was determined on the FACS Calibur. The experiments were performed in triplicate.

### Tumor xenografts assay

The endometrial carcinoma model was established by subcutaneously injecting tumor cells into the posterior flank of nude mice. We purchased 5–6-week-old female BALB/c athymic nude mice from SLAC Biotechnologic Company (Shanghai, China). Animal-handling procedures were performed in accordance with the approval of the Binzhou Medical College Animal Care and Use Committee. In brief,  $1 \times 10^6$  cells were injected on Day 1, and on Days 7, 14, 21, and 28 the length and width of tumor xenografts were measured by calipers using the formula: tumor volume =  $(\text{length} \times \text{width}^2)/2$ . On Day 28, all the mice were sacrificed and fresh tumor tissues were obtained for immunohistochemical staining.

### Statistical analysis

SPSS 16.0 was used for data analysis. All the data are shown as mean  $\pm$ SD.  $\chi^2$  test or t-test was used, as appropriate, and  $P < 0.05$  was defined to be statistically significant.



**Figure 2.** The effects of TESTIN overexpression on AN3CA cells: (A) both mRNA and protein of TESTIN were notably upregulated in AN3CA cells transfected by pcDNA3.1-TESTIN; (B and C) abundant TESTIN suppressed cellular growth and colony-forming abilities (P=0.012 and <0.001 on Day 2 and Day 3 in MTT assay, and P=0.008 in colony formation assay); (D and E) TESTIN inhibited cellular invasion through blocking the secretion of MMP2 (P=0.032 in Transwell assay, and P=0.02 for MMP2 alterations); (F and G) TESTIN significantly induced apoptosis and G1 phase arrest (P=0.016 and P=0.002, respectively); (H) 4TESTIN dramatically decelerated the xenograft growth (P=0.035, 0.018, 0.01 for the 2<sup>nd</sup>, 3<sup>rd</sup>, and 4<sup>th</sup> week); (I) the expression of Ki 67 was suppressed by TESTIN.

**Results**

**TESTIN protein was downregulated in endometrial carcinoma.**

Compared to the adjacent normal endometrium, the tumor tissues presented significantly lower expression of TESTIN; positive TESTIN staining was identified in 96% of the normal adjacent endometrium tissues (48/50), while in the endometrial carcinoma, positive TESTIN staining was only detected in 27 cases (54%, P<0.001, Figure 1, Table 1).

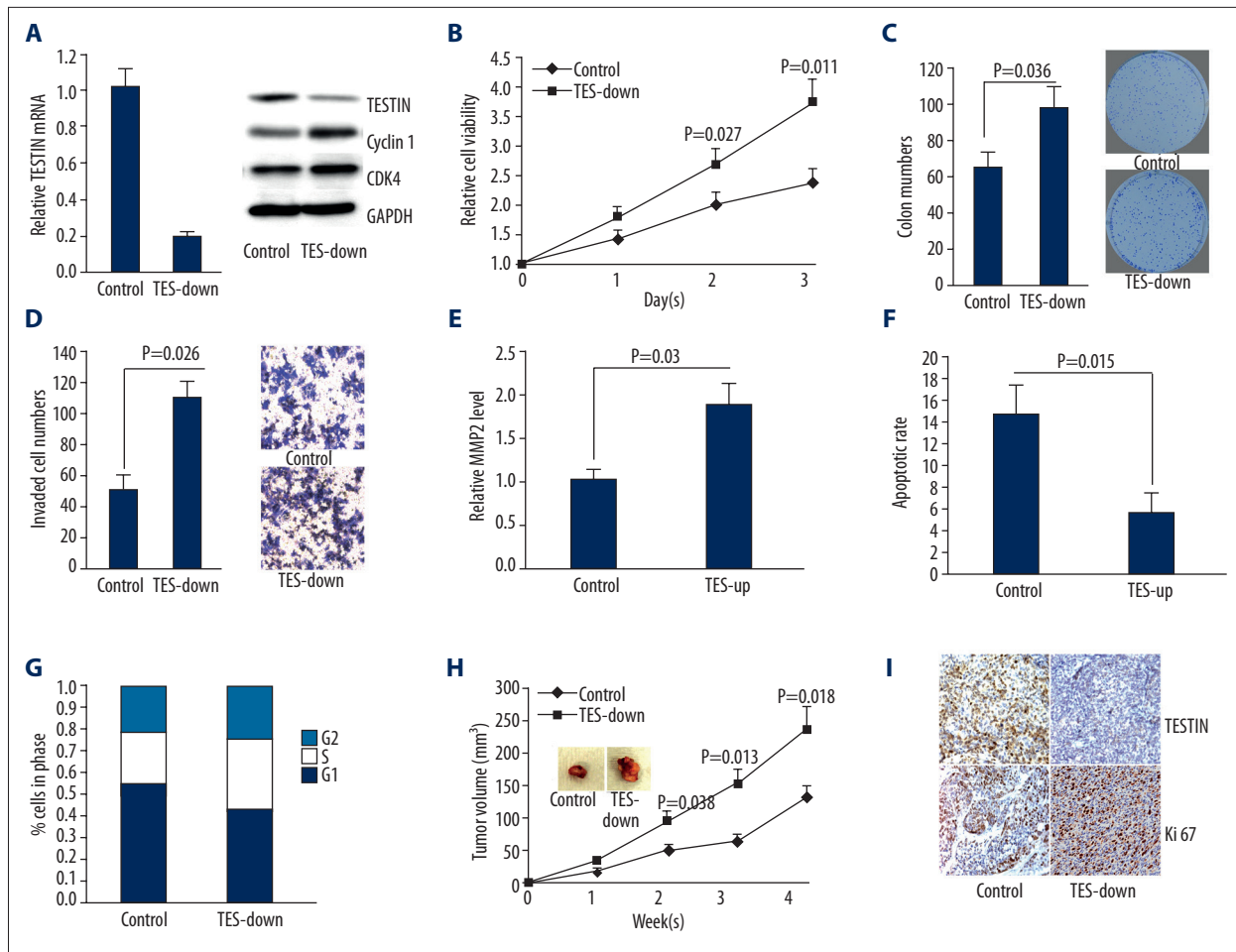
As shown in Table 1, loss of TESTIN protein was correlated with advanced tumor stage (P=0.047), high grade (P=0.034), and lymphatic vascular space invasion (P=0.036). There was no relation between TESTIN protein expression and patient

age, pathologic subtype, myometrial invasion, or lymphatic metastasis.

Among the 5 endometrial cancer cell lines, AN3CA had the lowest and Ishikawa showed the highest mRNA expression of TESTIN (Figure 1E).

Overexpression of TESTIN inhibited cellular proliferation and invasion in AN3CA cells.

We successfully overexpressed both mRNA and protein of TESTIN in AN3CA cells (Figure 2A). Abundant TESTIN suppressed cell growth (P=0.012 and <0.001 on Day 2 and Day 3, Figure 2B) and colony-forming ability (P=0.008, Figure 2C); overexpression of TESTIN also inhibited cellular invasion (P=0.032, Figure 2D) through blocking the secretion of MMP2 (P=0.02,



**Figure 3.** The affects of TESTIN knockdown on Ishikawa cells: **(A)** both mRNA and protein of TESTIN were downregulated in Ishikawa cells by transfection with shRNA-TESTIN; **(B and C)** loss of TESTIN enhanced cellular growth and colony formation ( $P=0.027$  and  $0.011$  on Day 2 and Day 3 in MTT assay, and  $P=0.036$  in colony formation assay); **(D and E)** loss of TESTIN promoted cellular invasion through upregulating the secretion of MMP2 ( $P=0.026$  in Transwell assay, and  $P=0.03$  for MMP2 alterations); **(F and G)** loss of TESTIN reduced cellular apoptosis and released many more cells into S phase ( $P=0.015$  and  $P=0.009$ , respectively); **(H)** loss of TESTIN notably accelerated the xenograft growth ( $P=0.038$ ,  $0.013$ ,  $0.018$  for the 2<sup>nd</sup>, 3<sup>rd</sup> and 4<sup>th</sup> week, respectively); **(I)** the expression of Ki 67 was upregulated by loss of TESTIN.

Figure 2E). Moreover, TESTIN significantly induced apoptosis ( $P=0.016$ , Figure 2F) and G1 phase arrest ( $P=0.002$ , Figure 2F), accompanied with decreased level of cyclin D1 and CDK4 (Figure 2B). In the xenografts growth assay, TESTIN significantly decelerated tumor growth ( $P=0.035$ ,  $0.018$ ,  $0.01$  for the 2<sup>nd</sup>, 3<sup>rd</sup>, and 4<sup>th</sup> week, Figure 2F). The proliferative marker (Ki 67) was also impaired by TESTIN (Figure 2G).

Knockdown of TESTIN promoted cellular proliferation and invasion in Ishikawa cells.

As shown in Figure 3A, both mRNA and protein of TESTIN were notably decreased in Ishikawa cells. With loss of TESTIN, Ishikawa cells presented upregulated cellular growth ( $P=0.027$  and  $0.011$  on Day 2 and Day 3, Figure 3B) and colony forming ( $P=0.036$ , Figure 3C). In Transwell assay, many more Ishikawa

cells invaded into the lower chamber ( $P=0.026$ , Figure 3D), with elevated secretion of MMP2 ( $P=0.03$ , Figure 3E). Loss of TESTIN also dramatically reduced apoptosis ( $P=0.015$ , Figure 3F), and a large number of Ishikawa cells were released into S phase ( $P=0.009$ , Figure 3G). Consistently, loss of TESTIN upregulated the protein of cyclin D1 and CDK4 (Figure 3B). *In vivo*, tumor growth was significantly promoted in the shRNA-TESTIN group ( $P=0.038$ ,  $0.013$ , and  $0.018$  for the 2<sup>nd</sup>, 3<sup>rd</sup> and 4<sup>th</sup> week, respectively, Figure 3H). The expression of Ki 67 was also upregulated as the result of TESTIN loss (Figure 3I).

## Discussion

Endometrial carcinoma was commonly confined in the endometrium and most tumors could be removed by hysterectomy

[27,28]. Unfortunately, more than one-fifth of patients presented identifiable regional or distant metastases, which would ultimately recur within the first 2–3 years after initial treatments [29,30]. Therefore, better understanding of the molecular mechanisms of endometrial carcinoma is needed to improve diagnosis and treatment. During recent decades, advances in the understanding of the molecular subtypes of endometrial cancer have underpinned the first step [4,31–33]. Recently, TESTIN was reported to be deeply involved in 2 sex hormone-associated cancers: prostate cancer (androgen-dependent) and breast cancer (estrogen-dependent) [21,24]. Thus, we hypothesized TESTIN might play a key role in endometrial carcinoma, which is a malignance highly dependent on unopposed estrogen exposure.

In the present study, using both *in vitro* and *in vivo* models, we elucidated the detailed functions of TESTIN gene on the proliferation, invasion, and cell cycle manipulation in endometrial carcinoma. First of all, we detected that TESTIN protein was commonly silenced in endometrial carcinoma samples, while the non-malignant adjacent endometrium presented normal expression of TESTIN. In addition, loss of TESTIN was associated with late tumor stage, advanced histological grade, and lymphatic vascular space invasion. These results are similar to those in other human cancers [17,21].

Next, we found that TESTIN could significantly suppress cell proliferation and the xenografts growth, through inhibiting cell cycle progression (G1 phase arrest); whereas loss of TESTIN accelerated the growth of Ishikawa cells and the xenografts through promoting cell cycle progression. We also found that TESTIN could induce notable apoptosis in AN3CA cells, and loss of TESTIN reduced apoptosis in Ishikawa cells. This is consistent with previously studies of ovarian and breast cancer,

in which TESTIN was proved to induce apoptosis in both caspase-dependent and caspase-independent manner [23,26].

Moreover, we detected dramatic impacts of TESTIN on cellular invasion in Tranwell assay; abundant TESTIN prohibited AN3CA cells from invading to the bottom chamber, while loss of TESTIN enhanced the invasion of Ishikawa cells. According to a breast cancer study, TESTIN can inhibit tumor invasion through down-regulating the miR-29-MMP2 axis [21]. Therefore, we investigated the effects of TESTIN on the secretion of MMP2. Similarly, the MMP2 level was significantly suppressed by TESTIN overexpression and promoted when TESTIN was silenced. However, we did not detect notable alterations of miR-29 (data not shown), and we hypothesized another pathway between TESTIN and MMP2 might exist, which will be further investigated in our next project.

## Conclusions

The expression of TESTIN was notably silenced in endometrial carcinoma tissues but did not match the expression in normal endometrium, and loss of TESTIN was significantly associated with poor prognostic markers like late tumor stage, advanced histological grade, and lymphatic vascular space invasion. Moreover, in *in vitro* and *in vivo* experiments, we demonstrated that TESTIN played a significant role in the inhibition of tumor growth (via arresting cell cycle progression) and invasion (via inhibiting the MMP2 secretion). Therefore, we propose that TESTIN might be a prognostic marker and therapeutic target for endometrial carcinoma.

## Conflicts of interest

None.

## References:

- Jemal A, Bray F, Center MM et al: Global cancer statistics. *CA Cancer J Clin*, 2011; 61: 69–90
- Siegel R, Naishadham D, Jemal A: Cancer statistics, 2013. *CA Cancer J Clin*, 2013; 63: 11–30
- Saso S, Chatterjee J, Georgiou E et al: Endometrial cancer. *BMJ*, 2011; 343: d3954
- Thanappapasr D, Thanappapasr K: Molecular therapy as a future strategy in endometrial cancer. *Asian Pac J Cancer Prev*, 2013; 14: 3419–23
- Wright JD, Barrena Medel NI, Sehoul J et al: Contemporary management of endometrial cancer. *Lancet*, 2012; 379: 1352–60
- Del Carmen MG, Boruta DM II, Schorge JO: Recurrent endometrial cancer. *Clin Obstet Gynecol*, 2011; 54: 266–77
- Farnebo M, Bykov VJ, Wiman KG: The p53 tumor suppressor: a master regulator of diverse cellular processes and therapeutic target in cancer. *Biochem Biophys Res Commun*, 2010; 396: 85–89
- Maehama T: PTEN: its deregulation and tumorigenesis. *Biol Pharm Bull*, 2007; 30: 1624–27
- Qiu H, Yan Q, Luo X et al: EMX2 is Downregulated in Endometrial Cancer and Correlated With Tumor Progression. *Int J Gynecol Pathol*, 2013; 32: 193–98
- Moreno-Bueno G, Hardisson D, Sanchez C et al: Abnormalities of the APC/beta-catenin pathway in endometrial cancer. *Oncogene*, 2002; 21: 7981–90
- Salvesen HB, Das S, Akslen LA: Loss of nuclear p16 protein expression is not associated with promoter methylation but defines a subgroup of aggressive endometrial carcinomas with poor prognosis. *Clin Cancer Res*, 2000; 6: 153–59
- Shu XS, Li L, Tao Q: Chromatin regulators with tumor suppressor properties and their alterations in human cancers. *Epigenomics*, 2012; 4: 537–49
- Yamada Y, Kamihira S: Inactivation of tumor suppressor genes and the progression of adult T-cell leukemia-lymphoma. *Leuk Lymphoma*, 2005; 46: 1553–59
- Simpson L, Parsons R: PTEN: life as a tumor suppressor. *Exp Cell Res*, 2001; 264: 29–41
- Soussi T: The p53 tumor suppressor gene: from molecular biology to clinical investigation. *Ann NY Acad Sci*, 2000; 910: 121–37; discussion 137–39
- Hussain SP, Hollstein MH, Harris CC: p53 tumor suppressor gene: at the crossroads of molecular carcinogenesis, molecular epidemiology, and human risk assessment. *Ann NY Acad Sci*, 2000; 919: 79–85
- Drusco A, Zanesi N, Roldo C et al: Knockout mice reveal a tumor suppressor function for Testin. *Proc Natl Acad Sci USA*, 2005; 102: 10947–51

18. Tatarelli C, Linnenbach A, Mimori K, Croce CM: Characterization of the human TESTIN gene localized in the FRA7G region at 7q31.2. *Genomics*, 2000; 68: 1–12
19. Tobias ES, Hurlstone AF, MacKenzie E et al: The TES gene at 7q31.1 is methylated in tumours and encodes a novel growth-suppressing LIM domain protein. *Oncogene*, 2001; 20: 2844–53
20. Coutts AS, MacKenzie E, Griffith E, Black DM: TES is a novel focal adhesion protein with a role in cell spreading. *J Cell Sci*, 2003; 116: 897–906
21. Zhu J, Li X, Kong X et al: Testin is a tumor suppressor and prognostic marker in breast cancer. *Cancer Sci*, 2012;103: 2092–101
22. Fang JH, Zhou HC, Zeng C et al: MicroRNA-29b suppresses tumor angiogenesis, invasion, and metastasis by regulating matrix metalloproteinase 2 expression. *Hepatology*, 2011; 54: 1729–40
23. Sarti M, Sevigani C, Calin GA et al: Adenoviral transduction of TESTIN gene into breast and uterine cancer cell lines promotes apoptosis and tumor reduction *in vivo*. *Clin Cancer Res*, 2005; 11: 806–13
24. Chene L, Giroud C, Desgrandchamps F et al: Extensive analysis of the 7q31 region in human prostate tumors supports TES as the best candidate tumor suppressor gene. *Int J Cancer*, 2004; 111: 798–804
25. Mueller W, Nutt CL, Ehrich M et al: Downregulation of RUNX3 and TES by hypermethylation in glioblastoma. *Oncogene*, 2007; 26: 583–93
26. Qiu H, Zhu J, Yuan C et al: Frequent hypermethylation and loss of heterozygosity of the testis derived transcript gene in ovarian cancer. *Cancer Sci*, 2010; 101: 1255–60
27. Hill EK, Dizon DS: Medical therapy of endometrial cancer: current status and promising novel treatments. *Drugs*, 2012; 72: 705–13
28. Ulrich LS: Endometrial cancer, types, prognosis, female hormones and anti-hormones. *Climacteric*, 2011; 14: 418–25
29. Jamison PM, Noone AM, Ries LA et al: Trends in endometrial cancer incidence by race and histology with a correction for the prevalence of hysterectomy, SEER 1992 to 2008. *Cancer Epidemiol Biomarkers Prev*, 2013; 22: 233–41
30. Amant F, Moerman P, Neven P et al: Endometrial cancer. *Lancet*, 2005; 366: 491–505
31. Hecht JL, Mutter GL: Molecular and pathologic aspects of endometrial carcinogenesis. *J Clin Oncol*, 2006; 24: 4783–91
32. Weigelt B, Banerjee S: Molecular targets and targeted therapeutics in endometrial cancer. *Curr Opin Oncol*, 2012; 24: 554–63
33. Kandath C, Schultz N, Cherniack AD et al: Integrated genomic characterization of endometrial carcinoma. *Nature*, 2013; 497: 67–73