



Case report

Metastatic Pulmonary Epithelioid Hemangioendothelioma: A case report and review of the literature

Sidharth Rishi Mehta^{a,*}, Arvind Das^b, Nicola Barnard^c, Alan Marcus^c^a Graduate School of Biomedical Sciences, UMDNJ-Robert Wood Johnson Medical School, 675 Hoes Lane, Piscataway, NJ 08854, United States^b Graduate School of Medicine, UMDNJ-Robert Wood Johnson Medical School, 675 Hoes Lane, Piscataway, NJ 08854, United States^c Graduate School of Pathology, UMDNJ-Robert Wood Johnson Medical School, 675 Hoes Lane, Piscataway, NJ 08854, United States

ARTICLE INFO

Article history:

Received 5 June 2012

Received in revised form

26 September 2012

Accepted 27 September 2012

Keywords:

PEH – Pulmonary Epithelioid

Hemangioendothelioma

CT – Cat Scan

PET – Positron Emission Tomography

EHE – Epithelioid Hemangioendothelioma

IVBAT – Intravascular Bronchiolo-Alveolar

Tumor

ABSTRACT

Pulmonary Epithelioid Hemangioendothelioma is a rare and low grade tumor of endothelial origin found in the lungs. At onset patients are usually asymptomatic or present with non-specific symptoms. Chest imaging shows the presence of multiple, bilateral small nodules and diagnosis usually requires a lung biopsy. At this time there is no standardized treatment regimen and the prognosis is variable.

© 2012 Elsevier Ltd. Open access under [CC BY-NC-ND license](http://creativecommons.org/licenses/by-nc-nd/4.0/).

Our patient is a 65-year-old male that presented to the emergency room with constant left sided anterior chest pain for the previous five days. Prior to his presentation he was asymptomatic and in the process of recovering from surgery on his trigger finger. He has degenerative disk disease of the lumbar spine, well controlled diabetes, hypercholesterolemia, and hypertension. The patient has a 20-pack-year smoking history and quit 32 years ago. On physical examination, there was localized tenderness in the area where the patient reported chest pain and the lung examination was normal. A CT angiogram ruled out a pulmonary embolism but did reveal multiple, well defined, and irregularly shaped, bilateral nodules. The largest of the nodules in the right lower lobe measured 2 cm in size. The CT scan also revealed a possible lytic lesion in the left second rib, and a sclerotic lesion located on the posterior portion of the 10th rib. A fine needle aspirate of the right lower lobe lesion as well as that of the left second rib were non-diagnostic, but did reveal atypical cells. A CT scan of the abdomen and pelvis showed no abnormalities and a FDG-PET scan showed faint tracer uptake in one of the right lower lobe nodules. This

nodule had an SUV of 3.5 and the background demonstrated an SUV of 2.7. The left second rib demonstrated an increased hyper metabolic activity of SUV of 14. The patient underwent a VATS lung biopsy with wedge resection of the nodule in the right lower lobe. The wedge resection contained multiple firm white nodules. One nodule measured 1 × 0.6 × 0.5 cm, a second nodule measured 0.6 × 0.3 × 0.2 cm and additional smaller nodules measured up to 0.2 cm in diameter. Microscopic examination revealed multiple nodular areas of eosinophilic material containing cells with small uniform nuclei. Some of these cells had prominent intracytoplasmic vacuoles. These cells stained positive with immunohistochemical markers for endothelial cells, CD31 and CD34, supporting the diagnosis of Epithelioid Hemangioendothelioma (EHE) (Figs. 1–4).

EHE is a rare vascular tumor of intermediate behavior that was first described by Weiss in 1982 as an Intravascular Broncho-Alveolar Tumor (IVBAT).¹⁷ Pulmonary Epithelioid Hemangioendothelioma (PEH) is a rare, low grade tumor of endothelial origin^{17,6} and can be found in many organ systems including the lungs, liver, bone, soft tissue and can be found sequentially, or simultaneously.⁵ When this occurs it can be hard to determine if the tumor is multicentric or a primary tumor with metastases to other tissues.⁵ PEH is initially recognized on a chest radiograph or CT scan with the presence of unilateral or bilateral nodules which range in

* Corresponding author. Tel.: +1 7322596728.

E-mail addresses: Mehtasr@umdnj.edu, sidharthmehta@gmail.com (S.R. Mehta).

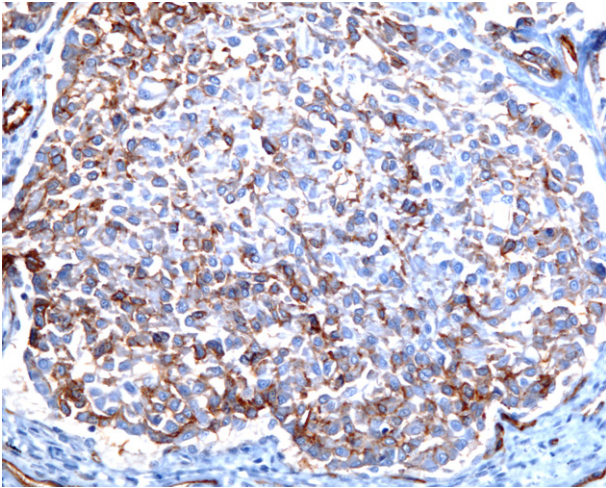


Fig. 1. CD-31 stain at 200× magnification.

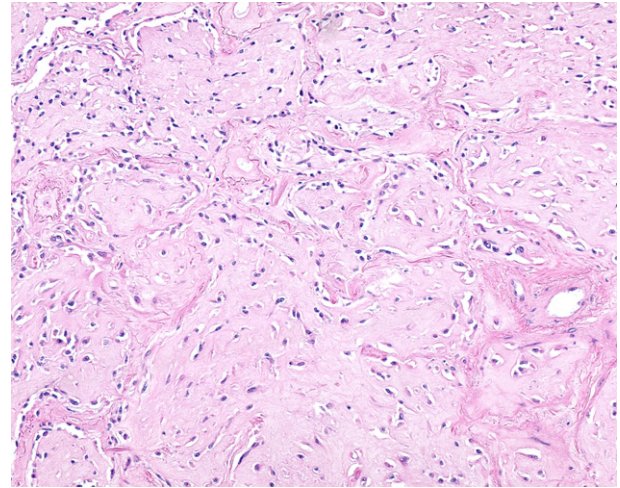


Fig. 3. Hematoxylin and eosin at 200× magnification.

size up to 2 cm^{3,10} and are usually found near medium sized vessels. The problem with this radiological presentation is that it is non-specific. Many physicians would consider a PET scan an important tool used to rule out malignant lung diseases; However, in our patient, only one nodule showed FDG uptake and a negative PET scan in PEH patients is not unheard of.⁴ There are two possible explanations that attempt to relate the malignancy of a nodule to the FDG uptake. The first is that a larger nodule may show a higher FDG uptake, but the PET scan can fail to detect nodules smaller than 6 mm in diameter. Secondly, a greater FDG uptake can represent a more clinically malignant potential and the lack of tracer uptake can be evidence of a more benign character.

The diagnosis of PEH is made on the basis of histopathological features which are confirmed using immunohistochemical staining. CD34, CD31 and Factor VIII are the well-recognized endothelial cell markers although a new marker, Nuclear Fli-1, a protein that is expressed in endothelial cells as well as in T-cells and megakaryocytes, is being considered for use as a marker for PEH. Gill et al. found that Nuclear Fli-1 was detected in 100 percent of their EHE cases and found that FLI-1, CD34 and CD31 were the markers most sensitive for EHE. It was also found that FLI-1 immuno-staining demonstrated better sensitivity than CD34 and better specificity than CD31.⁷ PEH is closely associated with arterioles, venules, and

lymphatic vessels and often display an intra-alveolar growth pattern.^{17,18} EHE and subsequently PEH demonstrates reactivity for factor VIII-related antigen (99%), CD31 (86%), and CD34 (94%).¹⁸ Calcification is commonly seen on the histology, but radiological calcification is quite rare⁸ and PEH does not show necrosis, cytological atypia or a high mitotic index.¹³ Cellular pleomorphism, mitotic activity, necrosis and extensive cellular spindling are cytologic features that predict aggressive behavior. Unfortunately there is no clear definition of malignant EHE or malignant PEH. PEH is known to have biological behavior intermediate between a hemangioma and a conventional angiosarcoma.

Pulmonary involvement is relatively rare with pulmonary EHE being approximately 19% of all EHE cases.¹⁰ Other commonly involved organ systems are the liver and bone with multi-organ involvement quite common in EHE. Multi-organ involvement of both the bone and lung is even rarer at 10% of all multi-organ involvement with the most common being liver and bone involvement.¹⁰ In a study of 93 patients distant metastasis was confirmed in 47 patients.² The most common was hepatic metastasis (22.6%) followed by pleural metastasis (20.4%) and lymph node metastasis (10.8%).²

The diagnosis of EHE is often incidental (Table 1) as a majority of patients are usually asymptomatic or have minor symptoms. Our

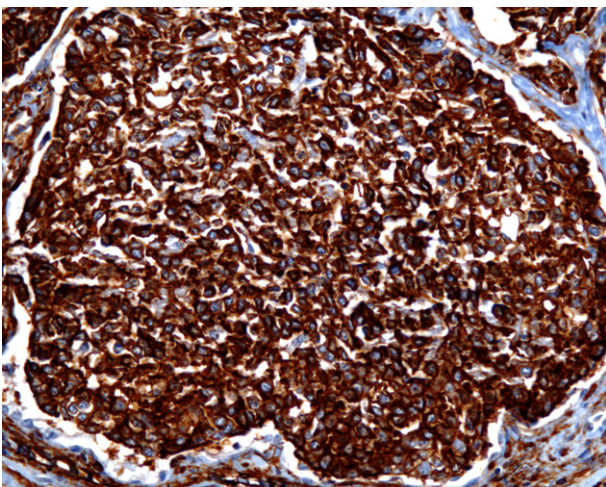


Fig. 2. CD-34 stain at 200× magnification.

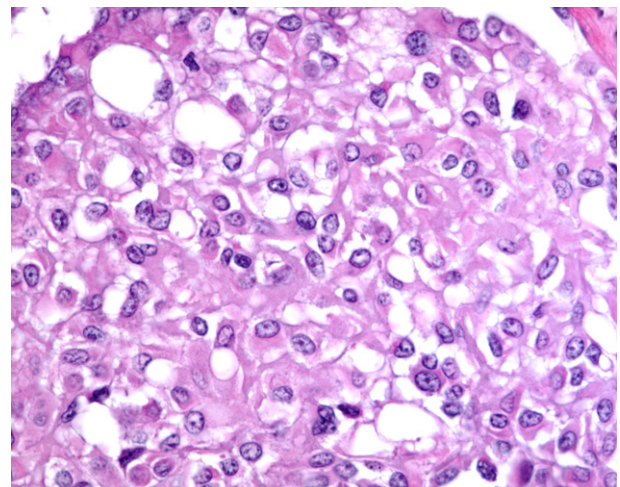


Fig. 4. Hematoxylin and eosin at 400× magnification.

Table 1
Review of the clinical, pathological and radiological features of published cases and reviews of PEH.

Name of study/ Authors	Female/Male	Age	Symptoms	Radiography	PET	Metastasis	Immuno features
Our case	Male	66	Chest pain & left anterior rib pain	Multiple bilateral	Pos 1 nodule	None	CD31, CD34
Amin case report	Female	70	Non-related	Unilateral single nodule	Not performed	Lymph node and pleural	VIII, CD34
Amin lit review (n = 93)	Female/Male (73%/27%)	40.1	Symptomatic/Asymptomatic (50.5%/49.5%)	Unilateral/Bilateral (12.2%/78.9%)	Not measured	Distant/Hepatic/Pleural/ Lymph (50.5%/22.6%/20.4%/ 10.8%)	Factor VIII, CD31, CD34, vimentin
Bagan (n = 80)	Female/Male (63.8%/36.2%)	39.4	Symptomatic/Asymptomatic (42.%/48.7%)	Unilateral/Bilateral (23.7%/76.2%)	No	38 70%	VIII, CD 31, CD34
Cazzuffi case	Male	67	Dyspnea and cough	Multiple bilateral	Negative	Spleen and liver	Factor VIII, CD31, Cd34
Cazzuffi data	3:1 Ratio	40.1	Weight loss, fatigue, and respiratory symptom	Multiple bilateral	Positive%??	Lymph, liver, bone	Factor VIII, CD31, Cd34
Cronin	Female	35		Multiple bilateral	None	No	Factor VIII, CD31, CD34
Jinghong	Female	20	No complaints	Multiple Bilateral	Not performed	No	Factor VIII, CD 31, CD34
Joo Lee	Female	31	Upper back, and bilateral shoulder pain	Unilateral and vertebral bodies	Bone scan	Multiple bone metastasis	a-sma, Vimentin, weak for CD34
Mhoyan	Female	25	Chest pain, generalized weakness	Multiple bilateral	Not performed	No	Factor VIII, CD 31, CD34
Okamura	Female	19	None	Multiple bilateral	Pos 1 nodule	None	Factor VIII, CD34
Shraim	Male	51	Dry cough, SOB exertion,	Multiple pleural	Not performed	Skin, anterior ab wall	Factor VIII, CD 31, CD34
Tochigi	Woman	5th Decade	None	Unilateral multiple	Not performed	No	Vimentin, CD31, FLI-1, CD34

patient was relatively asymptomatic except for the reported anterior rib pain. Given the rarity of this tumor, the demographic information is quite variable. Previous reports have suggested that EHE is often found in women in ratio's ranging from 3:1 female to male ratio to a 2:1 female to male involvement. Patients age in range from 19 to 70 years, with an average onset in the 4th decade. Patients have been reported to live for up to 20 years^{5,8} with no changes in tumor size or aggressiveness. There is even a report of a patient surviving 10 years without any treatment.¹⁴

Pulmonary involvement of EHE can be quite variable in its prognosis and the suggested risk factors have been quite variable. When PEH was first reported as IVBAT by Dial et al. in 1983, they observed that the poor prognostic factors were the presence of respiratory symptoms at presentation, lymphatic spread, pleural invasion, extensive intravascular spread, and hepatic metastases. Further research by Kitaichi et al., found that pleural effusion and spindle tumor cells were unfavorable prognostic factors. A medline literature review by Bagan et al. found that pleural effusion, significant loss of weight, and anemia were factors of a poor prognosis. When analyzing the long term survival of PEH patients, Bagan et al. discovered that patients could be placed into two categories: asymptomatic patients with nodules (median survival of 15 years) and patients with symptoms of vascular endothelial cell proliferation. The 5-year survival of patients with pleural effusion was 2% whereas survival of the population without effusion was 73%.³ The 5-year survival rate was at one point reported to be between 47 and 71% but an examination of an internet based EHE registry by Lau et al. found the 1 year survival rate to be 90% and 73% at 5 years. In Amin's review of 93 patients, they were able to reveal that male, symptomatic patients, pleural effusion, metastases and lymph node metastases were significant risk factors. The study of the online registry by Lau et al. found that the only significant risk factors were male sex, diagnosis in middle age, uncontained spread, and involvement of three or more bones all correlated with poor survival.

Various therapeutic modalities have been used in attempts to either stop or slow the progression of PEH. Because of the rarity of this condition there is no standard of agreed upon treatment. In patients with a unilateral nodule a surgical resection is possible.⁹ In situations of surgical resection as a form of treatment, use of a PET scan allows one to resect aggressive PEH nodules.¹⁶ Patients with lymph node metastases have undergone a surgical resection but due to the low

number of patients, the prognostic value remains unclear.¹⁵ The use of various chemotherapies has been reported for metastatic or unresectable PEH, but with variable effectiveness.¹² The use of interferon-2a found that pulmonary lesions regressed slightly and some beneficial results have been obtained with the use of bevacizumab. Other proposed treatments include azathioprine,^{1,4,11} thalidomide and multiple wedge resection. It is interesting to note that corticosteroids have been suggested as a possible form of treatment^{3,4} because the neoplastic cells express glucocorticoid receptors. For patients with diffuse PEH it has been suggested that hormonal therapy could be used if the neoplastic cells express estrogen or progesterone receptors. Although no cases have been reported to be positive for ER- α or PR, there is a single report of a patient testing positive for ER-B.² Lau et al.' study of the online registry found that 26% of patients chose medical treatments and 22% chose to simply wait and observe the disease. However, all of these treatment options represent single case reports or an analysis of a cohort of single case reports and lack convincing evidence of benefit.

Author contribution

Sidharth R. Mehta – Graduate Assistant and First Author.
Dr. Arvind Das – Managing Pulmonologist and Second Author.
Dr. Barnard – Anatomic Pathologist and Reviewer/Author.
Dr. Marcus – Pathology Resident and Reviewer/Author.

Conflict of interest statement

All authors confirm that there have been no financial incentives provided to report on this case, nor do they have any financial bias.

References

- Al-Shraim M, Mahboub B, Neligan PC, Chamberlain D, Ghazarian D. Primary pleural epithelioid haemangioendothelioma with metastases to the skin. A case report and literature review. *J Clin Pathol* 2005;**58**:107–9.
- Amin R, Hiroshima K, Kokubo T, et al. Risk factors and independent predictors of survival in patients with pulmonary epithelioid haemangioendothelioma. Review of the literature and case report. *Respirology* 2006;**11**:818–25.
- Bagan P, Hassan M, Barthes F, et al. Prognostic factors and surgical indications of pulmonary epithelioid hemangioendothelioma: a review of the literature. *Ann Thorac Surg* 2006;**82**:2010–3.

4. Cazzuffi R, Calia N, Ravenna F, et al. Primary pulmonary epithelioid hemangioendothelioma: a rare cause of PET-negative pulmonary nodules. *Case Rep Med* 2011.
5. Cronin P, Arenberg D. Pulmonary epithelioid hemangioendothelioma: an unusual case and a review of the literature. *Chest* 2004;**125**:789–92.
6. Dalil DH, Liebow AA, Gmelich JT, et al. Intravascular, bronchiolar, and alveolar tumor of the lung (IVBAT): an analysis of twenty cases of a peculiar sclerosing endothelial tumor. *Cancer* 1983;**51**:452–64.
7. Gill R, O'Donnell R, Horvai A. Utility of immunohistochemistry for endothelial markers in distinguishing epithelioid hemangioendothelioma from carcinoma metastatic to bone. *Arch Pathol Lab Med* 2009;**133**:967–72.
8. Jinghon X, Lirong C. Pulmonary epithelioid hemangioendothelioma accompanied by bilateral multiple calcified nodules in lung. *Diagn Pathol* 2011;**6**:21.
9. Kitaichi M, Nagai S, Nishimura K, et al. Pulmonary epithelioid haemangioendothelioma in 21 patients, including three with partial spontaneous regression. *Eur Respir J* 1998;**12**:89–96.
10. Lau K, Massad M, Pollack C, et al. Clinical patterns and outcome in epithelioid hemangioendothelioma with or without pulmonary involvement: insights from an internet registry in the study of a rare cancer. *Chest* 2011;**140**:1312–8.
11. Ledson MJ, Convery R, Carty A, Evans CC. Epithelioid hemangioendothelioma. *Thorax* 1999;**54**:560–1.
12. Lee YJ, Chung MJ, Jeong KC, et al. Pleural epithelioid hemangioendothelioma. *Yonsei Med J* 2008;**6**:1036–40.
13. Mhoyan A, Weidner N, Shabaik A. Epithelioid hemangioendothelioma of the lung diagnosed by transesophageal endoscopic ultrasound-guided fine needle aspiration. *Acta Cytol* 2004;**4**:555–9.
14. Roudier-Pujol C, Enjolras O, Lacronique J, et al. Multifocal epithelioid hemangioendothelioma with partial remission after interferon alfa-2a treatment. *Ann Dermatol Venereol* 1994;**121**:898–904.
15. Tochigi N, Tsuta K, Maeshima AM, et al. Malignant pulmonary epithelioid hemangioendothelioma with hilar lymph node metastasis. *Ann Diagn Pathol* 2011;**15**:207–12.
16. Watanabe S, Yano F, Kita T, et al. F-FDG-PET/CT as an indicator for resection of pulmonary epithelioid hemangioendothelioma. *Ann Nucl Med* 2008;**22**:521–4.
17. Weiss SW, Enzinger FM. Epithelioid hemangioendothelioma: a vascular tumor often mistaken for a carcinoma. *Cancer* 1982;**50**:970–81.
18. Weissferdt A, Moran C. Primary vascular tumors of the lungs: a review. *Ann Diagn Pathol* 2010;**14**:296–308.