

The diagnosis and management of giant cell lesions of the jaws

Access this article online

Website:
www.amsjournal.com

DOI:
10.4103/2231-0746.101325

Quick Response Code:



Anthony M. Pogrel

Department of Oral and Maxillofacial Surgery, University of California San Francisco, San Francisco, CA, USA

Address for correspondence:

Prof. M. A. Pogrel, Department of Oral and Maxillofacial Surgery, University of California San Francisco, 521 Parnassus Ave., Box - 0440, Room C522, San Francisco, CA - 94143-0440, USA.
E-mail: tony.pogrel@ucsf.edu

ABSTRACT

This article will review current thoughts with regard to the etiology, histopathology, diagnosis, and management of giant cell lesions of the jaws. It will attempt to point out the differences between these lesions and giant cell lesions elsewhere in the body and also the current techniques for medical management of these conditions including steroid injections, calcitonin treatment, and alpha interferon treatment.

Keywords: Alpha interferon treatment, craniofacial lesions, giant cell lesions

INTRODUCTION

Giant cell lesions of the jaws were separated out from other jaw lesions by Jaffe in 1953^[1] when they were termed “giant cell reparative granulomas.” The concept at that time was that these lesions only seemed to occur in the jaws, they were found in the first two decades of life, more frequently in females (approximately 2:1), and were believed to be related to the teeth in some way, though they were not truly thought to be an odontogenic lesion. One idea at that time was that the giant cells involved in the lesion may have been derived from the odontoclasts, which led to resorption of the deciduous teeth. This might explain why they were found in a certain age group and generally found in areas of the jaws that had previously held deciduous teeth.

It still remains unclear whether this lesion occurs anywhere else in the body. A very similar lesion does occur in the hands and feet^[2] but its exact relationship is unknown. Although other lesions containing giant cells do occur in other bones of the body, they are much less frequent and are generally felt to be variants of other tumors, most often a low-grade osteosarcoma. Whether these other types of giant cell lesions also occur in the jaws has been hotly debated for many years, and is still undecided.

Initially it was believed that the jaw lesions were indeed reparative lesions and would resolve spontaneously,^[3,4] which is why they were not found in older patients. The origin for this idea is difficult to confirm, and there are few reports in the literature of these lesions actually resolving. Worth in the last edition of his radiology textbook in 1981^[5] does describe a group of central giant cell granulomas, which were treated by diagnostic biopsy only and then followed radiographically, and the majority of them did indeed appear to resolve over a period of time. Occasional articles over the years do appear to have confirmed this, particularly after biopsy.^[6] We ourselves have seen the occasional lesion of this type resolve spontaneously, and this is shown in Figure 1 where a 23-year-old Caucasian female patient had biopsy only for this lesion and never had any definitive treatment carried out. The lesion resolved over an 18-month period. Whether resolution was stimulated by the biopsy is, of course, impossible to determine. At the present time, however, the overwhelming opinion is that these are not in fact self-healing lesions and will continue to increase in size without definitive treatment. It is even believed that a subgroup may be more aggressive than most and require more aggressive treatment^[7] extending as far as “en bloc” resection^[8] However, all attempts to diagnose the more aggressive type preoperatively have been unsuccessful.^[9-11] A soft tissue variant of this lesion known as a peripheral giant cell granuloma, or giant

cell epulis, is seen on the gingiva and is felt to represent a similar lesion [Figure 2], but is normally considered less aggressive and responds well to local excision.^[12]

Despite the fact that the majority of these lesions occur in young patients under the age of 20, there certainly is a percentage that occur in older patients, and in fact the oldest patient that we have seen with a central giant cell granuloma was a 94-year-old [Figure 3].

HISTOLOGICAL DIAGNOSIS

Diagnosis of central giant cell granuloma is normally made histologically from an incisional biopsy. The appearance is

generally distinctive with multinucleated giant cells spread throughout the lesion but often focal in distribution around areas of possible hemorrhage [Figure 4]. This is in contrast to the giant cell tumor of long bones, where the giant cells are more evenly distributed. There is generally a spindle cell matrix with possible areas of hemorrhage. The giant cells can have up to 30 nuclei fairly evenly distributed, unlike the giant cells of tuberculosis, which are arranged in a horseshoe shape. Interestingly enough, studies have shown that it may be the spindle cell, which is the active cell in this lesion,^[13] and the giant cells are osteoclasts.^[14] Similar histological appearances are seen in the following lesions, which must often be differentiated:

1. The brown tumor of hyperparathyroidism. If there is any doubt (with an aggressive lesion, a recurrent lesion, an atypical lesion or multiple lesions), hyperparathyroidism should be excluded with serum calcium and phosphate determination and in many cases also a parathormone assay.
2. The aneurysmal bone cyst. This lesion has more hemorrhage in it and also cystic areas, but many authorities agree that it actually represents a cystic variant of the central giant cell granuloma.

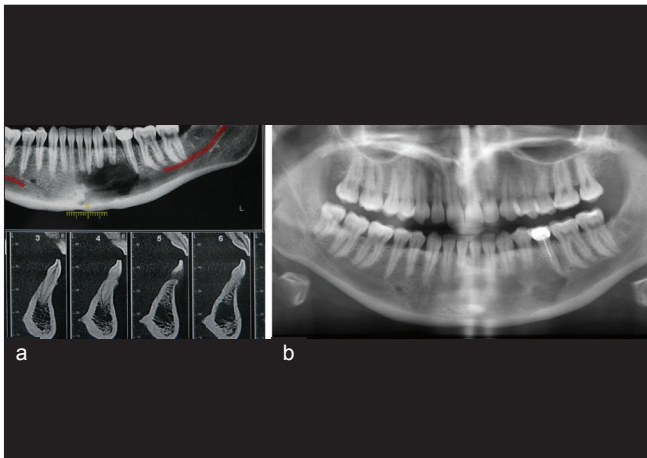


Figure 1: Radiographs of a biopsy-proven central giant cell granuloma of the left anterior mandible in a 23-year-old female (a) represents the lesion at the time of biopsy and (b) represents the lesion some 18 months later. No other surgical treatment than the biopsy was performed. Note that the lesion is almost completely resolved

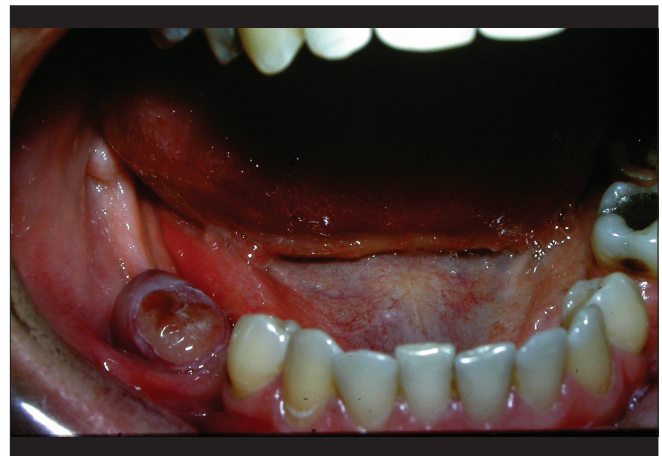


Figure 2: A peripheral giant cell granuloma or giant cell epulis on the ridge of the right mandible. The histological appearance is identical with the intrabony lesion

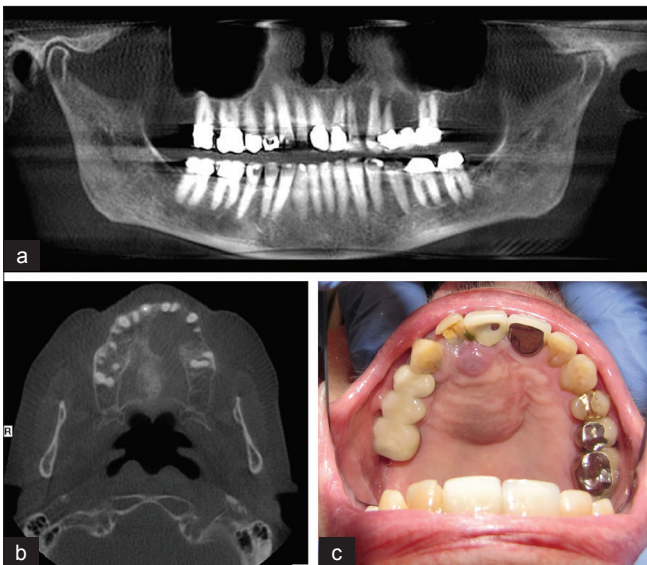


Figure 3: A radiograph of a central giant cell granuloma of the anterior maxilla in a 94-year-old male (a) Appearance on panorex radiograph. (b) Appearance on axial CT scan. (c) Clinical appearance. The lesion was locally enucleated

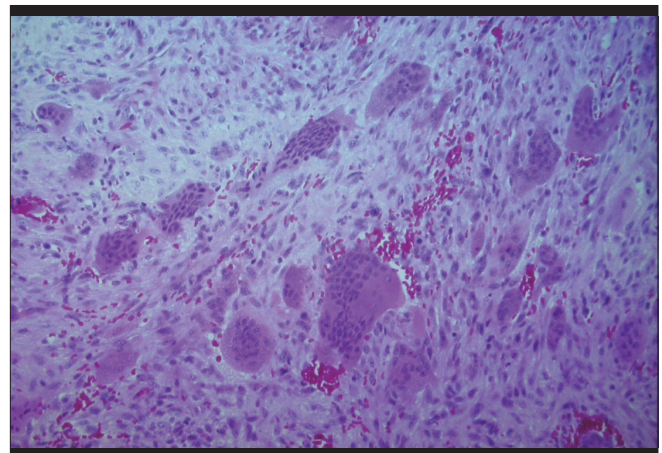


Figure 4: Typical histological appearance with focal distribution of giant cells in a benign spindle cell matrix

3. Cherubism. Although the histological appearance in cherubism is similar, the clinical history is different with multiple lesions, and a male:female ratio of 2:1. It is an autosomal dominant with higher penetrance in the male. Histologically there are also subtle differences from the central giant cell granuloma with fewer giant cells in cherubism and perivascular cuffing. Additionally, the genetic basis of cherubism has now been identified with a gene defect on chromosome 4p 16.3, which encodes the binding protein SH3 BP2,^[15-19] and a test for this is now becoming available.

MANAGEMENT OF THE CENTRAL GIANT CELL GRANULOMA

Conventional management is surgical and consists of enucleation and curettage. Despite this, a recurrence rate of 15-20% is often quoted, and in these cases treatment may need to be more aggressive and may need to consist of an “en bloc” resection.

However, because of the confusion regarding the etiology of this condition (whether it is a benign tumor, a reactive lesion, an inflammatory lesion or even a self-healing lesion), alternative medical treatments have been introduced over the last 15 years and are felt to have promise in some cases.

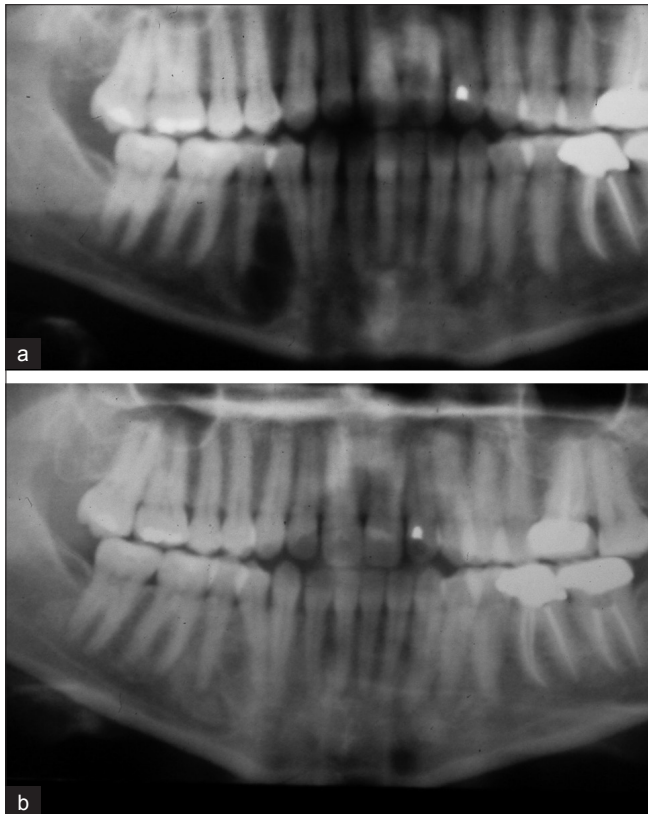


Figure 5: A unilocular central giant cell granuloma of the right mandible treated with a six-week course of intralesional steroids (a) shows the appearance prior to injection of the steroids and (b) shows the appearance some six months later showing a radiopacity rather than a radiolucency in the area of the lesion

Intralesional steroid injections

First described in 1988,^[20] the protocol that has been suggested is a 50/50 mixture of 2% lidocaine with 1:100,000 epinephrine with triamcinolone (Kenalog[®]) and to inject 2 ml/1 cm of lesion as seen on a Panorex X-ray and to repeat this six times at weekly intervals. Experience with this technique is limited, but it does appear to work more successfully in unilocular lesions than multilocular lesions, and this is probably because of the ease of access in a unilocular lesion, whereas in a multilocular lesion some areas may be missed. In the hands of those who use this technique on a regular basis, it appears that it is successful in around 50% of cases,^[21-23] but there is an appreciable failure rate. In some cases when the lesion heals, it actually ends up more radiopaque than the surrounding bony area as in Figure 5.

The rationale for steroid injections appears to be that histologically the lesion has a superficial resemblance to the lesions of sarcoid and, therefore, perhaps the same treatment as is given for sarcoid would work for this lesion. There is, however, no evidence that there is any relationship between the central giant cell granuloma

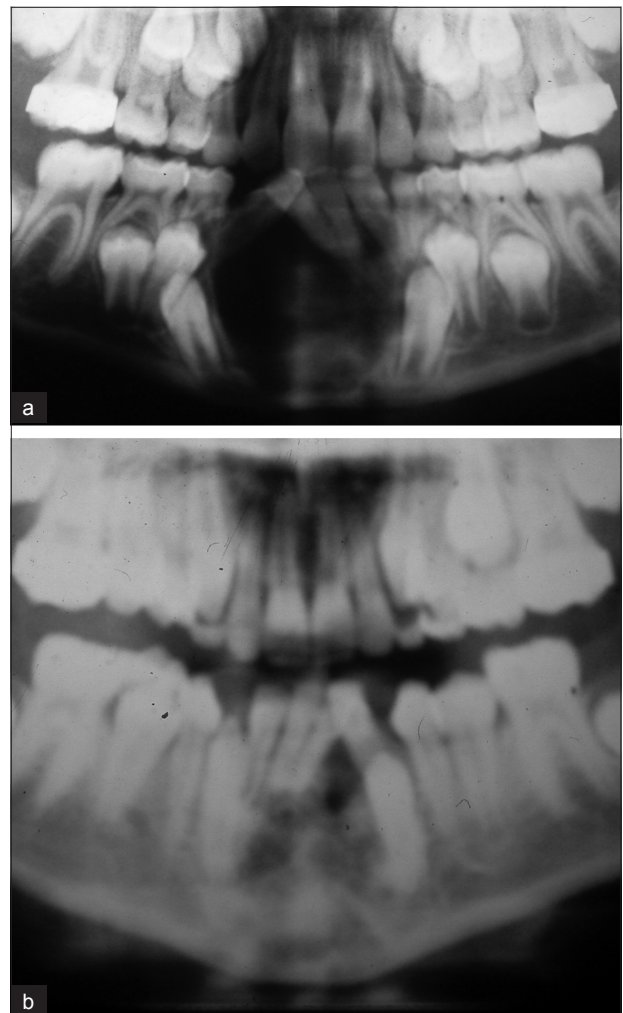


Figure 6: A central giant cell granuloma of the anterior mandible treated with subcutaneous calcitonin injections (a) shows the lesion prior to commencing calcitonin and (b) shows the lesions some 21 months later. Note the almost complete resolution of the lesion, the uprighting of the lower incisors, and the realignment of the lower canines

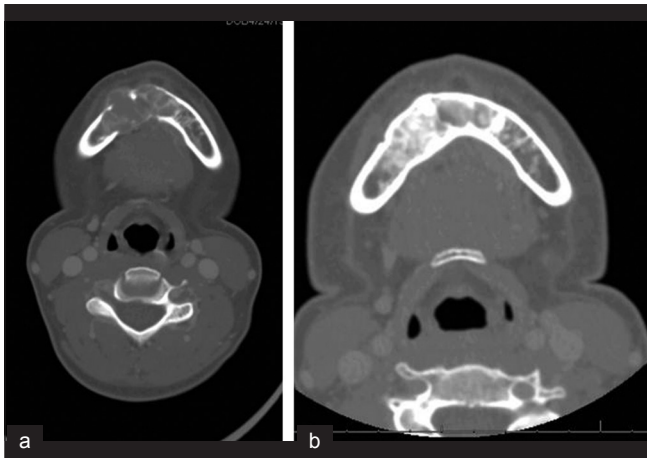


Figure 7: CT scan of a central giant cell granuloma of the anterior mandible (a) Prior to commencing calcitonin, and (b) after 18 months of subcutaneous calcitonin. Note the increased calcification (images courtesy of Mehran Hossaini DMD)

and sarcoid.

Calcitonin injections

The rationale behind injecting calcitonin in an attempt to cure a central giant cell granuloma originated with Professor Malcolm Harris from the Eastman Dental School in London in 1993.^[24] Because of the histological resemblance of the central giant cell granuloma with the brown tumor of hyperparathyroidism, he surmised that there may be an as yet unidentified parathormone-like hormone that could be the etiology of this lesion. This hormone or other factor, however, has never been identified. Nevertheless, calcitonin (the antagonist for parathormone) has been used in this condition with some success. The technique is to give a subcutaneous injection of 100 units of calcitonin daily and monitor the lesion radiographically. In some countries, human calcitonin is available and is preferable. In the United States only salmon calcitonin is available, and although it is more potent than human calcitonin, antibody formation can limit its effectiveness. Calcitonin is also available as a nasal spray, and studies have been published on its efficiency as a nasal spray,^[25] but the main problem is the variable absorption that occurs. Results from the use of calcitonin have shown fairly high success rates^[26-28] but also some failures have been reported.^[29] Radiographically, resolution does not normally commence until six to nine months of treatment, and treatment is continued for up to 24 months to see the maximum resolution [Figures 6 and 7]. Once further resolution is not occurring, the treatment can be terminated, and to date we have only noted one recurrence after termination. In this particular case, the patient was retreated with a second course of subcutaneous calcitonin and is now some 13 years after the initial treatment and still currently shows no signs of recurrence.

Treatment with alpha interferon

Based on the assumption that this lesion may be vascular in origin, subcutaneous alpha interferon has been used in the treatment of this lesion.^[30-32] It is given for its anti-angiogenic effects, though there is little evidence that the lesion is vascular in origin. The treatment has shown some success, but its use is limited by its side effects, which include headaches and a flu-like illness,

with a number of patients having to be admitted to hospital for management.

Nevertheless, it is interesting that these three medical treatments do appear to have long-term success in the management of this lesion, which adds to the controversy over the actual histopathogenesis of this lesion and its long-term prognosis with or without treatment. There is some thought that the original authors on this lesion, who termed it a "reparative giant cell granuloma," may have been correct in many cases, and it is possible that the medical treatments described above may in fact just kick start a natural restorative process, which would have occurred in any case but might have taken longer. This lesion continues to interest and mystify our profession.

REFERENCES

- Jaffe HL. Giant-cell reparative granuloma, traumatic bone cyst, and fibrous (fibro-oseous) dysplasia of the jawbones. *Oral Surg Oral Med Oral Pathol* 1953;6:159-75.
- Yamaguchi T, Dorfman HD. Giant cell reparative granuloma: A comparative clinicopathologic study of lesions in gnathic and extragnathic sites. *Int J Surg Pathol* 2001;9:189-200.
- Bernier JL, Cahn LR. The peripheral giant cell reparative granuloma. *J Am Dent Assoc* 1954;49:141-8.
- Bernier JL. The Management of oral diseases. St Louis MO: Mosby; 1955. p. 640-1.
- Worth HM. Principles and practice of oral radiology interpretation. Chicago IL: Chicago Year Book Medical Publishers; 1963. p. 498-505.
- Berti SA, Couto Souza PH, Jacobs R, Lambrichts I, Corpas LS, Arruda EP, *et al*. Spontaneous resolution of a central giant-cell granuloma after incisional biopsy: A case report. *J Oral Maxillofac Surg* 2009;67:1543-7.
- Roberts J, Shores C, Rose AS. Surgical treatment is warranted in aggressive central giant cell granuloma: A report of 2 cases. *Ear Nose Throat J* 2009;88:E8-13.
- Tosco P, Tanteri G, Iaquina C, Fasolis M, Rocchia F, Berrone S, *et al*. Surgical treatment and reconstruction for central giant cell granuloma of the jaws: A review of 18 cases. *J Craniomaxillofac Surg* 2009;37:380-7.
- Chuong R, Kaban LB, Kozakewich H, Perez-Atayde A. Central giant cell lesions of the jaws: A clinicopathologic study. *J Oral Maxillofac Surg* 1986;44:708-13.
- Eckardt A, Pogrel MA, Kaban LB, Chew K, Mayall BH. Central giant cell granulomas of the jaws. Nuclear DNA analysis using image cytometry. *Int J Oral Maxillofac Surg* 1989;18:3-6.
- Ficarra G, Kaban LB, Hansen LS. Central giant cell lesions of the mandible and maxilla: A clinicopathologic and cytometric study. *Oral Surg Oral Med Oral Pathol* 1987;64:44-9.
- Hernandez G, Lopez-Pintor RM, Torres J, de Vicente JC. Clinical outcomes of peri-implant peripheral giant cell granuloma: A report of three cases. *J Periodontol* 2009;80:1184-91.
- O'Malley M, Pogrel MA, Stewart JC, Silva RG, Regezi JA. Central giant cell granulomas of the jaws: Phenotype and proliferation-associated markers. *J Oral Pathol Med* 1997;26:159-63.
- Flanagan AM, Nui B, Tinkler SM, Horton MA, Williams DM, Chambers TJ. The multinucleate cells in giant cell granulomas of the jaw are osteoclasts. *Cancer* 1988;62:1139-45.
- Imai Y, Kanno K, Moriya T, Kayano S, Seino H, Matsubara Y, *et al*. A missense mutation in the SH3BP2 gene on chromosome 4p16.3 found in a case of nonfamilial cherubism. *Cleft Palate Craniofac J* 2003;40:632-8.
- Lo B, Faiyaz-UI-Haque M, Kennedy S, Aviv R, Tsui LC, Teebi AS. Novel mutation in the gene encoding c-Abl-binding protein SH3BP2 causes cherubism. *Am J Med Genet A* 2003;121A:37-40.
- Tiziani V, Reichenberger E, Buzzo CL, Niazi S, Fukai N, Stiller M, *et al*.

- The gene for cherubism maps to chromosome 4p16. *Am J Hum Genet* 1999;65:158-66.
18. Mangion J, Rahman N, Edkins S, Barfoot R, Nguyen T, Sigurdsson A, *et al*. The gene for cherubism maps to chromosome 4p16.3. *Am J Hum Genet* 1999;65:151-7.
 19. Ueki Y, Tiziani V, Santanna C, Fukai N, Maulik C, Garfinkle J, *et al*. Mutations in the gene encoding c-Abl-binding protein SH3BP2 cause cherubism. *Nat Genet* 2001;28:125-6.
 20. Jacoway JR. Central giant cell granuloma: An alternative to surgical therapy. *Oral Surg Oral Med Oral Pathol Oral Radiol Endod* 1988;66:572.
 21. Terry BC, Jacoway JR. Management of the central giant cell lesion: An alternative to surgical therapy. *Oral Maxillofac Surg Clin North Am* 1994;6:579-600.
 22. Kermer C, Millesi W, Watzke IM. Local injection of corticosteroids for central giant cell granuloma. A case report. *Int J Oral Maxillofac Surg* 1994;23:366-8.
 23. Carlos R, Sedano HO. Intralesional corticosteroids as an alternative treatment for central giant cell granuloma. *Oral Surg Oral Med Oral Pathol Oral Radiol Endod* 2002;93:161-6.
 24. Harris M. Central giant cell granulomas of the jaws regress with calcitonin therapy. *Br J Oral Maxillofac Surg* 1993;31:89-94.
 25. Allon DM, Anavi Y, Calderon S. Central giant cell lesion of the jaw: Nonsurgical treatment with calcitonin nasal spray. *Oral Surg Oral Med Oral Pathol Oral Radiol Endod* 2009;107:811-8.
 26. de Lange J, Rosenberg AJ, van den Akker HP, Koole R, Wirds JJ, van den Berg H. Treatment of central giant cell granuloma of the jaw with calcitonin. *Int J Oral Maxillofac Surg* 1999;28:372-6.
 27. O'Regan EM, Gibb DH, Odell EW. Rapid growth of giant cell granuloma in pregnancy treated with calcitonin. *Oral Surg Oral Med Oral Pathol Oral Radiol Endod* 2001;92:532-8.
 28. Pogrel MA. Calcitonin therapy for central giant cell granuloma. *J Oral Maxillofac Surg* 2003;61:649-53.
 29. de Lange J, van den Akker HP, van den Berg H, Richel DJ, Gortzak RA. Limited regression of central giant cell granuloma by interferon alpha after failed calcitonin therapy: A report of 2 cases. *Int J Oral Maxillofac Surg* 2006;35:865-9.
 30. Kaban LB, Mulliken JB, Ezekowitz RA, Ebb D, Smith PS, Folkman J. Antiangiogenic therapy of a recurrent giant cell tumor of the mandible with interferon alfa-2a. *Pediatrics* 1999;103:1145-9.
 31. Kaban LB, Troulis MJ, Wilkinson MS, Ebb D, Dodson TB. Adjuvant antiangiogenic therapy for giant cell tumors of the jaws. *J Oral Maxillofac Surg* 2007;65:2018-24.
 32. Kaban LB, Troulis MJ, Ebb D, August M, Hornicek FJ, Dodson TB. Antiangiogenic therapy with interferon alpha for giant cell lesions of the jaws. *J Oral Maxillofac Surg* 2002;60:1103-11.

Cite this article as: Pogrel AM. The diagnosis and management of giant cell lesions of the jaws. *Ann Maxillofac Surg* 2012;2:102-6.

Source of Support: Nil, **Conflict of Interest:** None declared.

Announcement

Android App



Download
**Android
application**

FREE

A free application to browse and search the journal's content is now available for Android based mobiles and devices. The application provides "Table of Contents" of the latest issues, which are stored on the device for future offline browsing. Internet connection is required to access the back issues and search facility. The application is compatible with all the versions of Android. The application can be downloaded from <https://market.android.com/details?id=comm.app.medknow>. For suggestions and comments do write back to us.