



CO₂ Laser Marsupialization for Internal and Combined Laryngocele

Barbara Verro¹ Carmelo Saraniti¹

¹ENT Clinic, Department of Biomedicine, Neuroscience and Advanced Diagnostic, University of Palermo, Palermo, Italy

Int Arch Otorhinolaryngol 2023;27(3):e428–e434.

Address for correspondence Carmelo Saraniti, Md, PhD, Otorhinolaryngology Clinic, Department of Biomedicine, Neurosciences and Advanced Diagnostic, University of Palermo, Via del Vespro n°129, Palermo, 90127, Italy (e-mail: carmelo.saraniti@unipa.it).

Abstract

Introduction Laryngocele is an air-filled dilatation of the laryngeal saccule that can be classified according to its extent (internal, external, or combined) and contents (laryngocele or laryngopyocele). To date, there is no consensus on the best treatment for laryngocele.

Objective The present study aims to demonstrate for the first time the effectiveness of CO₂ laser marsupialization for internal and combined laryngoceles.

Methods A retrospective study was accomplished in our ENT Clinic of the University Hospital, from 2010 to today, recruiting patients according to strict criteria. All patients had internal or combined laryngocele/laryngopyocele treated with CO₂ laser marsupialization.

Results A total of 15 patients were enrolled for a total of 17 laryngoceles; 66.67% of the patients were males and the mean age was 54.4 (±14.12) years old. Internal laryngoceles accounted for 64.71% of the total, and only 7 cases were laryngopyoceles. At the 3-year follow-up, no signs of recurrence were found.

Conclusion CO₂ laser marsupialization is efficacious in the treatment of laryngocele or laryngopyocele, both internal and combined, in terms of efficiency, safety, and fast postoperative recovery, without need for tracheotomy or open surgery.

Keywords

- ▶ laryngocele
- ▶ laser surgery
- ▶ laser therapy
- ▶ therapeutics

Introduction

Laryngocele is an air-filled dilatation of the laryngeal saccule, also known as appendix of the ventricle of Morgagni. In 1829, Larrey – a surgeon of Napoleon's army – first described it as a local air-filled swelling in the neck of Muslims.¹ Then, in 1867, Virchow named this dilatation laryngocele.²

Today, the etiopathogenesis of laryngocele remains unclear and several theories have been proposed: genetic predisposition (congenital wide saccule or congenital tissue weakness), mechanical obstruction (laryngeal amyloidosis or laryngeal cancer), increased laryngeal lumen

pressure (in case of wind instrument player or glass blower).^{3–5}

Laryngocele can be classified as *internal* if the laryngeal saccule does not pass the thyrohyoid membrane, *external* if the laryngeal saccule exceeds the thyrohyoid membrane, and *combined* if laryngocele is both internal and external.⁶ Moreover, in case of infection of this dilated saccule, it becomes a laryngopyocele that could cause acute respiratory obstruction.⁷

This clinical entity is a rare disease,⁶ usually combined and unilateral,⁸ that occurs five times more frequently in males between the 5th and the 6th decades of life.^{9,10}

received
August 28, 2021
accepted after revision
March 20, 2022

DOI <https://doi.org/10.1055/s-0042-1748926>
ISSN 1809-9777.

© 2023. Fundação Otorrinolaringologia. All rights reserved.
This is an open access article published by Thieme under the terms of the Creative Commons Attribution-NonDerivative-NonCommercial-License, permitting copying and reproduction so long as the original work is given appropriate credit. Contents may not be used for commercial purposes, or adapted, remixed, transformed or built upon. (<https://creativecommons.org/licenses/by-nc-nd/4.0/>)
Thieme Revinter Publicações Ltda., Rua do Matoso 170, Rio de Janeiro, RJ, CEP 20270-135, Brazil

Currently, treatment of laryngocele includes several surgical therapeutic strategies: endoscopic approach (CO2 laser, microdebrider, cold instrumentation), open surgery (thyrotomy, transthyrohyoid membrane approach), and transoral robotic surgery (TORS).^{7,11-15} However, there is no consensus on the best treatment for laryngocele. To date, the endolaryngeal approach is performed for most internal laryngoceles.¹⁶ Regarding combined laryngocele, a recent review reported the external approach as the most performed therapy.¹⁷ Furthermore, since 2013, TORS has also been used for this type of laryngocele with satisfactory results.^{7,18} However, the current literature is poor in studies about CO2 laser marsupialization as a single treatment for internal and combined laryngocele.

Therefore, the present study aims to demonstrate for the first time the effectiveness of CO2 laser marsupialization for internal and combined laryngoceles, limiting open surgery (more invasive) to external laryngoceles only.

Material and Methods

A retrospective study was accomplished in our ENT Clinic of the University Hospital, from 2010 to today. Patients were recruited according to strict criteria. The inclusion criteria were: 1) both males and females; 2) age > 18 years old; 3) patients with internal or combined laryngocele or laryngopyocele; 4) patients undergoing transoral CO2 laser marsupialization for laryngocele or laryngopyocele; 5) histological assessment of the specimen; 6) at least 3 years of follow-up.

The exclusion criteria included: 1) patients without preoperative imaging exams (neck computed tomography [CT] and/or magnetic resonance imaging [MRI]); 2) patients with external laryngocele or laryngopyocele; 3) patients undergoing other surgery than CO2 laser for laryngocele or laryngopyocele.

Study Protocol

Once patients were recruited, the following data were collected and analyzed: gender, age at diagnosis, type of laryngocele (internal/combined), contents of laryngocele (air/pus), side of laryngocele (right/left), histological assessment, duration of hospitalization, any postoperative complications, and any recurrence.

Surgical Technique

Surgery is performed under general anesthesia by orotracheal intubation. After medial retraction of false vocal folds by grasping forceps, endoscopic CO2 laser vestibulectomy is performed to remove the collar of the laryngeal sacculae. Then, marsupialization of laryngocele and drainage of any pus are made (►Fig. 1). The excised mucosa is sent for histological assessment.

Statistical Analysis

Data were collected on Excel spreadsheets and reported as numbers, percentages and/or mean values (\pm standard deviation [SD]).

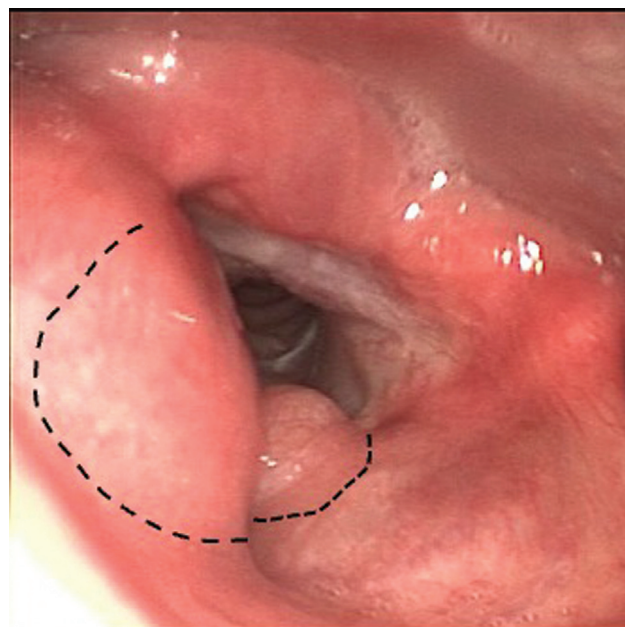


Fig. 1 Bilateral laryngocele: the dotted lines represent the point where the CO2 laser incision is performed for the vestibulectomy to show the laryngocele with its collar.

Results

After strict selection, 15 patients were enrolled in the present study, for a total of 17 laryngoceles (►Table 1). Two-thirds (66.67%) of the patients were males and the average age was 54.4 (\pm 14.12) years old. Internal laryngoceles accounted for 64.71% of the total and only 7 cases were laryngopyoceles (►Fig. 2). In nine patients, it occurred on the left laryngeal sacculae. Moreover, we had 2 cases of bilateral laryngoceles (#1 and #4) (►Fig. 3). Histological examinations showed chronic inflammation of the mucosa and connective tissue in most cases; squamous cell carcinoma was found in only 2 specimens (#3 and #6).

After surgery, patients were discharged in 2.33 (\pm 1.49) days on average, without any postoperative complication or need for tracheotomy. In particular, the average hospitalization lasted 1.9 (\pm 0.89) days for patients with internal laryngocele, 3.33 (\pm 1.79) days for patients with combined laryngocele, and 2.42 (\pm 1.17) days for patients with laryngopyocele. So, patients with combined laryngocele and those with laryngopyocele had a slightly longer hospitalization than those with internal laryngocele.

Enrolled patients were followed-up for at least 3 years with nasolaryngoscopy – and neck CT in case of very large laryngocele – and no signs of recurrence were found.

These data are shown in ►Table 2.

Below, we reported a remarkable case of combined bilateral large laryngocele.

Case #4

A 70-year-old male patient, smoker, came to our ENT clinic reporting a swelling in the left side of the neck that increased in size when coughing. He also reported dysphonia, denied dyspnea and dysphagia. On physical examination, a bulging,

Table 1 Enrolled patients

#	Gender	Age	Type*	Contents*	Side*	Histology	Hospitalization (days)	Postoperative complications	Recurrence**
1	F	48	Combined	Pus	Right	Inflamed tissue	4	None	None
			Internal	Pus	Left				
2	M	50	Combined	Air	Left	Inflamed tissue + mild dysplasia	2	None	None
3	M	47	Internal	Pus	Right	Cancer	3	None	None
4	M	70	Combined	Air	Left	Inflamed tissue	2	None	None
			Internal	Air	Right				None
5	F	25	Combined	Air	Right	Inflamed tissue	6	None	None
6	M	54	Internal	Pus	Left	Cancer	2	None	None
7	M	48	Combined	Air	Left	Inflamed tissue	5	None	None
8	F	70	Internal	Air	Left	Inflamed tissue	2	None	None
9	M	72	Internal	Air	Left	Inflamed tissue	1	None	None
10	M	71	Internal	Air	Left	Inflamed tissue	2	None	None
11	M	68	Internal	Air	Right	Inflamed tissue	1	None	None
12	M	66	Internal	Air	Left	Inflamed tissue	1	None	None
13	F	75	Internal	Pus	Left	Inflamed tissue	2	None	None
14	M	50	Combined	Pus	Left	Inflamed tissue	1	None	None
15	F	77	Internal	Pus	Right	Inflamed tissue	1	None	None

Abbreviations: F, female; M, male.

*of laryngocele.

** 3 years after surgery.

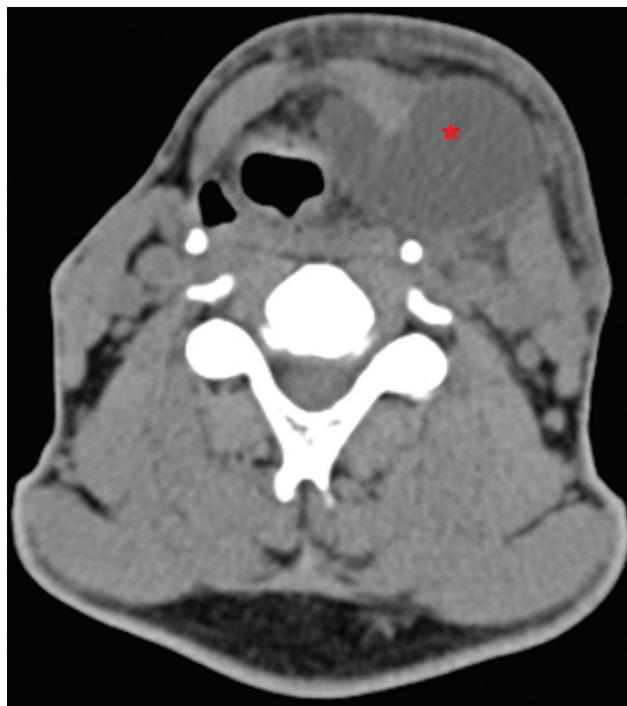

Fig. 2 Left laryngocele: axial scan of neck computed tomography (red asterisk).

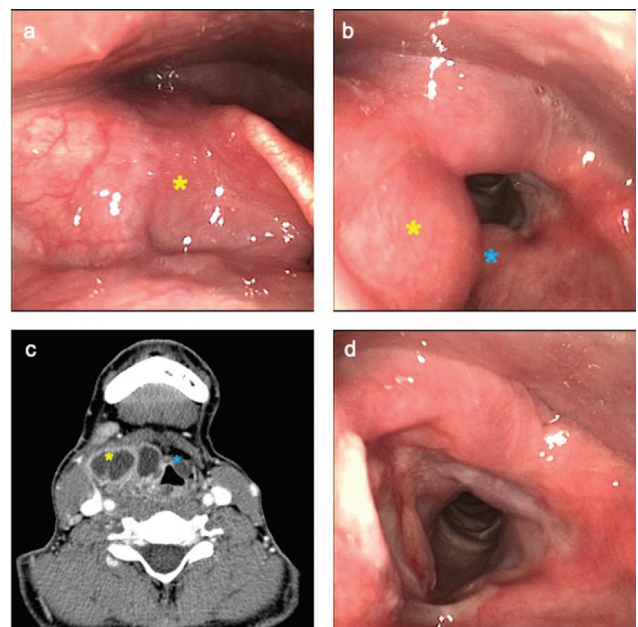


Fig. 3 Bilateral laryngocele: (a) preoperative laryngoscopic image of right laryngocele (yellow asterisk), (b) preoperative laryngoscopic image of bilateral laryngoceles (left laryngocele: blue asterisk, right laryngocele: yellow asterisk), (c) preoperative axial CT scan of neck (left laryngocele: blue asterisk, right laryngocele: yellow asterisk), (d) 7-day postoperative laryngoscopic image.

Table 2 Characteristics of the patients'

Characteristics	n (%)
Gender	
Male	10 (66.67)
Female	5 (33.33)
Age at diagnosis (years old)	
Range	25–77
Mean (\pm SD)	54.4 (\pm 14.12)
Type of laryngocele*	
Internal	11 (64.71)
Combined	6 (35.29)
Contents of laryngocele*	
Air	10 (58.82)
Pus	7 (41.18)
Side of laryngocele	
Right	4 (26.66)
Left	9 (60)
Bilateral	2 (13.34)
Histology	
Inflamed mucosa	13 (86.66)
Cancer	2 (13.34)
Duration of hospitalization (days)	
Range	1–6
Mean (\pm SD)	2.33 (\pm 1.49)
Internal laryngocele	1.9 (\pm 0.89)
Combined laryngocele	3.33 (\pm 1.79)
Laryngopyocele	2.42 (\pm 1.17)
Postoperative complications	
Yes	0 (0)
No	15 (100)
Recurrence of disease at 3 years	
Yes	0 (0)
No	15 (100)
Total	15 (100)

Abbreviation: SD, standard deviation.

*out of a total of 17 cases.

soft, nonpulsatile and tender swelling, measuring $\sim 5 \times 7$ cm, covered by normal skin, which increased in size with the Valsalva maneuver, was found on the left side of his neck. Fiberoptic laryngoscopy showed a bulging of the left false vocal fold, covered by normal mucosa that medialized the left hemilarynx and obstructed the ipsilateral piriform sinus. On the right false vocal fold, a similar bulging was found. The glottic plane was normal, with good airway patency. Therefore, the patient underwent a neck CT with contrast medium that showed a huge laryngocele on the left side, measuring $\sim 4.3 \times 5.8 \times 9$ cm, which extended up to ipsilateral laterocervical subcutaneous soft tissues (\rightarrow Fig. 4). The CT also showed

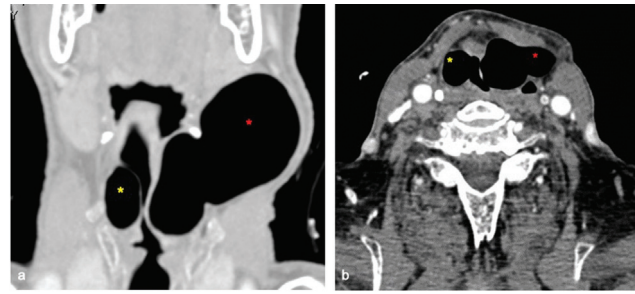


Fig. 4 Neck computed tomography of preoperative bilateral combined laryngocele (left laryngocele: red asterisk, right laryngocele: yellow asterisk): (a) coronal scan, (b) axial scan.

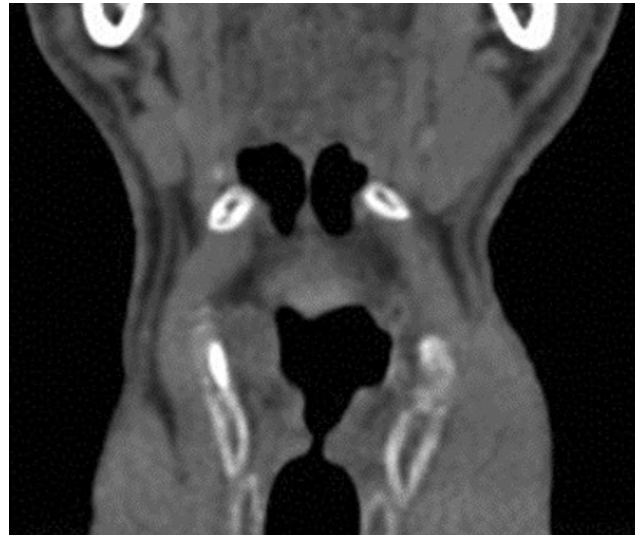

Fig. 5 Six months after surgery: computed tomography coronal scan.

a laryngocele in the right side, measuring $\sim 2 \times 1.6 \times 3$ cm. Therefore, marsupialization of bilateral laryngocele by CO2 laser was performed. He was discharged on the 2nd postoperative day. During follow-up, no disease recurrence occurred (\rightarrow Fig. 5).

Laryngeal Cancer and Laryngocele

In two cases (#3 and #6), a squamous cell carcinoma was found on histological examination. A preoperative laryngoscopy, also using narrow band imaging (NBI), showed a suspicious glottic lesion. Due to this finding, a CT with contrast medium was performed, confirming our hypothesis of malignancy and simultaneous presence of an internal laryngopyocele (\rightarrow Fig. 6). Case #3 was cT4aN0 and case #6 was cT3N0.¹⁹ Therefore, during surgery, endoscopic CO2 laser vestibulectomy and marsupialization of laryngocele and drainage of pus were performed. After this step, multiple biopsies of the glottic lesion were performed for histological assessment in case #6. In case #3, debulking of the lesion was performed to avoid tracheostomy. Once histology confirmed the cancer, possible therapeutic strategies (surgical or non-surgical), with their pros and cons, were explained to the

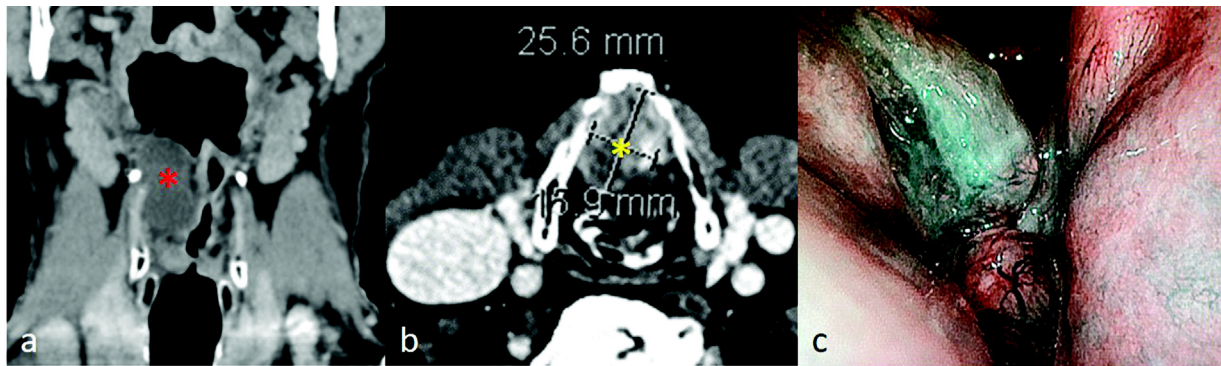


Fig. 6 Case #6: (a) coronal computed tomography scan showing left laryngopyocele (red asterisk), (b) axial computed tomography scan showing the glottic cancer (yellow asterisk), (c) preoperative Narrow Band Imaging (NBI) laryngoscopy with glottic cancer involving the anterior commissure.

patients. They accepted surgery; therefore, a total laryngectomy with bilateral neck dissection and tracheoesophageal puncture was performed. To date, case #3 and #6 are disease-free after 5 years and 6 years, respectively.

Discussion

Laryngocele is a rare enlarged air-filled laryngeal sacculle. It usually occurs in middle-aged men,¹⁰ as we have found in our study, where 66.67% of the patients were males with a mean age of 54.4 (± 14.12) years old. Laryngocele can be classified according to its extent or contents. Therefore, it can be external or internal if the laryngeal sacculle passes the thyrohyoid membrane or not, or it can be combined if it is both internal and external.⁶ Regarding the contents, an enlarged laryngeal sacculle is usually filled with air; however, in some cases, it can become infected and filled with pus, the so-called laryngopyocele.¹² In our patient cohort, data were consistent with the current literature: 41.18% of the patients had laryngopyocele and 35.29% had the combined type. A correct and prompt diagnosis of the disease is mandatory to attain the best therapy and the best prognosis for the patients. In fact, in the literature, some cases of tracheotomy are reported,⁹ especially for laryngopyocele.¹² Before a CO₂ laser marsupialization, an accurate study of laryngoscopy and radiological scans is essential. Fiber optic laryngoscopy provides information about the morphology of the laryngeal mucosa, cordal motility, and possible airway obstruction. In addition, Narrow Band Imaging (NBI)²⁰ allows to search for any suspicious anomalies of malignancy in mucosal and submucosal vascular patterns. Radiological scans allow to confirm the diagnostic hypothesis of laryngocele, identifying the origin of the laryngocele in the anterior third of the Morgagni ventricle, its extralaryngeal extent and its contents, as well as its relationship with surrounding structures. Moreover, radiology is useful and necessary in the differential diagnosis of lesions that may require different surgical treatments (laryngeal cancer, external laryngocele, saccular cyst, neck abscess, branchial cyst, and neck adenopathy). Therefore, in all cases, a multidisciplinary approach is important to determine the most appropriate and proper therapy.^{21,22} Anyway, the histological examination is the

gold standard diagnostic examination that allows to differentiate laryngocele from other macroscopically similar lesions such as saccular cyst, neck abscess, branchial cyst, and neck adenopathy.⁶ Moreover, histology provides another important information: the concomitant presence of a laryngeal cancer or amyloidosis. In fact, these findings are very rare: only 5% of laryngocele are associated with laryngeal cancer.⁵ In our study, samples of excised mucosa were always sent for histological assessment, and laryngeal cancer was found in two cases. Therefore, once the diagnosis has been made, the proper treatment should be detected and performed. To date, there is no agreement on the best therapeutic approach; a recent review⁷ analyzed studies published from 1946 and found several different laryngocele management strategies: endoscopic approach (CO₂ laser, microdebrider,¹¹ and cold instrumentation¹²), open surgery (thyrotomy, transthyrohyoid membrane approach), and TORS.⁷ Each therapeutic approach has advantages and limitations. However, several authors concluded that endoscopic resection with CO₂ laser is the preferred therapy for internal laryngocele in terms of effectiveness, safety, fast surgery, and fast postoperative recovery with faster speech and swallowing rehabilitation.^{6,7,9} Possible limitations and complications of this surgical procedure are limited laryngeal exposure, laryngeal scars, incomplete resection, and the experience of the surgeon with this technique. In addition, Transoral Laser Microsurgery (TLM) has now almost completely supplanted cold laryngeal microsurgery in the treatment of laryngocele, considerably reducing the risk of bleeding.

In turn, combined laryngocele is usually treated with an open approach and, more recently, with TORS.^{4,23} Anyway, although the external approach ensures a better view of the laryngocele and a lower risk of recurrence, it also has several disadvantages and complications, such as wound infection, hematoma, skin scar, injury of the superior laryngeal nerve and/or artery, longer duration of surgery, increased risk of infection, longer hospitalization, and, therefore, higher costs than TLM.¹⁶ Some authors recommend a combined external and endolaryngeal approach for the treatment of combined laryngocele.¹⁰ Transoral robotic surgery represents a new therapeutic resource that allows better laryngeal exposure

and, therefore, complete resection of the laryngocele, when compared with classical laryngeal microsurgery.^{13,17} A 2020 review reported 18 combined laryngocele cases treated with TORS: 1 case had covering tracheotomy, 1 case had postoperative bleeding, and 5 cases needed nasogastric feeding postoperatively.⁷ Therefore, even TORS is related to more or less serious complications, but they are rare; moreover, compared with CO2 laser, not all hospitals have a DaVinci Robot.

However, in our cohort, we performed CO2 laser marsupialization for both internal and combined laryngoceles and we proved that a proper and correct execution of the surgical technique does not correlate with disease recurrence, which disagrees with the current literature, which does not recommend it due to its high rate of recurrence.⁴ In fact, we found satisfactory results in all of the cases in which we used this surgical technique and, for this reason, in our opinion, it represents the first therapeutic choice for internal and combined laryngoceles. There are no particular cases (based on preoperative laryngoscopic or radiological findings) in which marsupialization is indicated rather than another technique. Moreover, this surgery does not involve excision of the entire laryngeal pouch, regardless of the size of the laryngocele. In particular, in the case of internal laryngocele, resolution is immediate; however, in the case of combined laryngocele, healing occurs more slowly; in fact, removing the valve mechanism and, therefore, stopping the filling of the pouch, a complete healing is achieved spontaneously within 2 months without risk of recurrence. In fact, the key point of this surgery is the vestibulectomy that is performed with the aim of removing the valve mechanism that is the basis of the pathogenesis of laryngocele.

Reviewing the literature, we found few articles about marsupialization; however, it was performed only for internal laryngocele without recurrence.^{11,12,24,25} Moreover, each author described only a case report in which surgery was performed with CO2 laser, microdebrider, or cold instrumentation. In turn, we reported 15 cases of internal and combined laryngocele (sometimes even bilateral and/or infected) treated with CO2 laser marsupialization without need for tracheotomy, postoperative complications and/or recurrence and with short hospitalization. Obviously, the choice of a surgical strategy depends not only on the type of laryngocele (external versus internal or combined), but also on the experience of the surgeon.³

However, although our case study is the largest in the literature about the use of CO2 laser marsupialization for internal and combined laryngoceles, it includes only 15 patients. Therefore, other studies with more cases would be necessary to support these results.

Conclusion

The present study demonstrated the effectiveness of CO2 laser marsupialization in the treatment of laryngocele or laryngopyocele, both internal and combined, in terms of efficiency, safety, and fast postoperative recovery. Anyway, it should be emphasized that the success of this surgical

technique depends on the experience of the surgeon and on a careful study of the specific clinical case.

Funding

The author(s) received no financial support for the research.

Conflict of Interests

The authors have no conflict of interests to declare.

References

- Larrey DJ. Clinique Chirurgicale, exercé particulierizável dans les Camps, et les Hôpitaux Militaires depuis 1792, jusqu' en 1829. *Med Chir Rev* 1831;15(29):1-21
- Virchow R. Die krankhaften geschwielste. Berlin A Hirschwald 1867;3:35
- Dursun G, Ozgursoy OB, Beton S, Batikhan H. Current diagnosis and treatment of laryngocele in adults. *Otolaryngol Head Neck Surg* 2007;136(02):211-215. Doi: 10.1016/j.otohns.2006.09.008
- Zelenik K, Stanikova L, Smatanova K, Cerny M, Kominek P. Treatment of Laryngoceles: what is the progress over the last two decades? *BioMed Res Int* 2014;2014:819453. Doi: 10.1155/2014/819453
- Marom T, Roth Y, Cinamon U. Laryngocele: a rare long-term complication following neck surgery? *J Voice* 2011;25(03):272-274. Doi: 10.1016/j.jvoice.2010.01.011
- Swain SK, Chandra Mallik K, Mishra S, Chandra Sahu M. Laryngocele: Experience at a Tertiary Care Hospital of Eastern India. *J Voice* 2015;29(04):512-516. Doi: 10.1016/j.jvoice.2014.09.013
- Singh R, Karantanis W, Fadhil M, Kumar SA, Crawford J, Jacobson I. Systematic review of laryngocele and pyolaryngocele management in the age of robotic surgery. *J Int Med Res* 2020;48(10):300060520940441. Doi: 10.1177/0300060520940441
- Keles E, Alpay HC, Orhan I, Yildirim H. Combined laryngocele: a cause of stridor and cervical swelling. *Auris Nasus Larynx* 2010;37(01):117-120. Doi: 10.1016/j.anl.2009.02.011
- Suqati AA, Alherabi AZ, Marglani OA, Alaidarous TO. Bilateral combined laryngocele. *Saudi Med J* 2016;37(08):902-903. Doi: 10.15537/smj.2016.8.15104
- Mobashir MK, Basha WM, Mohamed AE, Hassaan M, Anany AM. Laryngoceles: Concepts of diagnosis and management. *Ear Nose Throat J* 2017;96(03):133-138. Doi: 10.1177/014556131709600313
- Fraser L, Pittore B, Frampton S, Brennan P, Puxeddu R. Laryngeal debridement: an alternative treatment for a laryngopyocele presenting with severe airway obstruction. *Acta Otorhinolaryngol Ital* 2011;31(02):113-117
- Al-Yahya SN, Baki MM, Saad SM, Azman M, Mohamad AS. Laryngopyocele: report of a rare case and systematic review. *Ann Saudi Med* 2016;36(04):292-297. Doi: 10.5144/0256-4947.2016.292
- Villeneuve A, Vergez S, Bakhos D, Lescanne E, Pinlong E, Morinière S. Management of laryngoceles by transoral robotic surgery. *Eur Arch Otorhinolaryngol* 2016;273(11):3813-3817. Doi: 10.1007/s00405-016-4171-6
- Bisogno A, Cavaliere M, Scarpa A, Cuofano R, Troisi D, Iemma M. Left mixed laryngocele in absence of risk factors: A case report and review of literature. *Ann Med Surg (Lond)* 2020;60:356-359
- Lisan Q, Hoffmann C, Jouffroy T, Hans S. Combined laser and robotic approach for the management of a mixed laryngomucocele. *J Robot Surg* 2016;10(01):81-83. Doi: 10.1007/s11701-015-0552-x
- Kara İ, Kökoğlu K, Çağlı S, Yüce İ Bilateral Laryngocele Causing Epiglottic Deformity and Upper Airway Obstruction. *Turk Arch Otorhinolaryngol* 2019;57(02):99-101. Doi: 10.5152/tao.2019.3949
- Juneja R, Arora N, Meher R, et al. Laryngocele: A Rare Case Report and Review of Literature. *Indian J Otolaryngol Head Neck Surg* 2019;71(Suppl 1):147-151. Doi: 10.1007/s12070-017-1162-x

- 18 Gal TJ, Hixon B, Zhang P. Transoral robotic resection of a combined laryngocele. *J Robot Surg* 2017;11(02):263–266. Doi: 10.1007/s11701-016-0666-9
- 19 Jones TM, De M, Foran B, Harrington K, Mortimore S. Laryngeal cancer: United Kingdom National Multidisciplinary guidelines. *J Laryngol Otol* 2016;130(S2):S75–S82. Doi: 10.1017/S0022215116000487
- 20 Saraniti C, Chianetta E, Greco G, Mat Lazim N, Verro B. The Impact of Narrow-band Imaging on the Pre- and Intra- operative Assessments of Neoplastic and Preneoplastic Laryngeal Lesions. A Systematic Review. *Int Arch Otorhinolaryngol* 2021;25(03):e471–e478. Doi: 10.1055/s-0040-1719119
- 21 Lancellata A, Abbate G, Dosdegani R. Mixed laryngocele: a case report and review of the literature. *Acta Otorhinolaryngol Ital* 2007;27(05):255–257
- 22 Slonimsky G, Hawng G, Goldenberg D, Gagnon E, Slonimsky E. Terminology, Definitions, and Classification in the Imaging of Laryngoceles. *Curr Probl Diagn Radiol* 2021;50(03):384–388. Doi: 10.1067/j.cpradiol.2020.06.002
- 23 Mahdoui R, Barhmi I, Tazi N, Abada R, Roubal M, Mahtar M. Mixed Pyolaryngocele: A Rare Case of Deep Neck Infection. *Iran J Otorhinolaryngol* 2017;29(93):225–228
- 24 Hirvonen TP. Endoscopic CO₂ laser surgery for large internal laryngocele. *ORL J Otorhinolaryngol Relat Spec* 2001;63(01):58–60. Doi: 10.1159/000055708
- 25 Myssiorek D, Persky M. Laser endoscopic treatment of laryngoceles and laryngeal cysts. *Otolaryngol Head Neck Surg* 1989;100(06):538–541. Doi: 10.1177/019459988910000602