

Nonsurgical Correction of Stahl's Ear in Neonates: A Case Study

Georgina Panopoulou, MD*†
Ilias Petrou‡
Andreas Vassiliou, MD*§

Summary: Stahl's ear deformity is a congenital auricular anomaly characterized by a third crus in the auricular cartilage, giving rise to an irregular helical rim and a bent scaphoid fossa. This deformity is mainly treated surgically during childhood. However, studies regarding ear-molding techniques show that postpartum splinting offers a safer and more effective permanent correction, and that happens because of the high circulating levels of estrogen that neonates receive from their mothers right after birth, making the cartilage more malleable. We present a case that shows a newborn with unilateral Stahl's ear deformity, in which we used a molding device (EarBuddies) to permanently correct the ear's shape. After 3 weeks of treatment, the affected auricle regained its normal appearance. There were no complications. Long-term follow-up showed no recurrence. Splinting of this ear deformity seems to be a nonpainful, stress-free and, most importantly, effective nonoperative treatment. Postpartum clinical examination of the ears is crucial, as the sooner the nonsurgical correction of the deformity begins, the better the results are. A clinical screening for ear deformities should be established immediately after every child's birth to eliminate the risk for surgical intervention later in childhood. (*Plast Reconstr Surg Glob Open* 2022;10:e4566; doi: 10.1097/GOX.0000000000004566; Published online 11 October 2022.)

Stahl's ear deformity is an uncommon congenital auricular anomaly that can lead to psychological disruption. It is mainly characterized by a third crus in the ear cartilage, extending from the antihelix to the helix crus, giving rise to an irregular helical rim and a bent scaphoid fossa. This causes the top of the ear to appear pointed and flat.¹ It is usually corrected surgically during childhood. Alternatively, the ear molding technique has been shown to be a safe and effective nonsurgical treatment.²⁻⁶ Choosing a conservative treatment over otoplasty includes fewer complications and is less stressful for both parents and children.⁷⁻⁹

Nonsurgical procedures for the correction of congenital ear deformities were first published during the 1980s in Japan by plastic surgeons, and since then their use has been popularized. It is now acknowledged that keeping

the ear in a constant position for a specific period will result in a normal ear shape.²⁻⁶ That happens because of the softness and lack of elasticity that the auricle of the neonate has right after birth.^{10,11} Physiologically this can be explained by the increased estrogen production during neonatal period, which results in elevated hyaluronic acid levels.^{10,11} The increased levels of the former leads to the separation of the intercellular materials (collagen, elastin, proteoglycans) from the chondrocytes, thus the cartilage lacks elasticity.^{10,11} During this fundamental period, when the ear is softer and more malleable, the application of constant pressure on the deformed cartilage will give the ear a more normal shape.^{3,12,13} That is why the sooner the intervention begins, the shorter the application period will be.^{3,12,13}

CASE PRESENTATION

A 1-week-old neonate was brought by the parents to the plastic surgery ward because of an ear deformity dating from birth, with no pathological history according to the parents' report. The female child was born at full term. Clinical examination revealed a unilateral Stahl's ear deformity (Fig. 1A). It was mainly characterized by a third crus and a deformed scaphoid fossa. A splinting device (EarBuddies) was applied on the same day (Fig. 1B).

Disclosure: The authors have no financial interests to declare in relation to the content of this article.

From the *Plastic and Reconstructive Surgery Department, Nicosia General Hospital, Nicosia, Cyprus; †School of Medicine, University of Ioannina, Ioannina, Greece; ‡Student of Medicine, School of Medicine, European University Cyprus, Nicosia, Cyprus; and §School of Medicine, University of Crete, Heraklion, Greece.

Received for publication May 26, 2022; accepted August 11, 2022.

Copyright © 2022 The Authors. Published by Wolters Kluwer Health, Inc. on behalf of The American Society of Plastic Surgeons. This is an open-access article distributed under the terms of the Creative Commons Attribution-Non Commercial-No Derivatives License 4.0 (CCBY-NC-ND), where it is permissible to download and share the work provided it is properly cited. The work cannot be changed in any way or used commercially without permission from the journal.

DOI: 10.1097/GOX.0000000000004566

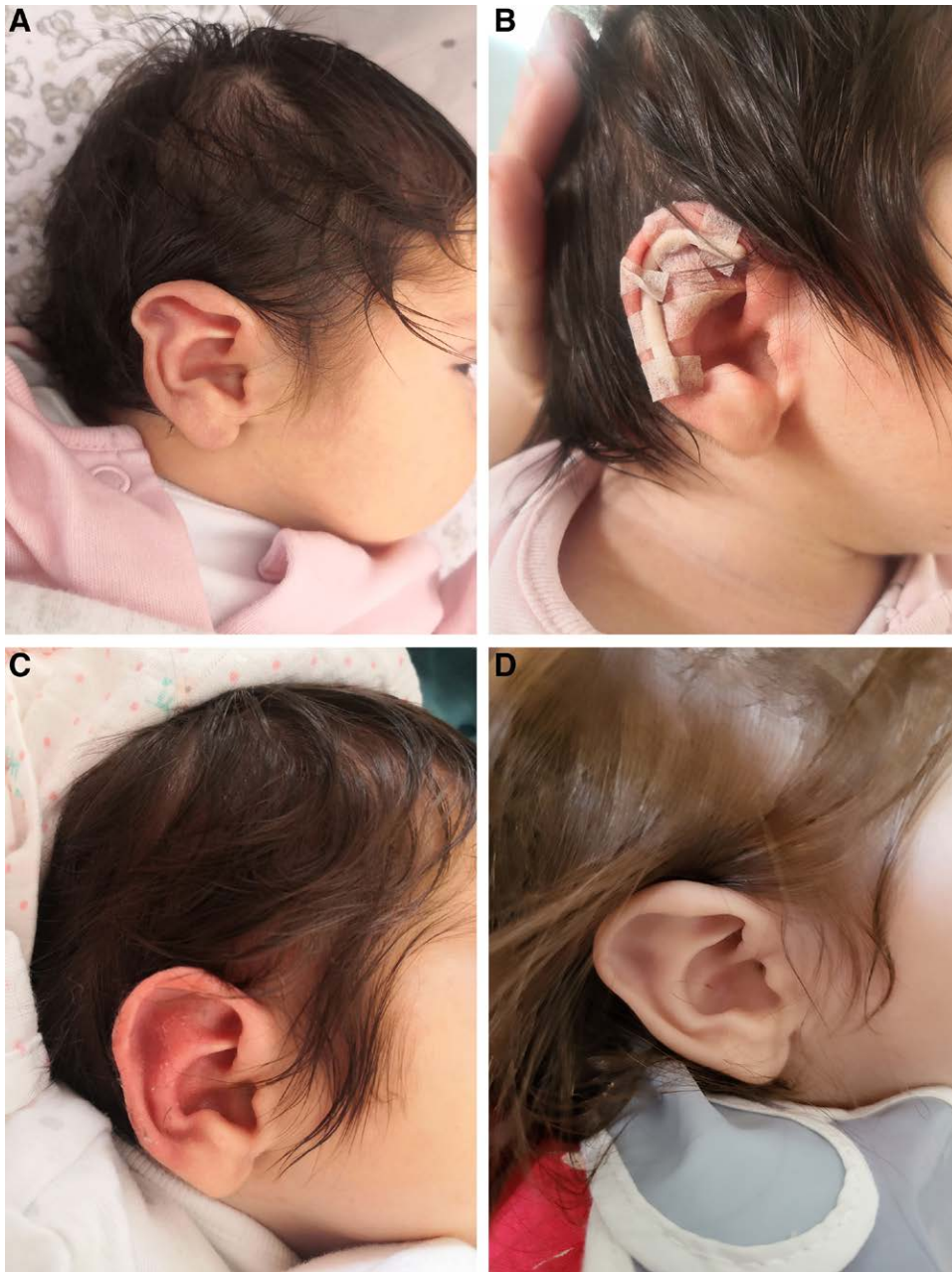


Fig. 1. The neonate's auricle. (A) Stahl's ear before correction. (B) Molding device stabilized with adhesive tapes. (C) The affected auricle regained its normal appearance 3 weeks later. (D) Long-term follow-up at 7 months.

MANAGEMENT AND OUTCOME

The newborn was managed with a nonsurgical method by applying an ear molding device, on the 7th day postpartum. A bendable splint made of medical grade plastics, silicones, and inert metals was placed, and left in position for a period of 3 weeks. Starting just above the triangular fossa, the splint was applied to the scaphal hollow inside the rim. After that, the splint was stabilized with the use of hypoallergenic, latex-free, and water-resistant adhesive tapes, which were changed once a week or when needed. The splinted ear was further supported using a bigger tape attached to the head. The parents were instructed to readjust the tapes

when displacement of the molding device was observed. During bath time, a small plastic shower cap was used to keep the area dry. Regular follow-up visits were done every 7 days. An improvement of the appearance of the ear was notable on day 12. Regarding the outcome, the affected auricle regained its normal appearance (Fig. 1C). The parents were satisfied with the result. Long-term follow-up showed no recurrence of the deformity (Fig. 1D).

DISCUSSION

According to a large review of 1000 infants, congenital auricular deformities are found in 55.2% of neonates at

birth, with Stahl's ear appearing in only 8.7% of all newborns.¹⁴ Stahl's ear deformity is characterized by a misshaped but fully developed pinna, and it is only developed perinatally. Postpartum splinting can be performed in many ways, as long as the desired shape of the auricle is maintained in position with continuous pressure.¹³

A variety of techniques for surgical reconstruction of this deformity have been described, but nonoperative methods also have satisfactory results, mainly when used during the neonatal period.^{2-5,15,16} The complications of an otoplasty (hematoma, bleeding, and postoperative infections) are absent,⁷ and as Smith et al¹⁷ reported, there is a 100% correction rate for Stahl's ear deformity. Moreover, Byrd et al¹⁸ showed a correction rate of more than 90%, which was significantly higher than the self-correction rate (30%). Additionally, the noninvasive method prevents later emotional distress for both parents and the child, as the deformity is treated right after birth, in a painless and inexpensive way.

Over the past few years, splinting congenital ear deformities in early neonatal life is becoming even more popular; however, it needs to be better brought to the attention of the scientific community. Firstly, it is fundamental that health care providers should be properly educated about early detection and efficient management of the ear deformity. Furthermore, guidance regarding the correct application of splinting should be given to the parents.⁶ It is crucial that neonatal pediatricians must establish a full physical examination, including detailed auricular inspection, and once the diagnosis is reached, a referral to a plastic surgeon must be suggested as soon as possible. Any delay may result in a possible unneeded surgery in the future.

Georgina Panopoulou, MD

Nicosia General Hospital
Nicosia, Cyprus

E-mail: georginapanopoulou@yahoo.co.uk

REFERENCES

- Joukhadar N, McKee D, Caouette-Laberge L, et al. Management of congenital auricular anomalies. *Plast Reconstr Surg.* 2020;146:205e-216e.
- van Wijk MP, Breugem CC, Kon M. Non-surgical correction of congenital deformities of the auricle: a systematic review of the literature. *J Plast Reconstr Aesthet Surg.* 2009;62:727-736.
- Matsuo K, Hirose T, Tomono T, et al. Nonsurgical correction of congenital auricular deformities in the early neonate: a preliminary report. *Plast Reconstr Surg.* 1984;73:38-51.
- Tan ST, Shibu M, Gault DT. A splint for correction of congenital ear deformities. *Br J Plast Surg.* 1994;47:575-578.
- Doft MA, Goodkind AB, Diamond S, et al. The newborn butterfly project: a shortened treatment protocol for ear molding. *Plast Reconstr Surg.* 2015;135:577e-583e.
- Anstadt EE, Johns DN, Kwok AC, et al. Neonatal ear molding: timing and technique. *Pediatrics.* 2016;137:e20152831.
- Kennedy KL, Katrib Z. Otoplasty. *Plast Reconstr Surg.* 2005;115:60e-72e.
- Prabhu N, MacNevin W, Wheelock M, et al. Understanding child anxiety before otoplasty: A qualitative study. *Int J Pediatr Otorhinolaryngol.* 2020;139:110489.
- Santapuram P, Stone AL, Walden RL, et al. Interventions for parental anxiety in preparation for pediatric surgery: a narrative review. *Children (Basel).* 2021;8:1069.
- Hardingham T, Muir H. The specific interaction of hyaluronic acid with cartilage proteoglycans. *Biochim Biophys Acta.* 1972;279:401-5.
- Hascall V, Heinegård D. Aggregation of cartilage proteoglycans. *J Biol Chem.* 1974;249:4232-41.
- Brown F, Colen L, Addante R, et al. Correction of congenital auricular deformities by splinting in the neonatal period. *Pediatrics.* 1986;78:406-11.
- Chang CS, Bartlett SP. Deformations of the ear and their nonsurgical correction. *Clin Pediatr (Phila).* 2019;58:798-805.
- Matsuo K, Hayashi R, Kiyono M, et al. Nonsurgical correction of congenital auricular deformities. *Clin Plast Surg.* 1990;17:383-395.
- Kurozumi N, Ono S, Ishida H. Non-surgical correction of a congenital lop ear deformity by splinting with Reston foam. *Br J Plast Surg.* 1982;35:181-182.
- Nakajima T, Yoshimura Y, Kami T. Surgical and conservative repair of Stahl's ear. *Aesthetic Plast Surg.* 1984;8:101-107.
- Smith W, Toye J, Reid A, et al. Nonsurgical correction of congenital ear abnormalities in the newborn: case series. *Paediatr Child Health.* 2005;10:327-331.
- Byrd HS, Langevin CJ, Ghidoni LA. Ear molding in newborn infants with auricular deformities. *Plast Reconstr Surg.* 2010;126:1191-1200.