

Immunoexpression of p53 in histologically negative surgical margins adjacent to oral squamous cell carcinoma: A preliminary study

Mamata S Kamat¹, Bhagwan Das Rai², Rudrayya S Puranik³, Uma V Datar⁴

¹PhD Scholar, Faculty of Dental Sciences, Pacific Academy of Higher Education and Research University, ²Department of Oral and Maxillofacial Surgery, Pacific Dental College and Hospital, Udaipur, Rajasthan, ³Department of Oral Pathology and Microbiology, PMNM Dental College and Hospital, Bagalkot, Karnataka, ⁴Department of Oral Pathology, BV(DU) Dental College and Hospital, Sangli, Maharashtra, India

Abstract

The prognostic significance of genetic changes occurring in the histologically negative surgical margins (HNMs) has been focus of various studies recently. Since p53 is the most frequently observed genetic alteration found in oral squamous cell carcinoma (OSCC), we hypothesized that a similar variation might be evident in HNMs as well. Literature is scarce regarding comparison of expression of p53 in the tumor tissue and its adjacent HNMs; hence, the aim of the present study was to study p53 immunoexpression in OSCC and its HNMs. We included 12 paraffin-embedded tissue blocks of OSCC having tumor tissue and HNMs. The samples were subjected to immunohistochemical staining using primary mouse monoclonal antibody against p53, and the stained slides were evaluated for staining intensity and percentage of expression. Descriptive analysis and Chi-square test were applied. The expression of p53 was observed in 66% of HNMs and 91.6% of tumor tissue. The three cases which showed local recurrence demonstrated the expression of p53 in HNM. Hence, molecular analysis of p53 in surgical margins might potentially predict local recurrence of OSCC.

Keywords: Immunohistochemistry, oral squamous cell carcinoma, p53 protein, recurrence, surgical margins

Address for correspondence: Dr. Mamata S Kamat, QRTS No 7, B Block, Bharati Vidyapeeth Medical Campus, Miraj Road, Wanlesswadi, Sangli - 416 416, Maharashtra, India.

E-mail: kmamata@yahoo.com

Submitted: 01-Jan-2019, **Accepted:** 15-Oct-2019, **Published:** 08-May-2020

Complete surgical excision of the tumor proper along with the removal of the surgical margins is the treatment of choice for oral squamous cell carcinoma (OSCC).^[1,2] However, the rate of local recurrence remains high (30%) even though histologically negative surgical margins (HNMs) have been achieved.^[3,4] Hence, molecular evaluation of surgical margins to detect residual cancer cells or a field of genetically altered cells is of paramount importance.^[1] Mutation in p53 gene is an early event in carcinogenesis that can precede clinically evident morphological changes. Thus, its detection in

HNMs may indicate an impending malignancy.^[2] However, till date, literature is lacking regarding the immunoexpression of p53 in HNMs and its comparison with adjacent OSCC. Hence, the aim of the present study was to evaluate the immunoexpression of p53 in OSCC and its HNMs and to correlate it with clinicopathological parameters.

Twelve paraffin-embedded tissue blocks of OSCC containing HNMs were collected from the archives

This is an open access journal, and articles are distributed under the terms of the Creative Commons Attribution-NonCommercial-ShareAlike 4.0 License, which allows others to remix, tweak, and build upon the work non-commercially, as long as appropriate credit is given and the new creations are licensed under the identical terms.

For reprints contact: reprints@medknow.com

How to cite this article: Kamat MS, Rai BD, Puranik RS, Datar UV. Immunoexpression of p53 in histologically negative surgical margins adjacent to oral squamous cell carcinoma: A preliminary study. *J Oral Maxillofac Pathol* 2020;24:184.

Access this article online

Quick Response Code:



Website:

www.jomfp.in

DOI:

10.4103/jomfp.JOMFP_288_19

of the Department of Oncopathology, Karnataka Cancer Therapy and Research Institute, Navanagar, Hubli, Karnataka. HNM was defined as the distance from invasive carcinoma to surgical margin of ≥ 5 mm. Cases affecting the gingivobuccal complex or buccal mucosa classified as T₁/T₂/T₃, N₀/N₁/N₂, M₀ were included. Margins showing evidence of epithelial dysplasia, patients who had received radiotherapy or chemotherapy prior to surgery, histological variants of OSCC and recurrent tumors were excluded. Five micron thick sections from each paraffin-embedded block were subjected to p53 immunostaining (DAKO). The immunohistochemistry stained slides were evaluated based on intensity of staining and number of positively stained cells. In tumor proper, p53 expression was considered positive if nuclear expression was noted in more than or equal to 20 tumor cells. For HNMs, brown staining of nuclei in more than 50 parabasal/suprabasal cells was considered positive. Varying degrees of p53 expression were noted in 11 out of 12 cases (91.6%) of tumor proper [Figure 1a], while one case showed no expression (8.3%). Comparison of p53 expression with clinicopathological parameters is depicted in Table 1. The correlation of p53 immunorexpression with age and habits is depicted in Table 2.

When HNMs were evaluated for immunorexpression, eight cases (66%) expressed p53, whereas four cases were negative for p53. Among the eight HNMs positive for p53, three

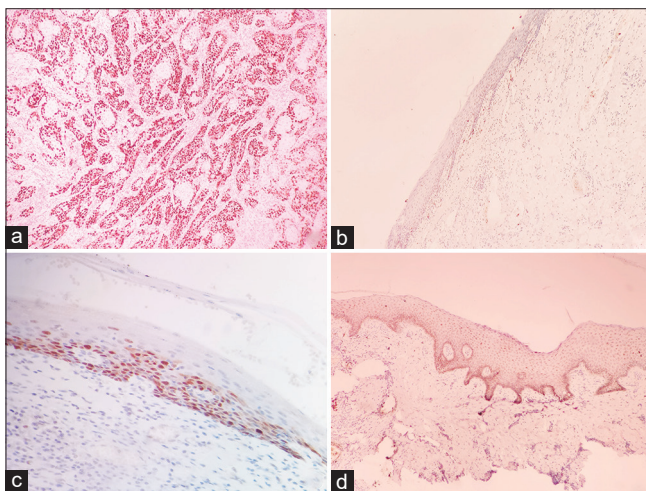


Figure 1: (a) Photomicrograph showing strong p53 expression in oral squamous cell carcinoma tumor tissue (Immunohistochemistry, $\times 10$). (b) Photomicrograph showing immunorexpression of p53 confined to basal cells of histologically negative surgical margin (Immunohistochemistry, $\times 10$). (c) Photomicrograph showing immunorexpression of p53 in basal and parabasal cell layers of histologically negative surgical margin (Immunohistochemistry, $\times 10$). (d) Photomicrograph showing immunorexpression of p53 in the entire thickness of histologically negative surgical margin (Immunohistochemistry, $\times 10$)

cases showed expression only in basal layer [Figure 1b], three in both basal and parabasal layers [Figure 1c], and two cases demonstrated immunoreactivity in the entire thickness of epithelium [Figure 1d]. Interestingly, all three cases with recurrence/death demonstrated overexpression of p53 in HNM.

Most of the patients (9 out of 12), with p53 expression in tumor tissue and HNMs, were >40 years of age and practiced tobacco and alcohol consumption habits [Table 2]. This can be attributed to genetic modifications owing to the long term exposure of carcinogens such as polycyclic aromatic hydrocarbons.^[1] However, the results were statistically insignificant, which might be due to a smaller sample size.

In our study, eight out of 12 cases (66%) showed p53 expression in HNMs. Studies by Singh *et al.*^[5] (54.2%), Bilde *et al.*^[3] (75%), Wang *et al.*^[11] (31%) have also found p53 expression in HNMs. Five out of eight (62.5%) immunopositive HNMs, showed basal and suprabasal p53 staining. Bilde *et al.*^[3] reported similar results in their samples. Immunopositive cells in the tissue adjacent to malignant epithelium represent genetically stressed cells and are early indication of carcinogenesis; thus reflecting field cancerization.^[2]

In the present study, p53 expression was observed in 91.6% of tumor tissue and 66% of HNMs. Except for one case, in all the immunopositive HNMs, the respective tumor tissue also showed p53 Immunorexpression. Bilde *et al.*^[3] reported that, of the 12 HNMs which were immunopositive for p53, seven HNMs had corresponding tumour tissue positive for p53. It has been hypothesized that p53 expressing cells are a part of preneoplastic field that escapes normal growth control gain growth advantage develops an expanding clone ultimately leading to recurrent tumor.^[2]

Negative expression in adjacent tumor in some cases could be due to lack of representative tumor tissue sample, or due to the role of different cell cycle markers involved in the development of cancer. The presence of p53 immunoreaction only in HNM and not in the adjacent tumor, require further research.

However, in a study by Cruz *et al.*^[6,7] all the cases showed p53 immunorexpression in both HNMs and adjacent tumor. They also found that three of the HNMs with suprabasal p53 staining later developed carcinomas.^[6,7] In the present study, recurrence in two patients and death in one patient was noted. Among these three cases, two showed immunoreaction in both HNMs and tumor tissue, and one

Table 1: Comparison of p53 expression with clinicopathological parameters

Case	Age/sex	Habit	Stage	Recurrence	p53 expression	
					HNMs	OSCC
1	50/male	Tobacco + alcohol	T ₃ N ₀ M ₀	Died at 6 months	Para basal	+++
2	28/male	Tobacco	T ₃ N ₁ M ₀	-	-	++
3	34/male	Tobacco + alcohol	T ₂ N _{2b} M ₀	-	Basal	++
4	49/male	Tobacco + alcohol	T ₂ N ₀ M ₀	-	-	+
5	48/male	-	T ₃ N ₀ M ₀	-	-	+
6	38/male	Tobacco + alcohol	T ₃ N ₀ M ₀	-	Para basal+	+++
7	58/male	-	T ₃ N ₁ M ₀	-	Basal	+++
8	55/female	Tobacco	T ₂ N ₀ M ₀	-	-	++
9	52/male	Tobacco + alcohol	T ₂ N ₁ M ₀	-	Basal	+++
10	60/male	Tobacco	T ₂ N _{2b} M ₀	Recurrence at 6 months	Para basal+	-
11	45/male	Tobacco + alcohol	T ₃ N ₁ M ₀	-	Para basal	++
12	65/male	Tobacco + alcohol	T ₃ N ₀ M ₀	Recurrence at 8 months	Para basal	+++

+: 20-40% positively stained nuclei of tumor cells, ++: 41-60% positively stained nuclei of tumor cells, +++: >60% positively stained nuclei of tumor cells. HNMs: Histologically negative surgical margins, OSCC: Oral squamous cell carcinoma

Table 2: Correlation of p53 expression in oral squamous cell carcinoma tumor proper and histologically negative surgical margins with clinicopathological parameters

Clinicopathological parameters	n	p53 in OSCC		P	p53 in HNMs		P
		Positive, n (%)	Negative, n (%)		Positive, n (%)	Negative, n (%)	
Age (years)							
<40	3	3	0	0.50 (NS)	2	1	0.764 (NS)
>40	9	8 (72.72)	1		6	3	
Habit							
No habit	2	2	0	0.833 (NS)	1	1	0.576 (NS)
Habit	10	9 (81.81)	1		7	3	
Recurrence/death							
Yes	3	2	1	0.250 (NS)	3	0	0.255 (NS)
No	9	9	0		5	4	
Total	12	11 (91.6)	1 (8.3)		8 (66)	4 (33)	

P-value obtained by Chi-square test. NS: Not significant, HNMs: Histologically negative surgical margins, OSCC: Oral squamous cell carcinoma

showed p53 expression only in HNMs. This indicates that analysis of molecular nature of the HNMs is of paramount importance to identify the genetically altered fields.

However, it is noteworthy that in spite of the high frequency of immunopositive HNMs, only a few patients developed recurrence. The possible reason could be due to the fact that a large number of patients undergo postoperative radiotherapy and chemotherapy, that eradicate residual cancer cells.^[1,4]

Overall, the results of the present study suggest that besides the gold standard histopathological assessment, the inclusion of "Molecular Status" of HNMs is of value to identify patients at risk of developing recurrence. Future prospective studies with a larger sample size with inclusion of additional margins may be needed to confirm our findings. In addition, combining TP 53 gene analysis by methods like PCR along with p53 protein in HNMs might improve the predictive value of p53 overexpression.

Acknowledgment

The authors would like to thank Karnataka Cancer Therapy and Research Institute, Navanagar, Hubli,

Karnataka, for providing the necessary help. We would also like to thank Dr. Sanjay Navani, Lab Surgpath, Mumbai, for immunohistochemical staining procedures.

Financial support and sponsorship

Nil.

Conflicts of interest

There are no conflicts of interest.

REFERENCES

- Wang X, Chen S, Chen X, Zhang C, Liang X. Tumor-related markers in histologically normal margins correlate with locally recurrent oral squamous cell carcinoma: A retrospective study. *J Oral Pathol Med* 2016;45:83-8.
- Clark DJ, Mao L. Understanding the surgical margin: A Molecular assessment. *Oral Maxillofac Surg Clin North Am* 2017;29:245-58.
- Bilde A, von Buchwald C, Dabelsteen E, Therkildsen MH, Dabelsteen S. Molecular markers in the surgical margin of oral carcinomas. *J Oral Pathol Med* 2009;38:72-8.
- van Houten VM, Leemans CR, Kummer JA, Dijkstra J, Kuik DJ, van den Brekel MW, et al. Molecular diagnosis of surgical margins and local recurrence in head and neck cancer patients: A prospective study. *Clin Cancer Res* 2004;10:3614-20.
- Singh J, Jayaraj R, Baxi S, Mileva M, Skinner J, Dhand NK, et al.

Kamat, *et al.*: p53 in surgical margins

- Immunohistochemical expression levels of p53 and eIF4E markers in histologically negative surgical margins, and their association with the clinical outcome of patients with head and neck squamous cell carcinoma. *Mol Clin Oncol* 2016;4:166-72.
6. Cruz IB, Meijer CJ, Snijders PJ, Snow GB, Walboomers JM, Van Der Waal I. p53 immunoeexpression in non-malignant oral mucosa adjacent to oral squamous cell carcinoma: potential consequences for clinical management. *J Pathol* 2000;191:132-7.
 7. Cruz IB, Snijders PJ, Meijer CJ, Braakhuis BJ, Snow GB, Walboomers JM, *et al.* p53 expression above the basal cell layer in oral mucosa ia an early event of malignant oral squamous cell carcinoma. *J Pathol* 1998;184:360-8.