

CASE REPORT

Bathing Epilepsy: Report of Three Caucasian Cases

Florian Dashi, Arsen Seferi, Arben Rroji, Eugen Enesi, Mentor Petrela

Department of Neurosurgery “Prof Kurti”, University Hospital Center “Mother Theresa”, Tirana, Albania

Corresponding author: Florian Dashi, MD. Rr. Functional Exploration Unit, Department of Neurosurgery, Tirana, Albania. Tel: +355 666 55 6876. E-mail: fdashi76@hotmail.com

ABSTRACT

Introduction: Bathing epilepsy is a specific type of reflex epilepsy triggered by domestic bathing in water. It is a geographically specific epilepsy syndrome that is more prevalent in India Cases in Caucasian population are very rarely reported. These cases share many similar clinical features and a similar prognosis to the Indian cases. **Case report:** We describe three cases of bathing epilepsy in Albanian population; two cases with well controlled seizures and one with drug-resistant seizures.

Key words: epilepsy, case report

1. INTRODUCTION

Bathing epilepsy is a specific type of reflex epilepsy triggered by domestic bathing in water. It is a geographically specific epilepsy syndrome, as it is more prevalent in India (1), which implies a possible genetic predisposition and recognized under the term of “hot water epilepsy.” In the Caucasian population these cases are only rarely reported. But, similar to the Indian patients, they are benign, self-limited, and treatment with monotherapy is generally sufficient to control seizures. We describe three cases of bathing epilepsy: two cases with well-controlled seizures and one with drug-resistant seizures.

2. CASES

Case 1. A 25-year-old woman began having seizures at the age of 8. Seizures would start during bathing with dizziness followed by left arm posturing, rarely progressing to secondary generalization. She had normal development, with no history of trauma, febrile convulsions, or family history of reflex epilepsy. Bathing was eastern-style. She had been treated with carbamazepine 400 mg/day. At the age of 16, seizures abated and medication was stopped. At the age of 24, seizures recurred after three months post-partum, with above symptomatology. Brain CT scan was normal. Interictal EEG was also normal. Carbamazepine was restarted, and seizure freedom followed.

Case 2. A 10-year-old boy began having seizures at the age of 7 during eastern-style baths with hot water. The seizures consisted of staring, oral automatisms, and unresponsiveness, followed in rare occasions by brief tonic posturing of upper extremities, perioral cyanosis, and secondary generalizations. The child had normal psychomotor development, with no history of trauma, febrile convulsions, or family history of epilepsy. He had a normal neurological examination. Interictal EEG demonstrated epileptiform

discharges in the right frontal-anterior temporal region, consisting of spike-wave complexes in brief runs of 1–3 Hz (Figure 1). MRI of the brain was normal. The first suggestion in the management of this patient was to change the style of bathing, with concomitant reduction of water temperature. This resulted in freedom from seizures at two-year follow up.

Case 3. A 13-year-old boy began to present seizures at the age of 8 during bathing (shower or eastern-style bathing), along with nocturnal, generalized tonic-clonic seizures. The seizures occurred with a frequency of 6–7 episodes per month. We evaluated seizures from a recorded video of a typical shower at the age of 12. Seizures started without prodrome or aura. The patient was seen making automatic movements of the bilateral upper limbs associated with important oroalimentary automatisms. Besides that, autonomic phenomena with peri-ictal flushing and peri-ictal pallor were seen to alternate all over the body and face. At the end of the seizure, the patient began to talk confusedly. The seizure stopped with no secondary generalization, and the patient was amnesic of the event. The parent explained that the sei-

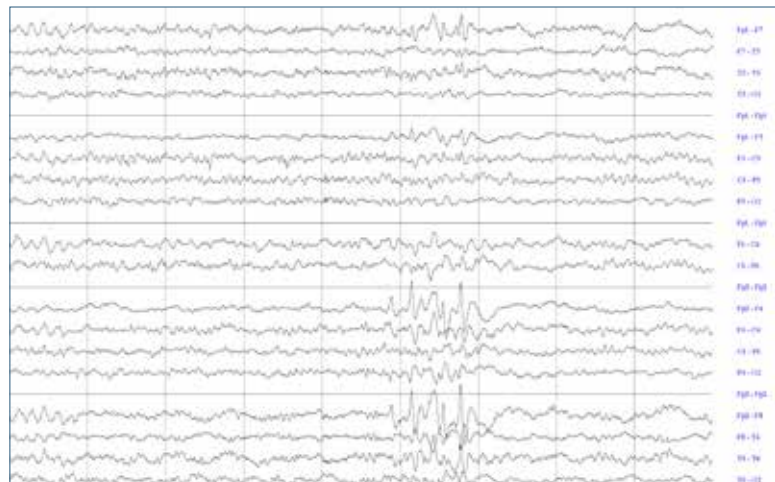


Figure 1. Case 2 – Interictal EEG demonstrating epileptiform discharges in the right fronto-temporal region

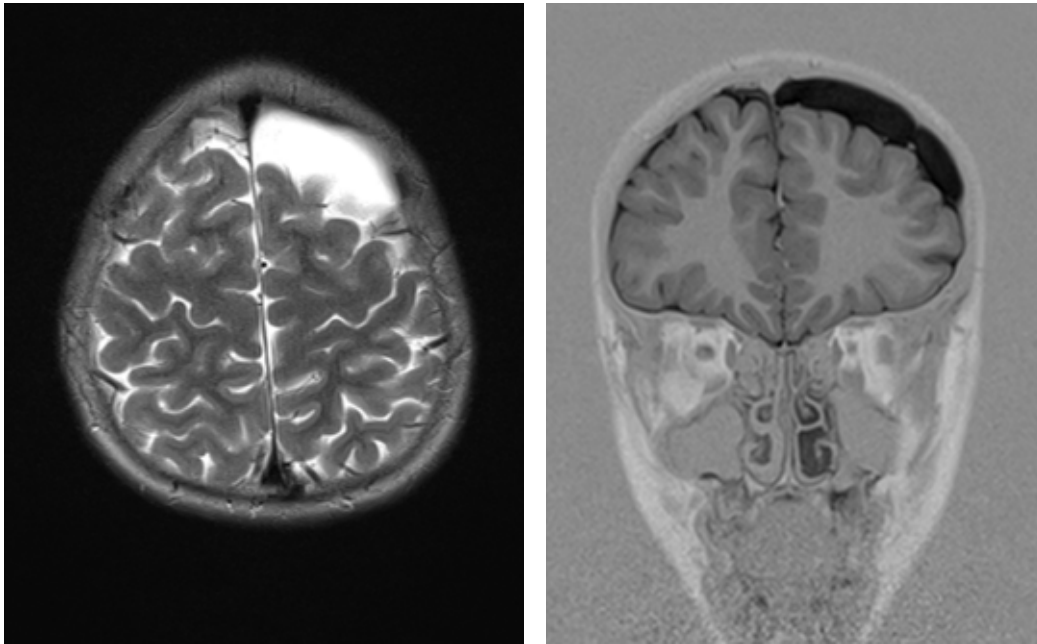


Figure 2. Case 3—Brain MRI demonstrating an arachnoidal cyst over the left frontal lobe

zure would not recur during an ongoing bathing session or until 2–3 days afterwards. The patient had normal development and no history of trauma, febrile convulsions, or family history for epilepsy. Interictal EEG was normal. MRI of the brain revealed a left frontal arachnoidal cyst (Figure 2). The patient was first treated with carbamazepine 600 mg/day. Spontaneous seizures abated, whereas reflex-bathing seizures persisted. Lamotrigine at 250 mg/day was tried, but without efficacy. The patient was switched to levetiracetam 1000 mg/day in monotherapy, but no added efficacy was observed. Valproate 750 mg/day was tried in bitherapy with levetiracetam, but, because of a lack of added efficacy, levetiracetam was withdrawn. Moreover, rectal diazepam did not influence the frequency of seizures during bathing time, nor did changes in bathing style (cloth washing) or lowering of the water temperature.

3. DISCUSSION

Bathing epilepsy is a rare form of reflex epilepsy first described by Allen in 1945 (1, 2). Male predominance in cases is observed. Eastern-style bathing, with hot water poured over the head, has been considered a very potent trigger for these seizures. However, many other triggers have been described in case reports, including water poured over the body at different temperatures, drops of water touching the face or various body parts, and memories linked to bathing or to other sensory stimuli (e.g., odor of the soap, sound of the water) (3, 4).

Both partial and generalized tonic-clonic seizures are related to bathing epilepsy (3). However, complex partial seizures are reported with higher frequency (67–80%) (5). As in many other types of reflex seizures, the same stimulus (hot water) triggers either generalized tonic-clonic or partial seizures, suggesting that generalized and localized epilepsies might be influenced by the same afferent pathways (7, 8, 9, 10). Half of patients may present with spontaneous seizures, which may precede or follow typical reflex seizures by months to years, with an average of 5 years (1).

Interictal EEG and imaging in most cases are normal. When present, abnormalities are mainly localized in the temporoparietal, temporooccipital, and frontotemporal regions, suggesting important involvement of the temporal lobe in the generation of these seizures (1). Ictal EEG has been described in isolated cases. These consisted of focal, unilateral, temporal, and rhythmic slow-wave activity, epileptiform discharges, or unilateral, irregular slow waves over the temporal region (6). Neuroimaging studies are generally normal, though isolated cases have been described with arachnoidal cysts, pineal cysts, cavum septi pellucidi, or epileptogenic lesions, such as focal dysplasia and hippocampal sclerosis (11). Arachnoidal cysts are a relatively common incidental finding on intracranial imaging in pediatric patients. Unless they are large and compress the surrounding structures, these cysts do not cause symptoms, and a relationship with epileptogenic foci has not been demonstrated.

Our first two cases are an example of the generally accepted opinion that bathing or hot water epilepsy is a self-limited condition that is benign and easy-to-treat. Changing bathing habits, lowering the water temperature, and low-dose monotherapy were sufficient to control seizures in both cases. Our third case escapes this generally accepted opinion. Drug-resistant epilepsy is defined as the failure of adequate trials of two tolerated, appropriately chosen, and correctly used antiepileptic drug schedules (whether administered monotherapeutically or in combination) to achieve sustained freedom from seizures (12). Failure to control seizures with changes in bathing style, lowering of water temperature, with trial of two antiepileptic medications in mono- and bitherapy, or with the preventive use of rectal diazepam suggests a drug-resistance that has not yet been described. This raises concern about a probably symptomatic type of bathing epilepsy that might be different in prognosis from the better-known benign, idiopathic type.

CONFLICT OF INTEREST: NONE DECLARED.

REFERENCES

1. Bebek N, Gurses C, Gokyigit A, Baykan B, Ozkara C, Derwent A. Hot water epilepsy: Clinical and electrophysiologic findings based on 21 cases. *Epilepsia*. 2001; 42: 1180-1184.
2. Allen IM. Observations on cases of reflex epilepsy. *N Z. Med*. 1945; 44: 135-142.
3. Lee YC, Yen DJ, Lirng JF, Yiu CH. Epileptic seizures in a patient by immersing his right hand into hot water. *Seizure*. 2000; 9: 605-607.
4. Auvin S, Lamblin MD, Pandit F, Bastos M, Derambure P, Vallee L. Hot water epilepsy occurring at temperature below the core temperature. *Brain Dev*. 2006; 28: 265-268.
5. Satichandra P, Ullal GR, Shankar SK. Hot water epilepsy. In: Zifkin BJ, Andermann F, Beaumanoir A, Rowan AJ. *Reflex epilepsies and reflex seizures: Advances in neurology* (Vol. 75). New York: Raven, 1998: 283-293.
6. Jansen K, Vervisch J, Lagae L. Bathing Epilepsy: A video case of autonomic seizure. *Epileptic disorder*. 2010; 3: 12.
7. Franzoni E, Gentile V, Grosso S, Brunetto D, Cordelli DM, Bal-estri P. Bathing epilepsy: Report of two Caucasian cases. *Epileptic Disord*. 2010; 1: 12.
8. Kowacs PA, Marchioro IJM, da Silva EB, da Rocha SFB, Simão CA, Meneses MS. "Hot-water epilepsy", "warm-water epilepsy" or Bathing epilepsy? Report of three cases and considerations regarding an old theme. *Arq Neuropsiquiatr*. 2005; 63(2-B): 339-401.
9. Argumosa A. Reflex epilepsy from hot water: A new case and review of the literature. *Rev Neurol*. 2002; 35: 349-353.
10. de Keyzer K, Corthouts I, Van Coster R, Verhelst H. Hot-water epilepsy: A new Caucasian case. *Eur J Pediatr*. 2005; 164: 184-185.
11. Tzer FI, Ertas N, Yalcin D, Saygi S. Hot water epilepsy with cerebral lesions: A report of five cases with cranial MRI findings. *Epilepsy Behav*. 2006; 8: 672-676.
12. Kwan P, Arzimanoglou A, Berg AT, Brodie MJ, Allen Hauser W, Mathern G, et al. Definition of drug resistant epilepsy: Consensus proposal by the ad hoc Task Force of the ILAE Commission on Therapeutic Strategies. *Epilepsia*. 2010; 51: 1069-1077.

The screenshot shows the COPE website homepage. At the top, there is a dark navigation bar with the COPE logo and menu items: Home, About COPE, Resources, Cases, Become a member, Members, Events, News & Opinion, and Contact Us. A search bar is located on the right side of the header. Below the header, the main content area features a large heading "Promoting integrity in research publication" and a "Join here" button with the text "What are the benefits of COPE membership?". A social media section shows "Tweet (210)" and "Recommend 310 people recommend this." Below this is a horizontal menu with "All Latest", "Latest Cases", "Latest News", and "Upcoming Events". The main content area is divided into several sections: "NEWS" with a "New Discussion Document" section, "NEWS" with "New guidelines from COPE", "NEWS" with "COPE Forum 10 March 2015 meeting", "NEWS" with "FORUM DISCUSSION TOPIC: Coming back from disgrace", and "NEWS" with "COPE is recruiting for a part-time, freelance Membership...". Below these are four columns: "Resources" with links like "Code of Conduct", "Guidelines", "Sample letters", "Flowcharts", "Discussion documents", and "E-learning"; "Cases" with a search bar and "Find cases by classification"; "eLearning" with a link to "Access the modules here"; and "This month's COPE Digest" with a link to "View this issue". The footer contains "Committee on Publication", "Site map", "Resources", and social media icons for LinkedIn, Facebook, and Twitter.