



# Frequency of hypotonic maculopathy observed by spectral domain optical coherence tomography in post glaucoma filtration surgery eyes

Kunihiro Azuma<sup>a,b</sup>, Hitomi Saito<sup>a,b,\*</sup>, Muneyuki Takao<sup>b</sup>, Makoto Araie<sup>a</sup>

<sup>a</sup> Department of Ophthalmology, Kanto Central Hospital of the Mutual Aid Association of Public School Teachers, Tokyo, Japan

<sup>b</sup> Department of Ophthalmology, University of Tokyo, Graduate School of Medicine, Tokyo, Japan

## ARTICLE INFO

### Keywords:

Glaucoma  
Optical coherence tomography  
Hypotonic maculopathy  
Filtration surgery  
Ocular hypotony

## ABSTRACT

**Purpose:** To report the frequency of post glaucoma filtration surgery hypotonic maculopathy determined by spectral domain optical coherence tomography (SD-OCT).

**Methods:** A cross-sectional retrospective observational study. Post glaucoma filtration surgery patients whose intraocular pressures (IOP) achieved 30% reduction from baseline or was controlled to IOP <14 mm Hg and had SD-OCT images and fundus photographs were enrolled. Hypotonic maculopathy was diagnosed independently on SD-OCT images and on fundus photographs.

**Results:** 112 eyes of 88 patients were included in this study. 17 eyes of 14 patients were diagnosed with hypotonic maculopathy on SD-OCT images (17/112, 15.2%). Among these eyes, only 3 eyes were also diagnosed with hypotony maculopathy on fundus photography. Hypotonic maculopathy on SD-OCT was found only in eyes with IOP ≤10 mm Hg. (17.4% in eyes with IOPs between 7 and 10 mm Hg, and 22.7% in eyes with IOP ≤6 mm Hg). Associations with age, sex, central corneal thickness, refractive error, IOP reduction rate and interval between surgery and OCT acquisition were not significant (P > 0.05).

**Conclusion:** In most cases, hypotonic maculopathy detected by SD-OCT were not recognizable on fundus photographs. Hypotonic maculopathy was detected not only in eyes with conventional ocular hypotony (IOP < 6 mm Hg) but also in eyes with IOP between 7 and 10 mm Hg.

## 1. Introduction

Hypotonic maculopathy is one of the sight-threatening post-glaucoma filtration surgery complications, and is known to occur at low postoperative intraocular pressure (IOP). Clinical features of hypotonic maculopathy are characterized by optic disc edema, vascular tortuosity and chorioretinal folds in the posterior pole.<sup>1,2</sup> Ocular hypotony is usually defined by a statistical criterion of IOP <6.5 mm Hg<sup>3</sup> or as IOP ≤5 mm Hg 3 months or later after glaucoma filtration surgery.<sup>4</sup> Previous studies have reported that hypotonic maculopathy occurs in up to 10% to 35% of eyes with ocular hypotony,<sup>5-7</sup> However, there has been no study that researched the frequency of hypotonic maculopathy in eyes with IOP above 6 mm Hg.

Recently, the development of spectral domain-optical coherence tomography (SD-OCT) has enabled clinicians to detect subtle retinal and choroidal changes,<sup>8</sup> and a few investigators have suggested that hypotonic maculopathy not detected with fundus examination can be detected by the use of SD-OCT. Previous reports employing SD-OCT to

detect hypotonic maculopathy had included only 3 to 8 cases with IOP <6.5 mm Hg<sup>9,10</sup>

The purpose of this study was to investigate the frequency of hypotonic maculopathy observed on SD-OCT images in post glaucoma filtration surgery eyes with well controlled IOP.

## 2. Material and methods

This cross-sectional retrospective observational study followed the tenets of the Declaration of Helsinki and was approved by the institutional review board of Kanto Central Hospital, Tokyo, Japan. We reviewed charts of all patients who received glaucoma filtration surgery (trabeculectomy and ExPress shunt implantation) at our institute between April 2011 and July 2019. All filtration surgeries were performed by one surgeon (M.A.). Limbal based procedures were performed in the filtration surgeries, and large blebs with avascular conjunctiva were common. All patients whose postoperative courses were considered to be clinically successful (30% IOP reduction from baseline and post

\* Corresponding author. Department of Ophthalmology, University of Tokyo, Graduate School of Medicine Hongo 7-3-1, Bunkyo-ku, Tokyo, Japan.

E-mail address: [saitohitomi-oph@umin.ac.jp](mailto:saitohitomi-oph@umin.ac.jp) (H. Saito).

<https://doi.org/10.1016/j.ajoc.2020.100786>

Received 26 March 2020; Received in revised form 1 June 2020; Accepted 5 June 2020

Available online 18 June 2020

2451-9936/© 2020 The Authors.

Published by Elsevier Inc.

This is an open access article under the CC BY-NC-ND license

(<http://creativecommons.org/licenses/by-nc-nd/4.0/>).

operative IOP  $\leq 14$  mm Hg) and with at least one postoperative OCT macula image and fundus photograph (taken on the same day) were enrolled in the study. If there were multiple postoperative SD-OCT images and fundus photographs, images from the closest date from surgery were adopted. All patients in this study had undergone routine ophthalmological examinations including IOP measurement with Goldmann applanation tonometry.

2.1. Optical coherence tomography and fundus photography

All patients underwent macular imaging by the vertical scan protocol using a SD-OCT instrument (3D-OCT 2000, Topcon, Tokyo, Japan). Only SD-OCT images with an image quality score of more than 50 were included, and fundus photographs were taken using a 3D-OCT 2000 built-in fundus camera.

2.2. Diagnosis of hypotonic macular change on SD-OCT images and fundus photographs

All SD-OCT images were independently reviewed and judged by two glaucoma subspecialists (H.S. and K.A.) who were blinded to each other's diagnosis. Hypotonic maculopathy on SD-OCT images was defined as the presentation of macular chorioretinal folds, central macular thickness, and/or macular intra/subretinal fluid observed on the cross sectional retinal images (Fig. 1).<sup>9-12</sup> When there was a disagreement in diagnosis, a senior glaucoma specialist (M.A.) made the final judgement. Hypotony maculopathy on fundus photographs was defined as presentation of optic disc edema, vascular tortuosity and chorioretinal folds in the posterior pole. All fundus photographs were carefully reviewed and judged by an independent retina subspecialist (M.T.) blinded to the SD-OCT findings. We reviewed all OCT images and fundus photographs in the same manner again on a separate day for reproducibility analysis.

2.3. Exclusion criteria

Eyes with any macular diseases were carefully excluded. Eyes with bleb leakage or choroidal detachment at the time of SD-OCT imaging were also excluded.

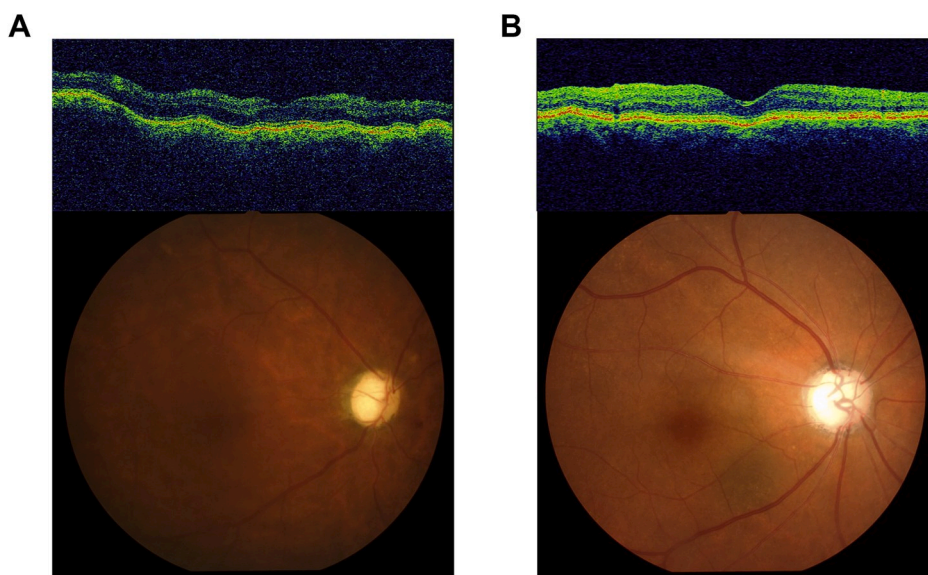


Fig. 1. a) A representative image that was diagnosed as hypotonic maculopathy by both SD-OCT and fundus photograph. (67 years old male). b) A representative image that was diagnosed with hypotonic maculopathy on SD-OCT but not on fundus photographs. (63 years old male). Retinal and subretinal undulation were observed on the SD-OCT image, while no abnormal findings were observed on the fundus photograph. Both images were taken on the same day.

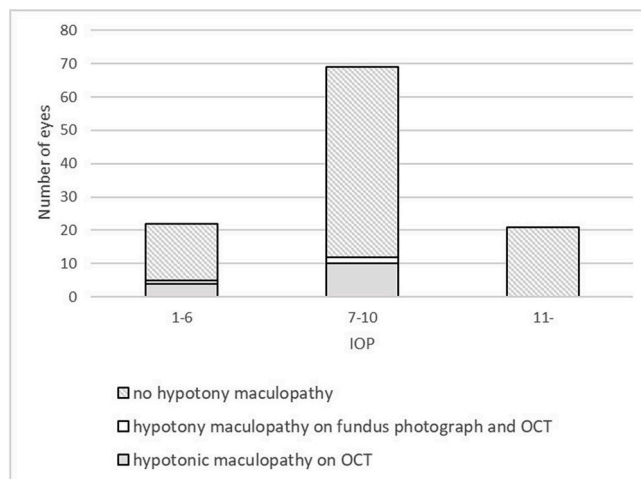


Fig. 2. Histogram demonstrating frequency of hypotonic maculopathy on SD-OCT in each IOP category.

2.4. Statistical analysis

Age, sex, IOP, IOP reduction rate, refractive error, central corneal thickness and interval between surgery and OCT acquisition were investigated as possible related factors. IOP reduction rate was calculated by dividing the IOP at the time of OCT imaging by the preoperative IOP. Preoperative and postoperative best corrective visual acuity (BCVA) were compared between eyes with and without hypotonic maculopathy on SD-OCT. Univariate comparison comparing factors between the two groups were performed using the Mann-Whitney U test. Kappa coefficients were calculated to evaluate diagnosis reproducibility. The threshold IOP for occurrence of hypotonic maculopathy on SD-OCT images was assessed by receiver operating characteristic curve (ROC) analysis. All statistical analysis was performed using R 3.5.2. (The R Foundation for Statistical Computing, Vienna, Austria).

3. Results

112 eyes of 88 patients were included in this study. 6 successful

postsurgical eyes were excluded due to low quality SD-OCT images. Patient demographics are summarized in Table 1. When both eyes of the same subject met the inclusion criteria, both eyes were included in the study. Pearson's correlation coefficients were calculated for IOP and hypotonic macular change on SD-OCT between right and left eyes. The correlation coefficients were very close to 0 (−0.06 and 0.14, respectively), justifying our methodology.

17 eyes of 14 patients were diagnosed with hypotonic maculopathy on SD-OCT images (17/112, 15.2%). Chorioretinal folds including central macular thickening were observed in eyes with maculopathy but no eyes had intra or subretinal fluid. Reproducibility of hypotonic maculopathy detection on OCT images and fundus photographs between the two observers (KA, HS) were both satisfactory (Kappa = 0.963, Kappa = 1, respectively). 3 eyes (2 eyes with IOP <6.5 mm Hg, 1 eye with 7 < IOP <10) presented hypotony maculopathy on fundus photographs, and all 3 of these eyes also presented macular changes on OCT images.

22 eyes of 20 patients of our current study met the criteria of statistical ocular hypotony of IOP <6.5 mm Hg, and 5 eyes from this group were diagnosed with hypotonic maculopathy upon OCT images (5/22, 22.7%). 69 eyes of 57 patients had IOPs between 7 mm Hg and 10 mm Hg. 12 eyes from this group were diagnosed with hypotonic maculopathy upon SD-OCT images (12/69, 17.4%). Of the 21 eyes of 18 patients with IOP ≥11 mm Hg, none presented hypotonic maculopathy on either SD-OCT images or fundus photographs (Fig. 2). An IOP of 10 mm Hg was chosen as the threshold for occurrence of hypotonic maculopathy by ROC analysis (Fig. 3).

Since no hypotonic maculopathy was observed in eyes with IOP over 11 mm Hg, we analyzed possible related factors in eyes with IOP ≤10 mm Hg. There was no significant difference in age, sex, IOP at the time of OCT imaging, IOP reduction rate, CCT, and interval between surgery and OCT acquisition between the two groups. (Table 2, all P > 0.05, Mann-Whitney U test) Preoperative BCVA or postoperative BCVA were not statistically different between the two groups either.

4. Discussion

Past reports on OCT observed hypotonic macular changes were all small scale studies on eyes with IOP <6.5 mmHg. Budenz et al. reported 3 eyes with IOP ≤6.5 mm Hg in which chorioretinal folds were found on OCT images but not on fundus photographs.<sup>9</sup> Lima et al. reported that in

Table 1 Patient demographics.

Baseline characteristics	Mean ± SD
Age (years old)	66.2 ± 12.5
Male/Female	43/45
Preoperative IOP (mm Hg)	18.1 ± 5.7
Postoperative IOP (mmHg)	8.5 ± 2.7
Axial length (mm)	24.94 ± 1.87
Spherical equivalent (D)	−4.07 ± 3.80
Best corrected visual acuity (logMAR)	0.40 ± 0.43
Central corneal thickness (µm)	519.2 ± 41.1
Mean interval between surgery and SD-OCT acquisition (days)	638 ± 772
Surgery procedure	
Filtering Surgery (trabeculectomy)	106
Filtering Surgery (ExPress)	6
Glaucoma Subtype	
POAG	61
NTG	37
XFG	6
SOAG	5
Congenital	2
CACG	1

SD; standard deviation, IOP; intraocular pressure, POAG; primary open angle glaucoma, NTG; normal tension glaucoma, XFG; pseudoexfoliative glaucoma, SOAG; secondary open angle glaucoma, CACG; chronic closure angle glaucoma.

Table 2 Comparisons of parameters between eyes with and without hypotony maculopathy.

	hypotony maculopathy (n = 14)	No hypotony maculopathy (n = 56)	p-value <sup>a</sup>
	Mean ± SD	Mean ± SD	
Age (year)	69.9 ± 10.0	63.9 ± 13.9	p = 0.2
Male/Female	8/6	30/26	p = 0.58
Mean interval between surgery and SD-OCT acquisition (days)	464 ± 607	686 ± 810	p = 0.46
IOP (mm Hg)	7.4 ± 2.2	7.8 ± 1.9	p = 0.6
IOP reduction rate	0.57 ± 0.12	0.55 ± 0.17	p = 0.69
Spherical equivalence (D)	−2.30 ± 5.36	−5.18 ± 4.19	p = 0.054
CCT (µm)	509.4 ± 33.1	515.3 ± 39.9	p = 0.5
Preoperative BCVA	0.12 ± 0.31	0.18 ± 0.35	p = 0.26
Postoperative BCVA	0.32 ± 0.43	0.44 ± 0.44	p = 0.18

SD; standard deviation, IOP; intraocular pressure, CCT; central corneal thickness, BCVA; best corrected visual acuity.

<sup>a</sup> Mann-Whitney U test.

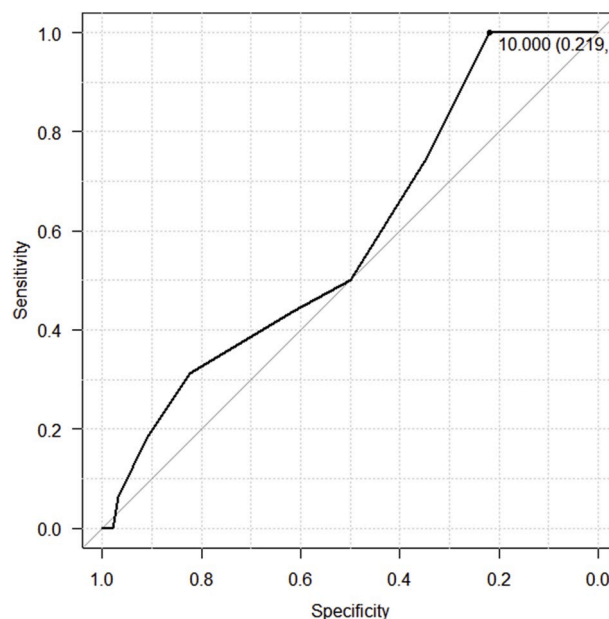


Fig. 3. Receiver operating characteristic curve (ROC) analysis of the relationship between IOP and occurrence of hypotonic maculopathy on SD-OCT. IOP of 10 mm Hg was chosen as the threshold.

14 eyes with IOP ≤6 mm Hg, chorioretinal folds were found in 8 eyes by OCT images.<sup>10</sup> To the best of our knowledge, this is the first report of frequency of hypotonic maculopathy detected by OCT in a larger number of eyes and in eyes with a wider range of postoperative IOP.

Only 3 of the 21 eyes presenting hypotonic maculopathy on OCT images were diagnosed on fundus photographs. This demonstrated that SD-OCT can help us to detect more subtle hypotonic maculopathies that are difficult to diagnose on fundus photographs.

The frequency of hypotonic maculopathy in eyes with statistical ocular hypotony (IOP ≤ 6.5 mm Hg) was 22.7% (5/22) in our study. Furthermore, in our current study, we discovered that 17.4% (12/69) of eyes with post-operative IOP higher than 7 mm Hg also had hypotonic maculopathy determined by SD-OCT, suggesting that some eyes may

develop hypotonic maculopathy at IOPs higher than statistical ocular hypotony. However, no hypotonic maculopathy was observed in eyes with IOP  $\geq 11$  mm Hg. Results of our ROC analysis suggests that an IOP of 10 mm Hg, which is higher than the conventional definition of ocular hypotony, may be the threshold IOP for hypotonic maculopathy. Furthermore, hypotonic maculopathy seems to have occurred independently from IOP in postoperative IOPs lower than 10 mmHg. Tseng et al. noted their observation of some eyes with IOP  $>6$  mm Hg that demonstrated hypotonic maculopathy on OCT.<sup>6</sup> However, to the best of our knowledge, this is the first report that investigated the frequency of hypotonic maculopathy in eyes with IOP higher than the conventional statistical criteria of hypotony.

In this study, we were not able to find any factors that were significantly correlated to the presentation of hypotonic maculopathy on SD-OCT, although previous reports myopia and young age were associated with hypotonic maculopathy.<sup>5,7,13</sup> This may have been due to the small number of eyes with hypotonic maculopathy in this study and/or the selection biases upon enrolling patients in the study. Some articles also reported that hypotonic maculopathy affects visual function.<sup>9,10</sup> However, we found no significant difference in BCVA in this study. This is most likely because post filtration surgery vision loss can occur from several reasons (cataract, astigmatism etc.) other than hypotonic maculopathy and the results may have been masked in our study. Also, we were looking at more subtle maculopathy than conventional fundoscopically diagnosed maculopathy and the visual acuity change may have been too small to detect.

We acknowledge that there are several limitations to this study. First, the frequency found in our study is not the true incidence rate of hypotonic maculopathy determined by SD-OCT because eyes that developed hypotonic maculopathy but did not undergo OCT imaging at that time may have been overlooked due to the varied timing of OCT acquisition. However, SD-OCT images in post surgical eyes were taken routinely in our hospital and we found no significant difference in the interval between surgery and OCT acquisition between eyes with and without hypotonic maculopathy. Second, our diagnosis of hypotonic macular changes on SD-OCT images and hypotony maculopathy on fundus photographs was subjective. However, this was inevitable since there is no objective diagnostic criteria. Third, in this study, preoperative IOP of 18.1 mm Hg was relatively lower than previous reports. This may have affected the frequency of hypotony maculopathy in this study.

## 5. Conclusions and importance

In conclusion we observed a higher frequency of hypotonic maculopathy on OCT images when compared to fundus photographs. Hypotonic maculopathy was observed not only in eyes with statistical hypotony but also in eyes with higher IOP. Our results indicate that the occurrence of hypotonic maculopathy may be higher than conventionally believed, and SD-OCT imaging in post glaucoma filtration surgery eyes with hypotony may be able to detect changes that are otherwise missed.

## Patient consent

This retrospective observational study was approved by the

institutional review board of Kanto Central Hospital, Tokyo, Japan.

## Funding

No funding or grant support

## Authorship

All authors attest that they meet the current ICMJE criteria for Authorship.

## Declaration of competing interest

The following authors have no financial disclosures: KA, HS, MT, MA.

## CRedit authorship contribution statement

**Kunihiro Azuma:** Investigation, Formal analysis, Writing - original draft. **Hitomi Saito:** Conceptualization, Methodology, Formal analysis, Investigation, Writing - review & editing. **Muneyuki Takao:** Formal analysis, Supervision. **Makoto Araie:** Writing - review & editing, Supervision.

## Acknowledgements

The authors would like to thank Tomoko Aoki, Rieko Obata, Risako Yamamoto and Koichi Mishima for assisting data acquisition.

## References

- Gass J. *Contemporary Ophthalmology . Honoring Sir Stewart Duke-Elder*. Baltimore: Williams & Wilkins; 1972:343–366.
- Costa VP, Arcieri ES. Hypotony maculopathy. *Acta Ophthalmol Scand*. 2007 Jun;85(6):586–597.
- Pedersen J. *The Glaucoma*. second ed. St. Louis, MO: Mosby; 1996:385–395.
- Gedde SJ, Schiffman JC, Feuer WJ, Parrish RK, Heuer DK, Brandt JD. The tube versus trabeculectomy study: design and baseline characteristics of study patients. *Am J Ophthalmol*. 2005 Aug;140(2):275–287.
- Fannin LA, Schiffman JC, Budenz DL. Risk factors for hypotony maculopathy. *Ophthalmology*. 2003 Sep;110(6):1185–1191.
- Tseng VL, Kim CH, Romero PT, et al. Risk factors and long-term outcomes in patients with low intraocular pressure after trabeculectomy. *Ophthalmology*. 2017 Oct;124(10):1457–1465.
- Saeedi OJ, Jefferys JL, Solus JF, Jampel HD, Quigley HA. Risk factors for adverse consequences of low intraocular pressure after trabeculectomy. *J Glaucoma*. 2014 Aug;23(1):e60–e68.
- Schuman J, Puliafito C, Fujimoto J. *Optical Coherence Tomography of Ocular Diseases*. third ed. Thorofare, NJ: Slack Inc; 2013:1–640.
- Budenz DL, Schwartz K, Gedde SJ. Occult hypotony maculopathy diagnosed with optical coherence tomography. *Arch Ophthalmol*. 2005 Jan;123(1):113–114.
- Lima VC, Prata TS, Castro DPE, et al. Macular changes detected by Fourier-domain optical coherence tomography in patients with hypotony without clinical maculopathy. *Acta Ophthalmol*. 2011 Jul;89(3):e274–e277.
- Giuffrè G, Distefano MG. Optical coherence tomography of chorioretinal and choroidal folds. *Acta Ophthalmol Scand*. 2006 Jul;85(3):333–336.
- Lee R, Ameri H. Hypotony maculopathy: a silent mimicker of common macular diseases with nonspecific optical coherence tomography findings. *J VitreoRetinal Dis*. 2018 Apr;2(3):155–159.
- Bindlish R, Condon GP, Schlosser JD, D'Antonio J, Lauer KB, Lehrer R. Efficacy and safety of mitomycin-C in primary trabeculectomy. *Ophthalmology*. 2002 Jul;109(7):1336–1341.