

RESEARCH ARTICLE

Loss of corneal nerves and brain volume in mild cognitive impairment and dementia

Georgios Ponirakis¹ | Hanadi Al Hamad² | Adnan Khan¹ | Ioannis N. Petropoulos¹ | Hoda Gad¹ | Mani Chandran² | Ahmed Elstouhy^{1,3} | Marwan Ramadan² | Priya V. Gawhale² | Marwa Elorrabi² | Masharig Gadelseed² | Rhia Tosino² | Anjum Arasn² | Pravija Manikoth² | Yasmin H.M. Abdelrahim² | Mahmoud A Refaee² | Noushad Thodi⁴ | Surjith Vattoth⁵ | Hamad Almuhammad¹ | Ziyad R. Mahfoud¹ | Harun Bhat¹ | Ahmed Own³ | Ashfaq Shuaib⁶ | Rayaz A. Malik^{1,7,8}

¹ Department of Medicine, Weill Cornell Medicine-Qatar, Qatar Foundation, Doha, Qatar

² Geriatric & Memory Clinic, Rumailah Hospital, Hamad Medical Corporation, Doha, Qatar

³ Neuroradiology, Hamad General Hospital, Hamad Medical Corporation, Doha, Qatar

⁴ MRI Unit, Rumailah Hospital, Hamad Medical Corporation, Doha, Qatar

⁵ Radiology, University of Arkansas for Medical Sciences, Arkansas, USA

⁶ Department of Medicine, University of Alberta, Alberta, Canada

⁷ Faculty of Biology, Medicine and Health, University of Manchester, Manchester, UK

⁸ Faculty of Science and Engineering, Manchester Metropolitan University, Manchester, UK

Correspondence

Rayaz A. Malik, Weill Cornell Medicine-Qatar, Qatar Foundation, Education City, Doha, Qatar.
Email: ram2045@qatar-med.cornell.edu

Funding information

Qatar National Research Fund, Grant/Award Numbers: BMRP-5726113101, NPRP125-0213-190080

Abstract

Introduction: This study compared the capability of corneal confocal microscopy (CCM) with magnetic resonance imaging (MRI) brain volumetry for the diagnosis of mild cognitive impairment (MCI) and dementia.

Methods: In this cross-sectional study, participants with no cognitive impairment (NCI), MCI, and dementia underwent assessment of Montreal Cognitive Assessment (MoCA), MRI brain volumetry, and CCM.

Results: Two hundred eight participants with NCI (n = 42), MCI (n = 98), and dementia (n = 68) of comparable age and gender were studied. For MCI, the area under the curve (AUC) of CCM (76% to 81%), was higher than brain volumetry (52% to 70%). For dementia, the AUC of CCM (77% to 85%), was comparable to brain volumetry (69% to 93%). Corneal nerve fiber density, length, branch density, whole brain, hippocampus, cortical gray matter, thalamus, amygdala, and ventricle volumes were associated with cognitive impairment after adjustment for confounders (All *P*'s < .01).

Discussion: The diagnostic capability of CCM compared to brain volumetry is higher for identifying MCI and comparable for dementia, and abnormalities in both modalities are associated with cognitive impairment.

KEYWORDS

brain volumetry, corneal confocal microscopy, dementia, mild cognitive impairment, neurodegeneration

This is an open access article under the terms of the [Creative Commons Attribution-NonCommercial](https://creativecommons.org/licenses/by-nc/4.0/) License, which permits use, distribution and reproduction in any medium, provided the original work is properly cited and is not used for commercial purposes.

© 2022 The Authors. *Alzheimer's & Dementia: Diagnosis, Assessment & Disease Monitoring* published by Wiley Periodicals, LLC on behalf of Alzheimer's Association

RESEARCH IN CONTEXT

- 1. Systematic Review:** We searched PubMed and Google Scholar with the terms dementia, neurodegeneration, biomarker, and magnetic resonance imaging (MRI) brain for studies published in the English language from database inception to April 25, 2021. We identified a need for non-invasive and reliable biomarkers of neurodegeneration for mild cognitive impairment (MCI) and dementia. The diagnostic capability of corneal confocal microscopy (CCM) an ophthalmic marker of neurodegeneration for MCI and dementia has not been tested against MRI brain volumetry.
- 2. Interpretation:** Compared to MRI brain volumetry, the diagnostic capability of CCM is higher for identifying people with MCI and comparable for dementia.
- 3. Future directions:** Longitudinal studies are required to compare the capability of CCM and MRI brain volumetry for predicting progression of individuals with MCI to dementia.

1 | INTRODUCTION

Dementia is a progressive neurodegenerative disease affecting 40 to 50 million people worldwide.^{1,2} Therapeutic and psychological interventions for people with early stage dementia can improve cognition, independence, and quality of life.³ However, dementia is an insidious disease, and it is therefore important to establish biomarkers that provide direct or indirect evidence of the underlying pathology in the asymptomatic stages.⁴ The National Institute on Aging–Alzheimer's Association (NIA-AA) has proposed that diagnostic biomarkers of Alzheimer's disease (AD) should include amyloid beta (A β) and tau alongside biomarkers of neurodegeneration to stage the severity of the disease.⁵ The “*diagnostic accelerator program*” call from the Alzheimer's Drug Discovery Foundation has targeted the need for accurate, reliable, and non-invasive biomarkers that identify mild cognitive impairment (MCI) and predict the development of dementia.

Structural neuroimaging is an established method to identify neurodegeneration in AD.^{4,6} Studies employing magnetic resonance imaging (MRI) brain volumetry have shown progressive brain atrophy in people with MCI and dementia compared to people with no cognitive impairment (NCI).^{7,8} Visual rating of medial temporal lobe atrophy can differentiate probable⁹ and established AD from NCI^{10,11} and between amnesic and non-amnesic MCI.¹² The rate of hippocampal atrophy may also identify people with MCI who are at risk of developing dementia.^{13,14}

Corneal confocal microscopy (CCM) is a rapid noninvasive ophthalmic imaging technique that allows objective quantification of corneal nerve fiber morphology.^{15–18} It has been used to identify neurodegeneration in diabetic neuropathy,^{19–21} HIV neuropathy,²²

Friedreich ataxia,²³ multiple sclerosis,^{24,25} and Parkinson disease.^{26–28} More recently, we have shown that corneal nerve loss is associated with the severity of cognitive impairment and functional independence in people with MCI and dementia.^{29,30}

The primary objective of this study was to compare the diagnostic accuracy of CCM to brain volumetry for distinguishing patients with MCI and dementia from people with NCI. The secondary objective was to assess the association of corneal nerve morphometry and MRI brain volumetry with cognitive function in MCI and dementia.

2 | METHODS

Subjects with MCI, dementia—including AD, vascular dementia (VaD), and mixed AD—and no cognitive impairment (NCI) 60 to 85 years of age were recruited from the geriatric and memory clinic in Rumailah Hospital, Doha, Qatar between September 18, 2016 and February 9, 2020. We excluded subjects with reversible cognitive impairment, complex and young-onset dementia, severe dementia, frontotemporal dementia, Lewy body dementia, Parkinson disease, severe anxiety, severe depression, mood disorders, psychosis, hypomania, peripheral neuropathy including severe vitamin B₁₂ deficiency, hypothyroidism, HIV infection, and hepatitis C. We also excluded subjects with severe dry eye, corneal dystrophies, ocular trauma, or surgery in the preceding 12 months, and subjects who were unable to cooperate during the assessments. A history of severe dry eye was obtained by reviewing the medical records and direct interview with the participant. Dry eye assessment was not performed in the study. Diabetes is highly prevalent in patients 50 years of age or older in Qatar³¹ and is a common comorbidity in VaD and mixed dementia and was not excluded.

This study was approved by the institutional review board of Weill Cornell Medicine in Qatar and Hamad Medical Corporation, and all participants gave informed consent to take part in the study. The research adhered to the tenets of the Declaration of Helsinki.

2.1 | Demographic and metabolic measures

Age, gender, blood pressure, body weight, body mass index (BMI), hemoglobin A1c (HbA1c), cholesterol, triglycerides, hemoglobin, mean corpuscular volume (MCV), vitamin B₁₂, thyroid-stimulating hormone (TSH), free thyroxine (FT4), and medical history were recorded from the electronic medical register (Cerner).

2.2 | Cognitive function assessment

Cognitive function was assessed using the Montreal Cognitive Assessment (MoCA) basic test, version 7.1, which includes seven cognitive domains including visuospatial/executive, naming, memory, attention, language, abstraction, and delayed recall, with a score of $\leq 26/30$ indicating cognitive impairment.³² An extra point was added for individuals who were illiterate or had only attended primary school, as it was

suggested in the original validation study that an extra point should be added to the total score if the individual had ≤ 12 years of education. The duration of cognitive dysfunction was recorded from the patient's medical history.

2.3 | Diagnosis

The diagnosis of MCI and dementia, including AD, VaD, and mixed AD, was based on the International Classification of Diseases, Tenth Revision (ICD-10) criteria.³³ A consensus diagnosis was reached by geriatricians, geriatric psychiatrists, and neurologists based on a comprehensive history of cognitive impairment, psychiatric history, medical history including episodes of delirium and other medical comorbidities, medication history, and functional history of basic daily living activities. MRI brain was undertaken to exclude potentially reversible causes of cognitive decline such as brain tumors, subdural hematoma, or normal-pressure hydrocephalus.

The diagnosis of AD was based on typical features of AD such as atrophy in hippocampi, entorhinal cortex, and amygdala on MRI and no significant decline in functioning. Brain atrophy was assessed by neuro-radiologists using the criteria of Dubois et al³⁴ blinded to the diagnosis and clinical data.

The diagnosis of probable or possible VaD was based on the National Institute of Neurological Disorders and Stroke-Association Internationale pour la Recherche et l'Enseignement en Neurosciences (NINDS-AIREN) criteria,³⁵ which includes multiple large vessel infarcts or a single strategically placed infarct in the angular gyrus, thalamus, basal forebrain, or posterior (PCA) or anterior cerebral artery (ACA) territories, and multiple basal ganglia and white matter lacunes, extensive periventricular white matter lesions, or combinations thereof.

The diagnosis of mixed dementia was based on the presence of AD and significant vascular changes.

2.4 | MRI brain acquisition

MRI was performed on a 3T MRI system (MAGNETOM Skyra, Siemens AG, Erlangen). A T1-weighted three-dimensional (3D) magnetization prepared rapid acquisition gradient echo sequence (MPRAGE) was obtained in the sagittal plane with a 1 mm slice thickness, repetition time of 1900 ms, echo time of 2.67 ms and 2.46 ms, inversion time of 1100 ms and 900 ms, flip angle of 9 degrees and 15 degrees, and field of view (FOV) of 240 × 100. Coronal and axial reformatted MPRAGE images were made from the sagittal 3D sequence.

2.5 | Brain volume analysis

MRI brain volumetry was undertaken on a T1-weighted 3D MPRAGE sequence using NeuroQuant (NQ), a US Food and Drug Administration (FDA)-approved fully automated software.^{36,37} The brain volume was adjusted for the percentage of intracranial volume (ICV), which includes all segmented structures to minimize the impact of the

head size as a confounding factor. This study focused on 12 different brain structures, including the ICV percentage of the hippocampus, whole brain, ventricle, cortical gray matter, entorhinal cortex, thalamus, amygdala, cingulate gyrus, and frontal, temporal, parietal, and occipital lobes.

2.6 | Corneal confocal microscopy

CCM analysis was performed with the Heidelberg Retinal Tomograph III (HRT-3) Rostock Cornea Module (Heidelberg Engineering GmbH, Heidelberg, Germany). The cornea was locally anesthetized by instilling one drop of 0.4% benoxinate hydrochloride (Chauvin Pharmaceuticals, Chefaro, UK). Viscotears (Carbomer 980, 0.2%, Novartis, UK) was used as the coupling agent between the cornea and the TomoCap as well as between the TomoCap and the objective lens. Subjects were instructed to fixate on a target with the eye not being examined. Several scans of the sub-basal nerve plexus in the central cornea were captured per eye for ≈ 2 minutes. At a separate time, three high-clarity non-overlapping images per eye were selected based on depth, focus position, and contrast, as described previously¹⁶⁻¹⁸ by one investigator who was blinded from the diagnosis, cognitive function, and MRI brain volumetry. To ensure that the selected images were representative, an image with low-, medium-, and high-fiber density was selected from a different location within the central corneal region. The mean corneal nerve fiber density (CNFD, fibers/mm²), branch density (CNBD, branches/mm²), and fiber length (CNFL, total fiber length mm/mm²) were measured manually using CCMetrics.¹⁵

2.7 | Peripheral neuropathy assessment

Vibration perception threshold (VPT) was assessed using a Neurothesiometer (Horwell Scientific Laboratory Supplies) on the pulp of the large toe on both feet, and the average value of three measurements was recorded as a VPT in volts (V) ranging from 0 to 50 V.

2.8 | Sample size calculation

Based on our previous study,³⁰ the smallest effect size between the two groups (MCI and dementia) and the NCI group was 0.85 for CNFD, 0.75 for CNBD, and 0.90 for CNFL. For an 80% power and 2.5% significance level to account for at least two comparisons the sample size would be 34 per arm.

2.9 | Statistical analysis

Patient demographics and clinical characteristics were summarized using the mean and SD for numeric variables and frequency distribution for categorical variables. Variables were compared between the NCI, MCI, and dementia group using one-way analysis of variance

(ANOVA) with Bonferroni post hoc test for pairwise comparisons and chi-square test, respectively.

Univariate analysis by simple linear regression was performed with CCM measures and confounding factors as independent variables and cognitive function or brain volumetric MRI as the dependent variable. Multiple linear regression analysis included all variables with $P \leq .05$ at the bivariate level. The regression coefficient (beta) and the corresponding 95% confidence intervals (95% CIs) are presented.

Receiver-operating characteristic (ROC) curve analysis was used to determine the ability of CNFD, CNBD, CNFL, volume of hippocampus, whole brain, ventricle, cortical gray matter, thalamus, amygdala, entorhinal cortex, and frontal and temporal lobe to distinguish between subjects with MCI or dementia from subjects with NCI. The area under the ROC curve (AUC) and a cut-off point with the maximal sensitivity and specificity were calculated.

All analyses were performed using IBM-SPSS (version 26; SPSS Inc, Armonk, NY, USA). A two-tailed P value of $\leq .05$ was considered statistically significant.

3 | RESULTS

3.1 | Demographic and clinical characteristics

Of the 208 subjects studied, those with no cognitive impairment (NCI) ($n = 42$), mild cognitive impairment (MCI) ($n = 98$), and dementia ($n = 68$) had a comparable mean age (70.8 ± 6.2 vs 71.2 ± 5.9 vs 73.4 ± 5.8 , $P = .06$), gender (females: 31.0% vs 39.8% vs 41.2%, $P = .53$), and prevalence of type 2 diabetes (T2D) (69.0% vs 58.2% vs 64.7%, $P = .43$), respectively. The dementia group was comprised of pure Alzheimer's disease (or AD) (32.2%), vascular dementia (VaD) (23.7%), and mixed AD with vascular lesions (44.1%). Systolic blood pressure (SBP), diastolic blood pressure (DBP), body weight, BMI, HbA1c, cholesterol, triglycerides, and MCV were comparable between the groups (Table 1).

The MoCA score was lower in the MCI (22.0 ± 5.8 , $P < .0001$) and dementia (13.0 ± 5.9 , $P < .0001$) group compared to the NCI group (27.6 ± 3.8) (Table 1). The mean duration of cognitive impairment was significantly longer in the dementia (3.1 ± 2.7 years) compared to the MCI (1.6 ± 2.1 years) group, $P < .0001$.

All subjects completed the assessment without expressing any concerns about the eye drop or contact of the cornea with the CCM TomoCap. There was a reduction in corneal nerve fibers in subjects with MCI and dementia compared to subjects with NCI (Figure 1). Compared to those with NCI corneal nerve fiber density (CNFD, fibers/mm²) (31.9 ± 7.4 vs 24.0 ± 9.3 and 20.1 ± 8.3 , $P \leq .0001$), branch density (CNBD, branches/mm²) (86.4 ± 44.9 vs 52.9 ± 35.8 and 46.1 ± 27.0 , $P \leq .0001$) and length (CNFL, mm/mm²) (22.5 ± 6.0 vs 16.5 ± 6.5 and 14.7 ± 5.8 , $P \leq .0001$) were significantly lower in subjects with MCI and dementia (Table 1). After excluding those with diabetes, compared to those with NCI ($n = 13$), CNFD (35.3 ± 5.6 vs 26.0 ± 9.1 and 21.4 ± 7.7 fibers/mm², $P = .001$ -.0001), CNBD (95.2 ± 49.2 vs

57.3 ± 38.2 and 52.8 ± 26.5 branches/mm², $P = .002$ -.001), and CNFL (24.7 ± 4.5 vs 17.7 ± 6.8 and 15.9 ± 4.8 mm/mm², $P \leq .0001$) remained significantly lower in subjects with MCI ($n = 41$) and dementia ($n = 24$). CNFD ($P = .66$), CNBD ($P = .40$), and CNFL ($P = .43$) were comparable between those with pure AD, VaD, and mixed AD with vascular lesions.

Vibration perception threshold (VPT) on the feet was significantly higher in subjects with dementia ($P \leq .0001$) but not in those with MCI compared to subjects with NCI (17.3 ± 9.4 vs 11.4 ± 8.4 , $P = .07$) and comparable between subjects with MCI and dementia (17.3 ± 9.4 vs 21.2 ± 10.6 , $P = .16$).

The volume of the whole brain (73.1 ± 2.8 vs 70.8 ± 3.5 vs 67.6 ± 2.9 , $P \leq .0001$) and hippocampus (0.46 ± 0.05 vs 0.42 ± 0.08 vs 0.34 ± 0.08 , $P \leq .0001$) were lower in MCI and dementia groups compared to NCI (Table 1). The volume of cortical gray matter ($P \leq .0001$) and amygdala ($P < .01$) was lower and ventricle volume was larger in subjects with dementia compared to NCI, but there was no difference between MCI and NCI. The volume of the entorhinal cortex ($P < .05$), thalamus ($P = .01$), and frontal ($P < .05$) and temporal lobes ($P = .001$) was significantly lower in subjects with dementia compared to MCI but was comparable between MCI and NCI. There was no significant difference in the volume of the parietal lobe, occipital lobe, or cingulate gyrus between subjects with MCI and dementia.

3.2 | Diagnostic accuracy for distinguishing MCI from NCI

Table 2 and Figure 2 show the diagnostic accuracy of CCM measures and brain volumetry for identifying subjects with MCI and dementia. CNFL distinguished subjects with MCI from NCI with 81% AUC (95% CI 71-91%). Using an CNFL cutoff of ≤ 21 mm/mm² the sensitivity and specificity were 80% and 76%, respectively. CNFD, CNBD, MoCA score, volume of whole brain, ventricle, and hippocampi showed an AUC ranging from 63% to 79%. The volume of the cortical gray matter, frontal, temporal, parietal, occipital lobe, entorhinal cortex, thalamus, amygdala, and cingulate gyrus could not distinguish MCI from NCI.

3.3 | Diagnostic accuracy for distinguishing dementia from NCI

Measures to distinguish dementia from NCI with $\geq 80\%$ AUC were: CNFD (AUC: 85%, 95% CI 75-95%), CNFL (AUC: 84%, 95% CI 73-95%), whole brain (AUC: 93%, 95% CI 85-100%), hippocampus (AUC: 89%, 95% CI 81-98%), ventricle (AUC: 82%, 95% CI 70-93%) volumes, and MoCA (AUC: 97%, 95% CI 92-100%). The sensitivity and specificity using a cutoff point with a $\geq 80\%$ specificity were 81% and 80% for a CNFD ≤ 27 fibers/mm², 81% and 76% for a CNFL ≤ 21 mm/mm², 85% and 92% for whole brain ≤ 70 ICV%, 85% and 92% with hippocampi ≤ 0.40 ICV%, 70% and 84% with ventricle ≥ 3.58 ICV%, and 100% and 88% with MoCA score ≤ 26 . The volume of cortical gray matter,

TABLE 1 Demographic and clinical characteristics of the study population

	NCI (n = 42)	MCI (n = 98)	Dementia (n = 68)	P value ^a	P value ^b	P value ^c
Cognitive function						
MoCA score	27.6 ± 3.8	22.0 ± 5.8	13.0 ± 5.9	≤.0001	≤.0001	≤.0001
Cognitive impairment duration, years	N/A	1.6 ± 2.1	3.1 ± 2.7			≤.0001
Corneal nerve fiber measures						
CNFD, fibers/mm ²	31.9 ± 7.4	24.0 ± 9.3	20.1 ± 8.3	≤.0001	≤.0001	.01
CNBD, branches/mm ²	86.4 ± 44.9	52.9 ± 35.8	46.1 ± 27.0	≤.0001	≤.0001	NS
CNFL, mm/mm ²	22.5 ± 6.0	16.5 ± 6.5	14.7 ± 5.8	≤.0001	≤.0001	NS
Brain volumetric MRI						
Whole brain, ICV %	73.1 ± 2.8	70.8 ± 3.5	67.6 ± 2.9	<.01	≤.0001	≤.0001
Cortical gray matter, ICV %	28.9 ± 3.2	28.6 ± 3.6	24.8 ± 3.8	NS	≤.0001	≤.0001
Ventricle, ICV %	2.7 ± 1.3	3.3 ± 1.4	5.1 ± 2.5	NS	≤.0001	≤.0001
Hippocampus, ICV %	0.46 ± 0.05	0.42 ± 0.08	0.34 ± 0.08	<.05	≤.0001	≤.0001
Entorhinal cortex, ICV %	0.31 ± 0.12	0.33 ± 0.10	0.27 ± 0.09	NS	NS	<.05
Thalamus, ICV %	0.91 ± 0.08	0.91 ± 0.13	0.84 ± 0.10	NS	NS	.01
Amygdala, ICV %	0.19 ± 0.02	0.19 ± 0.03	0.16 ± 0.04	NS	<.01	<.01
Cingulate gyrus, ICV %	0.89 ± 0.28	0.95 ± 0.18	0.88 ± 0.12	NS	NS	NS
Frontal lobe, ICV %	9.5 ± 3.0	10.1 ± 1.8	8.8 ± 1.4	NS	NS	<.05
Temporal lobe, ICV %	7.0 ± 2.2	7.4 ± 1.4	6.2 ± 1.2	NS	NS	.001
Parietal lobe, ICV %	6.1 ± 2.0	6.2 ± 1.2	5.8 ± 0.9	NS	NS	NS
Occipital lobe, ICV %	3.2 ± 1.1	3.5 ± 0.8	3.2 ± 0.6	NS	NS	NS

Characteristics of 208 participants presented as mean ± SD for numeric variables and frequency distribution for NCI, MCI, and dementia. Continuous and categorical variables were compared using one-way ANOVA with Bonferroni post hoc test and chi-square test, respectively. Abbreviations: Montreal cognitive assessment (MoCA); no cognitive impairment (NCI), mild cognitive impairment (MCI), corneal nerve fiber density (CNFD); corneal nerve branch density (CNBD); corneal nerve fiber length (CNFL); and mean corpuscular volume (MCV).

^aNCI versus MCI.

^bNCI versus Dementia.

^cMCI versus Dementia.

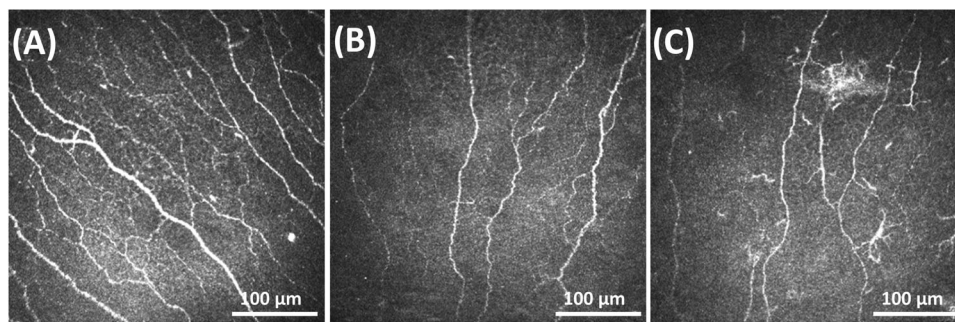


FIGURE 1 Corneal nerve fiber morphology in a subject with no cognitive impairment, mild cognitive impairment (MCI), and dementia. Corneal confocal microscopy (CCM) images of the sub-basal nerve plexus from a subject with (A) no cognitive impairment, (B) MCI, and (C) dementia showing decreased corneal nerve fiber density, length, and branch density in subjects with MCI and dementia compared to subjects with no cognitive impairment

TABLE 2 Receiver-operating characteristic (ROC) curve analysis for the diagnostic accuracy of corneal confocal microscopy and MRI brain volumetry for MCI and dementia

MCI	AUC % (95% CI)	P value	Cutoff point	Sensitivity (%)	Specificity (%)	Dementia	AUC % (95% CI)	P value	Cutoff point	Sensitivity (%)	Specificity (%)
AUC ≥ 80%											
CNFL, mm/mm ²	81 (71-91)	≤.0001	≤21	80	76	MoCA score	97 (92-100)	≤.0001	≤26	100	88
AUC 60-80%					Whole brain, ICV %	93 (85-100)	≤.0001	≤70	85	92	
MoCA score	79 (68-90)	≤.0001	≤27	73	84	Hippocampi, ICV %	89 (81-98)	≤.0001	≤0.40	85	84
CNFD, fibers/mm ²	76 (66-87)	≤.0001	≤27	59	80	CNFD, fibers/mm ²	85 (75-95)	≤.0001	≤27	81	80
CNBD, branches/mm ²	76 (66-87)	≤.0001	≤58	59	80	CNFL, mm/mm ²	84 (73-95)	≤.0001	≤21	81	76
Whole brain, ICV %	70 (59-81)	.001	≤71	53	80	Ventricle, ICV %	82 (70-93)	≤.0001	≥3.58	70	84
Ventricle, ICV %	67 (54-80)	.01	≥2.86	58	68	AUC 60-80%					
Hippocampus, ICV %	67 (55-79)	<.01	≤0.41	50	80	Cortical gray matter, ICV %	79 (67-91)	≤.0001	≤25.4	63	84
Unable to distinguish					CNBD, branches/mm ²	77 (64-90)	≤.0001	≤58	67	80	
Amygdala, ICV %	53 (40-67)	.63	N/A	N/A	N/A	Thalamus, ICV %	76 (63-89)	≤.0001	≤0.83	56	80
Cortical gray matter, ICV %	52 (38-66)	.77	N/A	N/A	N/A	Frontal lobe, ICV %	75 (61-89)	≤.0001	≤8.8	59	88
Thalamus, ICV %	52 (39-64)	.76	N/A	N/A	N/A	Temporal lobe, ICV %	75 (62-89)	≤.0001	≤6.5	63	84
Parietal lobe, ICV %	51 (38-65)	.84	N/A	N/A	N/A	Amygdala, ICV %	72 (58-86)	<.01	≤0.18	63	80
Entorhinal cortex, ICV %	51 (37-65)	.86	N/A	N/A	N/A	Entorhinal cortex, ICV %	69 (53-84)	<.05	≤0.26	56	80
Cingulate gyrus, ICV %	49 (36-62)	.89	N/A	N/A	N/A	Parietal lobe, ICV %	69 (54-84)	<.05	≤5.8	59	84
Temporal lobe, ICV %	48 (34-63)	.82	N/A	N/A	N/A	Cingulate gyrus, ICV %	66 (51-81)	<.05	≤0.87	52	76
Frontal lobe, ICV %	48 (34-61)	.75	N/A	N/A	N/A	Unable to distinguish					
Occipital lobe, ICV %	46 (32-60)	.54	N/A	N/A	N/A	Occipital lobe, ICV %	63 (48-79)	.10	N/A	N/A	N/A

Abbreviations: no cognitive impairment (NCI), mild cognitive impairment (MCI), corneal nerve fiber density (CNFD), corneal nerve branch density (CNBD); and corneal nerve fiber length (CNFL).

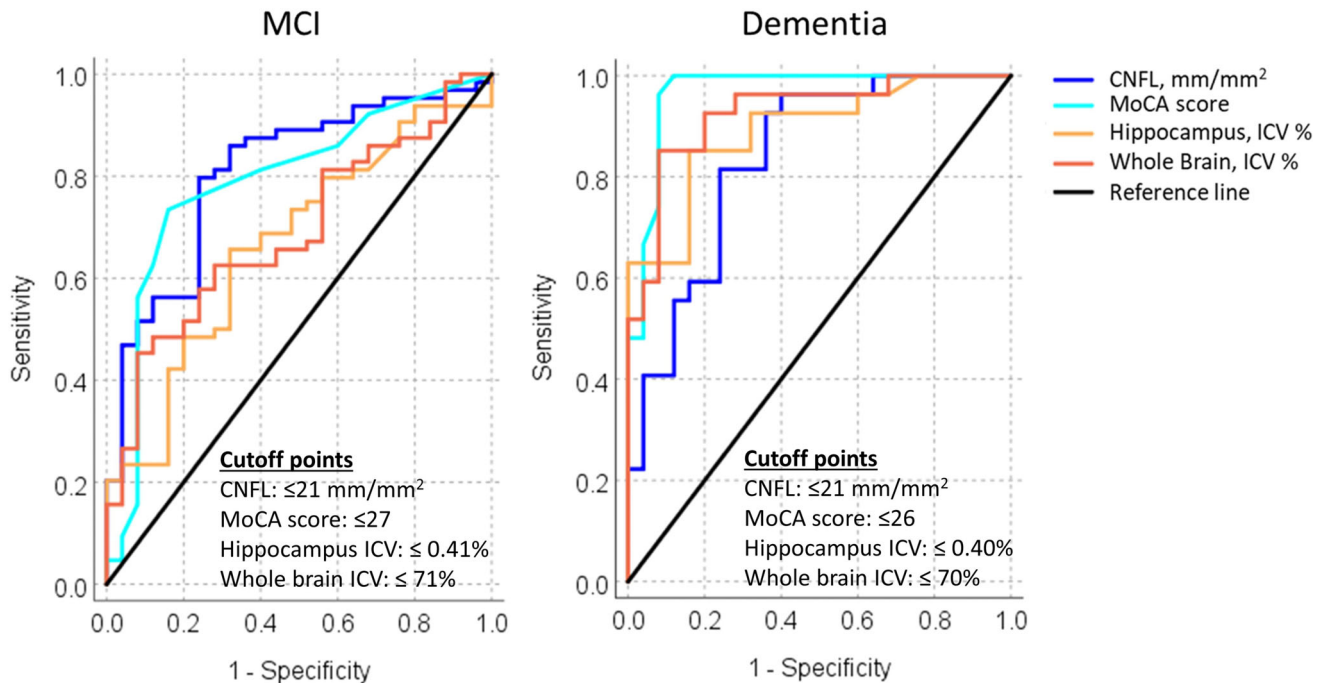


FIGURE 2 The diagnostic accuracy of corneal nerve fiber length, Montreal Cognitive Assessment (MoCA), hippocampus, and whole brain intracranial volume percentage for MCI and dementia. Receiver-operating characteristic (ROC) curve analysis showing the area under the curve for corneal nerve fiber length, MoCA, hippocampus, and whole brain intracranial volume percentage

frontal, temporal and parietal lobe, amygdala, entorhinal cortex, thalamus, cingulate gyrus, and CNBD showed an AUC ranging from 66% to 79%. Occipital lobe volume could not distinguish dementia from NCI (Table 2).

3.4 | Association of CCM measures and brain volumetry with cognitive function

The association of cognitive function with CCM and brain volumetry was assessed after adjustment for duration of cognitive impairment, body weight, and MCV (Table 3). Cognitive function was positively associated with CNFD ($P = .001$), CNBD ($P < .01$), CNFL ($P < .01$), volume of whole brain ($P < .0001$), hippocampi ($P < .0001$), cortical gray matter ($P < .0001$), thalamus ($P < .01$), and amygdala ($P < .01$), and negatively associated with ventricle volume ($P = .001$). Cognitive function had no association with frontal lobe ($P = .34$), temporal lobe ($P = .07$), entorhinal cortex ($P = .44$), and cingulate gyrus ($P = .87$) volumes.

3.5 | Association of CCM measures with brain volumetric MRI

The association of whole brain volume with CCM measures was assessed after adjusting for age, cholesterol, and MCV (Table 3). Whole brain volume was positively associated with CNFD (β coefficient: 0.08 fibers/mm², 95% CI 0.003, -0.16; $P < .05$) but not CNBD ($P = .23$) or CNFL ($P = .12$).

4 | DISCUSSION

This study shows that the diagnostic capability of corneal confocal microscopy (or CCM) is superior to MRI brain volumetry for distinguishing MCI from NCI and comparable for distinguishing dementia from NCI. Furthermore, after adjustment for confounding factors, corneal nerve measures and MRI brain volumetry were associated with cognitive function in MCI and dementia.

Structural neuroimaging has been validated as a diagnostic biomarker of neurodegeneration in AD.^{4,6} A significant reduction in the volume of the hippocampus, amygdala, and entorhinal cortex and an increase in the volume of the lateral ventricles are established features of dementia but not MCI.^{13,38} This study shows that the volume of whole brain, hippocampi, and lateral ventricles identifies patients with dementia with high accuracy (AUC $\geq 80\%$), whereas the volume of cortical gray matter, thalamus, amygdala, entorhinal cortex, cingulate gyrus, frontal, temporal, and parietal lobes has only moderate accuracy (AUC = 66-79%). Furthermore, we and others^{30,39} have shown that MRI brain volumetry performs poorly in identifying people with MCI, indicating that significant brain atrophy only occurs in established dementia, although the annual change in hippocampal volume is a good predictor of MCI progression to dementia.^{13,14}

CCM, an ophthalmic imaging technique, shows corneal nerve degeneration in people with MCI and dementia, which was related to the severity of cognitive dysfunction and impaired activity of daily living.^{29,30} Corneal nerve fiber measures are significantly lower in patients with AD, VaD, and mixed dementia compared to MCI and

TABLE 3 The association between corneal nerve fiber measures, MRI brain volumetry, and cognitive function

	Adjusted beta coefficient	95% Confidence Interval	P value
MoCA score as a dependent variable			
CNFD, fibers/mm ²	0.22	0.09 to 0.35	.001
CNBD, branches/mm ²	0.04	0.01 to 0.08	<.01
CNFL, mm/mm ²	0.27	0.09 to 0.45	<.01
Whole Brain, ICV %	0.98	0.63 to 1.33	<.0001
Hippocampi, ICV %	37.14	21.38 to 52.90	<.0001
Ventricle, ICV %	-1.42	-2.22 to -0.61	.001
Cortical gray matter, ICV %	0.72	0.38 to 1.06	<.0001
Frontal lobe, ICV %	0.30	-0.32 to 0.91	NS
Temporal lobe, ICV %	0.76	-0.06 to 1.57	NS
Entorhinal cortex, ICV%	5.04	-7.88 to 17.95	NS
Thalamus, ICV %	17.91	5.59 to 30.22	<.01
Amygdala, ICV %	58.56	18.55 to 98.58	<.01
Cingulate gyrus, ICV %	-0.54	-7.31 to 6.23	NS
Whole brain volume, ICV % as a dependent variable			
CNFD, fibers/mm ²	0.08	0.003 to 0.16	<.05
CNBD, branches/mm ²	0.01	-0.01 to 0.03	NS
CNFL, mm/mm ²	0.09	-0.02 to 0.20	NS

All the variables considered in the fitted model had $P < .05$. MoCA score was adjusted for duration of cognitive impairment, body weight, and mean corpuscular volume. Whole brain volume was adjusted for age, cholesterol, and mean corpuscular volume. Abbreviations: corneal nerve fiber density (CNFD), length (CNFL), branch density (CNBD), and intra cranial volume (ICV).

NCI.^{29,30} We have also shown that CCM is superior to the presence of medial temporal lobe atrophy (MTA) for distinguishing MCI from NCI.³⁰ The pathogenic processes common to dementia and corneal nerve fiber damage are not known. Corneal nerves are derived from the ophthalmic division of the trigeminal nerve and are anatomically components of the peripheral nervous system.^{40,41} Tauopathy is a key feature of dementia,⁴² and we have recently shown stromal corneal nerve loss in transgenic mice overexpressing human tau.⁴³ Corneal nerve loss has also been associated with many of the risk factors for MCI and dementia including hyperglycemia, hypertension and hyperlipidemia,²¹ and the presence of white matter hyperintensities,⁴⁴ and cerebral ischemia.⁴⁵ Although diabetes is associated with corneal nerve loss,^{17,46-49} this study shows that the loss of corneal nerve fibers in patients with MCI and dementia remained significant after excluding those with diabetes. Indeed, in our recent study in which diabetes was excluded, there was evidence of significant corneal nerve fiber loss in patients with MCI and dementia.²⁹

MTA is associated with memory loss in MCI and AD.^{50,51} Stelmokas et al³⁷ reported reduced hippocampal volume and enlarged lateral ventricles with delayed memory performance in MCI. This study shows that the volume of whole brain, hippocampi, ventricles, cortical gray matter, thalamus, and amygdala were significantly associated with cognitive function in MCI and dementia. In line with our previous findings,²⁹ this study also showed that corneal nerve fiber loss was

associated with cognitive decline. The association between neurodegeneration and cognitive function in dementia is complex, as some post-mortem studies have shown that there are cases of dementia with limited neurodegeneration and equally there are patients with neurodegeneration without cognitive impairment.⁵²⁻⁵⁴ The association between neurodegeneration and cognitive impairment may also be influenced by cerebrovascular ischemia,^{45,55} which reduces the brain reserve to tolerate neurodegeneration.^{54,56} The association of corneal nerve loss with cognitive impairment may be influenced by diabetes, as it increases the odds of cerebral ischemia, infarct, and lacunes,⁵⁷ which increase the risk of cognitive impairment⁵⁸ and dementia.⁵⁹

Further studies are needed to compare the diagnostic performance of CCM in MCI and dementia against established biomarkers of AD including [¹⁸F] fluorodeoxyglucose (FDG) uptake on PET,^{60,61} cerebrospinal fluid (CSF) concentrations of amyloid beta (A β) 42, A β 40 or tau/phosphorylated tau,^{62,63} or positron emission tomography (PET) for A β deposition.^{64,65}

An ideal biomarker for dementia should be able to identify sub-clinical pathology in MCI and predict those who develop dementia.⁵ In the present study, although all three corneal nerve fiber measures were reduced in MCI and dementia, a proportion of people with MCI had corneal nerve loss that was comparable to that of patients with dementia. A longitudinal study is currently underway to assess whether people who progress from MCI to dementia show greater evidence of

corneal nerve loss. We acknowledge as a study limitation that we have not assessed for severe dry eye, which is associated with corneal nerve abnormalities.⁶⁶ Our study shows that there was an increase in the vibration perception threshold in subjects with dementia. However, vibration perception threshold is a subjective psychophysical test, which may have been influenced by a lack of motivation, alertness, and concentration, especially in patients with dementia.

In conclusion, this study shows that CCM has high diagnostic accuracy for MCI and dementia, whereas MRI brain volumetry has high diagnostic accuracy for dementia only. Loss of corneal nerves and MRI brain volume was associated with cognitive impairment in MCI and dementia. These data support the contention that CCM could act as a surrogate marker of neurodegeneration in MCI and dementia, especially to identify people with MCI who progress to dementia.

ACKNOWLEDGMENTS

The authors thank Dr Hanadi Al-Hamad, the Medical Director of Rumailah Hospital and Qatar Rehabilitation Institute and her staff at Rumailah Hospital for providing the facility and helping to undertake this study. They also particularly thank all the participants and their relatives for their efforts, will, and commitment to be involved in the study. They also thank the WCM-Q Clinical Research Core for statistical advice. This work was funded by the Qatar National Research Fund (BMRP-5726113101 & NPRP12S-0213-190080).

CONFLICTS OF INTEREST

The authors confirm that the manuscript has been read and approved by all named authors and that there are no other persons who satisfied the criteria for authorship and are not listed. They also confirm that the order of authors listed in the manuscript has been approved by all authors. Dr. Surjith Vattoth has Elsevier book author royalty, received consulting fee as an Elsevier master author consultant in head and neck imaging, and received payment for ESNR - ECHNR course faculty. None of the other authors have received or anticipate receiving income, goods, or benefit from a company that will influence the design, conduct, or reporting of the study.

REFERENCES

- Wu YT, Beiser AS, Breteler MMB, et al. The changing prevalence and incidence of dementia over time - current evidence. *Nat Rev Neurol*. 2017;13:327-339.
- Prince M, Bryce R, Albanese E, et al. The global prevalence of dementia: a systematic review and metaanalysis. *Alzheimers Dement*. 2013;9:63-75.
- Prince M, Bryce R, Ferri C. World Alzheimer report 2011: the benefits of early diagnosis and intervention. *Alzheimers Dis Int*. 2011.
- Albert MS, DeKosky ST, Dickson D, et al. The diagnosis of mild cognitive impairment due to Alzheimer's disease: recommendations from the National Institute on Aging-Alzheimer's Association workgroups on diagnostic guidelines for Alzheimer's disease. *Alzheimers Dement*. 2011;7:270-279.
- Jack CR Jr, Bennett DA, Blennow K, et al. NIA-AA Research Framework: toward a biological definition of Alzheimer's disease. *Alzheimers Dement*. 2018;14:535-562.
- McKhann GM, Knopman DS, Chertkow H, et al. The diagnosis of dementia due to Alzheimer's disease: recommendations from the National Institute on Aging-Alzheimer's Association workgroups on diagnostic guidelines for Alzheimer's disease. *Alzheimers Dement*. 2011;7:263-269.
- Du AT, Schuff N, Amend D, et al. Magnetic resonance imaging of the entorhinal cortex and hippocampus in mild cognitive impairment and Alzheimer's disease. *J Neurol Neurosurg Psychiatry*. 2001;71:441-447.
- Urs R, Potter E, Barker W, et al. Visual rating system for assessing magnetic resonance images: a tool in the diagnosis of mild cognitive impairment and Alzheimer disease. *J Comput Assist Tomogr*. 2009;33:73-78.
- Thies B, Truschke E, Morrison-Bogorad M, Hodes RJ. Consensus report of the Working Group on: molecular and biochemical markers of Alzheimer's disease. *Neurobiol Aging*. 1999;20:247.
- Heo JH, Kim MK, Lee JH, Lee JH. Usefulness of medial temporal lobe atrophy visual rating scale in detecting Alzheimer's disease: preliminary study. *Ann Indian Acad Neurol*. 2013;16:384-387.
- Cavedo E, Pievani M, Boccardi M, et al. Medial temporal atrophy in early and late-onset Alzheimer's disease. *Neurobiol Aging*. 2014;35:2004-2012.
- Duara R, Loewenstein DA, Potter E, et al. Medial temporal lobe atrophy on MRI scans and the diagnosis of Alzheimer disease. *Neurology*. 2008;71:1986-1992.
- Ledig C, Schuh A, Guerrero R, Heckemann RA, Rueckert D. Structural brain imaging in Alzheimer's disease and mild cognitive impairment: biomarker analysis and shared morphometry database. *Sci Rep*. 2018;8:11258.
- Barnes J, Bartlett JW, van de Pol LA, et al. A meta-analysis of hippocampal atrophy rates in Alzheimer's disease. *Neurobiol Aging*. 2009;30:1711-1723.
- Dabbah MA, Graham J, Petropoulos IN, Tavakoli M, Malik RA. Automatic analysis of diabetic peripheral neuropathy using multi-scale quantitative morphology of nerve fibres in corneal confocal microscopy imaging. *Medical Image Analysis*. 2011;15:738-747.
- Vagenas D, Pritchard N, Edwards K, Shahidi AM, et al. Optimal image sample size for corneal nerve morphometry. *Optom Vis Sci*. 2012;89:812-817.
- Petropoulos IN, Manzoor T, Morgan P, et al. Repeatability of in vivo corneal confocal microscopy to quantify corneal nerve morphology. *Cornea*. 2013;32:e83-9.
- Kalteniece A, Ferdousi M, Adam S, et al. Corneal confocal microscopy is a rapid reproducible ophthalmic technique for quantifying corneal nerve abnormalities. *PLoS One*. 2017;12:e0183040.
- Petropoulos IN, Ponirakis G, Khan A, et al. Corneal confocal microscopy: ready for prime time. *Clin Exp Optom*. 2020;103:265-277.
- Perkins BA, Lovblom LE, Bril V, et al. Corneal confocal microscopy for identification of diabetic sensorimotor polyneuropathy: a pooled multinational consortium study. *Diabetologia*. 2018;61:1856-1861.
- Ferdousi M, Kalteniece A, Azmi S, et al. Diagnosis of neuropathy and risk factors for corneal nerve loss in Type 1 and Type 2 diabetes: a corneal confocal microscopy study. *Diabetes Care*. 2021;44:150-156.
- Kemp HI, Petropoulos IN, Rice ASC, et al. Use of Corneal Confocal Microscopy to Evaluate Small Nerve Fibers in Patients With Human Immunodeficiency Virus. *JAMA Ophthalmol*. 2017;135:795-800.
- Pagovich OE, Vo ML, Zhao ZZ, et al. Corneal confocal microscopy: neurologic disease biomarker in Friedreich ataxia. *Ann Neurol*. 2018;84:893-904.
- Petropoulos IN, Kamran S, Li Y, et al. Corneal Confocal Microscopy: an Imaging Endpoint for Axonal Degeneration in Multiple Sclerosis. *Invest Ophthalmol Vis Sci*. 2017;58:3677-3681.
- Bitirgen G, Akpınar Z, Malik RA, Ozkagnici A. Use of Corneal Confocal Microscopy to Detect Corneal Nerve Loss and Increased

- Dendritic Cells in Patients With Multiple Sclerosis. *JAMA Ophthalmol.* 2017;135:777-782.
26. Misra SL, Kersten HM, Roxburgh RH, Danesh-Meyer HV, McGhee CN. Corneal nerve microstructure in Parkinson's disease. *J Clin Neurosci.* 2017;39:53-58.
 27. Lim SH, Ferdousi M, Kalteniece A, et al. Corneal confocal microscopy detects small fibre neurodegeneration in Parkinson's disease using automated analysis. *Sci Rep.* 2020;10:20147.
 28. Kass-Iliyya L, Javed S, Gosal D, et al. Small fiber neuropathy in Parkinson's disease: a clinical, pathological and corneal confocal microscopy study. *Parkinsonism Relat Disord.* 2015;21:1454-1460.
 29. Ponirakis G, Al Hamad H, Sankaranarayanan A, et al. Association of corneal nerve fiber measures with cognitive function in dementia. *Ann Clin Transl Neurol.* 2019;6:689-697.
 30. Al-Janahi E, Ponirakis G, Al Hamad H, et al. Corneal Nerve and Brain Imaging in Mild Cognitive Impairment and Dementia. *J Alzheimers Dis.* 2020;77:1533-1543.
 31. Bener A, Zirir M, Janahi IM, Al-Hamaq AO, Musallam M, Wareham NJ. Prevalence of diagnosed and undiagnosed diabetes mellitus and its risk factors in a population-based study of Qatar. *Diabetes Res Clin Pract.* 2009;84:99-106.
 32. Nasreddine ZS, Phillips N, Chertkow H. Normative data for the Montreal Cognitive Assessment (MoCA) in a population-based sample. *Neurology.* 2012;78:765-766. author reply 6.
 33. *The ICD-10 classification of mental and behavioural disorders : clinical descriptions and diagnostic guidelines.* World Health Organization; 1992.
 34. Dubois B, Picard G, Sarazin M. Early detection of Alzheimer's disease: new diagnostic criteria. *Dialogues Clin Neurosci.* 2009;11:135-139.
 35. Roman GC, Tatemichi TK, Erkinjuntti T, Cummings JL, Masdeu JC, Garcia JH, et al. Vascular dementia: diagnostic criteria for research studies: Report of the NINDS-AIREN International Workshop. *Neurology.* 1993;43:250-260.
 36. Brewer JB, Magda S, Airriess C, Smith ME. Fully-automated quantification of regional brain volumes for improved detection of focal atrophy in Alzheimer disease. *AJNR Am J Neuroradiol.* 2009;30:578-580.
 37. Stelmokas J, Yassay L, Giordani B, et al. Translational MRI Volumetry with NeuroQuant: effects of Version and Normative Data on Relationships with Memory Performance in Healthy Older Adults and Patients with Mild Cognitive Impairment. *J Alzheimers Dis.* 2017;60:1499-1510.
 38. Min J, Moon WJ, Jeon JY, Choi JW, Moon YS, Han SH. Diagnostic efficacy of structural MRI in patients with mild-to-moderate alzheimer disease: automated volumetric assessment versus visual assessment. *AJR Am J Roentgenol.* 2017;208:617-623.
 39. Falgas N, Sanchez-Valle R, Bargallo N, et al. Hippocampal atrophy has limited usefulness as a diagnostic biomarker on the early onset Alzheimer's disease patients: a comparison between visual and quantitative assessment. *Neuroimage Clinical.* 2019;23:101927.
 40. Al-Aqaba MA, Fares U, Suleman H, Lowe J, Dua HS. Architecture and distribution of human corneal nerves. *Br J Ophthalmol.* 2010;94:784-789.
 41. Muller LJ, Marfurt CF, Kruse F, Tervo TM. Corneal nerves: structure, contents and function. *Exp Eye Res.* 2003;76:521-542.
 42. Attems J, Quass M, Jellinger KA. Tau and alpha-synuclein brainstem pathology in Alzheimer disease: relation with extrapyramidal signs. *Acta Neuropathol.* 2007;113:53-62.
 43. Marquez A, Guernsey LS, Frizzi KE, et al. Tau associated peripheral and central neurodegeneration: identification of an early imaging marker for tauopathy. *Neurobiol Dis.* 2021;151:105273.
 44. Kamran S, Khan A, Salam A, et al. Cornea: a Window to White Matter Changes in Stroke; Corneal Confocal Microscopy a Surrogate Marker for the Presence and Severity of White Matter Hyperintensities in Ischemic Stroke. *J Stroke Cerebrovasc Dis.* 2020;29:104543.
 45. Ponirakis G, Elstouhy A, Al Hamad H, et al. Association of Cerebral Ischemia With Corneal Nerve Loss and Brain Atrophy in MCI and Dementia. *Front Neurosci.* 2021;15:690896.
 46. Petropoulos IN, Alam U, Fadavi H, et al. Rapid automated diagnosis of diabetic peripheral neuropathy with in vivo corneal confocal microscopy. *Invest Ophthalmol Vis Sci.* 2014;55:2071-2078.
 47. Petropoulos IN, Alam U, Fadavi H, et al. Corneal nerve loss detected with corneal confocal microscopy is symmetrical and related to the severity of diabetic polyneuropathy. *Diabetes Care.* 2013;36:3646-3651.
 48. Malik RA, Kallinikos P, Abbott CA, et al. Corneal confocal microscopy: a non-invasive surrogate of nerve fibre damage and repair in diabetic patients. *Diabetologia.* 2003;46:683-688.
 49. Ahmed A, Bril V, Orszag A, et al. Detection of diabetic sensorimotor polyneuropathy by corneal confocal microscopy in type 1 diabetes: a concurrent validity study. *Diabetes Care.* 2012;35:821-828.
 50. Kovacevic S, Rafii MS, Brewer JB. Alzheimer's Disease Neuroimaging Initiative. High-throughput, fully automated volumetry for prediction of MMSE and CDR decline in mild cognitive impairment. *Alzheimer Dis Assoc Disord.* 2009;23:139-145.
 51. Shen Q, Loewenstein DA, Potter E, et al. Volumetric and visual rating of magnetic resonance imaging scans in the diagnosis of amnesic mild cognitive impairment and Alzheimer's disease. *Alzheimers Dement.* 2011;7:e101-8.
 52. Espay AJ, Vizcarra JA, Marsili L, et al. Revisiting protein aggregation as pathogenic in sporadic Parkinson and Alzheimer diseases. *Neurology.* 2019;92:329-337.
 53. Illan-Gala I, Pegueroles J, Montal V, et al. Challenges associated with biomarker-based classification systems for Alzheimer's disease. *Alzheimers Dement (Amst).* 2018;10:346-357.
 54. Canevelli M, Arisi I, Bacigalupo I, et al. Biomarkers and phenotypic expression in Alzheimer's disease: exploring the contribution of frailty in the Alzheimer's Disease Neuroimaging Initiative. *Geroscience.* 2020;43, 1039-1051.
 55. Iadecola C. The pathobiology of vascular dementia. *Neuron.* 2013;80:844-866.
 56. Wallace LMK, Theou O, Darvesh S, Bennett DA, Buchman AS, Andrew MK, et al. Neuropathologic burden and the degree of frailty in relation to global cognition and dementia. *Neurology.* 2020;95: e3269.
 57. Abner EL, Nelson PT, Kryscio RJ, Schmitt FA, Fardo DW, Woltjer RL, et al. Diabetes is associated with cerebrovascular but not Alzheimer's disease neuropathology. *Alzheimers Dement.* 2016;12:882-889.
 58. Snowdon DA, Greiner LH, Mortimer JA, Riley KP, Greiner PA, Markesbery WR. Brain infarction and the clinical expression of Alzheimer disease. The Nun Study. *JAMA.* 1997;277:813-817.
 59. Vermeer SE, Prins ND, den Heijer T, Hofman A, Koudstaal PJ, Breteler MM. Silent brain infarcts and the risk of dementia and cognitive decline. *N Engl J Med.* 2003;348:1215-1222.
 60. Landau SM, Harvey D, Madison CM, et al. Comparing predictors of conversion and decline in mild cognitive impairment. *Neurology.* 2010;75:230-238.
 61. Suppiah S, Didier MA, Vinjamuri S. The Who, When, Why, and How of PET Amyloid Imaging in Management of Alzheimer's Disease-Review of Literature and Interesting Images. *Diagnostics (Basel).* 2019;9.
 62. Mattsson N, Zetterberg H, Hansson O, Andreassen N, Parnetti L, Jonsson M, et al. CSF biomarkers and incipient Alzheimer disease in patients with mild cognitive impairment. *JAMA.* 2009;302:385-393.
 63. Hansson O, Zetterberg H, Buchhave P, Londos E, Blennow K, Minthon L. Association between CSF biomarkers and incipient Alzheimer's disease in patients with mild cognitive impairment: a follow-up study. *Lancet Neurol.* 2006;5:228-234.

64. Forsberg A, Engler H, Almkvist O, et al. PET imaging of amyloid deposition in patients with mild cognitive impairment. *Neurobiol Aging*. 2008;29:1456-1465.
65. Grimmer T, Wutz C, Drzezga A, et al. The usefulness of amyloid imaging in predicting the clinical outcome after two years in subjects with mild cognitive impairment. *Curr Alzheimer Res*. 2013;10:82-85.
66. Cruzat A, Qazi Y, Hamrah P. In Vivo Confocal Microscopy of Corneal Nerves in Health and Disease. *Ocul Surf*. 2017;15:15-47.

How to cite this article: Ponirakis G, Hamad HAI, Khan A, et al. Loss of corneal nerves and brain volume in mild cognitive impairment and dementia. *Alzheimer's Dement*. 2022;8:e12269. <https://doi.org/10.1002/trc2.12269>