

Is it possible to preserve the blood supply of erectile organs by anastomosis using the hypogastric artery in kidney transplantation?

Afshar Zomorodi¹

Farzad Kakaei²

Sahar Zomorodi³

Amin Bagheri¹

¹Department of Urology and Kidney Transplantation, Emam Reza Hospital, Tabriz University of Medical Sciences, Tabriz, Iran; ²Department of Surgery, Emam Reza Hospital, Tabriz University of Medical Sciences, Tabriz, Iran; ³Tabriz University of Medical Sciences, Tabriz, Iran

Introduction: Three modalities for treating chronic kidney failure are peritoneal dialysis, hemodialysis, and kidney transplantation. Among them kidney transplantation is cost-efficient and leads to a somewhat normal quality of life. In this approach, most often the external iliac artery is selected for anastomosis, but this could be disastrous if anastomosis leads to a complication. The traditional end-to-end approach for anastomosis of the kidney artery to the internal iliac artery leads to pelvic organ ischemia. However, if the end-to-end anastomosis is replaced by an end-to-side approach, it is safer. This report discusses some cases of end-to-side anastomosis using the internal iliac artery.

Method: In ten cases of chronic kidney failure, we anastomosed the kidney artery to the internal iliac artery with an end-to-side approach.

Results: After vessels were unclamped, all patients had diuresis. Their creatinine was in normal range and was blood flow in the internal iliac artery, based on color Doppler ultrasound.

Conclusion: End-to-side anastomosis can be done in some chronic kidney failure patients if their internal iliac arteries are large enough. This approach is safer than anastomosis using the external iliac artery.

Keywords: kidney transplant, internal iliac artery, anastomosis

Introduction

The most effective treatment for chronic kidney failure is kidney transplantation in which the external iliac artery is used to preserve pelvic organs' circulation. Using the internal iliac artery for end-to-end anastomosis is a traditional approach for kidney transplantation (Figure 1). Even in repeated kidney transplantation the end-to-end is preferred to the end-to-side approach.

Kidney transplantation is the preferred choice of treatment for chronic kidney failure because it offers the patient a "near normal" lifestyle. Vascular anastomosis is still done according to Alex Carrel's technique for kidney transplantation and Kuss' technique for pelvic vessels.¹ With this method the hypogastric artery or external iliac artery is selected for vessel anastomosis.

The traditional approach used a pelvic vessel such as the internal iliac artery,² but later the external iliac artery was used for preserving pelvic organs' circulation, especially in the penis.³ End-to-end anastomosis using the hypogastric artery has been claimed to reduce the penis' blood circulation,³ as it is suggested that 50% of chronic kidney failure patients suffer from erectile dysfunction. Some studies suggest that end-to-end anastomosis is an etiology of post-kidney transplantation erectile dysfunction.⁴

Correspondence: Farzad Kakaei
Department of Surgery, Emam Reza Hospital, Daneshgah Street, Tabriz 5165687386, Iran
Tel +98 41 3555 3407
Fax +98 41 3334 7054
Email fkakaei@yahoo.com

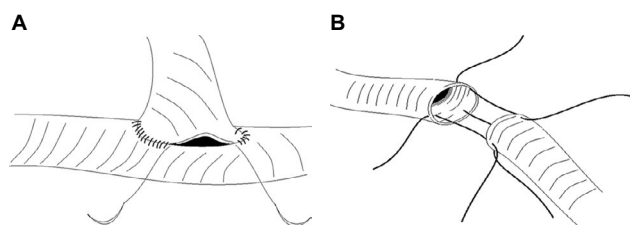


Figure 1 (A) End-to-side anastomosis, (B) end-to-end anastomosis.

Claudication has also been reported after end-to-end internal iliac artery anastomosis.⁵

To our knowledge, there has only been one study on end-to-side anastomosis of the internal iliac artery in a general hospital in Leicester, UK.⁶ Ours is the second to discuss some cases of end-to-side anastomosis using the internal iliac artery in a hospital in Tabriz city, Iran.

Cases

This study was done on ten kidney transplant patients (Table 1). The end-to-side internal iliac artery anastomosis approach was used in all patients.

One of the cases was a 45-year-old male with chronic kidney failure because of hypertension. Kidney transplantation was carried out with allograft kidney procured from an unrelated live donor. It was the donor's left kidney. To prepare the recipient's hypogastric artery, we performed end-to-side kidney artery anastomosis. After 2 months' follow-up his creatinine level was normal =0.3 mg/dL (Figure 2).

Another case was a 25-year-old male with chronic kidney failure due to glomerulopathy. We performed end-to-side anastomosis using the hypogastric (internal iliac) artery with good results (Figure 3). His creatinine level was 1.5 mg/dL after 2 months. He was treated with tacrolimus, CellCept® (mycophenolate mofetil), and prednisolone.

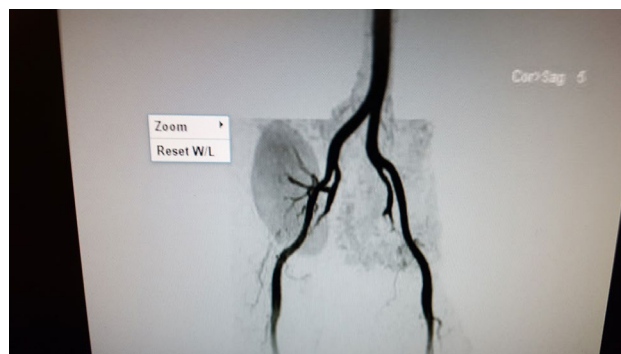

Figure 2 Magnetic resonance angiogram of allograft kidney with end-to-side anastomosis using the internal iliac artery, and distal blood flow beyond anastomosis.

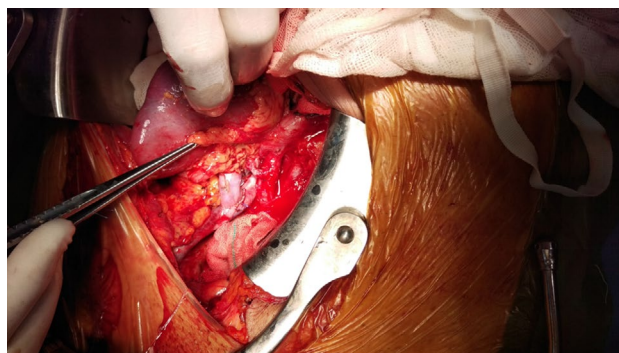


Figure 3 End-to-side anastomosis using the internal iliac artery.

In our hospital more than ten kidney transplantations have been performed successfully by end-to-side anastomosis using the internal iliac artery. All of the patients were treated with tacrolimus, mycophenolate mofetil, and prednisolone and their creatinine levels were ≤ 1.5 mg/dL.

Discussion

The internal iliac artery separates from the common iliac artery. It has nine branches including: sacral, gluteal inferior, gluteal superior, lumbar, umbilical, obturator artery, superior

Table 1 The patient's age, sex, race, outcomes, and complications

Case	Age (years)	Sex	Race	Serum creatinine 2 months after transplantation, mg/dL	Glomerular filtration rate, mL/min	Complications
1	28	Male	Caucasian	1.8	58.7	none
2	25	Male	Caucasian	1.5	83	none
3	36	Female	Caucasian	1.6	56.2	none
4	34	Male	Caucasian	1.5	67.7	none
5	43	Female	Caucasian	1.3	67.3	none
6	39	Male	Caucasian	1.8	45.97	none
7	50	Male	Caucasian	2.1	44	none
8	47	Male	Caucasian	1.9	56.4	none
9	29	Male	Caucasian	1.5	86.3	none
10	42	Male	Caucasian	1.6	53.5	none

Table 2 Complications and advantages of internal and external iliac artery anastomosis

Arteries	Anastomosis	Complications	Advantages
External iliac artery	End-to-side	Possible lower limb amputation in case of complications in the anastomosis site	An easy way to perform anastomosis
	End-to-end		
Internal iliac artery	End-to-side	Needs release of internal iliac artery	Preserved arterial blood supply to pelvic organs
	End-to-end	Claudication, impotence	Easier access to perform anastomosis

vesical, inferior vesical, and pudendal. In end-to-end anastomosis using the kidney artery we omit nine internal iliac artery branches. This can have consequences for a kidney transplant recipient. For example, omitting the pudendal branch reduces perfusion of penile arteries⁵ and causes erectile dysfunction; or omission of the gluteal branch causes claudication⁵ (Table 2).

Considering that erectile dysfunction is more common in kidney transplant patients, the end-to-side instead of end-to-end anastomosis approach can be useful in a patient with high risk of erectile dysfunction and claudication, especially in young people, if the internal iliac artery is large enough in diameter for anastomosis. Also, if there is arterial plaque, it is possible to perform an endarterectomy and then end-to-side anastomosis to preserve pelvic organs' perfusion, especially erectile organs' blood flow.

Conclusion

Chronic kidney failure can be associated with a pelvic organ dysfunction if the hypogastric artery is used for anastomosis.

End-to-side anastomosis can be considered instead, to preserve pelvic organs' blood flow, especially the erectile organs, in young people.

Ethics statement

This study was approved by the ethics committee of Tabriz University of Medical Sciences (code number: IR.TBZMED.REC.1394.769). The two patients whose cases are reported signed an informed consent for publication of their case details.

Acknowledgment

The authors thank Seyed Muhammed Hussein Mousavinasab for his sincere cooperation in editing this text.

Disclosure

The authors report no conflicts of interest in this work.

References

1. Carrel A. Suture of Blood-Vessels and transplantation of Organs. In: *Nobel Lectures, Physiology or Medicine 1901-1921*. Singapore: World Scientific Publishing Company; 1999:442-464.
2. Mosley JG, Castro JE. Arterial anastomoses in renal transplantation. *Br J Surg*. 1978;65(1):60-63.
3. Abdel-Hamid IA, Eraky I, Fouda MA, Mansour OE. Role of penile vascular insufficiency in erectile dysfunction in renal transplant recipients. *Int J Impot Res*. 2002;14(1):32-37.
4. El-Bahnasawy MS, El-Assmy A, Dawood A, et al. Effect of the use of internal iliac artery for renal transplantation on penile vascularity and erectile function: a prospective study. *J Urol*. 2004;172(6 Pt 1):2335-2339.
5. Rayt HS, Bown MJ, Lambert KV, et al. Buttock claudication and erectile dysfunction after internal iliac artery embolization in patients prior to endovascular aortic aneurysm repair. *Cardiovasc Intervent Radiol*. 2008;31(4):728-734.
6. Mohamed IH, Bagul A, Doughman T, Nicholson ML. Use of internal iliac artery as a side-to-end anastomosis in renal transplantation. *Ann R Coll Surg Engl*. 2012;94(1):e36-e37.