

# Acute urticaria alone after CoronaVac COVID-19 vaccination should not be a contraindication for revaccination

J. Triwatcharikorn,<sup>1</sup> T. Puaratana-arunkon,<sup>1</sup> P. Punyaratabandhu,<sup>2</sup> P. Mongkolpathumrat,<sup>3,4</sup> S. Palapinyo,<sup>5</sup> S. Buranapraditkul,<sup>3,4</sup> P. Rerknimitr,<sup>1,4,6</sup> and J. Klaewsongkram<sup>3,4,6</sup>

<sup>1</sup>Division of Dermatology and <sup>3</sup>Division of Allergy and Clinical Immunology, Department of Medicine, Faculty of Medicine, Chulalongkorn University, Bangkok, Thailand; <sup>2</sup>Department of Disease Control, Ministry of Public Health, Bamrasnaradura Infectious Diseases Institute, Nonthaburi, Thailand; <sup>4</sup>King Chulalongkorn Memorial Hospital, Thai Red Cross Society, Bangkok, Thailand; <sup>5</sup>Department of Pharmacy Practice, Faculty of Pharmaceutical Sciences, Chulalongkorn University, Bangkok, Thailand; and <sup>6</sup>The Skin and Allergy Research Unit, Chulalongkorn University, Bangkok, Thailand

doi:10.1111/ced.14962

## Summary

Patients who develop an immediate allergic reaction within the first 4 h of COVID-19 vaccine injection are recommended not to receive the same vaccine again. This recommendation mainly focuses on the mRNA and adenoviral vector COVID-19 vaccines, but data for whole virus vaccines are unknown. We report seven patients who developed an immediate reaction within 4 h (six had generalized urticaria, one had localized urticaria) after the first vaccination with CoronaVac, the inactivated SARS-CoV-2 vaccine. The results of skin tests and basophil activation tests suggested that spike peptides play a role in exacerbating urticaria in some patients. However, all subjects who developed urticaria within 4 h after CoronaVac vaccination were successfully revaccinated without graded challenge, although recurrent urticaria was common. This preliminary result indicates that acute urticaria alone should not be a contraindication for the second dose of CoronaVac if the supply of alternative vaccines is limited.

The World Health Organization has approved several types of COVID-19 vaccines worldwide for emergency use, including inactivated SARS-CoV-2 vaccines such as CoronaVac (SinoVac Biotech, Beijing, China). Although virus-inactivated vaccines may generate a weaker immune response than live attenuated vaccines or mRNA vaccines, they can be transported and stored at average refrigerated temperatures, offering some advantage in vaccine distribution. Allergic reactions to COVID-19 vaccines are rare; however, excipients such as polyethylene glycol (PEG) and polysorbate are believed to be the potential causes of allergic reactions to mRNA vaccines and adenoviral

vector vaccines.<sup>1</sup> CoronaVac was one of the first COVID-19 vaccines available in Thailand. The principal ingredients in CoronaVac are whole inactivated virus cultured in Vero cells with aluminium hydroxide adjuvant and some mineral salts.<sup>2</sup> Despite containing no polysorbate or PEG, the reported prevalence of urticaria among healthcare workers in Turkey after receiving CoronaVac was about 0.8%.<sup>3</sup> For safety reasons, The US Centers for Disease Control and Prevention currently recommends that patients who develop any immediate allergic reactions within 4 h after getting vaccinated should not receive the same vaccine again.<sup>4</sup> We report the results of immunological investigations in seven consecutive patients with a history of generalized urticaria developing within 4 h after vaccination with the first or second doses of CoronaVac.

*Correspondence:* Dr Jettanong Klaewsongkram, Division of Allergy and Clinical Immunology, Department of Medicine, Faculty of Medicine, Chulalongkorn University, 1873 Rama 4 Road, Pathumwan, Bangkok 10330, Thailand  
E-mail: jettanong.k@chula.ac.th

Conflict of interest: the authors declare that they have no conflicts of interest.

Accepted for publication 4 October 2021

## Report

Institutional approval for this retrospective observational report was obtained from the ethics and

research committee of the Faculty of Medicine, Chulalongkorn University, and the study was conducted in accordance with the Declaration of Helsinki. Informed consent for both study participation and publication was obtained from all participants prior to any tests.

This study analysed the results of immunological investigations in seven consecutive patients (six women, one man) who were referred to King Chulalongkorn Memorial Hospital with a history of generalized urticaria developing within 4 h after vaccination with either the first or second dose of CoronaVac. Data were retrieved from electronic medical records.

All seven patients developed reactions after the first vaccination (six had generalized urticaria and one had localized urticaria) (Table 1). Four patients developed urticaria after both vaccinations with CoronaVac, while two patients developed urticaria only after the first vaccination, and one patient developed generalized urticaria even after being switched from CoronaVac to a different vaccine type (the Oxford-AstraZeneca adenovirus vaccine, ChAdOx1 nCov-19). Both the first and second vaccinations were administered at full dose without graded challenge.

Skin tests were performed on all subjects. Each patient underwent a skin prick test (SPT) with an undiluted vaccine and an intradermal test (IT) with the vaccine diluted 1 : 10 and 1 : 100 with saline. To evaluate whether the rash was the allergic reaction to the viral spike protein itself, all patients also underwent SPT and IT with the synthetic SARS-CoV-2 spike peptides (Mimotopes Pty Ltd, Mulgrave, VIC, Australia) with undiluted peptides (10 mg/mL) and with peptides diluted 1 : 10 and 1 : 100 with saline. The concentrations used in this study were tested on 10 healthy volunteers to confirm that they had no irritating effects. Basophil activation tests (BATs) (Flow2-CAST; Bühlmann Laboratories, Schönenbuch, Switzerland) were performed for all seven patients with the vaccine diluted 1 : 10 and 1 : 100 with saline, and BATs with spike peptides (1 : 100 and 1 : 1000 diluted in saline) were also performed for the four subjects with a positive skin test.

The SPTs were negative for all patients. In addition, in the CoronaVac IT no patients showed a significant increase in weal diameter (> 3 mm) between 15 and 30 min after injection compared with the initial weal. Interestingly, the IT with spike peptides produced a positive erythematous weal in four patients. In the BATs, the percentage of activated basophils (CD63/CCR3-positive cells) upon stimulation with CoronaVac were comparable with baseline controls and considered negative results (0.53% vs. 0.65%). For the four patients with a positive skin test, the percentages of

**Table 1** Clinical characteristics of seven patients who developed generalized urticaria within 4 h after CoronaVac injection.

Patient	Sex	Age, years	Underlying allergic conditions	Other systemic diseases	First vaccination	Symptoms (onset)	Treatment	Second vaccination	Symptoms (onset)	Treatment
1	F	39	None	Graves disease (euthyroid status)	CoronaVac	Generalized urticaria (40 min)	CPM	CoronaVac	None	NA
2	F	35	Allergic rhinitis	None	CoronaVac	Generalized urticaria (15 min)	None	ChAdOx1-S	Generalized urticaria (2 h)	CPM
3	F	35	Allergic rhinitis, chronic urticaria	None	CoronaVac	Localized urticaria (18 h)	LCT	CoronaVac	Generalized urticaria (5 min)	CPM
4	M	58	Shellfish allergy	None	CoronaVac	Generalized urticaria (30 min)	CPM, DEX	CoronaVac	None	NA
5	F	37	Allergic rhinitis, chronic urticaria	None	CoronaVac	Generalized urticaria (5 min)	LCT	CoronaVac	Generalized urticaria (5 min)	None
6	F	28	Allergic rhinitis	None	CoronaVac	Generalized urticaria (1 h)	CPM	CoronaVac	Generalized urticaria (15 min)	None
7	F	42	None	None	CoronaVac	Generalized urticaria (3 h)	FEX	CoronaVac	Generalized urticaria (2 h)	FEX

CPM, chlorpheniramine; DEX, dexamethasone; FEX, fexofenadine; LCT, levocetirizine; NA, not applicable.

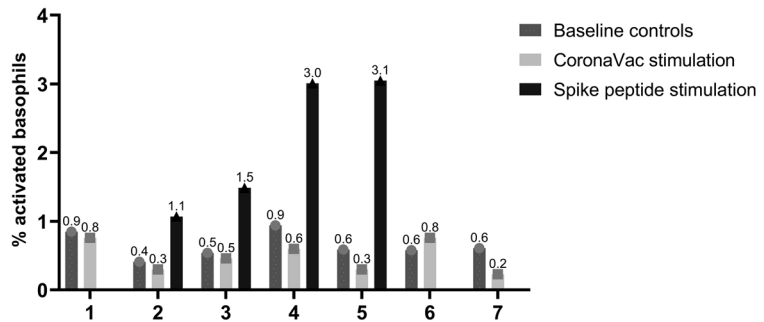
activated basophils upon stimulation with spike peptides did not reach the commonly used positive criteria (stimulation index  $\geq 2$  and activated basophils  $> 5\%$ <sup>5</sup>); however, the percentage (2.16%) was higher than in the baseline control groups (Fig. 1).

Based on these preliminary data, we could not confirm that IgE-mediated hypersensitivity was the cause of CoronaVac-associated urticaria, as the skin tests (SPT and IT) and BAT results were negative. Apart from the potential of aluminium-induced granuloma,<sup>6</sup> other excipients in CoronaVac are mineral salts, which are rarely allergenic. The fact that patients who developed urticaria within 4 h after CoronaVac vaccination in our study were successfully revaccinated, even though it triggered a relapse of urticaria in some of

them, indicates that, unlike anaphylaxis, acute urticaria alone should not be a contraindication for a second dose of CoronaVac if the supply of alternative vaccines is limited. Given that there are no crossreactive excipients between CoronaVac and the ChAdOx1 nCov-19 vaccine, it is possible that the immune response to vaccines may also be responsible for urticaria, as the rash still developed even after switching to the other type of vaccine in some cases.

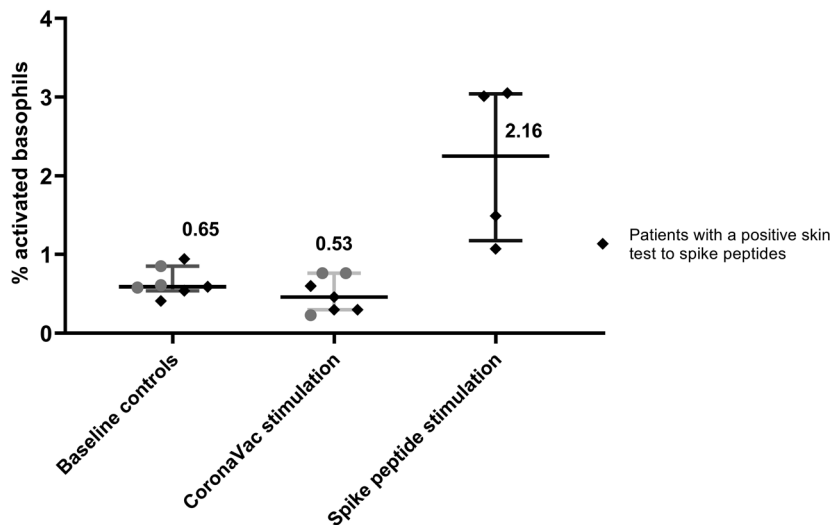
It is worth noting that the SARS-CoV-2-spike protein could induce a positive skin response and activate basophils to a certain extent in some individuals. A recurrent urticarial rash was recently reported in a patient with SARS-CoV-2 infection whose skin biopsy demonstrated a positive SARS-CoV-2 spike protein in

(a) Effects of CoronaVac whole vaccine and spike peptides on basophil activation



Patients with an immediate reaction to CoronaVac

(b) Basophil activation percentages upon stimulation with different reagents



**Figure 1** Effects of CoronaVac whole vaccine and spike peptides on basophil activation. Average percentages of activated basophils (median with interquartile range) in patients upon stimulation with spike peptides were higher than those at baseline and those upon stimulation with the CoronaVac vaccine.

the endothelium of the dermal blood vessels.<sup>7</sup> Therefore, we speculate that the urticarial rash that occurs in some patients after CoronaVac injection may not be due to allergic reaction to the vaccine excipients but rather that it could in sensitive subjects result from a crossreactive immune response to SARS-CoV-2-spike protein present from previous coronavirus infections. The effects of different concentrations of spike protein on the results of skin tests and BATs in patients who develop acute urticaria after exposure to inactivated whole SARS-CoV-2-vaccines should be determined in a larger sample size.

In summary, we found that patients developing acute urticaria after CoronaVac injection could safely be readministered the same vaccine, thus urticaria should not be an absolute contraindication for revaccination if the supply of alternative vaccines is limited. The pathogenic roles of the spike protein in inducing basophil/mast cell activation and urticaria in vaccinated subjects warrant further studies.

### Acknowledgement

This study was supported by the Skin and Allergy Research Unit, Chulalongkorn University.

### Learning points

- CoronaVac-associated urticaria is less likely to be IgE-mediated hypersensitivity to the vaccine.
- Acute urticaria alone after CoronaVac injection is not an absolute contraindication for revaccination.
- An immune response to the SARS-CoV-2-spike protein, rather than the vaccine excipients, may

play a role in the pathogenesis of CoronaVac-associated urticaria.

### References

- 1 Turner PJ, Ansotegui IJ, Campbell DE *et al.* COVID-19 vaccine-associated anaphylaxis: a statement of the World Allergy Organization Anaphylaxis Committee. *World Allergy Organ J* 2021; **14**: 100517.
- 2 Zhang Y, Zeng G, Pan H *et al.* Safety, tolerability, and immunogenicity of an inactivated SARS-CoV-2 vaccine in healthy adults aged 18–59 years: a randomised, double-blind, placebo-controlled, phase 1/2 clinical trial. *Lancet Infect Dis* 2021; **21**: 181–92.
- 3 Riad A, Sağiroğlu D, Üstün B *et al.* Prevalence and risk factors of CoronaVac side effects: an independent cross-sectional study among healthcare workers in Turkey. *J Clin Med* 2021; **10**: 2629.
- 4 Centers for Disease Control and Prevention What to do if you had an allergic reaction after getting a COVID-19 vaccine. Available at: <https://www.cdc.gov/coronavirus/2019-ncov/vaccines/safety/allergic-reaction.html> (accessed 11 July 2021).
- 5 Santos AF, Alpan O, Hoffmann H-J. Basophil activation test: mechanisms and considerations for use in clinical trials and clinical practice. *Allergy* 2021; **76**: 2420–32. <https://doi.org/10.1111/all.14747>
- 6 Vogelbruch M, Nuss B, Körner M *et al.* Aluminium-induced granulomas after inaccurate intradermal hyposensitisation injections of aluminium-adsorbed depot preparations. *Allergy* 2000; **55**: 883–7.
- 7 Welsh E, Cardenas-de la Garza JA, Cuellar-Barboza A *et al.* SARS-CoV-2 spike protein positivity in pityriasis rosea-like and urticaria-like rashes of COVID-19. *Br J Dermatol* 2021; **184**: 1194–5.