

# Sudden valproate-induced hyperammonemia managed with L-carnitine in a medically healthy bipolar patient

## Essential review of the literature and case report

Carlo Ignazio Cattaneo, MD<sup>a,\*</sup>, Francesca Ressico, MD<sup>a</sup>, Roberta Valsesia, MD<sup>b</sup>, Pierluigi D'Innella, MD<sup>b</sup>, Matteo Ballabio, MA<sup>a</sup>, Michele Fornaro, MD, PhD<sup>c</sup>

### Abstract

**Rationale:** Valproic Acid is a commonly used psychiatric drug primarily used as a mood stabilizer. Mild hyperammonemia is a Valproic Acid common adverse effect. This report presents an example of treated hyperammonemia on Valproic acid therapy managed with L-carnitine administration in BD patients characterized by sudden vulnerability.

**Patient concerns:** We report the case of a 29-year-old man suffering from bipolar disorder (BD) and substance use disorder who exhibited sudden altered mental status upon admittance to the inpatient unit. The patient was started on Valproic acid with no improvement.

**Diagnoses:** The patient had remarkably high ammonia levels (594  $\mu\text{g/dL}$ ) without hepatic insufficiency, likely due to his valproate treatment.

**Interventions:** The patient was administered lactulose, intravenous hydration, and i.v. levocarnitine supplementation 4.5 g/day.

**Outcomes:** The administration leads to reduction of ammonia levels to 99  $\mu\text{g/dL}$  within 12 hours upon initiation of carnitine therapy and progressive restore of his mental status within 24 hours.

**Lessons:** Resolution of hyperammonemia caused by Valproic acid therapy may be enhanced with the administration of L-carnitine. An interesting aspect of this case was how rapidly the patient responded to the carnitine therapy.

**Abbreviations:** AED = antiepileptic drug, AEs = adverse effects, AW = alcohol withdrawal, BD = bipolar disorder, BPD = borderline personality disorder, CBZ = carbamazepine, ECG = electrocardiography, EEG = electroencephalogram, i.m = intramuscular, i.v = intravenous, MR = mental retardation, o.s = oral administration, PB = phenytoin, PHT = phenobarbital, SUD = substance use disorder, TBI = traumatic brain injury, VHE = valproate-induced hyperammonemic encephalopathy, VPA = valproic acid.

**Keywords:** bipolar disorder, carnitine, hepatic dysfunction, hyperammonemia, neurotoxicity, valproic acid

## 1. Introduction

Valproic acid (VPA) is a broad-spectrum antiepileptic drug (AED) that inhibits degradation, and promotes postsynaptic transmission of gamma-aminobutyric acid (GABA).<sup>[1]</sup> VPA is

widely used for the treatment of epilepsy, migraine, and a variety of psychiatric symptoms, including bipolar disorder (BD), borderline personality disorder (BPD), and alcohol withdrawal (AW). VPA has been used effectively to reduce agitation and aggression in both acute and postacute traumatic brain injury (TBI) patients,<sup>[2,3]</sup> as well as a variety of other neuropsychiatric syndromes, including dementia and mental retardation (MR).<sup>[4]</sup>

Overall, VPA is well tolerated with respect to cognitive functioning, yet common, essentially dose-related, adverse effects (AEs) include fatigue, gastrointestinal disturbances, weight gain, tremor, hair loss, thrombocytopenia, teratogenicity. On the contrary, pancreatitis, hepatotoxicity, and hyperammonemia are infrequent AEs.<sup>[5]</sup>

Hyperammonemia can be defined as a serum level of ammonia higher than 50  $\mu\text{mol/L}$ . It can be due to genetic conditions in newborns involving metabolism or liver disease, such as carnitine deficiency, malignancies, or portosystemic shunts. Elevated levels of ammonia can also be secondary to certain medications, such as 5-fluorouracil, salicylate, asparaginase, acetazolamide, diuretics, and VPA. Ammonia levels are increased in 12% to 52% of asymptomatic patients treated with VPA.<sup>[6]</sup> A recent study examined the frequency of hyperammonemia in a sample of older adults taking VPA compared with those not taking such medication, documenting 2-fold increased risk for hyperammonemia following VPA intake.<sup>[7]</sup>

Editor: Mirko Manchia.

Informed consent was obtained from the patient for publication of this case report.

The authors report no conflicts of interest.

<sup>a</sup> Asl Novara, Department of Mental Health – Outpatient Unit, <sup>b</sup> Asl Novara, Department of Mental Health – Inpatient Unit- Borgomanero, Novara,

<sup>c</sup> Department of Neuroscience, University School of Naples “Federico II”, Naples, Italy.

\* Correspondence: Carlo Ignazio Cattaneo, Azienda Sanitaria Locale Novara, Borgomanero 28021, Novara, Italy (e-mail: dr.carloignaziocattaneo@gmail.com).

Copyright © 2017 the Author(s). Published by Wolters Kluwer Health, Inc. This is an open access article distributed under the terms of the Creative Commons Attribution-Non Commercial-No Derivatives License 4.0 (CCBY-NC-ND), where it is permissible to download and share the work provided it is properly cited. The work cannot be changed in any way or used commercially without permission from the journal.

Medicine (2017) 96:39(e8117)

Received: 23 May 2017 / Received in final form: 15 August 2017 / Accepted: 1 September 2017

<http://dx.doi.org/10.1097/MD.00000000000008117>

## 2. Case history

We report the case of a 29-year-old male with lifetime diagnosis BD, according to DMS-V criteria (APA, 2013), and substance use disorder (SUD) who was forcedly hospitalized due to aggressive behavior. His family history was negative for psychiatric illness, while his personal history was also positive for childhood epilepsy and characterized by several prior involuntary hospitalizations occurred in similar contexts, and a poor compliance to both psychiatric interviews and medications. He was receiving haloperidol decanoate 150 mg q 28 days: the latest injection had been administered 4 days before hospitalization. His current SUD involved both nicotine and substances of abuse; urine toxicology screen performed at the Emergency Department (E.R.) documented the following records: opioids >2000 ng/mL (negative <300); cocaine >5000 ng/mL (negative <300); benzodiazepines 898 ng/mL (negative <200); buprenorphine 13 ng/mL (negative <5). Hemochrome, serum electrolytes, and liver functioning were within normal ranges, as the electrocardiography (ECG) tracking was.

Upon admission, he was alert and oriented to the person, place, and time. He was irritable and aggressive. He was started on VPA 1000 mg/day, lorazepam 7.5 mg/day, flurazepam 30 mg/day per o.s. (oral administration), and clotiapine 120 mg/day i.m. (intramuscular), which was later switched to oral formulation. One week upon admission, plasma valproate level was 73 µg/dL (reference range 27–102).

Despite the pharmacological treatment, he was still disputatious, irritable, suspicious, interpretative; he kept refusing treatment and going against any rehabilitation program.

Thus, VPA was slowly increased up to 1800 mg/day, clotiapine and flurazepam were stopped, while he started chlorpromazine 100 mg/day and haloperidol 6 mg/day.

Twenty days later, he showed no improvement in agitation, rather he was still fluctuating between aggressiveness and altered consciousness through lethargy, altogether with an altered walking mobility, characterized by an irregular gait pattern with a widened base of support and a decreased step length. His blood test revealed plasma valproate 124 µg/dL; serum ammonia was strikingly high—594 µg/dL, while his liver function was within normal range: aspartate aminotransferase (AST) 10 U/L, alanine aminotransferase (ALT) 8 U/L, gamma-glutamyl transpeptidase (GGT) 12 U/L, alkaline phosphatase (ALP) 59 U/L, prothrombin time International Normalized Ratio (PT INR) 1.13, Prothrombin Time Ratio (PR) 1.13, albumin 4.6 g/dL. Blood pressure was 110/70 mm Hg and the heart rate was 88 bpm. His temperature was 36.3°C and his respiratory rate was 20 breaths/min.

The patient was not delivered to the intensive care unit, rather he was treated on-site. VPA and antipsychotics were withdrawn, and he was administered lactulose (20 g orally 3 times a day), intravenous (i.v.) hydration (1500 mL/24 h), and i.v. L-carnitine supplementation 4.5 g/day diluted in 0.9% sodium chloride infusion solution. This latter treatment schedule was then administered for 2 consecutive days.

Ammonia levels reduced to 99 µg/dL about 12 hours following initiation of carnitine therapy; the patient's mental status gradually improved back to baseline over 24 hours. At that time, plasma VPA was back within therapeutic limits (65 µg/dL).

Four days later, he underwent EEG (electroencephalogram), which showed short sequences of slow-wave theta activity across the temporal cortex, bilaterally, yet the baseline EEG tracing was evaluated as normal. Abdominal ultrasonography showed a

slightly enlarged liver, yet homogeneous in structure and free from focal lesions; gallbladder and bile ducts were also normal.

Twelve days after being diagnosed with hyperammonemia, he was alert, calm, cooperative, euthymic; impulsiveness had recovered, motricity was normal. He was then discharged in good clinical conditions (Fig. 1).

## 3. Discussion

VPA can cause hyperammonemia in the setting of both high and therapeutic drug levels without evidence of hepatic dysfunction. Prompt measurement of serum ammonia should be considered when there is a decreased level of consciousness in patients receiving VPA irrespective of the diagnosis and even after a long-term exposure.

Hyperammonemia can be asymptomatic or may progress to focal neurological deficit, seizure, marked sedation, coma, due to encephalopathy. Clinically significant AEs occur in approximately 10% of the patients showing valproate-related hyperammonemia, with ammonia levels about 2-fold increased beyond normal ranges (35–65 µmol/L). Yet, conclusive relationship between the daily doses of VPA and the onset and severity of VHE (valproate-induced hyperammonemic encephalopathy) has not been established.<sup>[8]</sup> A direct relationship between the development of VHE and serum VPA levels seems excluded, even though data available in literature are not concordant.

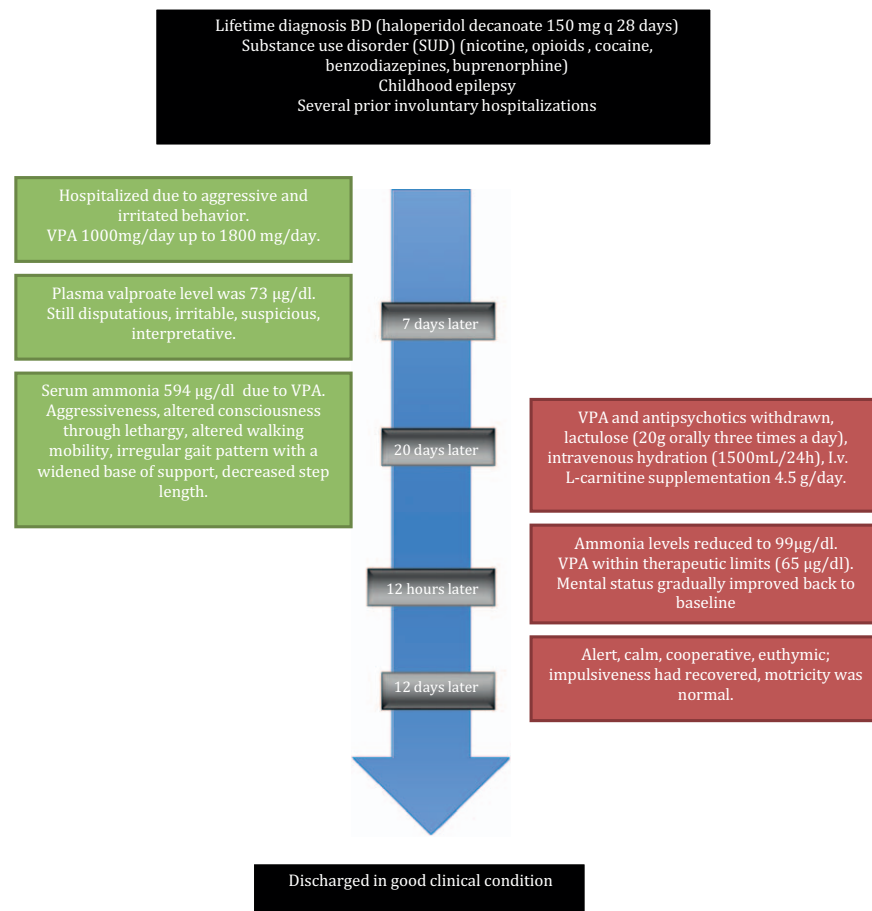
VPA is known to be associated with decreased carnitine levels and occasionally true deficiency, which is an unusual problem in the healthy, well-nourished adult population. VPA depletes carnitine storages through different mechanisms, usually in long-term or high-dose treatment<sup>[9,10]</sup>; the effects of VPA on urea metabolism occur primarily in the liver mitochondria, via the inhibition of the enzyme required for the first step in the urea cycle, CPS1.<sup>[11]</sup> This may lead to a dose-independent increase in the concentration of its substrate, ammonia, in the blood.<sup>[12]</sup> Carnitine results also necessary in the mitochondria for the transport and the subsequent oxidation of fatty acids.<sup>[13]</sup> VPA inhibits carnitine transport, causing the increase in renal carnitine excretion.<sup>[14]</sup> Indeed, a carnitine deficiency leads to the reduction of fatty acids metabolism and the successive increase of protein utilization. VPA also accelerates ammonia production by the kidney<sup>[13]</sup>

L-carnitine is an aminoacid derivative and important nutrient involved in fat metabolism. Up to 75% of L-carnitine is provided by diet, particularly red meat and dairy products. It is also biosynthesized endogenously from dietary amino acids (methionine, lysine), especially in the liver and in the kidneys.<sup>[15]</sup> Carnitine is responsible for 2 metabolic functions. It eases the fatty acyl-group transport into mitochondria and it also preserves the ratio of acyl-CoA to free CoA in the mitochondria.<sup>[16]</sup>

Carnitine supplementation has been suggested in the treatment of a variety of health conditions such as cardiomyopathies, diabetic neuropathy, tuberculosis, dementia, renal failure, and anemia, and has been added to newborns' foods and milk, even though data are preliminary.<sup>[17]</sup>

As VPA-induced hyperammonemia and VHE could be mediated at least in part by carnitine deficiency, it has been hypothesized that L-carnitine supplementation may prevent, correct, or attenuate these AEs.<sup>[16]</sup>

VPA-induced hyperammonemia is an AE that may be prevented, corrected, or attenuated by L-carnitine supplementation because of VHE mediation, at least partly, by carnitine deficiency.<sup>[16]</sup>



**Figure 1.** Valproate-induced hyperammonemia development and treatment: timeline of a case report.

Bohan et al [18] analyzed the association of L-carnitine treatment with hepatic survival in 92 patients with severe, symptomatic, VPA-induced hepatotoxicity, reporting that prompt intervention with i.v. rather than enteral L-carnitine was associated with the greatest hepatic survival. Because of the low (15%) bioavailability of enteral L-carnitine, the better survival with i.v. treatment may be related to higher blood levels.

Some Authors [19,20] also suggest that carnitine might be considered as a novel therapeutic option in the management of depression and associated mood disorders, as well as attention-deficit hyperactivity disorder. Fernandes [21] reviewed the emerging evidence on the role of carnitine in mood disorders, yet results are not univocal: some studies examined depression scores in further detail after 12 weeks of carnitine treatment, whereas others found no statistically significant negative correlation between patients' depression scores and total levels of serum carnitine. Carnitine supplementation has also been advocated in chronic VPA treatment, but data are limited [21].

In addition, patients who are treated with multiple anti-convulsants—such as VPA combined with PHT (phenobarbital), PB (phenytoin), or CBZ (carbamazepine)—are at a higher risk of developing hyperammonemia [22]. Yamamoto et al [23] evaluated a total of 2944 epileptic pediatric patients to identify risk factors for hyperammonemia: the authors observed that the mean ammonia level of the patients on VPA along with AEDs was significantly higher than that of those on VPA monotherapy, especially when VPA was combined to PHT or PB, rather than

CBZ. The patient described herein was not suffering from epilepsy, thus was not taking any other AED, which would have increased his risk of developing hyperammonemia (and contributed to hindered interpretation of the results due to confounding bias). His VPA serum levels were normal, but as we previously observed, data in literature are not concordant with respect to a direct relationship between the development of VHE and serum VPA levels. Moreover, he had previously been treated with VPA, without developing hyperammonemia, which reasonably allows us to exclude a genetically inherited urea cycle disorder, even though genetic testing was not performed.

In conclusion, resolution or prevention of hyperammonemia may be enhanced with the administration of L-carnitine, yet further investigation is required. An interesting aspect of this case was how rapidly the patient responded to the carnitine therapy.

## References

- [1] Davis LL, Ryan W, Adinoff B, et al. Comprehensive review of the psychiatric uses of valproate. *J Clin Psychopharmacol* 2000;20(1 Suppl 1):1S–7S.
- [2] Chatham Showalter PE, Kimmel DN. Agitated symptom response to divalproex following acute brain injury. *J Neuropsychiatry Clin Neurosci* 2000;12:395–7.
- [3] Wroblewski BA, Joseph AB, Kupfer J, et al. Effectiveness of valproic acid on destructive and aggressive behaviours in patients with acquired brain injury. *Brain Inj* 1997;11:37–47.
- [4] Lindenmayer JP, Kotsaftis A. Use of sodium valproate in violent and aggressive behaviors: a critical review. *J Clin Psychiatry* 2000;61:123–8.

- [5] Nanau RM, Neuman MG. Adverse drug reactions induced by valproic acid. *Clin Biochem* 2013;46:1323–38.
- [6] Murphy JV, Marquardt K. Asymptomatic hyperammonemia in patients receiving valproic acid. *Arch Neurol* 1982;39:591–2.
- [7] Adler LW, Regenold WT. Valproate-related hyperammonemia in older adult psychiatric inpatients. *Prim Care Companion CNS Disord* 2015; 17: E-collection 2015.
- [8] Verrotti A, Trotta D, Morgese G, et al. Valproate-induced hyperammonemic encephalopathy. *Metab Brain Dis* 2002;17:367–73.
- [9] Ishikura H, Matsuo N, Matsubara M, et al. Valproic acid overdose and L-carnitine therapy. *J Anal Toxicol* 1996;20:55–8.
- [10] Raskind JY, El-Chaar GM. The role of carnitine supplementation during valproic acid therapy. *Ann Pharmacother* 2000;34:630–8.
- [11] Ghodke-Puranik Y, Thorn CF, Lamba JK, et al. Valproic acid pathway: pharmacokinetics and pharmacodynamics. *Pharmacogenet Genomics* 2013;23:236–41.
- [12] Wadzinski J, Franks R, Roane D, et al. Valproate-associated hyperammonemic encephalopathy. *J Am Board Fam Med* 2007;20:499–502.
- [13] Bezinover D, Postula M, Donahue K, et al. Perioperative exacerbation of valproic acid-associated hyperammonemia: a clinical and genetic analysis. *Anesth Analg* 2011;113:858–61.
- [14] Camina MF, Rozas I, Castro-Gago M, et al. Alteration of renal carnitine metabolism by anticonvulsant treatment. *Neurology* 1991;41:1444–8.
- [15] Borum PR, Bennett SG. Carnitine as an essential nutrient. *J Am Coll Nutr* 1986;5:177–82.
- [16] Lheureux PE, Penalosa A, Zahir S, et al. Science review: carnitine in the treatment of valproic acid-induced toxicity: what is the evidence? *Crit Care* 2005;9:431–40.
- [17] Evangelidou A, Vlassopoulos D. Carnitine metabolism and deficit: when supplementation is necessary? *Curr Pharm Biotechnol* 2003;4: 211–9.
- [18] Bohan TP, Helton E, McDonald I, et al. Effect of L-carnitine treatment for valproate-induced hepatotoxicity. *Neurology* 2001;56:1405–9.
- [19] Tobe EH. Mitochondrial dysfunction, oxidative stress, and major depressive disorder. *Neuropsychiatr Dis Treat* 2013;9:567–73.
- [20] Anglin RE, Mazurek MF, Tarnopolsky MA, et al. The mitochondrial genome and psychiatric illness. *Am J Med Genet B Neuropsychiatr Genet* 2012;159B:749–59.
- [21] Fernandes R. Acetyl-L-carnitine for depression and mood disorders. *J IHP*. 2014:73–79.
- [22] Mock CM, Schwetschenau KH. Levocarnitine for valproic-acid-induced hyperammonemic encephalopathy. *Am J Health Syst Pharm* 2012; 69:35–9.
- [23] Yamamoto Y, Takahashi Y, Imai K, et al. Risk factors for hyperammonemia in pediatric patients with epilepsy. *Epilepsia* 2013;54: 983–9.