

CASE REPORT

doi: 10.5455/medarch.2018.72.285-288

MED ARCH. 2018 AUG; 72(4): 285-288

RECEIVED: MAY 20, 2018 | ACCEPTED: JUL 20, 2018

¹Special Hospital Heart Center BH Tuzla, Tuzla, Bosnia and Herzegovina

²Faculty of Pharmacy, University of Tuzla, Tuzla, Bosnia and Herzegovina

Corresponding author: Azra Avdic Salihovic, MD. Department of Cardiology, Special Hospital Heart Center BH Tuzla. Alekse Santica 8, 75000 Tuzla, Bosnia and Herzegovina, ORCID ID: 0000-0002-0044-802X, Phone: ++38761648157. E-mail: azra.avdic@bhsrce.ba

Successful Treatment of Cardiac Tamponade with Corticosteroids After Surgical Myocardial Revascularization: Case Report

Azra Avdic Salihovic¹, Edis Salihovic¹, Nedžad Kadric¹, Merima Ibisevic², Sevleta Avdic¹

ABSTRACT

Aim: The aim of this case report is to show the significance of the cardiac tamponade, it's timely diagnosis and to present the unusual approach of the treatment. That was conducted with corticosteroids when the surgical procedure gave no results in rare cases like this. **Case Report:** This paper presents the case of a man aged 72 years with a verified tamponade of pericardium. A large pericardial effusion with tamponade signs was verified by ultrasound and computerized tomography (CT) of the chest in a hemodynamically stable patient, and in the inability to evacuate the same, with pericardial fenestration, was successfully treated with corticosteroids. **Conclusion:** A large pericardial effusion with the signs of tamponade verified by echocardiography and computerized tomography, in hemodynamically stable patient, and in the inability to evacuate the same by fenestration, was treated successfully with corticosteroids.

Keywords: pericardial effusion, heart tamponade, corticosteroids.

1. INTRODUCTION

Pericardial effusion is a common complication after surgery on the heart, but rare is the case of unusual localisation and the unusual size of the effusion with the features of tamponade. It can be also resistant to conventional therapy leading to prolonged in-hospital stay and worsening of clinical conditions (1). Around 22% of patients with pericardial effusion, two weeks after surgery, are asymptomatic. Taking into account that 10% of them may develop tamponade of the pericardium a month after surgery, timely diagnosis is of a great importance (2). It is a condition that requires an urgent evacuation of fluid from a pericardial sac (pericardiocentesis or fenestration).

2. CASE REPORT

A man aged 72 years underwent elective surgery, a surgical revascularization of the myocardium, for a previously verified triple vessel coronary artery disease (CAD) with LAD 100%, CX 90%, RCA 90%. In the previous history of the disease he had diabetes mellitus type 2, arterial hypertension, myocardial infarction, hyperlipidemia and a positive family history of cardiovascular diseases.

The operation and early postoperative recovery went without any complications, and the patient was discharged on home care by protocol. On the first postoperative visit, 15 days after surgery, echocardiography showed a neat finding and upon recommendation, the patient continued with the previous treatment recommended for discharge. A month after the first visit or two months after the surgery, the patient was sent from a local hospital to our Heart Center with verified pericardial effusion and with the susceptible signs of right ventricular compression. At this point the patient had symptoms like fatigue and mild chest pain, more on his left side. On physical examination there were slightly pointed veins on the neck. He was afebrile and with neat diuresis. Heart tones were quieter, without murmurs and the action of the heart was rhythmic. Auscultatory findings on the lungs were without pathological murmurs. Measured blood pressure was 90/60 mmHg and the pulse was 96/min. Laboratory blood tests were in reference values range (white blood count - WBC, CRP). In addition to other discharge therapy, he had all

© 2018 Azra Avdic Salihovic, Edis Salihovic, Nedžad Kadric, Merima Ibisevic, Sevleta Avdic

This is an Open Access article distributed under the terms of the Creative Commons Attribution Non-Commercial License (<http://creativecommons.org/licenses/by-nc/4.0/>) which permits unrestricted non-commercial use, distribution, and reproduction in any medium, provided the original work is properly cited.

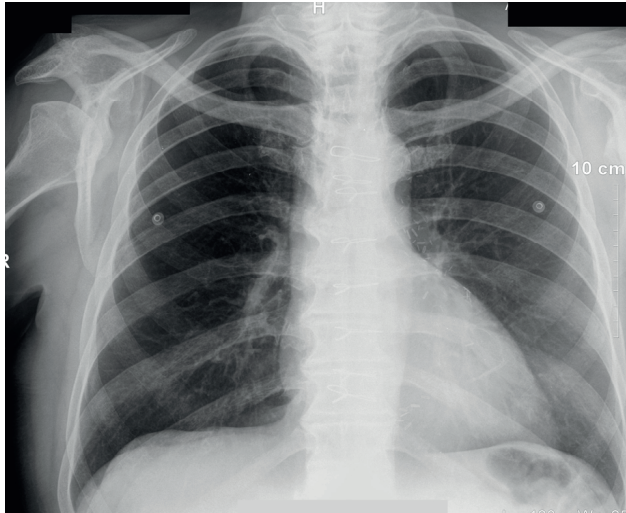


Figure 1. Chest-X Ray without the strong signs of the pericardial effusion that time acetylsalicylic acid 100 mg and clopidogrel 75 mg, without anticoagulation therapy.

The patient was kept for the observation. On the admission, a X-ray P/A of the chest was performed, that showed a regular size of the heart (Figure 1). Transthoracic echocardiography (TTE) showed free fluid by the lateral and posterior wall of the right ventricle and possible compression of it, but there was no visible fluid in some views e.g. long axis view (Figure 2). Due to a difficult visualization, it was recommended, at that time, to observe the patient and do frequent echo monitoring of pericardial effusion while making a decision about treatment. Echocardiographic findings showed also a preserved ejection fraction of the left ventricle and restrictive left ventricular filling.

After 24 hours, a control echocardiographic finding was performed and showed a large amount of the free fluid (around 2,7cm) by the right ventricle and apex, which significantly compressed the right ventricle cavity in the diastole and narrowed it, so that the opposite walls touched themselves (Figure 3). The heart team decided to evacuate the free fluid by fenestration in the general anesthesia. During the operation transesophageal echocardiography (TEE) was performed, but surprisingly it was impossible to verify the large amount of the fluid seen with other diagnostic procedures, in all cross sections. Because of the possibility of the right ventricle rupture, after several attempts to find the fluid, the heart team gave up from further manipulations and closed the patient. The patients problem was not solved so the heart team decided to do the computerized tomography (CT) of the thorax. On the recorded image, the left segment of the heart was enlarged, with pericardial effusion on the anterior side of the heart and especially in caudal aspect. By this diagnostic procedure the pericardial effusion with tamponade of left ventricle was confirmed (estimated amount of fluid was 380-400 mL).

On the control TTE echocardiography, persists the large amount of free fluid by the right ventricle and apex (around 2,7 cm) with the movements and compression also by the posterior wall of the left ventricle (around 2,7 cm). Due to the impossibility to evacuate the fluid by fenestration, and because the patient was still hemodynam-

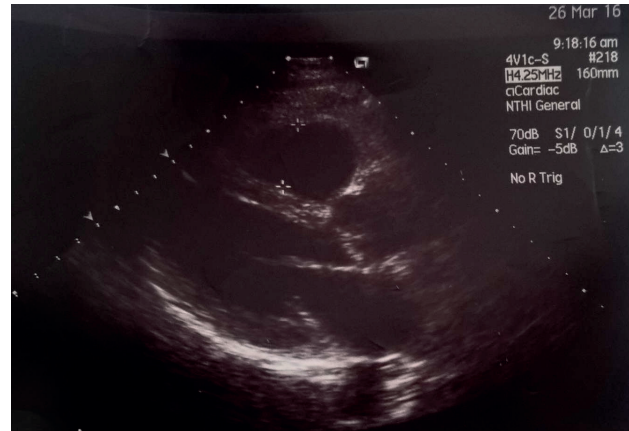


Figure 2. Transthoracic echocardiography (TTE) – Long axis view, where there are no signs of pericardial effusion

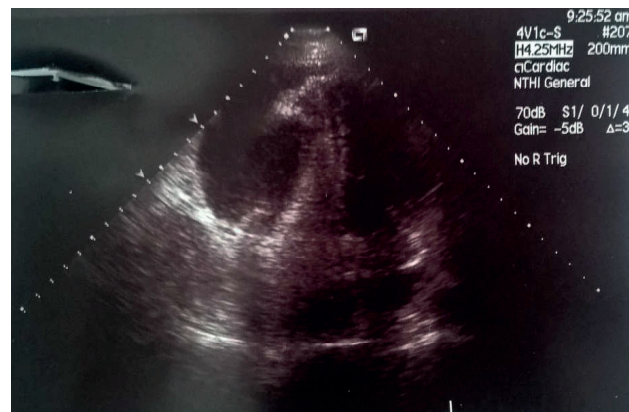


Figure 3. Transthoracic echocardiography (TTE) that shows free fluid by the lateral wall of the right ventricle and compression of it

ically stable, he was observed in our Center for several days, for the possible evacuation of pericardial fluid by opening the chest. After a few days of monitoring with the patient still stable, he was transferred to the local hospital for further monitoring with the new drug included in his therapy, a nonsteroidal anti-inflammatory drugs (NSAIDs) - Ibuprofen 600 mg to use it three times a day, during the follow up.

After two postoperative visits, in a monitoring period of two months, it persisted the same echocardiography finding, without any progression compared to previous findings and the patient was hemodynamically stable. Even in two months after the fenestration, with recommended therapy, there was no achievement. The patient was still being monitored, so it was decided to add new drug to the previous therapy. Due to a lack of Colchicin, that is mentioned in Guidelines as the next step, in the therapy was included Prednisone, a corticosteroidal drug, also mentioned in the Guidelines as one option. It was administered according to scheme with gradual dose reduction, as recommended (Table 1).

One month after the introduction of corticosteroidal therapy, echocardiography (TTE) showed a significant reduction of the pericardial effusion, and there was no compression on the right ventricle, like earlier verified. Considering the reduction of pericardial effusion, it was recommended to gradually reduce the corticosteroids and eventually exclude it. The patient was monitored

Average dose 0,25 – 0,50 mg/kg/day	Dose reduction
> 50 mg	10mg/day every 1 to 2 weeks
> 50 – 25 mg	5-10 mg/day every 1 to 2 weeks
> 25 – 15 mg	2,5 mg/day every 2 to 4 weeks
> 15 mg and less	1,25 – 2,5 mg/day every 2 to 6 weeks

Table 1. Gradual dose reduction of corticosteroidal therapy - Prednison

with frequent echocardiography findings. During all that time no side effects were observed.

Four months after introduction of combined therapy with NSAIDs and corticosteroids, echocardiography verified a complete reduction of pericardial effusion and the right ventricle had a neat triangular form. The treatment was considered successful. The patient was asymptomatic, so the therapy for pericardial effusion was completely excluded, after which the patient was monitored in every six months. After six months of good general condition, completely asymptomatic patient was without any sings of pericardial effusion, what was confirmed on echocardiography findings.

3. METHODS

Article has descriptive character and presents case report. All facts related to this case were compared to the valid Guidelines from 2015, that are dealing with the treatment of pericardial effusion. Studies dealing with similar issues were also used.

4. DISCUSSION

In the presented case report, due to an unusual localisation of pericardial effusion, a different or unusual treatment was administered. Invasive treatment, pericardiocentesis under ultrasound control and pericardial fenestration are commonly used when rapid evacuation of free fluid from pericardial sac is needed. In this case, heart team made a decision for pericardial fenestration. Due to the impossibility to evacuate the fluid by fenestration, because of unusual localisation of it, the only possible method to evacuate the fluid was to open the chest, but the comorbidity and the patient’s age would increase the risk for the patient regardless the outcome. In addition, the patient was against this method of treatment. The only option remaining was the use of corticosteroids.

Standard treatment of pericardial effusion involves acetylsalicylic acid or NSAIDs. Ibuprofen (300-800 mg every 6-8 hours) is the first choice in the treatment, because it has the least side effects and a beneficial effect on the flow of coronary arteries. The studies have shown that Colchicin in a dose of 0,5 mg per day in combination with the NSAIDs or Colchicin alone, provides better results in the treatment of pericardial effusion. Treatment with the corticosteroids should be used only for connective tissue disorders, uremic pericarditis and chronic pericarditis that has no response on Colchicin (3).

There is little published information with regard to corticosteroidal management of pericardial effusion and tamponade. One study had worked on the detection and measurement of pericardial effusion size in a number of patients following heart surgery (780 samples in this study). Pericardial effusion was detected in 64% of the patients. From this number more of them

were after coronary artery bypass graft surgery (CABG), than in valvular surgery. Of these, 68,4% were minor effusions, 29,8% were mild and 1,6% were large. Heart tamponade developed in 1,9% patients included in this study (4) characteristics, and hemodynamic consequences of pericardial effusion after cardiac surgery. DESIGN - Clinical, echocardiographic, and Doppler evaluations before and 8 days after cardiac surgery; with echocardiographic and Doppler follow up of patients with moderate or large pericardial effusion after operation. SETTING - Patients undergoing cardiac surgery at a tertiary center. PATIENTS - 803 consecutive patients who had coronary artery bypass grafting (430).

There is also another condition that needs to be excluded to differentiate this case. That condition is post - pericardiotomy syndrome (PPS) caused by surgical trauma, also called Dressler’s syndrome (5) post-pericardiotomy syndrome, and post-traumatic pericarditis (iatrogenic, i.e. after percutaneous coronary or intracardiac interventions, such as pacemaker lead insertion, radio frequency ablation, or non-iatrogenic, i.e. following blunt or penetrating trauma. Dressler’s syndrome (DS) is a form of secondary pericarditis with or without a pericardial effusion, that occurs as a result of injury to the heart or pericardium. Though not a common condition, DS should be considered in all patients presenting with persistent malaise or fatigue, following a myocardial infarction (MI) or cardiac surgery, especially if symptoms present greater than two weeks following the event (6).

In one report, non complicated PCIS was defined as the presence of temperature greater than 100.5° F (38° C), patient irritability, pericardial friction rub, and a small pericardial effusion with or without pleural effusion following cardiac trauma. The incidence of PCIS is approximately 1% after myocardial infarction and is somewhat higher after cardiac surgery. The exact pathogenesis of this syndrome is unknown, but it appears to have an immunologic basis (7).

The syndrome typically develops about 3 weeks after the injury, but it can happen any time between 3 days and 1 year. The two cardinal symptoms are fever and chest pain. Pulmonary opacities are present in about 50% of patients, and laboratory evaluation reveals leukocytosis with an elevated erythrocyte sedimentation rate. The diagnosis of the syndrome is established by the clinical picture and by excluding CHF, PE, and pneumonia (7).

Echocardiography plays an essential role in diagnosis and management of large pericardial effusions after open heart surgery. Patients with large pericardial effusions who are clinically stable need only medical management, including serial echocardiograms, but drainage is indicated if the cardiovascular or respiratory status worsens (8).

According to the clinical manifestations and laboratory results, with no fever and with normal white blood cells count in this case we have excluded the Dressler’s syndrome.

Based on available literature and articles, access to the treatment of pericardial effusion and cardiac tamponade in the presented case does not deviate much from the

Guidelines. Given the inaccessibility of Colchicin and the inability to evacuate the fluid from pericardial sac by fenestration, the only method left for treatment was to use corticosteroids regardless to comorbidities.

5. CONCLUSION

A large pericardial effusion with the signs of tamponade verified by echocardiography and computerized tomography, in hemodynamically stable patient, and in the inability to evacuate the same by fenestration, was treated successfully with corticosteroids.

- **Author's contribution:** all authors equally participated in preparing this case report. Final proof reading made by the first author.
- **Conflict of interest:** none declared.
- **Declaration of patient consent:** Authors certify that they have obtained patient consent form.

REFERENCES

1. Dainese L, Cappai A, Biglioli P. Recurrent pericardial effusion after cardiac surgery: the use of colchicine after recalcitrant conventional therapy. *J Cardiothorac Surg.* 2011; 6(1): 96. doi: 10.1186/1749-8090-6-96.
2. Adler Y, Charron P, Imazio M, Badano L, Barón-Esquivias G, Bogaert J, et al. 2015 ESC Guidelines for the diagnosis and management of pericardial diseases The Task Force for the Diagnosis and Management of Pericardial Diseases of the European Society of Cardiology (ESC) Endorsed by: The European Association for Cardio-Thoracic Surger. *Eur Heart J.* 2015; 36(42): 2921.
3. Maisch B, Ristić AD. Practical aspects of the management of pericardial disease. *Heart.* 2003; 89. doi: 10.1136/heart.89.9.1096.
4. Pepi M, Muratori M, Barbier P, Doria E, Arena V, Berti M, et al. Pericardial effusion after cardiac surgery: incidence, site, size, and haemodynamic consequences. *Br Heart J.* 1994 Oct 1; 72(4): 327 LP-331.
5. Imazio M, Hoit BD. Post-cardiac injury syndromes. An emerging cause of pericardial diseases. *Int J Cardiol.* 2013 Sep 30; 168(2): 648-652.
6. Foris LA, Bhimji SS. Dressler Syndrome. *StatPearls.* StatPearls Publishing; 2018. Available from: <http://www.ncbi.nlm.nih.gov/pubmed/28723017>
7. Broaddus VC, Light RW. Pleural Effusion. In: Murray and Nadel's Textbook of Respiratory Medicine. Elsevier; 2016: 1396-1424.e10.
8. D'Cruz IA, Dick A, Pai GM, Kamath M V. Large pericardial effusion after cardiac surgery: role of echocardiography in diagnosis and management. *South Med J.* 1989 Mar; 82(3): 287-291.