



# Successful Treatment of Covid-19 Associated Cytokine Release Syndrome with Colchicine. A Case Report and Review of Literature

Nahal Mansouri<sup>a,b</sup>, Majid Marjani<sup>c</sup>, Payam Tabarsi<sup>c</sup>, Christophe von Garnier<sup>a</sup>, and Davood Mansouri<sup>b,c,d</sup>

<sup>a</sup>Division of Pulmonary Medicine, Department of Medicine, Lausanne University Hospital (CHUV), University of Lausanne (UNIL), Lausanne, Switzerland; <sup>b</sup>Department of Clinical Immunology and Infectious Diseases, National Research Institute of Tuberculosis and Lung Diseases, Shahid Beheshti University of Medical Sciences, Tehran, Iran; <sup>c</sup>The Clinical Tuberculosis and Epidemiology Research Center, National Research Institute of Tuberculosis and Lung Diseases, Shahid Beheshti University of Medical Sciences, Tehran, Iran; <sup>d</sup>Pediatric Respiratory Diseases Research Center, National Research Institute of Tuberculosis and Lung Diseases, Shahid Beheshti University of Medical Sciences, Tehran, Iran

## ABSTRACT

We describe the case of a 42 year old, healthy patient with Covid-19 who despite improvement in his respiratory symptoms developed a mild to moderate cytokine release syndrome (CRS) and an associated monoarticular gout flare. Since the patient refused admission to the hospital and had stable vital signs, we chose to treat him with a safe anti-inflammatory and non-immunosuppressive therapy. To hit two birds with one stone, we considered colchicine, as it has systemic anti-inflammatory effects and is also effective in gout flare. Unexpectedly, 48 hours after treatment, not only did his ongoing fever and toe pain disappear, he also had significant improvements in his general state of health and all his inflammatory markers including fibrinogen, ferritin, D-dimer, and IL-6 levels normalized. To our knowledge, the use of colchicine in Covid-19 and CRS has not been reported. This observation merits the consideration of colchicine as a safe, inexpensive and oral medication for the treatment of mild to moderate CRS in Covid-19 patients. More importantly, in Covid-19 patients with early lung involvement colchicine may be an appropriate candidate to prevent CRS in adjunction with routine antiviral agents. Indeed, multicenter, randomized controlled studies are required to evaluate the benefits of this therapy.

## KEYWORDS

Cytokine Release Syndrome; Covid-19; colchicine; gout flare; pain

## Introduction

Cytokine release syndrome (CRS) is a systemic inflammatory response caused by drugs, autoimmune diseases, and infections; it is characterised by fever, multiorgan dysfunction, and, in a rare case, crystalline arthritis (Chung et al. 2019; Moore and June 2020). Laboratory results show elevated inflammatory cytokines such as interleukin (IL)-2, IL-6, TNF-alpha, and nonspecific markers of inflammation such as C-reactive protein (CRP), ESR, ferritin, fibrinogen, and D-dimer. CRS is commonly seen in severe cases of Covid-19. Elevated ferritin, CRP, and IL-6 are suggested as predictors of respiratory failure and fatality

**CONTACT** Nahal Mansouri ✉ Nahal.mansouri@chuv.ch 📧 Division of Pulmonary Medicine, Department of Medicine, Lausanne University Hospital (CHUV), University of Lausanne (UNIL), Lausanne, Switzerland

(Moore and June 2020; Zhang et al. 2020). We report a patient with CRS associated with Covid-19 infection and a new gout flare following resolution of respiratory symptoms.

## Case description

A 42-year-old non-smoker man with no prior medical history presented to our clinic with fever, dry cough, myalgia, weakness, and sore throat beginning 3 days earlier. His vital signs were normal except for a fever of 38.5°C. He had an oxygen saturation level of 94% while breathing ambient air. The physical exam revealed scattered bilateral crackles on auscultation and was otherwise normal. Laboratory results and reference ranges can be found in Table 1. In brief, white blood cell (WBC), hemoglobin and platelet count were normal. He had a slightly elevated C-reactive protein (CRP, 15 mg per deciliter), erythrocyte sedimentation rate (ESR, 12 mm per hour), and Ferritin level was normal (254 ng per milliliter). Two sets of blood cultures and a urine culture were sterile. A nasopharyngeal swab PCR was negative for all respiratory viruses except Covid-19 (positive on two occasions 24 hours apart). Chest computed tomography (CT) revealed bilateral basilar ground glass opacities (Figure 1). The patient was started on oseltamivir 75 mg twice a day and hydroxychloroquine 200 mg twice a day for 5 days. Respiratory symptoms improved 5 days following his presentation. However, fever, fatigue, and loss of appetite persisted.

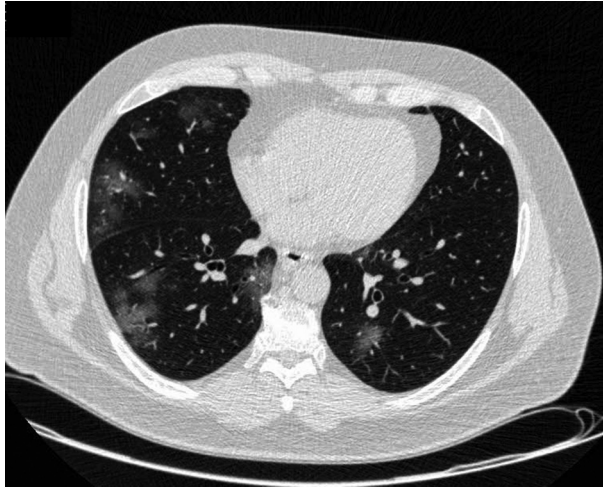
On day 10, the patient experienced a stabbing pain in his right first metatarsal joint. This was associated with warmth and severe tenderness on the region, however no erythema or edema was apparent. Off note, the patient had no history of gout until this presentation.

This presentation was associated with a fever of 40°C with shaking chills, headache, severe myalgia, and a decrease in his urine output. On physical exam he had a blood pressure of 118/72 mm Hg, pulse rate of 95 beats per minute, and respiratory rate of 14 breaths per minutes

**Table 1.** Laboratory results.

Variable	Reference range, adult	On presentation	Day 10, prior colchicine	Day 24, after colchicine
Sodium (mmol/liter)	136–148	142	144	141
Potassium (mmol/liter)	5/3/2005	3.8	4.4	4.3
Creatinine (mg/dl)	0.9–1.3	1	1.4	0.86
Urea nitrogen (mg/dl)	Sep-21	16	24	14
Aspartate transaminase (u/liter)	<37	18	41	24
Alanine transaminase (u/liter)	<41	32	76	50
Alkaline phosphatase (U/liter)	80–306	199	320	201
Ceatine phosphokinase (U/liter)	39–308	110	186	140
Triglyceride (mg/dl)	<200	138	142	x
Uric acid (mg/dl)	3.6–8.2	7	8.8	7.3
White blood cell (per ul)	4000–10500	9400	10100	7100
Neutrophiles (%)	40–80	67.6	75	46.8
Lymphocytes (%)	20–40	21.6	21	42.7
Hemoglobin (g/dl)	13.5–17.5	15.5	14.5	14.9
Platelet count (per ul)	150000–350000	282000	407000	379000
C-reactive protein (mg/liter)	<6	15	62	undetectable
Erythrocyte sedimentation rate (mm/hr)	0–10	12	75	10
D-dimer (ng/ml)	<500	x	7123	530
Ferritin (ng/ml)	30–400	254	3200	446.5
Fibrinogen (mg/dl)	150 – 400	x	520	340
Lactate dehydrogenase (U/liter)	<250	x	1200	138
Interleukin-6 (pg/ml)	<6	x	71	5

x: data not available.



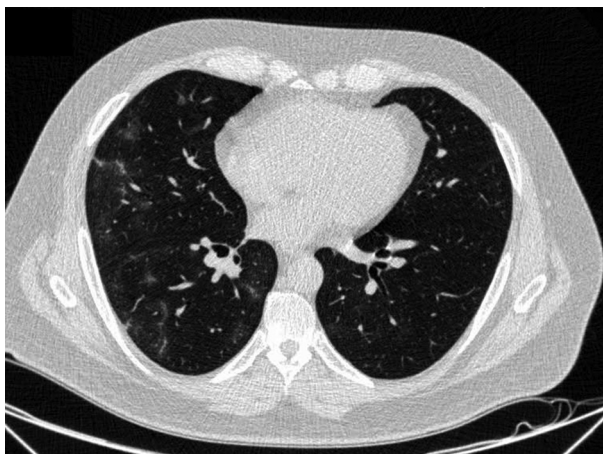
**Figure 1.** Axial CT image at presentation shows bilateral pleural-based ground glass opacities.

with a normal oxygen saturation while breathing ambient air (95%). Lung auscultation was normal. Laboratory tests showed mild acute kidney injury (Creatinine, 1.4 mg per deciliter), leukocytosis (WBC, 10,100 per cubic millimeter) with a neutrophil count of 75% and a lymphocyte count of 21%, and thrombocytosis (platelet 407,000 per cubic millimeter). Other markers of inflammation were elevated as well: CRP (75 mg per deciliter), ESR (62 mm per hour), ferritin (3200 ng per milliliter), fibrinogen (520 mg per deciliter), lactate dehydrogenase (1200, LDH) and D-dimer level (7123 ng per milliliter). IL-6 level was elevated to 71 pg per millilitre. Liver function tests showed slightly elevated liver enzymes. Uric acid was as high as 8.8 mg per deciliter (normal on routine laboratory tests performed prior to the initial presentation). Blood and urine cultures were negative. Nasopharyngeal swab was again positive for Covid-19, and a repeat chest CT showed significant improvement in alveolar infiltrates (Figure 2). A bilateral lower extremity doppler study did not show any deep vein thrombosis.

Based on clinical and laboratory findings, a diagnosis of cytokine release syndrome associated with Covid-19 infection was made. Due to the lack of respiratory symptoms, improvement in lung infiltrates on imaging, and the patient's refusal to be admitted to the hospital, he was started on oral colchicine at a dose of 1 mg twice a day with intravenous and oral hydration at home. Following 48 hours of therapy, the patient had a notable clinical improvement. He became afebrile, urine output returned to normal, regained his appetite, and had no more toe pain. The colchicine was maintained at a dose of 1 mg once a day for a total of 14 days. At the end of colchicine treatment his nasopharyngeal swab became negative at two consecutive occasions. His WBC, platelet count, LDH, ferritin, fibrinogen, D-dimer, IL-6 and uric acid levels all returned to normal range. ESR declined to 10 mm per hour and CRP was not detectable. He became symptom-free and was able to stop self-isolation.

## Discussion

We suggest this patient experienced a late onset mild CRS presenting with a monoarticular gout flare. The constellation of clinical and laboratory findings and the absence of



**Figure 2.** Axial CT image 10 days later shows improvement in previously noted lung infiltrates.

alternative etiology makes this diagnosis very likely. In this patient, respiratory symptoms preceded and improved prior to the onset of a systemic inflammatory response.

The inflammatory response secondary to mild CRS likely resulted in hyperuricemia and eventual gout flare. The clinical picture with high fevers, shaking chills, myalgia, severe weakness and acute kidney injury associated with significantly elevated inflammatory markers (such as fibrinogen, LDH, D-dimer, ferritin and IL-6) is not compatible with a simple gout flare (Cavalcanti et al. 2016). The normalisation of uric acid levels after colchicine therapy without the introduction of uric acid depleting agents also supports this notion. Although an arthrocentesis was not performed, gout flare seemed the most plausible etiology. Other less likely etiologies for an arthropathy are septic arthritis and pseudogout, both of which do not fit the clinical presentation of this patient.

Polyarticular gout has been reported in CRS following chimeric antigen receptor T cells (CAR-T) therapy, such an association has not been reported in CRS secondary to viral infections particularly with Covid-19 (Chung et al. 2019).

Whether the fatigue and myalgia were a consequence of Covid-19 or elevated IL-6 levels, both symptoms alleviated following colchicine therapy (Coaccioli et al. 2008; Vittori et al. 2020).

Tocilizumab (inhibitor of IL-6 receptor), intravenous immunoglobulin, and corticosteroids have been suggested as treatments for severe CRS. (Zhang et al. 2020) IL-6 serves as an important mediator of CRS released by the activated immune cells and its elevation is associated with Covid-19 progression. Treatment of Covid-19 patients with tocilizumab leads to suppression of IL-6 levels and its off-label use has shown a reduction in Covid-19 symptoms. (Xu et al. 2020) Tocilizumab is undergoing a phase 3 clinical trial at this point. This medication is however expensive, requires hospitalization for intravenous administration, and is associated with secondary side effects. Due to outpatient management of this stable patient, lack of access to tocilizumab, and active infection (ongoing positive nasopharyngeal swab for Covid-19) precluding the use of corticosteroids, we considered colchicine as a non-immunosuppressive therapy. Colchicine is a safe, oral anti-inflammatory drug that is widely used in systemic inflammatory diseases such as acute gout, familial Mediterranean

fever (FMF), pericarditis, prevention of recurrent cardiac events, and other auto-inflammatory disorders (El Hasbani et al. 2019; Imazio et al. 2013; Ostrov 2015; Pascart and Richette 2018; Tardif et al. 2019). In autoinflammatory diseases similar to CRS, proinflammatory cytokines mainly IL-1, IL-6 and TNF contribute to the pathogenesis. Additionally, Colchicine is a first line treatment in acute gout flare (Hausmann 2019).

Colchicine exhibits its immunomodulatory effect by inhibiting microtubule formation and interfering with the inflammasome complex in immune cells (Molad 2002).

The use of colchicine in this patient not only alleviated the gout flare but also resulted in the regression of all clinical symptoms and inflammatory markers. We indeed hit two birds with one stone.

Colchicine use in CRS, particularly Covid-19 associated CRS has not been previously described in the literature. Interestingly, recent randomized control trials are now investigating the potential beneficial effects of colchicine in covid-19 such as shortening the hospitalization rate, decreasing the risk of mechanical ventilation, and cardiac injury. In support of the potential preventive effects of colchicine, a recent case report has described a patient with FMF on colchicine who presented with Covid-19 but only exhibited mild symptoms (Kobak 2020).

Off note, the two off-labelled medications used at the presentation of the symptoms, oseltamivir and hydroxychloroquine, have both shown no additional benefits in follow up clinical trials (Boulware et al. 2020; Geleris et al. 2020; Wang et al. 2020).

This observation merits the consideration of colchicine as a safe, inexpensive and oral medication for the treatment of mild to moderate CRS in Covid-19 patients even in an outpatient setting. More importantly, in Covid-19 patients with early lung involvement colchicine may be an appropriate candidate to prevent CRS in adjunction with routine antiviral agents.

## Declaration statement

- There are no conflict of interest to enclose
- NM and DM participated in manuscript writing and patient care. MM, PT and CvG participated in patients care and manuscript editing.
- All authors have consented on publication of the journal

## Funding

No funding sources to declare

## ORCID

Nahal Mansouri  <http://orcid.org/0000-0002-8348-0737>

## References

Boulware DR, Pullen MF, Bangdiwala AS, Pastick KA, Lofgren SM, Okafor EC, Skipper CP, Nascene AA, Nicol MR, Abassi M, et al. 2020. A randomized trial of hydroxychloroquine as postexposure prophylaxis for covid-19. *N Engl J Med*. doi:10.1056/NEJMoa2016638

- Cavalcanti NG, Marques CD, Lins ELTU, Pereira MC, Rego MJ, Duarte AL, Pitta Ida R, Pitta MG. 2016. Cytokine profile in gout: inflammation driven by IL-6 and IL-18? *Immunol Invest.* 45 (5):383–95.
- Chung SH, Hughes G, Koffman B, Turtle CJ, Maloney DG, Acharya UH. 2019. Not so crystal clear: observations from a case of crystalline arthritis with cytokine release syndrome (CRS) after chimeric antigen receptor (CAR)-T cell therapy. *Bone Marrow Transplant.* 54(4):632–34.
- Coaccioli S, Varrassi G, Sabatini C, Marinangeli F, Giuliani M, Puxeddu A. 2008. Fibromyalgia: nosography and therapeutic perspectives. *Pain Pract.* 8(3):190–201.
- Colchicine Coronavirus SARS-CoV2 Trial (COLCORONA). [accessed 2020 Mar 23]. <https://ClinicalTrials.gov/show/NCT04322682>.
- Colchicine counteracting inflammation in COVID-19 pneumonia. [accessed 2020 Apr 20]. <https://ClinicalTrials.gov/show/NCT04322565>.
- Colchicine in COVID-19: a pilot study. [accessed 2020 Apr 18]. <https://ClinicalTrials.gov/show/NCT04375202>.
- Colchicine in moderate-severe hospitalized patients before ARDS to treat COVID-19. [accessed 2020 May 01]. <https://ClinicalTrials.gov/show/NCT04363437>.
- Colchicine to reduce cardiac injury in COVID-19 (COLHEART-19). [accessed 2020 May 26]. <https://ClinicalTrials.gov/show/NCT04355143>.
- Colchicine twice daily during 10 days as an option for the treatment of symptoms induced by inflammation in patients with mild and severe coronavirus disease. [accessed 2020 May 27]. <https://ClinicalTrials.gov/show/NCT04367168>.
- The effects of standard protocol with or without colchicine in Covid-19 Infection. [accessed 2020 Mar 20]. <https://ClinicalTrials.gov/show/NCT04360980>.
- El Hasbani G, Jawad A, Uthman I. 2019. Update on the management of colchicine resistant familial mediterranean fever (FMF). *Orphanet J Rare Dis.* 14(1):224.
- Geleris J, Sun Y, Platt J, Zucker J, Baldwin M, Hripcsak G, Labella A, Manson D, Kubin C, Barr RG, et al. 2020. Observational study of hydroxychloroquine in hospitalized patients with Covid-19. *N Engl J Med.* 382(25):2411–18.
- The Greek study in the effects of colchicine in Covid-19 complications prevention. [accessed 2020 Apr 03]. <https://ClinicalTrials.gov/show/NCT04326790>.
- Hausmann JS. 2019. Targeting cytokines to treat autoinflammatory diseases. *Clin Immunol.* 206:23–32.
- Imazio M, Brucato A, Cemin R, Ferrua S, Maggolini S, Beqaraj F, Demarie D, Forno D, Ferro S, Maestroni S, et al. 2013. A randomized trial of colchicine for acute pericarditis. *N Engl J Med.* 369 (16):1522–28.
- Kobak S. 2020. COVID-19 infection in a patient with FMF: does colchicine have a protective effect? *annrheumdis.* 217882. doi:10.1136/annrheumdis-2020-217882
- Molad Y. 2002. Update on colchicine and its mechanism of action. *Curr Rheumatol Rep.* 4(3):252–56.
- Moore BJB, June CH. 2020. Cytokine release syndrome in severe COVID-19. *Science.* 368 (6490):473–74.
- Ostrov BE. 2015. Immunotherapeutic biologic agents in autoimmune and autoinflammatory diseases. *Immunol Invest.* 44(8):777–802.
- Pascart T, Richette P. 2018. Colchicine in gout: an update. *Curr Pharm Des.* 24(6):684–89.
- Preemptive therapy with colchicine in patients older than 70 years with high risk of severe pneumoniae due to coronavirus. [accessed 2020 May 25]. <https://ClinicalTrials.gov/show/NCT04416334>.
- Tardif JC, Kouz S, Waters DD, Bertrand OF, Diaz R, Maggioni AP, Pinto FJ, Ibrahim R, Gamra H, Kiwan GS, et al. 2019. Efficacy and Safety of Low-Dose Colchicine after Myocardial Infarction. *N Engl J Med.* 381(26):2497–505.
- Tocilizumab in COVID-19 pneumonia (TOCIVID-19). [accessed 2020 Mar 19]. <https://ClinicalTrials.gov/show/NCT04317092>.
- Trial to study the benefit of colchicine in patients with COVID-19. [accessed 2020 Apr 30]. <https://ClinicalTrials.gov/show/NCT04350320>.
- Vittori A, Lerman J, Cascella M, Gomez-Morad AD, Marchetti G, Marinangeli F, Picardo SG. 2020. COVID-19 pandemic ARDS survivors: pain after the storm? *Anesth Analg.* 131(1):117–19.

- Wang D, Hu B, Hu C, Zhu F, Liu X, Zhang J, Wang B, Xiang H, Cheng Z, Xiong Y, et al. 2020. Clinical characteristics of 138 hospitalized patients with 2019 novel coronavirus-infected pneumonia in Wuhan, China. *JAMA*. 323(11):1061.
- Xu X, Han M, Li T, Sun W, Wang D, Fu B, Zhou Y, Zheng X, Yang Y, Li X, et al. 2020. Effective treatment of severe COVID-19 patients with tocilizumab. *Proc Natl Acad Sci U S A*. 117(20):10970–75.
- Zhang C, Wu Z, Li JW, Zhao H, Wang GQ. 2020. The cytokine release syndrome (CRS) of severe COVID-19 and Interleukin-6 receptor (IL-6R) antagonist Tocilizumab may be the key to reduce the mortality. *Int J Antimicrob Agents*. 55(5):105954.