

# The Wandering *Mirena*: Laparoscopic Retrieval

Mark Erian, FRANZCOG, FRANZCOG, DM,  
Glenda McLaren, FRANZCOG, FRANZCOG, David Baartz, FRANZCOG

## ABSTRACT

Levonorgestrel-containing intrauterine contraceptive devices, marketed as *Mirena* (Bayer HealthCare Pharmaceuticals, Inc. Australia) are widely used in contemporary gynecology, primarily as an effective method for contraception and for control of menstrual disorders like menorrhagia and dysmenorrhea. In this article, the authors report 2 cases of *Mirena* migration following intrauterine insertion by general practitioners (family physicians). In the first case, the contraceptive device had moved to the patient's right iliac fossa just anterior to the cecum and, in the second, within the peritoneal cavity close to the left leaf of the diaphragm. Both patients underwent uneventful laparoscopic retrieval of the devices.

**Key Words:** *Mirena*, Laparoscopic removal.

## SUMMARY OF CLINICAL FEATURES

### Patient One

CM is a 44-year-old multiparous lady, with children 19 and 17 years of age. She delivered both of her children by spontaneous vaginal deliveries. About 15 months ago, she was fitted with a *Mirena* for contraception. Regular vaginal examinations by her family physician confirmed that the threads of *Mirena* were coming off the uterine cervix. She was totally asymptomatic when she went for a periodic cervical smear, at which point this problem with the *Mirena* device was detected. Ultrasound scan confirmed that the device was not present within the uterine cavity. A computerized tomography scan showed that the device had attached to the posterior aspect of the patient's right rectus sheath. Laparoscopy was performed by using the "triple port" of entry, and the device was found in the patient's right iliac fossa just above her cecum and was surrounded by omental adhesions. Laparoscopic adhesiolysis was affected to free the device off the omental and cecal adhesions and that was followed by laparoscopic retrieval of the *Mirena* (**Figures 1 and 2**). The procedure was uneventful, and there was no sign of uterine perforation. The patient was discharged after the outpatient procedure.

### Patient Two

NG is a 19-year-old single lady. She underwent an unremarkable vaginal suction termination of her first pregnancy (STOP) at about 8 week's gestation and was fitted with a *Mirena*, at the same time, by the treating physician. She was admitted to the hospital 10 days after the *Mirena* insertion with a history of acute severe pelvic pain that required administration of narcotic analgesic injections. Ultrasound scanning showed that the uterus was "empty." Plain X-ray of the abdomen showed that the *Mirena* was in the peritoneal cavity close to the pouch of Douglas. Emergency laparoscopy ("triple port" of entry) was performed, and the peritoneal cavity was carefully inspected. The *Mirena* was spotted within approximately 3cm of the left leaf of the diaphragm (**Figures 3 and 4**). There was no sign of uterine perforation. Laparoscopic removal of the device was carried out smoothly, and the patient was discharged after the outpatient procedure.

High Doctorate of Medicine, University of Queensland, Royal Brisbane and Women's Hospital, Brisbane, Queensland, Australia (Dr Erian).

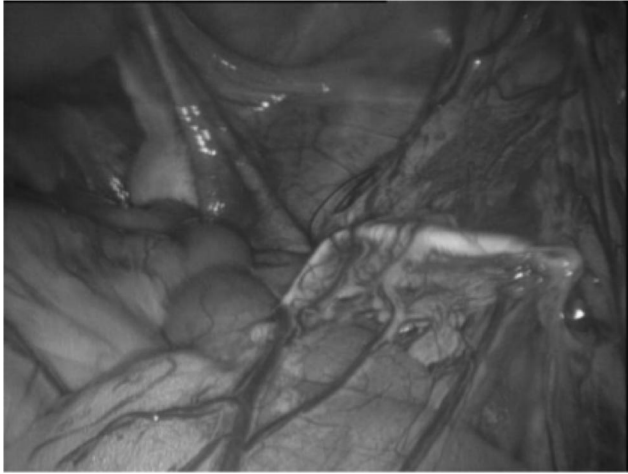
Senior Consultant Obstetrician and Gynaecologist, Mater Mother's Hospital, Brisbane, Queensland, Australia (Dr McLaren).

Senior Consultant Obstetrician and Gynaecologist, Royal Brisbane and Women's Hospital, Brisbane, Queensland, Australia (Dr Baartz).

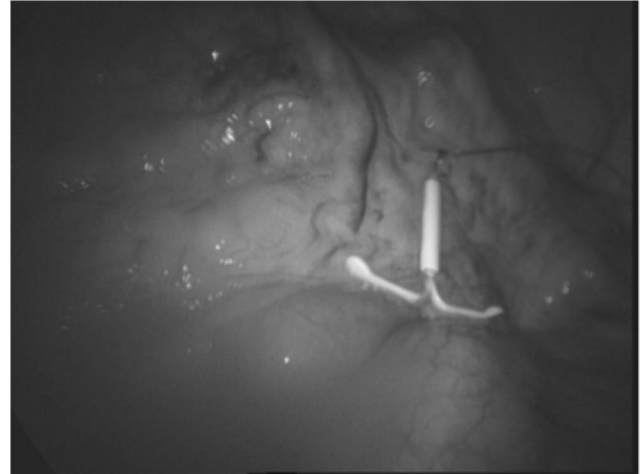
Address correspondence to: A/Professor Mark Erian, 6th Floor, Teaching and Research, Ned Hanlon Building, Royal Brisbane and Women's Hospital, Herston, Queensland 4029, Australia. Email: m.erian1@uq.edu.au

DOI: 10.4293/108680811X13022985131732

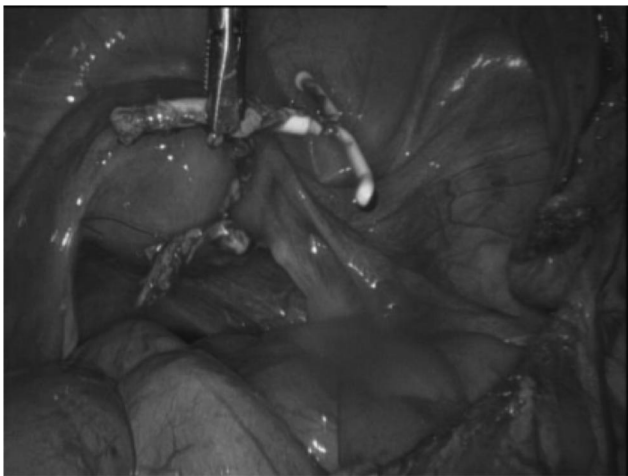
© 2011 by JSLS, *Journal of the Society of Laparoendoscopic Surgeons*. Published by the Society of Laparoendoscopic Surgeons, Inc.



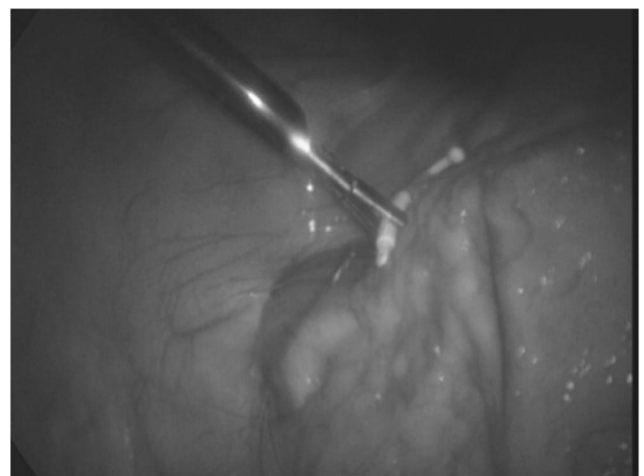
**Figure 1.** Migrated *Mirena*® lying within abdominal cavity on top of the cecum, surrounded by omental adhesions.



**Figure 3.** Migrated *Mirena*® is close to the left leaf of the patient's diaphragm.



**Figure 2.** Laparoscopic retrieval of the migrated *Mirena*® device, following an adhesiolysis procedure.



**Figure 4.** Laparoscopic retrieval of the migrated *Mirena*® device.

## DISCUSSION

The levonorgestrel-releasing intrauterine system (LNG-IUS, *Mirena*) is the most widely used contraceptive method, with prevalence rates ranging among countries from 2% to 80% of contraceptive users.<sup>1</sup> It releases 20 $\mu$ gm of levonorgestrel/day<sup>2</sup> and is used as an effective and reliable method of contraception, to manage menstrual disorders as in menorrhagia<sup>3</sup> and dysmenorrhoea,<sup>4</sup> as an endometrial protective agent in women using hormonal replacement therapy (HRT),<sup>5</sup> and in the management of select cases of endometrial carcinoma<sup>6</sup> and precancerous conditions, such as atypical endometrial hyperplasia.<sup>7</sup>

As a contraceptive, *Mirena* is probably the most effective reversible method of contraception<sup>8</sup> and without the need to take daily oral medication, as is the case with combined oral contraceptive or progesterone-only pills.<sup>9</sup> It is well tolerated, long acting, reversible, and adequately retained within the uterine cavity. Patient satisfaction is high with acceptance among parous and nulliparous women alike, as in the above 2 patients, and it also provides reassuring results for clinicians and adolescents considering use of *Mirena*.<sup>10</sup>

In addition, *Mirena* is usually recommended as a means of contraception in “high risk” patients as in those with a history of deep venous thrombosis,<sup>11</sup> type 1 diabetes mellitus,<sup>12</sup> liver disease,<sup>13</sup> epileptic seizures,<sup>14</sup> and immuno-

compromised conditions including HIV.<sup>15</sup> Nevertheless, like many therapeutics in contemporary medicine, Mirena has some side effects. Continuing pain and discomfort as well as irregular vaginal bleeding are most likely the main reasons for patients' requests to discontinue the Mirena device therapy.<sup>16</sup> Discontinuation is accompanied by return of fertility.<sup>17</sup> Contrary to old views, the device does not increase the incidence of pelvic inflammatory disease<sup>18</sup> and infertility, nor does it enhance tubal ectopic pregnancies in women with no sexually transmitted infections.<sup>19</sup> In fact, Mirena may be considered protective against infection, especially in nulliparous women.<sup>20</sup>

Uterine perforation related to the insertion of this device is one of the recognized side effects of Mirena. The incidence of such perforations varies from 0 to 2.6 per 1000 insertions and is largely related to the experience of the operating clinician.<sup>21,22</sup> Expulsion of the device, however, can happen in about 8 per 1000 insertions.<sup>23</sup> In case number 1 above, the uterine perforation was thought to have happened more than a year after insertion, because the patient had periodic speculum examinations initially every month for the first 3 months, then followed by 1 speculum exam every 3 months for the subsequent year. The "threads" of the Mirena device were clearly seen coming off the cervix. The patient remained completely asymptomatic until the device was laparoscopically removed after the threads ceased to be visualized through the cervix. Imaging, especially ultrasonography, has a crucial role in the evaluation and management of intrauterine contraceptive devices and associated complications.<sup>24</sup> Although it is difficult to be certain of the exact cause of "migration" of intrauterine contraceptive devices within the peritoneal cavity, a possible mechanism is that the peristalsis of the intestines could well assist this journey within the patient's abdomen after uterine perforation has occurred.

In case number 2, the patient experienced severe, excruciating pelvic pain, a common symptom of uterine perforation. Interestingly, there was no sign of perforation of the uterus on laparoscopic examination during the Mirena procedure. In relation to the management of this case, one may ask the question: Was it a good idea to insert the intrauterine contraceptive device immediately following STOP (Suction Termination of Pregnancy)? In fact, there is no evidence to support the idea that delayed insertion of the device carries fewer complications.<sup>25</sup> Immediate insertion after first- and second-trimester abortions has a high initial continuation and patient satisfaction rate.<sup>26</sup> Moreover, this simultaneous therapeutic approach assures the operating clinician

and the patient that an unwanted pregnancy in the future is very unlikely with the Mirena device inserted on the same occasion as the termination of pregnancy is to be carried out.<sup>27</sup>

## CONCLUSION

Because Mirena is gaining in popularity among clinicians and enjoys a wide range of candidacy among gynecological patients, it is imperative that health care providers are fully informed of the value as well as the possible side effects of the device, notably uterine perforation. An experienced gynecological endoscopist should be able to safely remove a missed Mirena out of the peritoneal cavity without any complications.

## References:

1. ESHRE Capri Workshop Group. Intrauterine devices and intrauterine systems. *Hum Reprod Update*. 2008 May-Jun;14(3):197-208.
2. Wildemeersch D, Janssens D, Andrade A. The Femilis LNG-IUS: Contraceptive performance- an interim analysis. *Eur J Contracept Reprod Health Care*. 2009 Apr;14(2):103-110.
3. Chen EC, Danis PG, Tweed E. Clinical inquiries. Menstrual disturbances in perimenopausal women: What's best? *J Fam Pract*. 2009 Jun;58(6):E3.
4. Bahamondes L, Petta CA, Fernandes A, Monteiro L. Use of Levonorgestrel-releasing intrauterine system in women with endometriosis, chronic pelvic pain and dysmenorrhea. *Contraception*. 2007 Jun;75(6 suppl):S123-S129.
5. Cameron S. Contraception and gynaecological care. *Best Pract Res Clin Obstet Gynaecol*. 2009 Apr;23(2):211-220.
6. Montz FJ, Bristow RE, Bovicelli A, Tomacruz R, Kumar RJ. Intrauterine progesterone treatment of early endometrial cancer. *Am J Obstet Gynecol*. 2002 Apr;186(4):651-657.
7. Bahamondes L, Bahamondes MV, Monteiro I. Levonorgestrel-releasing intrauterine system: uses and controversies. *Expert Rev Med Devices*. 2008 Jul;5(4):437-445.
8. Mansour D, Inki P, Gemzell-Danielsson K. Efficacy of contraceptive methods: A review of the literature. *Eur J Contracept Reprod Health Care*. 2010 Feb;15(1):4-16.
9. Kottke M, Cwiak C. Non-daily contraceptive options user benefits, potential for high continuation, and counselling issues. *Obstet Gynecol Surv*. 2008 Oct;63(10):661-668.
10. Godfrey EM, Memmel LM, Neustadt A, et al. Intrauterine contraception for adolescents aged 14-18 years: a multicenter randomised pilot study of Levonorgestrel-releasing intrauterine system compared to the Copper T 380 A. *Contraception*. 2010 Feb;81(2):123-127.

11. van Hylckama Vileg A, Helmerhorst FM, Vandenbroucke JP, Doggen CJ, Rossendaal FR. The venous thrombotic risk of oral contraceptives, effects of oestrogen dose and progestogen type: results of the MEGA case-control study. *BMJ*. 2009 Aug 13;339:b2921.
12. Rogovskaya S, Rivera R, Grimes DA, et al. Effect of a Levonorgestrel intrauterine system on women with type 1 diabetes: a randomised trial. *Obstet Gynecol*. 2005 Apr;105(4):811–815.
13. Connolly TJ, Zuckerman AL. Contraception in the patient with liver disease. *Semin Perinatol*. 1998 Apr;22(2):178–182.
14. Schwenkhausen AM, Stodieck SR. Which contraception for women with epilepsy? *Seizure*. 2008 Mar;17(2):145–150.
15. Steen R, Shapiro K. Intrauterine contraceptive devices and risk of pelvic inflammatory disease: standard of care in high STI prevalence settings. *Reprod Health Matters*. 2004 May;12(23):138–143.
16. Backman T. Benefit-risk assessment of the Levonorgestrel intrauterine system in contraception. *Drug Saf*. 2004;271(15):1185–1204.
17. Mishell Dr Jr., Sulak PJ. The IUD: dispelling the myths and assessing the potential. *Dialogues Contracept*. 1997 Spring;5(2):1–4.
18. Shimoni N. Intrauterine contraceptives: a review of uses, side effects, and candidates. *Semin Reprod Med*. 2010 Mar;28(2):118–256.
19. Gold MA, Johnson LM. Intrauterine devices and adolescents. *Curr Opin Obstet Gynecol*. 2008 Oct;20(5):464–469.
20. Prager S, Damey PD. The Levonorgestrel intrauterine system in nulliparous women. *Contraception*. 2007 Jun;75 (6 Suppl):S12–S15.
21. Pappas A, Shambhu S, Phillips K, Guthrie K. A Levonorgestrel-releasing intrauterine system embedded in the omentum in a woman with abdominal pain: a case report. *J Med Case Reports*. 2009 Nov;3:9301.
22. van Houdenhoven K, van Kaam KJ, van Grootheest AC, Salemans TH, Dunselman GA. Uterine perforation in women using a Levonorgestrel-releasing intrauterine system. *Contraception*. 2006 Mar;73(3):257–270.
23. Paterson H, Ashton J, Harrison-Woolrych M. A nationwide cohort study of the use of the Levonorgestrel intrauterine device in New Zealand adolescents. *Contraception*. 2009 Jun;79(6):433–438.
24. Peri N, Graham D, Levine D. Imaging of intrauterine contraceptive devices. *J Ultrasound Med*. 2007 Oct;26(16):1389–1401.
25. Kapp N, Curtis KM. Intrauterine device insertion during the postpartum period: a systematic review. *Contraception*. 2009 Oct;80(4):327–336.
26. Drey EA, Reeves MF, Ogawa DD, Scholoff A, Darney PD, Steinauer JE. Insertion of intrauterine contraceptives immediately following first-and second-trimester abortions. *Contraception*. 2009 May;79(5):397–402.
27. Grimes D, Sculz K, Stanwood N. Immediate postabortal insertion of intrauterine devices. *Cochrane Database Syst Rev*. 2004 Oct;18(4):CDOO1777.