

Preoperative Modeling for Mirror Hand: Simplifying a Difficult Problem Using 3-Dimensional Printing and Simulation

Dale J. Podolsky, MD, PhD*†
Gregory H. Borschel, MD*†

Summary: Mirror hand is an extremely rare congenital anomaly. We modeled and simulated the reconstruction of mirror hand in a 2-year-old boy utilizing a preoperative 3-dimensional model to aid surgical planning. A soft-tissue hand model was created using preoperative imaging, 3-dimensional printing, and silicone casting, and the model was used to perform trial surgery. Given the complexity of the deformity, the model greatly facilitated the final operative plan for reconstruction. (*Plast Reconstr Surg Glob Open* 2019;7:e1929; doi: 10.1097/GOX.0000000000001929; Published online 8 January 2019.)

INTRODUCTION

Classical congenital mirror hand, also known as ulnar dimelia,¹ consists of an absent radius, ulna duplication and polydactyly with 7–8 digits symmetric around the midline.^{2,3} It is an extremely rare deformity with only a few dozen case reports described in the worldwide literature.^{1–5} Reconstruction consists of creating unusually oriented skin flaps, osteotomies, ray transpositions, and amputations. Such procedures present the surgeon with significant challenges: the geometry of these flaps may be unfamiliar, the vascular supply may be aberrant, and the bony anatomy may be highly unusual. Preoperative imaging, planning, and simulation may avoid unnecessary complications by allowing the surgeon to define the geometry of the flaps and the vascular and bony anatomy before the patient arrives in the operating room. Three dimensional (3D) modeling can aid surgical planning for challenging procedures.⁶ We report the utilization of 3D physical modeling to aid in preoperative planning in the reconstruction of a case of mirror hand deformity in a 2-year-old boy (Fig. 1).

METHODS

A computed tomography (CT) scan of the hand and forearm (including CT angiography) was utilized to generate a 3D computer model of the left forearm and hand soft tissue using segmentation software (Mimics, Materialize, Leuven, Belgium). A negative mold of the soft tissue computer model was created using 3D modeling software (Magics, Materialize, Leuven, Belgium). The molds were then 3D printed using a fused-deposition modeling printer (Replicator 2, Makerbot Industries, N.Y.). The hand soft tissue was then casted with silicone. The material cost of making the molds was under \$30, and mold printing time was approximately 8 hours. The computer modeling to prepare the molds took approximately 1 hour.

The resulting silicone hand model was then used for preoperative marking, planning, and trial surgery. The surgeons marked planned incisions and incised the silicone hand using surgical instruments to perform trial procedures to determine the optimal surgical approach. Preoperative visualization of the nerves was not possible. The bony portion of the reconstruction was considered using the 3D computer model rendered from the preoperative CT.

Operative Procedure

Utilizing the preoperative bony and vascular imaging (Fig. 1) in conjunction with the 3D silicone model (Fig. 2), the overall reconstructive plan included remov-

From the *Division of Plastic & Reconstructive Surgery, The Hospital for Sick Children, Toronto, Ontario, Canada; and †Division of Plastic & Reconstructive Surgery, Department of Surgery, University of Toronto, Toronto, Ontario, Canada.

Received for publication June 28, 2017; accepted July 13, 2018.

Copyright © 2019 The Authors. Published by Wolters Kluwer Health, Inc. on behalf of The American Society of Plastic Surgeons. This is an open-access article distributed under the terms of the Creative Commons Attribution-Non Commercial-No Derivatives License 4.0 (CCBY-NC-ND), where it is permissible to download and share the work provided it is properly cited. The work cannot be changed in any way or used commercially without permission from the journal.

DOI: 10.1097/GOX.0000000000001929

Disclosure: Dr. Podolsky is a shareholder of Simulare Medical Corp. which produces and manufactures high-fidelity surgical simulators. The model presented in this article is not a commercial product and was not produced by Simulare Medical Corp. The charge was paid for by the authors.

Supplemental digital content is available for this article. Clickable URL citations appear in the text.

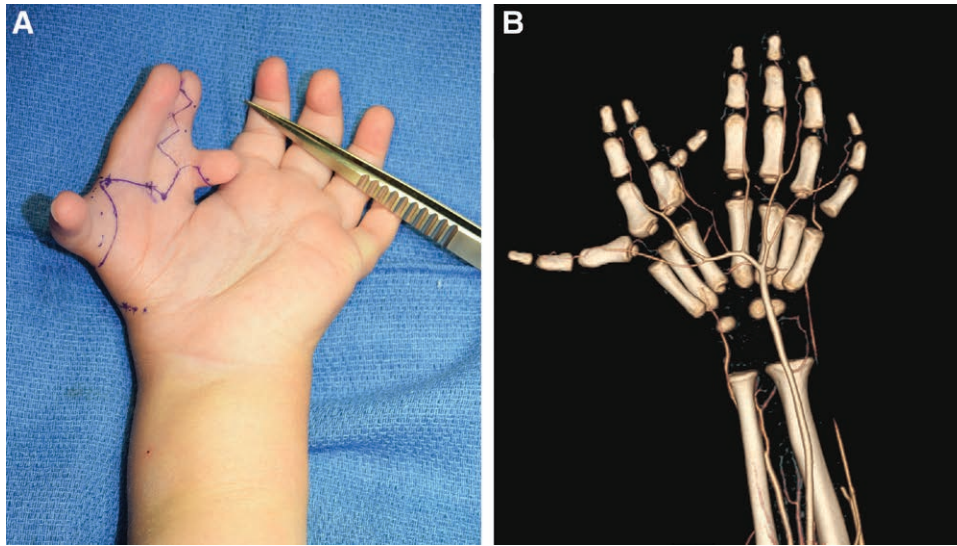


Fig. 1. Preoperative image (A) and computed tomography bony and vascular imaging of the deformity (B).

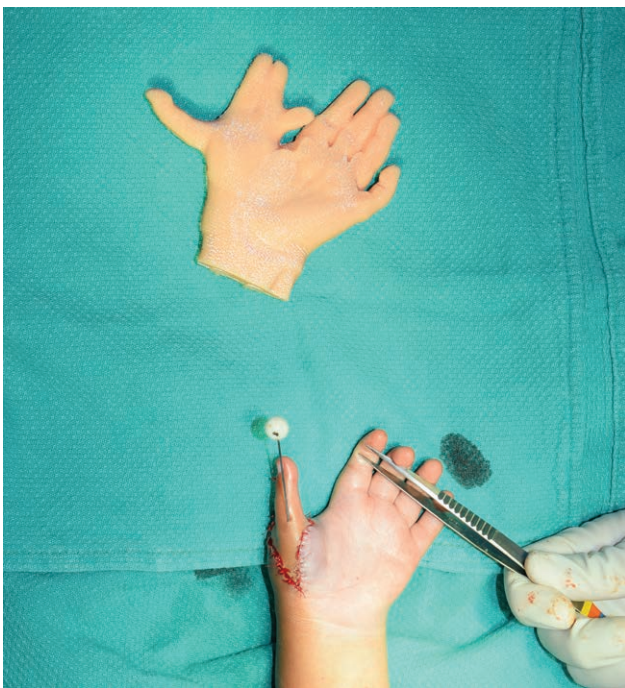

Fig. 2. Intraoperative image of the silicone soft-tissue model above with the repaired hand below.

ing the first, second, and fourth digits and retaining and pollicizing the second digit of the mirrored hand. The first, third, and fourth digits were amputated through their metacarpal bases. A mid-shaft osteotomy of the second digit metacarpal was then performed. A K-wire was then placed through the proximal phalanx through a hyperextended metacarpal head onto the proximal metacarpal stump. The abductor pollicis brevis, located during the dissection of the first digit, was transferred to the base of the proximal phalanx of the second digit. The interosseous muscles of digits 2 and 3 were combined

and transferred to the ulnar base of the proximal phalanx of the second digit to recapitulate adductor pollicis function. A web space between the new thumb and index finger was developed from a dorsal triangular flap at the base of the second digit. Release of the simple syndactyly of the second and third digits was done using a zigzag incision. Finally, the web space skin between the third and fourth digit were preserved.

RESULTS

The silicone hand provided excellent real time, 3-dimensional preoperative visualization of the deformity. The model allowed for preoperative trial markings and the ability to practice the procedure using surgical instruments. By incising and manipulating the silicone, the surgical team was better able to visualize the deformity to determine the most optimal surgical plan, resulting in a functional hand (Fig. 3) (see Video 1, Supplemental Digital Content 1, which demonstrates the function of the reconstructed left mirror hand immediately postoperative, <http://links.lww.com/PRSGO/A898>).

DISCUSSION

The use of 3D physical modeling for preoperative planning has increased in large part due to the rapid prototyping capability of 3D printers. The vast majority of physical preoperative reconstructions model bone or implants.⁷ As a result, the technology is widely used in craniomaxillofacial^{8,9} and orthopedic surgery.¹⁰

The ability to model soft tissue would provide increased capability to plan procedures that involve extensive soft-tissue reconstruction. However, 3D printers are unable to prototype with realistic soft-tissue material. To successfully model soft tissue, secondary techniques, such as casting are required. This process can be more labor intensive, requiring the development and 3D printing of molds and manually pouring polymer that takes time to cure. How-



Fig. 3. Postoperative image of the patient gripping an object using pollicized thumb.



Video Graphic 1. See video, Supplemental Digital Content 1, which demonstrates the function of the reconstructed left mirror hand immediately postoperative, <http://links.lww.com/PRSGO/A898>.

ever, our experience is that the process is only marginally more labor and time intensive than 3D printing alone.

As a result of this perceived barrier, the utilization of 3D modeling in hand surgery is scarce. The case presented demonstrates the novel use of a physical soft-tissue model for preoperative planning. The advantage of a soft-tissue model is the ability to practice surgical steps such as incising and mobilizing simulated tissue. This allows

for superior visualization of the deformity, implementing options for reconstruction and practicing procedures to determine the optimal plan. This was particularly helpful for planning the skin reconstruction, which included flaps with complex geometric arrangements.

A limitation of the model was the inability to appreciate the dynamic nature of the deformity. Observing the motion of the hand informed the team which digit was more robust and more likely to provide the most suitable pollicization. The development of a dynamic model would require a composite bone and soft-tissue model that simulates joint motion, and this may be possible in the future.

In conclusion, we developed a soft-tissue 3D physical model of a complex hand deformity that facilitated preoperative planning. The use of similar techniques would increase the application of preoperative 3D modeling in hand surgery and other procedures that require extensive soft-tissue reconstructions.

Dale J. Podolsky, MD, PhD

The Hospital for Sick Children

555 University Avenue

Room 5420, M5G 1X8

Toronto, Ontario, Canada

E-mail: dale.podolsky@mail.utoronto.ca

REFERENCES

1. Al-Qattan MM, Al-Kahtani AR, Al-Sharif EM, et al. Thumb reconstruction without formal pollicization in mirror hand deformity: a series of four cases. *J Hand Surg Eur Vol.* 2013;38:940–947.
2. Arayici S, Simsek GK, Oncel MY, et al. Congenital mirror hand deformity. *Genet Couns.* 2012;23:393–396.
3. Yang SS, Jackson L, Green DW, et al. A rare variant of mirror hand: a case report. *J Hand Surg Am.* 1996;21:1048–1051.
4. Al-Qattan MM, Al-Thunayan A, De Cordier M, et al. Classification of the mirror hand-multiple hand spectrum. *J Hand Surg Br.* 1998;23:534–536.
5. Barton NJ, Buck-Gramcko D, Evans DM, et al. Mirror hand treated by true pollicization. *J Hand Surg Br.* 1986;11:320–336.
6. Engel M, Hoffmann J, Castrillon-Oberndorfer G, et al. The value of three-dimensional printing modelling for surgical correction of orbital hypertelorism. *Oral Maxillofac Surg.* 2015;19:91–95.
7. Singare S, Lian Q, Wang WP, et al. Rapid prototyping assisted surgery planning and custom implant design. *Rapid Prototyping J.* 2009;15:19–23.
8. Peng Q, Tang Z, Liu O, et al. Rapid prototyping-assisted maxillofacial reconstruction. *Ann Med.* 2015;47:186–208.
9. Li WZ, Zhang MC, Li SP, et al. Application of computer-aided three-dimensional skull model with rapid prototyping technique in repair of zygomatico-orbito-maxillary complex fracture. *Int J Med Robot.* 2009;5:158–163.
10. Frame M, Huntley JS. Rapid prototyping in orthopaedic surgery: a user's guide. *Scientific World J.* 2012;2012:838575.