

# Isolated Cryptococcal Infection of the Thoracic Spine in an Immunocompetent Patient

Wensen Pi, Yang Liu, Haidan Chen, Hongwei Zhao

Department of Spine Surgery of Yichang Central People's Hospital, First Clinical Medical College of China Three Gorges University, Yichang, Hubei, 443000, People's Republic of China

Correspondence: Hongwei Zhao; Haidan Chen, Department of Spine Surgery of Yichang Central People's Hospital, First Clinical Medical College of China Three Gorges University, Yichang, Hubei, 443000, People's Republic of China, Email [ycguke@sina.com](mailto:ycguke@sina.com); [147811399@qq.com](mailto:147811399@qq.com)

**Abstract:** *Cryptococcus neoformans* is a type of fungal infection, which primarily affects the central nervous system and lungs of immunocompromised individuals. Spinal infections are known to be a rare manifestation of cryptococcosis. Herein, we report a case of a patient with isolated nonspecific spinal lesions at the T10 vertebra. The patient received non-surgical treatment with antifungal drugs, resulting in satisfactory clinical outcomes.

**Keywords:** cryptococcal, thoracic spine

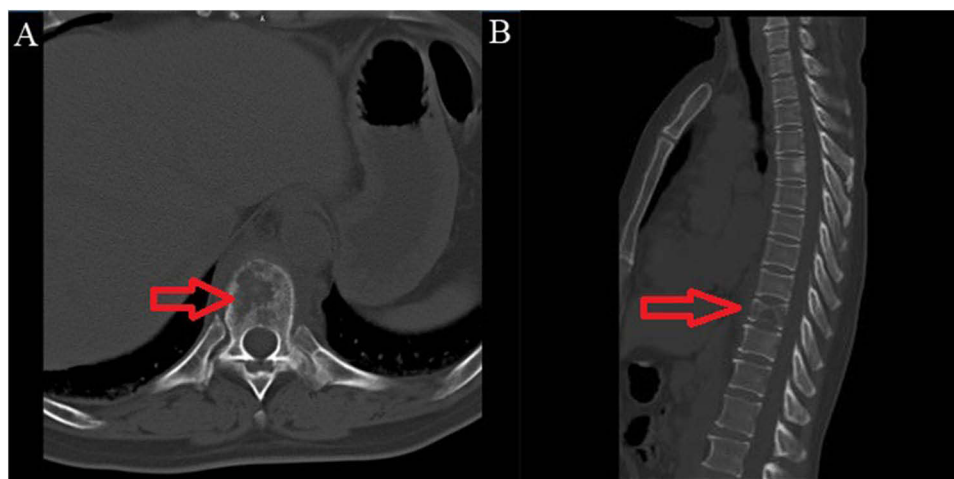
## Introduction

Cryptococcosis is a major globally transmitted invasive fungal infection that primarily occurs in patients with immune insufficiency.<sup>1</sup> Therefore, for patients with normal immune function, it is easy to overlook the issue of cryptococcal infection. In this report, we present a case of a 55-year-old female patient, who was not immunocompromised and did not have any other risk factors, with isolated thoracic vertebral cryptococcosis proven by biopsy. Based on imaging studies, the presumptive diagnosis at a local hospital was metastatic spinal cancer. However, cryptococcal osteomyelitis was diagnosed based on pathological examination. This case report emphasizes that we should be aware that thoracic cryptococcosis can be a rare cause of mimicking lesions with metastatic cancer and our report may help other clinicians manage similar cases of cryptococcal infections of spine.

## Case Presentation

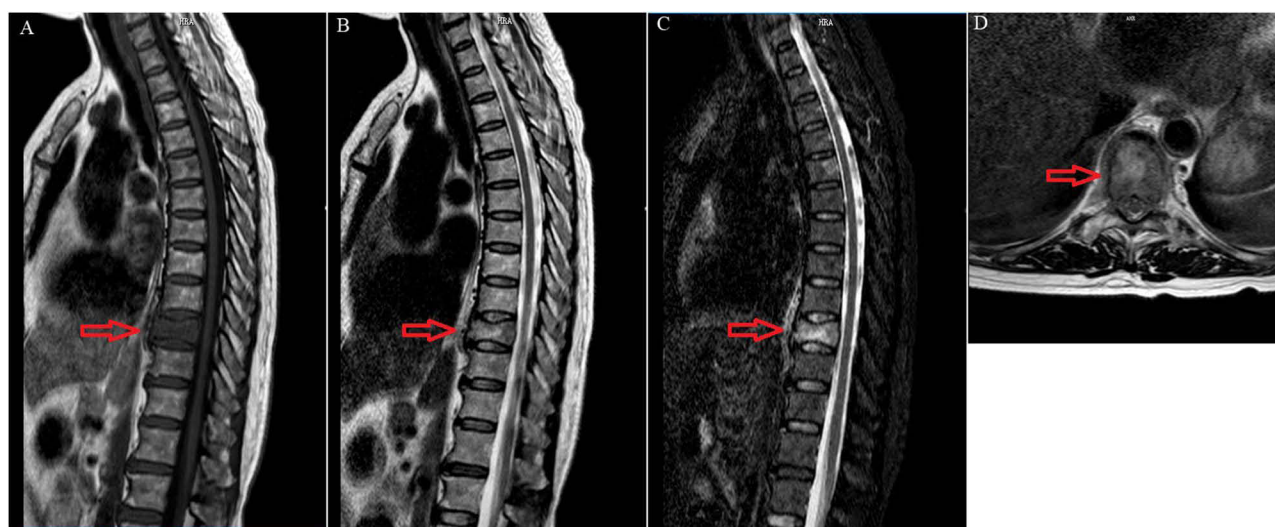
A 55-year-old woman presented to the outpatient department of spine in our hospital with a 3-month history of progressive sore back. She did not have nausea, fever, headaches, cough, vomiting, or night sweats. Moreover, she had no history of acquired immune deficiency syndrome (AIDS), diabetes, tuberculosis, leukaemia, lymphoma, tumor and immunosuppressive therapy. Initially, she visited a local county hospital, where a lumbar vertebra computed tomography (CT) was performed. Findings showed osteolytic lesions of the T10 vertebral body accompanied by paravertebral soft tissue masses. Her preliminary diagnosis was a thoracic vertebral tumor and was referred to our hospital for further treatment.

Clinical examination on admission revealed local tenderness and percussion pain in the back. The patient exhibited no abnormalities in strength or sensation in either lower extremity. The spinal movements were normal. Routine blood tests revealed a white blood cell count of  $4.5 \times 10^9/L$  (normal  $3.5 - 9.5 \times 10^9/L$ ), with 85.8% neutrophils (normal 40–75%), 5.8% lymphocytes (normal 20–50%), and 0.4% eosinophils (normal: 0.4–8%). The erythrocyte sedimentation rate (ESR) was 72 mm/h (normal 0–20 mm/h) and C-reactive protein (CRP) level was 85.71 mg/L (normal 0–10.0 mg/l). All other test results were normal, including those for tumor markers. Computed tomography (CT) of the thoracic vertebra showed some irregular osteolytic lesions in the thoracic vertebra of T10, which were surrounded by cystic low-density soft tissue masses of unequal size (Figure 1). Magnetic resonance imaging (MRI) revealed abnormal patchy signals in the thoracic

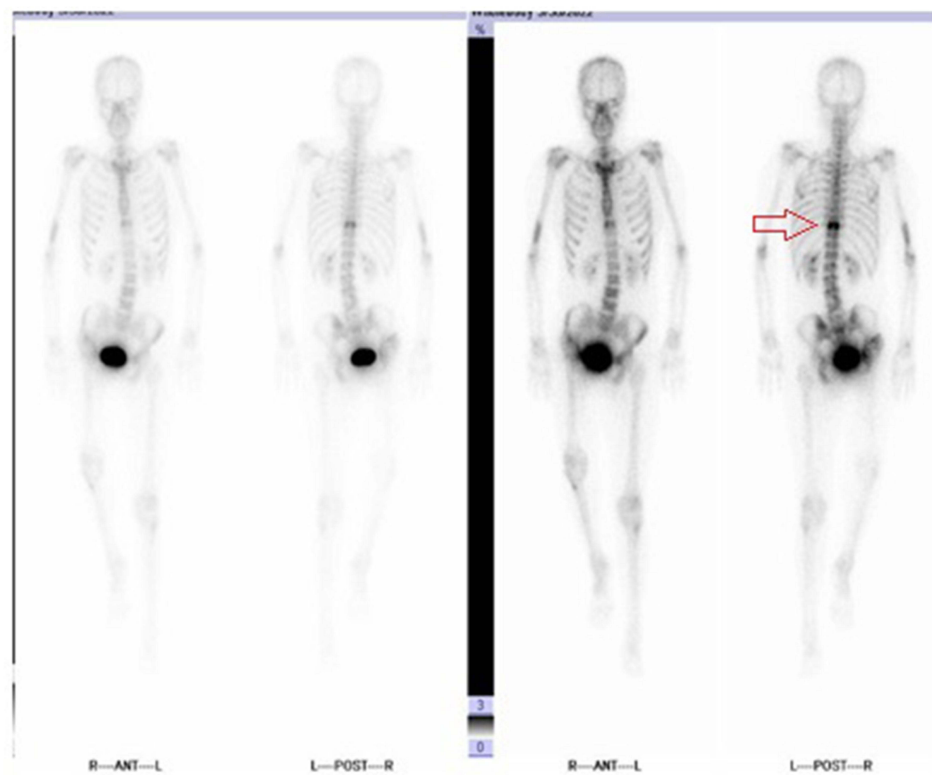


**Figure 1** Computed tomography (CT) (thoracic vertebra). T10 Vertebral lesions and vertebral invasion. A. transversal; B sagittal. Red arrows indicate location and extent of the lesions.

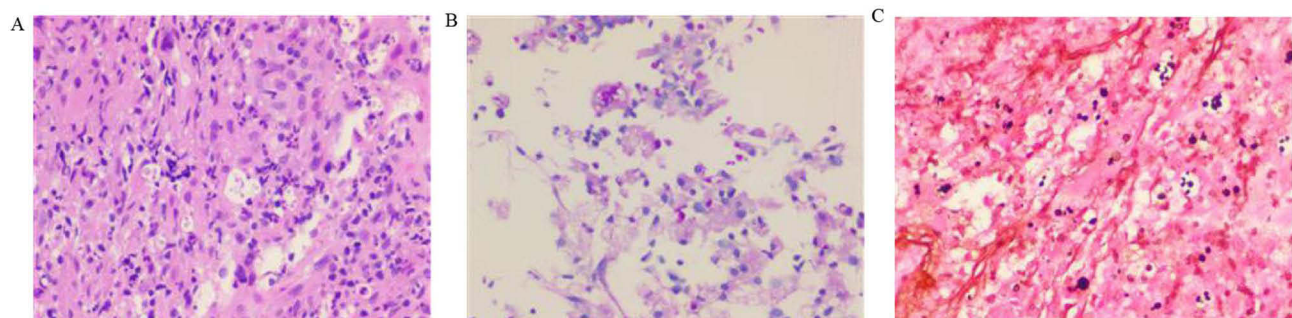
vertebra at T10, hyperintense signals on T2WI, and low signal intensity on T1WI (Figure 2). No other abnormalities were found on contrast-enhanced CT of the chest or whole abdomen. Radioisotope bone scans showed increased tracer uptake in the thoracic vertebra of T10, indicating a high possibility of considering tumor-related lesions (lymphoma?) (Figure 3). For further diagnosis, we performed a CT-guided puncture biopsy of the thoracic vertebral lesion. Biopsy results revealed an infected lesion with granulomatous inflammation and numerous round cocci under the microscope, with no obvious caseous necrosis. Special staining results: acid-fast staining (–), PAS staining (+), and silver staining (+) (Figure 4). Combined with the special staining results, it was considered a cryptococcal infection. We further conducted blood culture, cerebrospinal fluid (CSF) study, chest CT, and brain MRI. The results of these experiments were negative. There was no evidence of lung or brain involvement. These results indicated that the patient was diagnosed with isolated vertebral cryptococcosis rather than disseminated cryptococcosis. After consultation with the infectious disease doctors, amphotericin B (50 mg/day) and fluconazole (800 mg/day) were administered intravenously for approximately 1 week until disseminated cryptococcosis was ruled out. During the time of treatment, the patient was required to take an absolute bed rest for 1 month. After 2 months of treatment, follow-up examination showed that bone destruction and vertebral abnormalities of T10 have formed bone regeneration. (Figure 5). At this point, patients were allowed to exercise



**Figure 2** Magnetic resonance imaging (MRI) (thoracic vertebra). bone destruction and vertebral abnormalities of T10. (A) sagittal T1-weighted; (B) sagittal T2-weighted; (C) sagittal fat-suppressed T2-weighted; (D) transversal fat-suppressed T2-weighted). Red arrows indicate location and extent of the lesions.



**Figure 3** Systemic radionuclide bone-scanning shows active metabolism of T10 Vertebral (red arrows), which indicated metastatic tumors (lymphoma?).

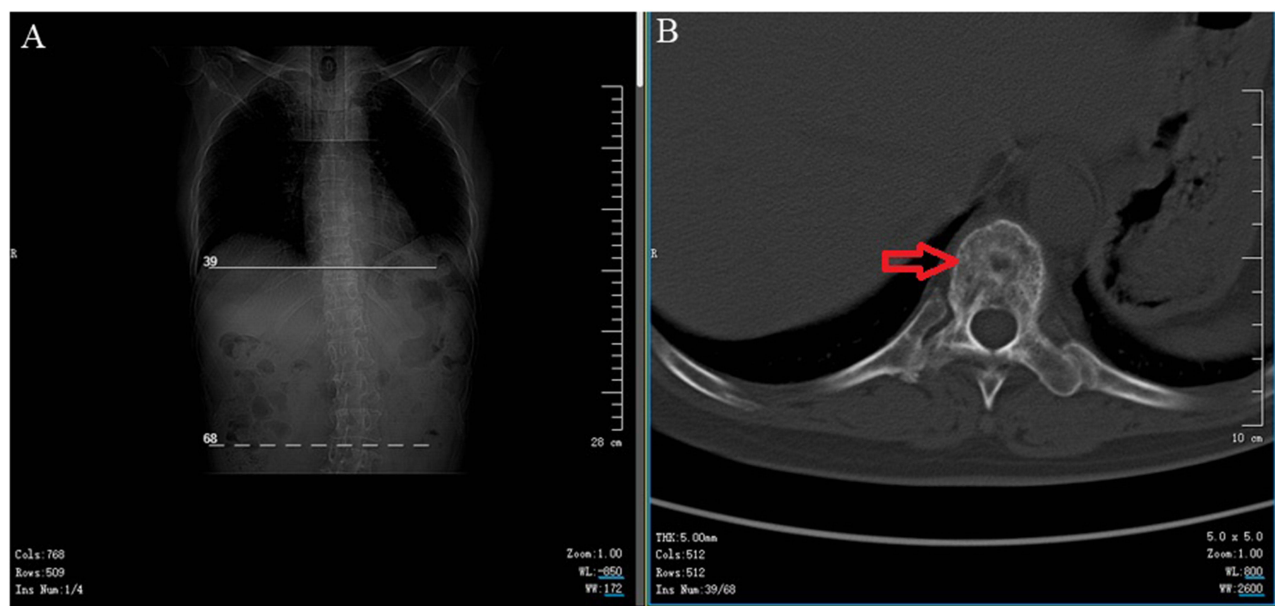


**Figure 4** The result of pathology of puncture biopsy-sample. Granulomatous inflammation and a large amount of round cocci under the microscope, with no obvious caseous necrosis observed. (A) Hematoxylin-eosin staining; (B) PAS staining (+); (C). hexamine silver staining (+).

with the assistance of protective gear for thoracic vertebrae. Fluconazole (450 mg/day) was administered orally for approximately 1 year. The patient's focal lesion was reduced, and the clinical symptoms disappeared during the 12-month follow-up.

## Discussion

Studies have shown that cryptococcal infection of the bone is more common in patients with immune insufficiency,<sup>2,3</sup> including HIV infection<sup>4</sup> or serious immunodeficiency with long-term use of immunosuppressants, as well as diabetes,<sup>5</sup> sarcoidosis,<sup>6</sup> tuberculosis,<sup>7</sup> lymphopenia,<sup>8</sup> rheumatoid arthritis<sup>9</sup> and other related immunodeficiencies. In 1955, Eisen et al<sup>10</sup> reported a case of cryptococcosis with lung and spinal involvement. *Aspergillus* and *Candida* spp. are the most common fungal infections of the spine. Cryptococcal infections are extremely rare and account for only 6.4%.<sup>11</sup> A literature review in 2023 reported all English language reports of cryptococcal osteomyelitis involving the spine



**Figure 5** Computed tomography (CT) (thoracic vertebra). bone destruction and vertebral abnormalities of T10 have formed bone regeneration. Red arrows indicate location and extent of the lesions. **(A)** Positioning piece; **(B)** transversal of T10.

since 1992 and identified 18 related cases. Among them, 10 (55.6%) cases involved the lumbar vertebrae, seven (38.9%) involved the thoracic vertebrae, and three (15.8%) involved the sacral vertebrae.<sup>12</sup> This finding suggests that fungal osteomyelitis is a rare type of vertebral infection.

The clinical manifestations of spinal cryptococcal osteomyelitis are atypical, usually including local pain, edema, limited mobility, etc.<sup>13</sup> When the spinal cord is compressed, neurological symptoms may occur. Imaging findings typically include irregular osteolytic destruction, vertebral bodies with or without paravertebral abscess. It is difficult to distinguish this fungal infection from spinal tumors, tuberculosis solely based on clinical symptoms and imaging findings.<sup>14,15</sup>

In our case, we encountered a 55-year-old, generally healthy woman with back pain, no underlying diseases, and no history of abnormal immune function. Her main symptoms included back pain with local tenderness and percussive pain. Her blood test results were nonspecific and revealed elevated levels of inflammatory markers. In addition to bone destruction on CT, a radioisotope bone scan showed increased tracer uptake in the thoracic vertebra of T10, indicating a high possibility of considering tumor-related lesions (lymphoma?). Therefore, the patient was initially misdiagnosed with a bone tumor. An accurate diagnosis was eventually made through a timely puncture biopsy, which revealed a cryptococcal infection. After non-surgical treatment, the patient's irregular osteolytic lesions reduced, and the clinical symptoms disappeared.

Some studies have found that surgical debridement combined with antifungal treatment can achieve a prominent therapeutic effect, and delayed surgery may result in poor prognosis of nerve function.<sup>16,17</sup> However, for immunocompromised patients, literature of reports suggested that surgery may increase the risk of infection dissemination.<sup>18</sup> David B Villafuerte et al<sup>19</sup> reported a 44-year-old Hispanic male with an immunocompetent function who developed transverse myelitis associated with *Cryptococcus neoformans*. The patient underwent non-surgical treatment and muscle strength improvement. However, patients continued to experience fecal and urinary incontinence. Wang et al<sup>17</sup> reported disseminating a cryptococcal infection of the lumbar spine in an immunocompetent man who underwent surgical debridement combined with antifungal treatment. He et al<sup>20</sup> reported a case of pubis cryptococcal osteomyelitis in a 45-year-old female who drained pus by aspiration and oral fluconazole (400 mg/day) treatment. Our patient had no neurological impairments. Simultaneously, considering the medical expenses and appropriate communication with the patient, we



decided to temporarily proceed with conservative treatment and adopt surgical treatment when neurological damage occurs.

## Conclusion

In summary, we encountered a rare case of isolated thoracic cryptococcal osteomyelitis in an immunocompetent patient. Thoracic cryptococcal osteomyelitis is a rare disease with atypical clinical symptoms and imaging findings, behaving similarly to spinal tuberculosis and metastatic bone tumors. Hence, invasive examinations such as puncture biopsies are needed. Nonsurgical therapy may be satisfactory for the treatment of spinal cryptococcal osteomyelitis when it does not compress the spinal cord or nerves. We need to dynamically observe the treatment effect. If the condition worsens, a combination of aggressive surgery and antifungal therapy is essential.

## Abbreviations

MRI, magnetic resonance imaging; CT, computed tomography; H&E, hematoxylin–eosin staining.

## Data Sharing Statement

The data used and analyzed during the current study are available from the corresponding author on reasonable request. All data files mentioned in this manuscript are available.

## Ethics Approval

Ethical approval was obtained from the Medical Ethics Committee of Yichang Central People's Hospital. The Medical Department of Yichang Central People's Hospital has approved the publication of case details.

## Informed Consent Statement

All published medical histories and photographs have been signed with informed consent from patients.

## Author Contributions

All authors made a significant contribution to the work reported, whether that is in the conception, study design, execution, acquisition of data, analysis and interpretation, or in all these areas; took part in drafting, revising or critically reviewing the article; gave final approval of the version to be published; have agreed on the journal to which the article has been submitted; and agree to be accountable for all aspects of the work.

## Disclosure

The authors declare that they have no competing interests in this work.

---

## References

1. Chang CC, Harrison TS, Bicanic TA, et al. Global guideline for the diagnosis and management of cryptococcosis: an initiative of the ECMM and ISHAM in cooperation with the ASM. *Lancet Infect Dis*. 2024. doi:10.1016/S1473-3099(23)00731-4
2. Onyishi CU, May RC. Human immune polymorphisms associated with the risk of cryptococcal disease. *Immunology*. 2022;165(2):143–157. doi:10.1111/imm.13425
3. Rathore SS, Sathiyamoorthy J, Lalitha C, et al. A holistic review on *Cryptococcus neoformans*. *Microb Pathog*. 2022;166:105521. doi:10.1016/j.micpath.2022.105521
4. Limper AH, Adenis A, Le T, et al. Fungal infections in HIV/AIDS. *Lancet Infect Dis*. 2017;17(11):e334–e343. doi:10.1016/S1473-3099(17)30303-1
5. Nsenga L, Kajjimu J, Olum R, et al. Cryptococcosis complicating diabetes mellitus: a scoping review. *Ther Adv Infect Dis*. 2021;8:20499361211014769. doi:10.1177/20499361211014769
6. Zhou B, She J, Yang L, et al. Coexistent pulmonary cryptococcal infection and pulmonary sarcoidosis: a case report and literature review. *J Int Med Res*. 2020;48(2):300060520903870. doi:10.1177/0300060520903870
7. Fang W, Zhang L, Liu J, et al. Tuberculosis/cryptococcosis co-infection in China between 1965 and 2016. *Emerg Microbes Infect*. 2017;6(8):e73. doi:10.1038/emi.2017.61
8. Amit A, Sudish K, Pople IK. Primary calvarial cryptococcal osteomyelitis in a patient with idiopathic lymphopenia. *Acta Neurochir*. 2008;150(7):713–714. doi:10.1007/s00701-008-1608-8
9. Yang G, Chen J, Ye J, et al. Possible environmental exposure-associated pulmonary cryptococcosis in a patient with rheumatoid arthritis: a case report and literature review. *J Int Med Res*. 2020;48(10):300060520962302. doi:10.1177/0300060520962302

10. Eisen D, Shapiro I, Fischer JB. A case of cryptococcosis with involvement of lungs and spine. *Can Med Assoc J.* 1955;72(1):33–35.
11. Ganesh D, Gottlieb J, Chan S, et al. Fungal Infections of the Spine. *Spine.* 2015;40(12):E719–28. doi:10.1097/BRS.0000000000000903
12. Zhong Y, Huang Y, Zhang D, et al. Isolated cryptococcal osteomyelitis of the sacrum in an immunocompetent patient: a case report and literature review. *BMC Infect Dis.* 2023;23(1):116. doi:10.1186/s12879-023-08066-6
13. Govender S, Mutasa E, Parbhoo AH. Cryptococcal osteomyelitis of the spine. *J Bone Joint Surg Br.* 1999;81(3):459–461. doi:10.1302/0301-620X.81B3.0810459
14. Joo HS, Ha J-K, Hwang CJ, et al. Lumbar cryptococcal osteomyelitis mimicking metastatic tumor. *Asian Spine J.* 2015;9(5):798–802. doi:10.4184/asj.2015.9.5.798
15. Matsuki T, Miyamoto S, Yamashita T. Cryptococcal osteomyelitis of the Zygomatic bone: a case report. *BMC Infect Dis.* 2020;20(1):399. doi:10.1186/s12879-020-05123-2
16. Lai Q, Liu Y, Yu X, et al. Diagnosis and treatment of nonadjacent cryptococcal infections at the L1 and S1 vertebrae. *Orthopade.* 2017;46(1):85–89. doi:10.1007/s00132-016-3349-3
17. Wang R, Luo H, Xin X, et al. Disseminated cryptococcal infection of the lumbar spine in an immunocompetent man. *Infect Drug Resist.* 2022;15:4229–4234. doi:10.2147/IDR.S359612
18. Zhou HX, Ning G-Z, Feng S-Q, et al. Cryptococcosis of lumbar vertebra in a patient with rheumatoid arthritis and scleroderma: case report and literature review. *BMC Infect Dis.* 2013;13:128. doi:10.1186/1471-2334-13-128
19. Villafuerte DB, Passeri MF, Qazi R, et al. Transverse myelitis associated with *Cryptococcus neoformans* in an immunocompetent patient. *Case Rep Infect Dis.* 2022;2022:2000246. doi:10.1155/2022/2000246
20. He S, Luo T, Xie Y, et al. Pubis cryptococcal osteomyelitis in an immunocompetent patient: a case report and recent literature review. *Infect Drug Resist.* 2022;15:7369–7375. doi:10.2147/IDR.S390881

## Infection and Drug Resistance

Dovepress

### Publish your work in this journal

Infection and Drug Resistance is an international, peer-reviewed open-access journal that focuses on the optimal treatment of infection (bacterial, fungal and viral) and the development and institution of preventive strategies to minimize the development and spread of resistance. The journal is specifically concerned with the epidemiology of antibiotic resistance and the mechanisms of resistance development and diffusion in both hospitals and the community. The manuscript management system is completely online and includes a very quick and fair peer-review system, which is all easy to use. Visit <http://www.dovepress.com/testimonials.php> to read real quotes from published authors.

Submit your manuscript here: <https://www.dovepress.com/infection-and-drug-resistance-journal>