

## General Urology

# “My bladder is hanging out of my anus”: Successful Management of First Reported Case of Male Transanal Bladder Prolapse



Samer W. Kirmiz<sup>a,b</sup>, Andrew J. Livingston<sup>c</sup>, Martin A. Luchtefeld<sup>d</sup>, Christopher M. Brede<sup>a</sup>, Sabrina L. Noyes<sup>a</sup>, Brian R. Lane<sup>a,b,\*</sup>

<sup>a</sup> Spectrum Health Hospital System, Division of Urology, 4069 Lake Drive SE, Ste 313, Grand Rapids, MI 49546, USA

<sup>b</sup> Michigan State University College of Human Medicine, 25 Michigan Street, Grand Rapids, MI 49503, USA

<sup>c</sup> Grand Health Partners, Division of Plastic Surgery, 2060 E Paris Ave SE # 100, Grand Rapids, MI 49546, USA

<sup>d</sup> Spectrum Health Hospital System, Division of Colorectal Surgery, 4100 Lake Dr SE #205, Grand Rapids, MI 49546, USA

## ARTICLE INFO

## Article history:

Received 7 October 2015

Accepted 14 October 2015

## Keywords:

Recto-urethral fistula

Transanal bladder prolapse

## ABSTRACT

We present a case of an 81-year-old man who presented with a large recto-urethral fistula resulting in prolapsing bladder through the anus. A multi-disciplinary approach with urology, colorectal surgery and plastic surgery was utilized for management of the prolapse with excellent postoperative result. This unique scenario enabled a transanal cystoprostatectomy; the procedure was completed using a natural orifice without transabdominal surgery.

© 2016 The Authors. Published by Elsevier Inc. This is an open access article under the CC BY-NC-ND license (<http://creativecommons.org/licenses/by-nc-nd/4.0/>).

## Introduction

Transanal prolapse of the bladder is an exceedingly rare and extreme complication—no cases have been reported in humans. Recto-urethral fistulae are uncommon in their own right, often contributing to poor quality of life and necessitating repair that can lead to other complications.<sup>1,2</sup> The root causes of fistulae include: congenital maladies, trauma, neoplastic processes, infection, inflammation, and iatrogenic causes such as prior surgery and/or radiation. Repair of fistulae can be challenging because of the difficulty in accessing the pelvic anatomy, resulting in a high failure rate.<sup>1,2</sup> There are numerous reported approaches to repair, varying from challenging transanal repairs to extremely complex approaches requiring a combination of abdominal and perineal techniques.<sup>1,2</sup> We report a case of a large recto-urethral fistula that eventually developed into complete prolapse of the bladder through rectum and anus.

## Case presentation

An 81-year old presented to our clinic with a chief complaint of “my bladder is hanging out of my anus.” His pertinent past medical

*Abbreviations:* BPH, Benign prostatic hypertrophy; TURP, Transurethral resection of the prostate.

\* Corresponding author. Urology, Spectrum Health Medical Group, 4069 Lake Drive, Suite 313, MC 9016, Grand Rapids, MI 49546, USA. Tel.: +1 616 267 7333; fax: +1 616 267 8040.

E-mail address: [brian.lane@spectrumhealth.org](mailto:brian.lane@spectrumhealth.org) (B.R. Lane).

history began with urinary retention leading to a transurethral resection of prostate for benign prostatic hypertrophy. He subsequently developed anterior urethral stricture disease which required multiple endoscopic procedures, including urethral dilations, direct visualization internal urethrotomy, and transurethral resection of urethral stricture and bladder neck contracture. Eventually, he began to void per rectum and was diagnosed with a large recto-urethral fistula. He was referred to a tertiary center and underwent diverting colostomy and ileal conduit. At the time of diversion, the bladder and rectum were left *in situ* due to a ‘hostile pelvis.’ After surgery, he developed rectal prolapse and underwent a Thiersch procedure. Unfortunately, the pelvic organ prolapse worsened and he was advised that no further operative options were available. He and his wife began to manage the prolapse of his bladder and rectum by manual reduction, packing the rectum with Kerlix gauze, and applying dressings and tape to his buttock. He sought out further surgical opinions and presented to our center for management of this extremely complex and rare scenario. After meeting with a team of urologic, plastic, and colorectal surgeons, he elected for repair.

Using a transanal approach, the posterior bladder wall was seen adjoined to the anterior rectal wall, consistent with a recto-urethral fistula. The anterior rectal wall was dissected from the posterior bladder wall, preserving all rectal tissue. The posterior bladder was then dissected laterally into the perivesical space. Bladder was mobilized off the peritoneal lining and the posterolateral pedicles were controlled with the LigaSure device. The anterior bladder was

then dissected off the pubic symphysis using the transanal approach with slight vertical extension to gain access and exposure of urethra and Foley. Resection of residual prostate with closure of the urethra was performed.

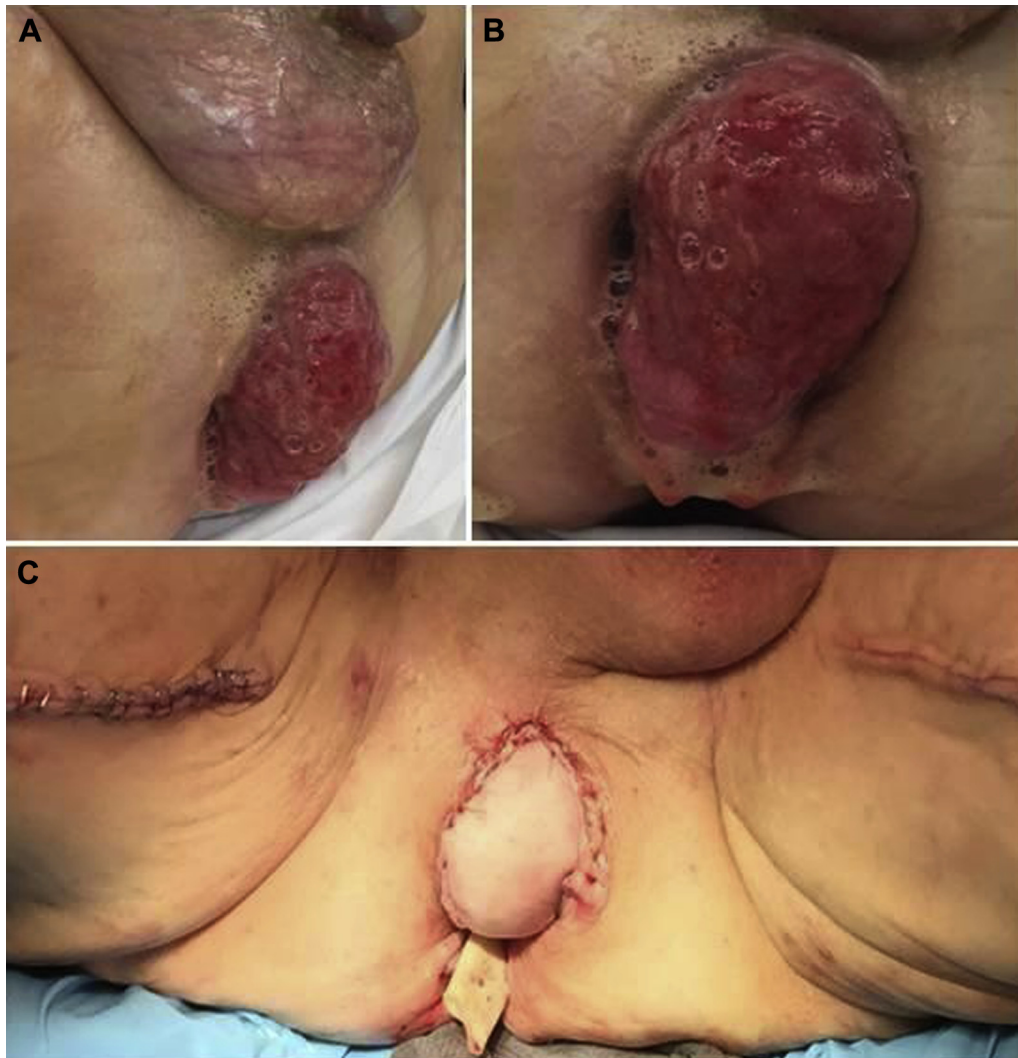
After cystoprostatectomy, completion proctectomy was judged to be impractical due to the presence of parastomal hernias of the anterior abdominal wall. Bilateral gracilis muscle flaps were harvested from medial thighs and transposed into the pelvic defect. Left gracilis muscle was wrapped around the rectum and sutured to ischium in order to restore some muscular support to the sphincter. The right gracilis myocutaneous flap was used to fill dead space within the pelvis, bridging the gap between the anterior rectal margin and anal verge. Postoperatively, he developed venous congestion of the myocutaneous flap which was treated with medical leaches and eventually necessitated a return to the operating room 7 days post-op. After debridement of skin and subcutaneous tissue, the anterior margin of rectum was inset to muscle and anal verge in place of the skin paddle. By 4 weeks after surgery, thigh donor sites healed well and anterior rectum and anal verge were re-epithelialized. No evident prolapse of viscera was seen or palpated with digital rectal exam. Patient (and

spouse) quality-of-life are now much improved, more than 6 months after surgery (Fig. 1).

## Discussion

Benign prostatic hypertrophy (BPH) is very common, and surgical management of BPH was once one of the most common surgeries performed in the U.S. Although surgery for BPH has become less common due to successful medical management, TURP and other approaches are still routinely performed for patients not sufficiently improved with more conservative measures. The complications of TURP are well-known and well-studied, including bladder neck contracture, urethral stricture, and only rarely RUF.<sup>3</sup> However, in the nearly 100 year history of TURP, never has transanal prolapse of the bladder been reported as a complication. A review of the medical literature has identified a single report of transanal bladder prolapse due to pelvic fracture occurring in two dogs.<sup>4</sup>

After diagnosis of RUF, traditional management with urinary and fecal diversion was accomplished in this patient.<sup>2</sup> The subsequent development of parastomal hernias and rectal prolapse



**Figure 1.** Preoperative views of the bladder prolapse through rectum from lateral (A) and caudal (B) views. Postoperative image of specimen after transanal cystectomy and final postoperative appearance after bilateral gracilis flaps (C).

was likely related to poor healing in this elderly gentleman. Unfortunately, the initial surgical approach for rectal prolapse (Thiersch procedure) was ineffective and transanal bladder prolapse developed. Multiple surgical options were considered for this unique situation and a multi-specialty team was consulted. Based on the parastomal hernias and reportedly 'hostile pelvis,' a perineal approach was preferred.<sup>5</sup> Interestingly, the anatomy lent itself to an unusual surgical approach: a transanal cystoprostatectomy. To our knowledge, there are no prior reports of natural orifice surgery for cystectomy for any cause. Management in this case has resulted in a desirable outcome in an unusual situation.

### Conclusion

Despite the unprecedented clinical scenario described here, the transanal bladder prolapse was successfully managed using a multi-disciplinary approach. Utilizing a natural orifice for cystectomy has not been reported to our knowledge. Furthermore, the success of this case's outcome shows that it is possible to perform a perineal cystectomy in extreme circumstances. We hope that our approach will provide guidance and affirmation that this complication, although rare, is manageable.

### Conflicts of interest

The authors have no conflicts of interest.

### Acknowledgment

The corresponding author would like to thank the Betz Family Endowment for Cancer Research for their continued support. Funding was provided in part by the Spectrum Health Foundation (RG0813-1036).

### References

1. Lane B, Angermeier K. Rectourethral fistulae. In: Potts J, ed. *Genitourinary Pain and Inflammation*. Humana Press; 2008:337–349.
2. Hechenbleikner EM, Buckley JC, Wick EC. Acquired rectourethral fistulas in adults: a systematic review of surgical repair techniques and outcomes. *Dis Colon Rectum*. 2013;56:374.
3. Mebust WK, Holtgrewe HL, Cockett AT, et al. Transurethral prostatectomy: immediate and postoperative complications. A cooperative study of 13 participating institutions evaluating 3885 patients. *J Urol*. 1989;141:243.
4. Crivellenti LZ, Silveira MP, Silva AN, et al. Transrectal bladder prolapse secondary to pelvic fracture in two dogs. *J Small Anim Pract*. 2014;55:424.
5. Wexner SD, Ruiz DE, Genua J, et al. Gracilis muscle interposition for the treatment of rectourethral, rectovaginal, and pouch-vaginal fistulas: results in 53 patients. *Ann Surg*. 2008;248:39.