

Pediatrics

Robotic repair of congenital vesicovaginal fistula masquerading as a ureterocele in a 10-year-old girl

Yuenshan Sammi Wong^a, Yuk Him Tam^{a,*}, Kristine Kit Yi Pang^a, Symphorosa Shing Chee Chan^b, Winnie Chiu Wing Chu^c

^a Division of Paediatric Surgery and Paediatric Urology, Department of Surgery, Prince of Wales Hospital, The Chinese University of Hong Kong, Hong Kong, China

^b Department of Obstetrics and Gynaecology, Prince of Wales Hospital, The Chinese University of Hong Kong, Hong Kong, China

^c Department of Imaging and Interventional Radiology, Prince of Wales Hospital, The Chinese University of Hong Kong, Hong Kong, China



ARTICLE INFO

Keywords:

Congenital vesicovaginal fistula

Ureterocele

Robot-assisted laparoscopy

Distal vaginal agenesis

Introduction

Acquired vesicovaginal fistula develops as a result of complications after surgical trauma, obstructed labor, neoplasms and local radiotherapy. In contrast, congenital vesicovaginal fistula (CVVF) is a rare condition which can present in childhood or adulthood. While CVVF can occur in isolation, more commonly it coexists with urological anomalies and vaginal obstruction due to distal vaginal agenesis or transverse vaginal septum.^{1–3} Children present with continuous urinary incontinence if vagina is normal.^{1,4} When vaginal obstruction is present, recurrent urinary tract infection may occur in childhood, or if there is delay in making the diagnosis, affected adults present with menouria and difficulty in sexual intercourse.^{1–3} In this report we presented a case which was initially managed as ureterocele while the final diagnosis was CVVF associated with distal vaginal agenesis and a dysplastic kidney.

Case presentation

With the antenatal history of a solitary right kidney, the patient presented with her first episode of urinary tract infection at the age of 6 years. Micturating cystourethrogram did not reveal any vesicoureteral reflux. Ultrasound (US) imaging showed unremarkable right kidney, empty left renal bed, a thin-walled cystic lesion in bladder suggestive of a left-sided ureterocele associated with a short ureteric remnant, and a fluid-filled vagina (Fig. 1). The patient was then managed conservatively.

The patient experienced periodic lower abdominal pain associated with urinary frequency at her age of 10 years, and was surgically managed in another institution. Under general anesthesia, she was found to have absent vaginal opening. Cystoscopy showed a roundish swelling at the left-sided hemi-trigone, and considered to be a ureterocele. Cystoscopic incision of the swelling released old blood. Laparoscopic removal of the left dysplastic kidney ectopically located at a low position was also performed in the same session.

After the surgery, the patient experienced periodic haematuria that happened monthly and lasted for a couple of days in each episode. The symptom was suggestive of menouria and the patient was referred to us. MR Urogram raised the suspicion of a vesicovaginal fistula but the exact course of the tract could not be delineated.

We repeated cystoscopy with contrast study under fluoroscopy. A swelling was noted at the left-sided hemi-trigone with an opening which was consistent with the previous cystoscopic incision. The opening allowed the passage of the cystoscopy into a cavity of 1.5–2cm in longitudinal dimension. At the cranial limit of the cavity we noted another opening which led to the blind-ended ureteric remnant. Although the cystoscope could not find the way from the abnormal cavity to the vagina, contrast injection readily showed up a distended vagina posterior to the abnormal cavity and the vagina ended blindly at around 2cm above the perineum. The overall cystoscopic findings were suggestive of CVVF associated with distal vaginal agenesis and a ureter ectopically opening on the fistula.

We performed the definitive surgery by a combined robot-assisted laparoscopic approach using the da Vinci S platform (Intuitive Surgical,

* Corresponding author.

E-mail address: pyhtam@surgery.cuhk.edu.hk (Y.H. Tam).

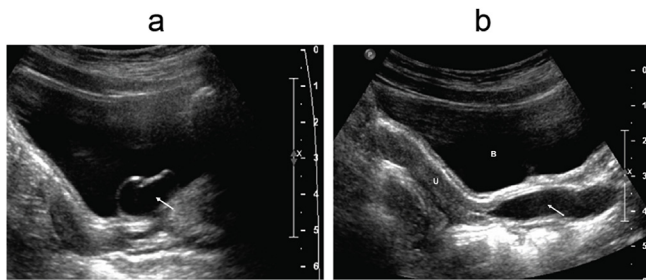


Fig. 1. Ultrasound images showing the intravesical end of CVVF and the fluid-filled vagina. (1a) The arrow points to the CVVF bulging into the bladder masquerading as a ureterocele; (1b) The arrow points to the fluid-filled vagina, U = uterus, B = bladder.

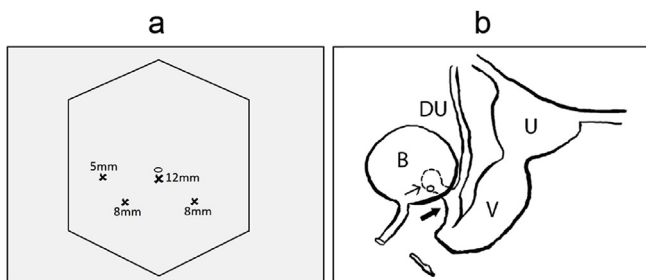


Fig. 2. Schematic drawing showing the port sites and the anatomy. (2a) An ancillary 5-mm port was used in addition to the three robotic ports; (2b) Thick arrow points to the extravascular part of the CVVF that measured around 4cm in length. Thin arrow points to the bladder end of the CVVF. B = bladder, U = uterus, V = distended vagina ending blindly, DU = distal ureter ending blindly onto the fistula.

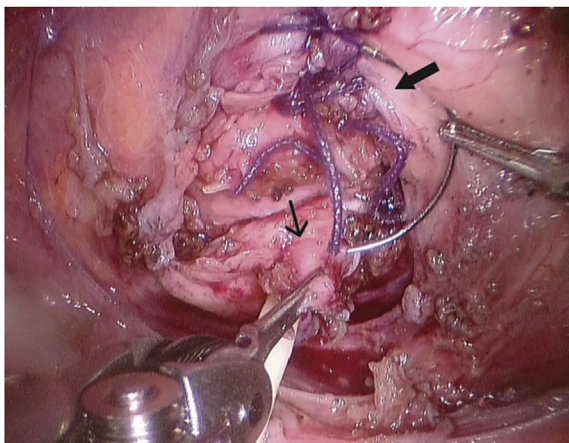


Fig. 3. Intraoperative view by robot-assisted laparoscopy. Thick arrow points to the bladder defect which was closed by sutures. Thin arrow points to the fistula on the vaginal side which was stented by an angiocatheter.

Sunnyvale, CA) for the closure of CVVF, and perineal approach for the vaginoplasty. The port sites were shown in Fig. 2a. The anatomical abnormalities were delineated intraoperatively (Fig. 2b). Cystostomy was made and the CVVF was excised from the bladder. The bladder defect and the fistula stump on the vaginal side were closed by sutures in double layers (Fig. 3). The patient recovered uneventfully after surgery with complete resolution of menouria. At a follow-up of two years, the patient has been free from any urinary tract symptoms with normal menses through the neovaginal opening.

Discussion

This is the first report of CVVF being confused with a ureterocele at the initial diagnosis. The thin-walled cystic lesion near the bladder base in US mimicked a ureterocele. We postulate that the urine production, though limited, by the dysplastic kidney draining directly into the CVVF, the distal vaginal obstruction, and the incomplete opening of the CVVF on the bladder side all contribute to the fluid distension within the fistula resulting in the development of a bulge into the bladder that masqueraded as a ureterocele.

Our patient was the second reported in the literature that a ureter ectopically opened onto a CVVF. The first case was reported by Asanuma et al. and their patient presented with continuous urinary incontinence in the presence of normal vagina.⁴ Others have reported CVVF associated with dysplastic kidney with ectopic ureteric insertion at the proximal vagina.³

Our findings demonstrated that complete patency may not be established in CVVF at the beginning. Menouria did not develop in our patient until the bladder end of the CVVF was incised cystoscopically. Had the CVVF not been incised, it is possible that the cyclical distension by the hematocolpos might eventually force open the bladder end of the CVVF.

Surgical treatment of CVVF associated with distal vaginal obstruction involves closure of the fistula and neovaginal construction. Previous reports mostly described fistula closure via laparotomy with or without bivalving the bladder or cystostomy.^{1,3,4} In contrast, minimally invasive surgery by either conventional laparoscopy or robot-assisted laparoscopy has been an established alternative to open surgery in closure of acquired vesicovaginal fistula.⁵ The use of robotic platform in this case alleviated the technical challenges of dissection and suturing in a small and deep pelvic cavity behind the bladder base if performed by conventional laparoscopy. We believe surgeons who are proficient in robot-assisted extravascular ureteral reimplant would agree with us that robotic repair is a sound if not superior treatment option in this case.

Conclusion

The diagnosis of CVVF in children is always delayed because of its rarity and its clinical presentations which are shared by other more common pathology. This diagnosis should be suspected, however, if a prepubertal girl has presumably a ureterocele while there is concern of vaginal obstruction suggested by a fluid-filled vagina in US. The diagnosis should also be born in mind before assuming as the culprit an ectopic ureter from a dysplastic kidney when treating girls who present with continuous urinary incontinence as the symptom would not be resolved after nephrectomy if CVVF is present.

Declarations of interest

None.

Funding source declaration

This research did not receive any specific grant from funding agencies in the public, commercial, or not-for-profit sectors.

References

- Martínez Escoriza JC, Palacios Marqués AM, López Fernández JA, et al. Congenital vesicovaginal fistula with or without menouria: a literature review. *Eur J Obstet Gynecol Reprod Biol.* 2014 Apr;175:38–48.
- Zeineddine HA, Nassif J, El-Hout Y, et al. Congenital vesicovaginal fistula: spontaneous or forced? Two cases and literature review. *Int Urogynecol J.* 2014 Sep;25(9):1167–1172.

3. Kumar S, Mandal A, Acharya N, Jain V, Kalra J, Singh S. Congenital vesicovaginal fistula with transverse vaginal septum and ectopic ureter opening in proximal vagina: case report and brief review. *Int Urogynecol J.* 2007;18:959–961.
4. Asanuma H, Nakai H, Shishido S, et al. Congenital vesicovaginal fistula. *Int J Urol* 2000;7(5):195–198.
5. Miklos JR, Moore RD, Chinthakanan O. Laparoscopic and robotic-assisted vesicovaginal fistula repair: a systematic review of the literature. *J Minim Invasive Gynecol.* 2015 Jul-Aug;22(5):727–736.