American Journal of Case Reports

e-ISSN 1941-5923
© Am J Case Rep, 2021; 22: e932048
DOI: 10.12659/AJCR.932048

Received: 2021.03.09
Accepted: 2021.05.17
Available online: 2021.06.01
Published: 2021.07.08

Brugada Pattern Manifesting During Hyperkalemia, Diabetic Ketoacidosis, and Acute Alcohol Intoxication

Authors' Contribution:
Study Design A
Data Collection B
Statistical Analysis C
Data Interpretation D
Manuscript Preparation E
Literature Search F
Funds Collection G

ACDEF 1 Kristopher S. Pfirman
ABEF 2 Connor J. Donley
ABEF 2 Emily B. Fryman
ABEF 2 Shivam U. Champaneria
BDEF 3 William T. Gatewood

1 Department of Cardiology, The Medical Center – Bowling Green, Western Kentucky Heart, Lung, and Gastroenterology, Bowling Green, KY, USA
2 University of Kentucky College of Medicine – Bowling Green, Bowling Green, KY, USA
3 Department of Emergency Medicine, Marietta Memorial Hospital, Marietta, OH, USA

Corresponding Author: Kristopher S. Pfirman, e-mail: kpfirman19@gmail.com
Conflict of interest: None declared

Patient: Male, 28-year-old
Final Diagnosis: Alcohol intoxication • Brugada pattern • diabetic ketoacidosis • hyperkalemia
Symptoms: Encephalopathy
Medication: —
Clinical Procedure: —
Specialty: Cardiology

Objective: Rare disease

Background: Brugada syndrome is a rare ion channelopathy that can lead to sudden cardiac death and lethal arrhythmias in patients without a structural cardiac defect, the most common of which being the gain-of-function mutation of the SCN5a sodium ion channel involving phase 0 of the cardiac action potential. In 2012, BrS electrocardiogram findings were redefined and classified as either congenital Brugada syndrome (BrS) or Brugada phenocopies (BrP). Several etiologies of BrP have been reported, such as metabolic derangements, electrolyte abnormalities, cardiovascular diseases, and pulmonary embolism.

Case Report: A 28-year-old man presented to the Emergency Department unresponsive. An initial ECG taken by Emergency Medical Services (EMS) was interpreted as a STEMI. An initial ECG in the ED showed a Brugada type I ECG pattern in leads V1-V2 and hyperacute T wave abnormalities, among other findings. Additionally, the patient had a serum potassium level of 9 mmol/L, glucose level of 1375 mmol/L, and peak cardiac troponin-I of 20.452 µg/L. All underlying medical conditions were stabilized, electrolyte and metabolic abnormalities were corrected, and subsequent normalization of electrocardiographic findings was achieved.

Conclusions: Distinguishing congenital Brugada syndrome from Brugada phenocopies can be difficult, especially when patients present to the ED with severe underlying conditions. Several factors can be used to direct clinical suspicion towards one or the other; however, confirmation may require EP studies and further tests. In this case, the following findings were suggestive of BrP: presence of an identifiable underlying abnormality, correction of the underlying condition resolves the ECG pattern, and the absence of family history of sudden cardiac death.

Keywords: Alcohol Induced Encephalopathy • Brugada Syndrome Diabetic Ketoacidosis • Hyperkalemia

Abbreviations: **BrS** – Brugada syndrome; **BrP** – Brugada ECG pattern; **ECG** – electrocardiogram; **ICD** – implantable cardiac defibrillator; **OMI** – occlusion myocardial infarction

Full-text PDF: https://www.amjcaserep.com/abstract/index/idArt/932048

2746 — 3 16

This work is licensed under Creative Common Attribution-NonCommercial-NoDerivatives 4.0 International (CC BY-NC-ND 4.0)

Indexed in: [PMC] [PubMed] [Emerging Sources Citation Index (ESCI)] [Web of Science by Clarivate]

Background

Since first reported in 1992, understanding of Brugada syndrome (BrS), a genetic, ion channelopathy responsible for 20% of unexplained sudden cardiac death (SCD) in patients without structural heart disease, has grown substantially [1,2]. Increased awareness and recognition of this rare syndrome has led to the discovery of familial gene mutations and variants responsible for the syndrome. In addition to better understanding the genetics and pathophysiology of the BrS, the diagnosis and management has evolved with these advances. Traditionally diagnosed by electrocardiogram (ECG) findings and clinically significant cardiac events, BrS demonstrated 3 separate ECG patterns (type 1 "coved", type 2 "saddleback", and type 3); however, the type 3 pattern is no longer thought to carry any diagnostic significance, as published in the European Heart Journal in 2017. While multiple cases of Brugada ECG pattern without BrS had been documented, it was in 2012 that the term "Brugada phenocopy" (BrP) was proposed to define these findings [2]. Of the many etiologies of BrP, metabolic derangements are the most common [2]. An important distinguishing characteristic of BrP is the resolution of the ECG pattern upon correcting the underlying or contributing abnormality, such as an electrolyte imbalance.

Case Report

The patient was a 28-year-old white man who presented to the Emergency Department (ED) via Emergency Medical Services (EMS) after being found unresponsive at his parents' home. EMS performed 12-lead electrocardiogram (**Figure 1:** ECG) obtained with ZOLL® X Series® Defibrillator and interpreted as an acute anterior myocardial infarction. The patient was brought to a Chest Pain-Accredited facility for further evaluation.

On arrival to the ED the patient's consciousness was waxing and waning and he demonstrated Kussmaul breathing. He was hypothermic and hypoxic with a core body temperature of 32.7°C and required 3 L of supplemental oxygen per nasal cannula to achieve an oxygen saturation of 100%. His blood pressure was 116/42 mmHg and heart rate 90 beats per minute. His pupils were equal and reactive to light, with non-icteric sclera. Oral mucous membranes were dry. His heart had regular rate and rhythm, with no murmurs. There was no jugular venous distension and no edema of the lower extremities. Radial and dorsal pedal pulses were intact and 2 plus bilaterally. The patient demonstrated Kussmaul breathing and was clear to auscultation bilaterally. His abdomen was soft and nontender. His skin had multiple tattoos, with no rashes or lesions. The patient was obtunded, but arousable and able to follow commands.

An initial arterial blood gas showed pH 6.85, carbon dioxide 14.0 kPa, oxygen 164.0 kPa, bicarbonate 2.3 mmol/L, base excess -29.6 mmol/L, and potassium of 9.0 mmol/L. Given that the pre-hospital ECG was suspicious for STEMI, Cardiology was consulted and evaluated the patient in the ED. The initial arrival ECG demonstrated an irregular rhythm without consistent p-wave to QRS complexes, and rSR' with down-sloping S-wave and inverted T-waves (**Figure 2:** ECG at 16: 17.) Cardiology agreed these findings were likely secondary to hyperkalemia and not STEMI. The Cardiac cath lab was not activated and empiric treatment was started with calcium carbonate and insulin therapy for suspected diabetic ketoacidosis. An ED repeat ECG (**Figure 3A:** ECG) showed improvement with reduction in rSR' in V1 and V2. Initial laboratory data showed sodium 115 mmol/L, potassium 9.0 mmol/L, chloride 76 mmol/L, blood urea nitrogen 88 mmol/L, creatinine 4.8 mmol/dL, glucose 1375 mmol/L. Calcium 7.9 mmol/L, alkaline phosphatase 112 µkat/L, bicarbonate <5.0 mmol/L, alanine aminotransferase 40 µkat/L, aspartate aminotransferase 26, µkat/L, albumin 3.5 g/L, total bilirubin 0.5 µmol/L, osmolality 330 mmol/kg, creatinine phosphokinase 176 units/L, troponin-I 0.596 µg/L,

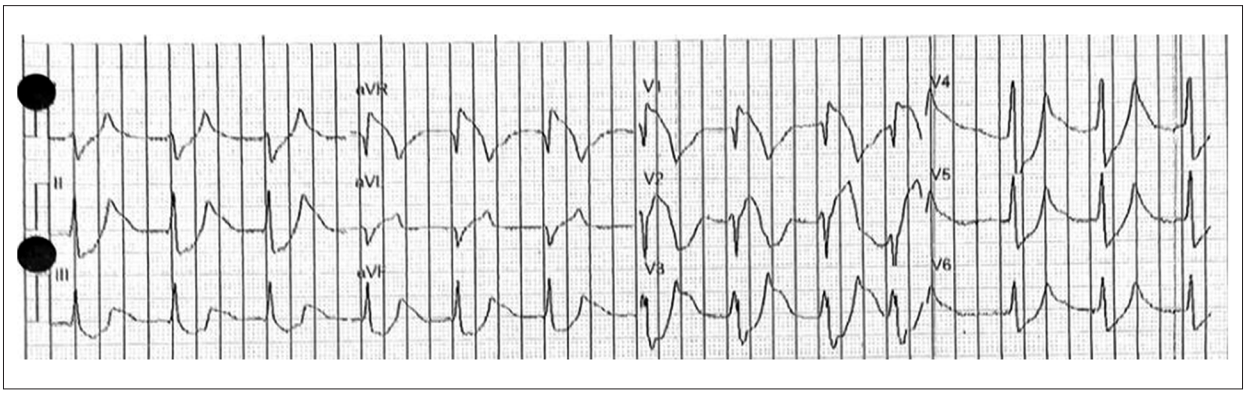

Figure 1. Presenting EKG obtained by EMS. Wide QRS complex with a rate of 74 beats per minute, Right axis deviation, absent P waves, ST depressions in inferior leads, T wave wide peaking/tenting, elevated J point in the septal leads with a type I Brugada pattern in V1-V2 with a nonspecific intraventricular conduction delay.

This work is licensed under Creative Common Attribution-NonCommercial-NoDerivatives 4.0 International (CC BY-NC-ND 4.0)

Indexed in: [PMC] [PubMed] [Emerging Sources Citation Index (ESCI)] [Web of Science by Clarivate]

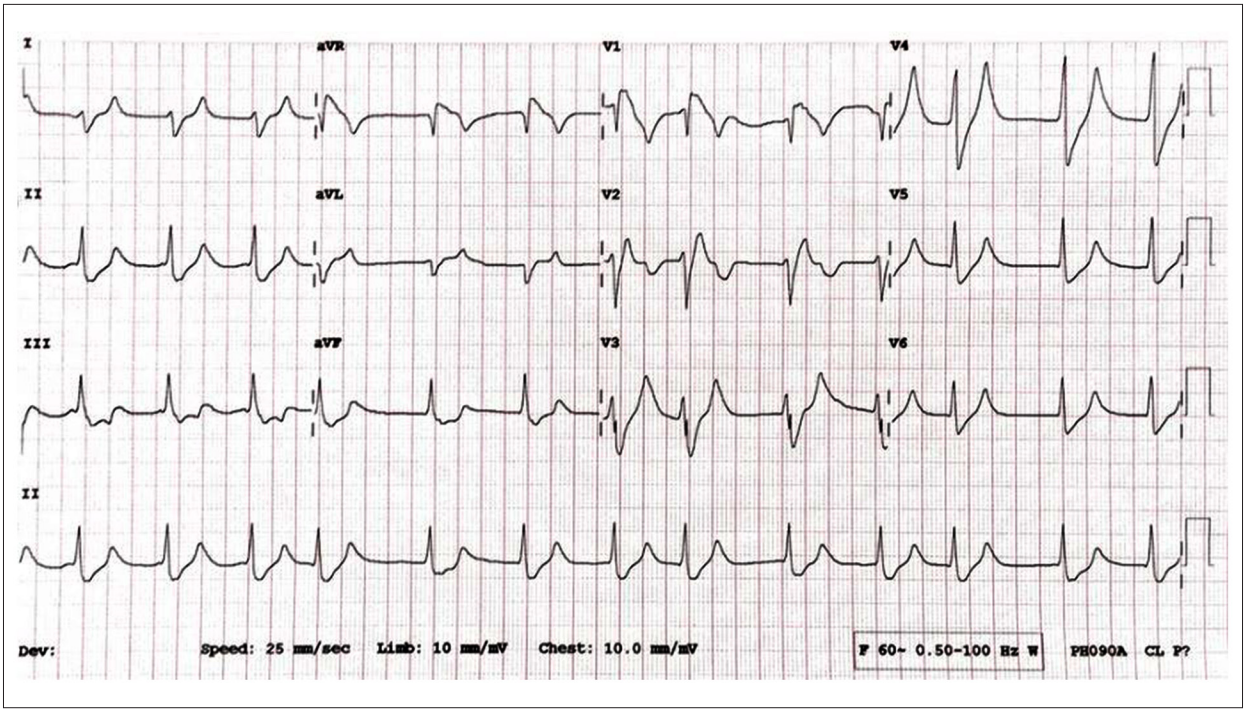

Figure 2. ECG obtained in the emergency department. Wide QRS complex with a rate of 75 beats per minute, Right axis deviation, ST depressions in inferior leads, absent P waves, T wave peaking/tenting, elevated J point in the septal leads with a type I Brugada pattern in V1-V2 with a nonspecific intraventricular conduction delay.

c-reactive protein 0.1 mg/L, glomerular filtration rate (GFR) 15 mL/s, creatinine kinase-MB 5.3 µg/L, myoglobin 551 nmol/L. White blood cell count 29.4×10^9/L, hemoglobin 8.1 g/L, hematocrit 25%,mean corpuscular volume 86.8 fL, and platelet count 301×10^9/L.

The patient was intubated, central venous access and dialysis catheter were placed, and he was covered with a Bair Hugger and multiple heated blankets. Intravenous access was started and aggressive volume resuscitation was started with 4 L of 0.09% normal saline boluses. The patient was admitted to the Intensive Care Unit (ICU) in guarded condition with presumed hyperosmolar coma secondary to diabetic ketoacidosis with type I diabetes mellitus, secondary to insulin therapy non-compliance and alcohol use.

Hospital course

During his initial course, the diabetic ketoacidosis was addressed with emergent central access placement, with aggressive fluid volume resuscitation and initiation of insulin infusion. Nephrology was consulted for his life-threatening electrolyte abnormalities and the potential need for emergent dialysis, which ultimately was not needed.

In response to having systemic inflammatory response syndrome on admission and suspected sepsis with elevated prolactin level (lactic acid pending), he was placed on empiric antibiotic therapy with vancomycin and meropenem. Chest radiography later confirmed a left lower-lobe aspiration pneumonia with lactic acidosis (lactic acid levels were not recorded in the documentation for this case report).

His initial cardiac troponin-I level was 0.596 µg/L, with subsequent 19.1 µg/L, peaking at 20.452 µg/L, and later trending downwards, while on weight-based heparin infusion and antiplatelet therapy. Cardiology consultation concluded that given no significant cardiac history and his presentation of DKA and profound hypovolemia, that this was likely a representation of a WHO fourth universal definition type-II myocardial infarction [3] given the lack of ST-segment elevation and 2D echocardiographic findings of preserved ejection fraction and absence of significant cardiac wall motion abnormalities.

By the sixth day of his hospital course, he continued to be biochemically and clinically improved, and was eager for discharge. No documented seizures or agonal nocturnal respirations were identified after extubation. His medical therapies were optimized and he was discharged home on atorvastatin 80 mg P.O. QHS, aspirin 81 mg p.o. daily, metoprolol tartrate 12.5 mg p.o. BID, amlodipine 5 mg p.o. daily, Levemir 25 units subcutaneous qam, and 10 units subcutaneous qpm, and novLog subcutaneous carb count.

This work is licensed under Creative Common Attribution-NonCommercial-NoDerivatives 4.0 International (CC BY-NC-ND 4.0)

Indexed in: [PMC] [PubMed] [Emerging Sources Citation Index (ESCI)] [Web of Science by Clarivate]

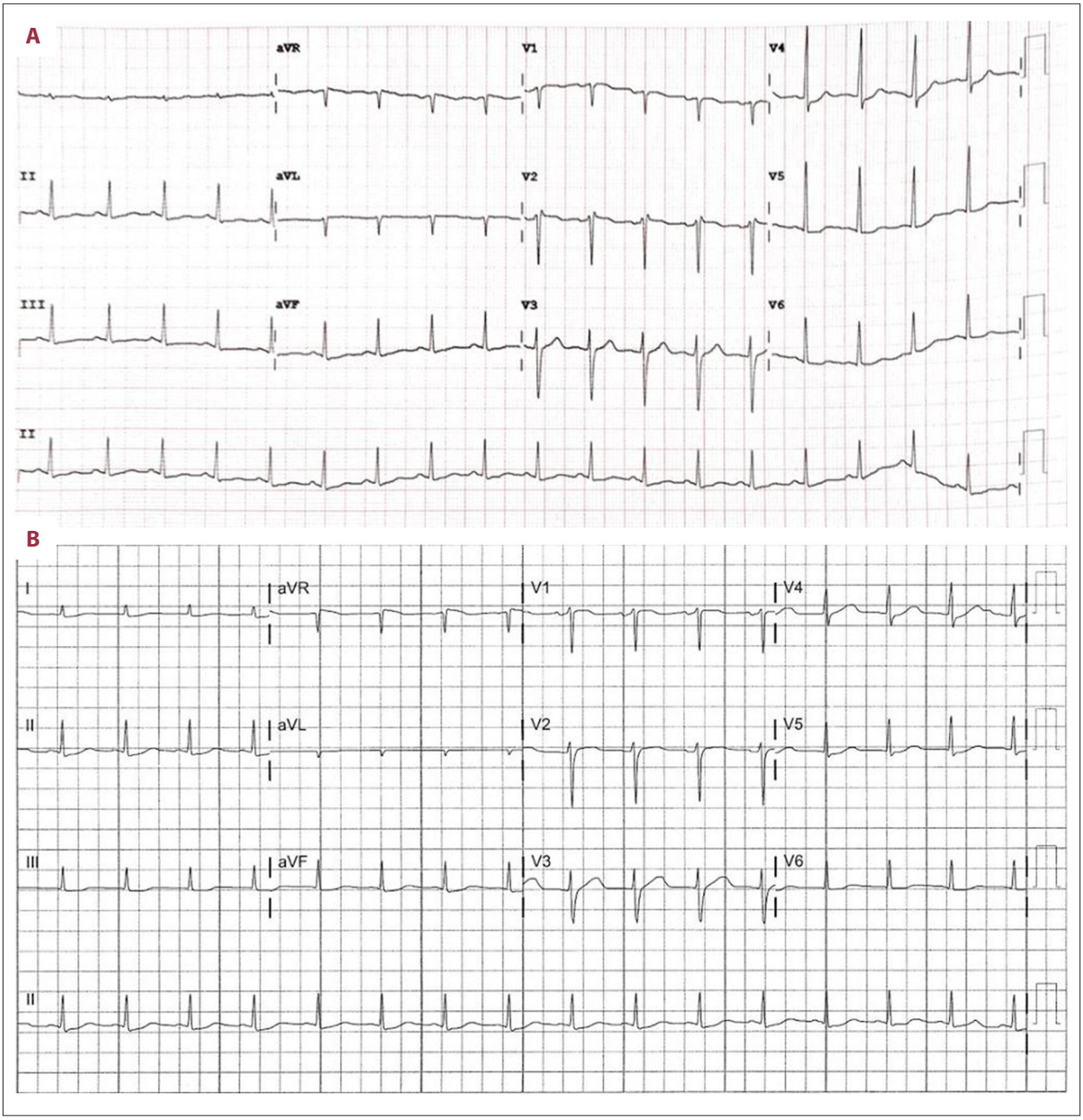

Figure 3. (**A, B**) Serial ECG when electrolyte and metabolic derangements were corrected. Normal sinus rhythm with a rate of 94 beats per minute. Narrow complex with a normal axis and normal PR interval. The both the hyperacute T wave abnormalities and Brugada pattern have resolved.

The patient had subsequent Cardiology follow-up for his non-ST-elevation myocardial infarction with a history of syncope, continued isolated dizzy spells with prior Brugada-like ECG findings, and high-risk diabetes. He underwent a left heart catheterization, selective coronary angiogram, and left ventriculogram with normal epicardial coronary arteries, and an ejection fraction of 65%. He was referred for electrophysiology consultation for further investigation (reports not available). There was no family history suggestive of sudden cardiac death nor proband-positive Brugada syndrome family history leading up to his hospital admission.

Discussion

The distinction needs to be made whether in this case, the patient demonstrated a Brugada pattern secondary to a Brugada phenocopy or from Brugada syndrome. This patient was found

This work is licensed under Creative Common Attribution-NonCommercial-NoDerivatives 4.0 International (CC BY-NC-ND 4.0)

Indexed in: [PMC] [PubMed] [Emerging Sources Citation Index (ESCI)] [Web of Science by Clarivate]

to be a high-risk diabetic stemming from early childhood. Additionally, it was Memorial Day weekend with patient-reported increased alcohol consumption, non-compliance with his insulin therapies leading to hyperosmolar diabetic ketoacidosis coma with severe dehydration, severe electrolyte and metabolic derangements, acute renal failure, sepsis and type-II myocardial infarction. This patient was originally alerted as a potential STEMI activation and was met by Cardiology in the ED. The EMS ECG and initial ED ECG taken in the context of a known diabetic and early arterial blood gas with electrolytes demonstrated the ECG findings were more likely to be secondary to severe hyperkalemia and not from an acute occlusive myocardial infarction, and the patient was treated with calcium carbonate, bicarbonate, and insulin infusion therapy. No cardiac resuscitation or ventricular arrhythmias were identified. Subsequent ECGs (**Figure 3A, 3B**) demonstrated normalization of Brugada pattern with resolution of the electrolyte and metabolic derangements, which favored BrP to BrS, although this was not confirmed by sodium-channel provocative electrophysiology testing while an inpatient.

The term STEMI refers to ST-elevation (STE) myocardial infarction. STE demonstrated on ECG with ischemic symptoms were concerning for an acute coronary occlusion that would benefit from emergent percutaneous coronary intervention (PCI) and reperfusion. The current 2013 ACCF/AHA STEMI Guidelines [4] utilize the Third Universal Definition of Myocardial Infarction for the diagnosis of STEMI (3). Known as "STEMI Criteria", in the absence of left bundle branch block and left ventricular hypertrophy, diagnostic ST-elevation is defined as "new ST-elevation at the J point in at least 2 contiguous leads of 2 mm (0.2 mV) in men or 1.5 mm (0.15 mV) in women in leads V2–V3 and/or of ≥1 mm (0.1 mV) in other contiguous chest leads or the limb leads" [3,4]. In 2016, the guidelines revised the age cutoff for ST-segment elevation in V2 and V3 to be men younger than 40 years of age STE of ≥2.5 mm or more in 2 contiguous leads [5].

While the presence of STE on ECG is helpful, not all acute coronary occlusions present with STE or meet the STEMI Criteria and are classified as non-ST-elevation myocardial infarction (STEMI) with the addition of positive cardiac biomarkers. A recent retrospective chart review of 467 high-risk acute coronary syndrome patients found that 40% of patients with OMI did not demonstrate STEMI criteria on ECG, which led to delayed cardiac catheterization and increased morbidity and mortality [6]. In our case, the patient's pre-hospital ECG (**Figure 1**) demonstrated a regular rhythm absent of P waves, with right axis deviation, left posterior fascicular block, intraventricular conduction delay (QRS >100 ms), ST-waves with a high-takeoff, STE at the J point in lead V1 of greater than 2.5 mm, and what appeared as J point elevation in V2, both followed by T wave inversions. Interestingly, leads II, III, and aVF demonstrated reciprocal ST-depressions, which support OMI (coronary angiography later revealed normal epicardial coronaries). The second ECG (**Figure 2**), recorded on arrival, showed an irregular rhythm absent of P waves, right axis deviation, left posterior fascicular block, intraventricular conduction delay, and similarly demonstrated STE in V1-V2 with T wave inversions with reciprocal STD.

Just as important as a missed occlusion myocardial infarction without ST-elevations (STEMI negative, OMI positive), the opposite can be true with a false positive STEMI. In 60-80% of patients presenting with STE, no acute coronary occlusion was found [7]. The diagnosis of myocardial infarction with nonobstructive coronary arteries has become a recent focus in the cardiac literature. Findings recently released at TCT and the publication of the MINOCA: HARP trial in 2020 have supported the role of optical coherence tomography in tandem with cardiac MRI to identify a conceivable etiology for the event in women.

Referred to as a STEMI mimics and defined as ST-elevation with no acute occlusion myocardial infarction, these mimics are often misinterpreted as acute STEMI, leading to inappropriate cardiac catheterization activation, and patients undergoing coronary angiography without potential benefit and increased risk of procedural harm.

In this case, the Brugada pattern is considered a STEMI mimic. These STEMI mimics are caused by non-acute coronary syndrome conditions, including Brugada syndrome [8]. More common clinically-encountered conditions include: electrolyte abnormalities (ie, hyperkalemia, hypokalemia, hypercalcemia), shock (cardioversion/defibrillation), inflammation (myocarditis/pericarditis), medications (ie, cardiac, chemotherapeutics, psychotropics), toxins (ie, cocaine, amphetamines, ethanol), and mechanical cardiac and thoracic disorders (ie, aortic dissection, coronary aneurysm, pulmonary embolism) [7-10]. Conversely, certain underlying chronic conditions, including early repolarization, left bundle branch block, and left ventricular hypertrophy, can make the diagnosis of STEMI difficult, these are described as *STEMI confounders*, and also mimickers of OMI [7].

As with STEMI criteria, Brugada syndrome has several ECG patterns used in its diagnosis. In each of these 3 Brugada ECG patterns (BrP) there will be a right bundle branch block (RBBB) or incomplete RBBB with STE in the precordial leads V1-V2. Additionally, a shortened PR interval can be seen but is not required, and ST-segment depressions are not commonly demonstrated [9]. Similarly, many conditions can mimic BrP and present as either acute (ie, metabolic derangements, infection) and chronic (ie, left ventricular hypertrophy or RBBB) [9]. In this case, severe hyperkalemia and acidosis secondary to diabetic ketoacidosis were likely the precipitating factors causing the BrP findings. The mechanism of BrP in patients

This work is licensed under Creative Common Attribution-NonCommercial-NoDerivatives 4.0 International (CC BY-NC-ND 4.0)

Indexed in: [PMC] [PubMed] [Emerging Sources Citation Index (ESCI)] [Web of Science by Clarivate]

with DKA is not fully understood but is proposed to be related to hyperkalemia and acidosis inactivating cardiac sodium ion channels by decreasing the resting membrane potential [11,12].

The pathophysiology of Brugada syndrome has yet to be completely identified, but 2 leading theories have emerged. The first theory is transmural dispersion of repolarization with ST-segment elevation. The second, which has obtained more attention in recent years, results from impeded conduction in the right ventricular outflow tract, resulting in ST-segment elevations in the right precordial leads. These regional differences in right ventricular epicardial conduction are aggravated by the decrease in inward sodium channels that are exacerbated by class Ic sodium channel inhibitors. Epicardial reentrant excitation waves are provoked and unmasked, resulting in the classic "coved" type I Brugada appearance on the electrocardiogram. This may also explain how Brugada patterns can be revealed by moving V1 and V2 more superior or cranially on the precordium to the second intercostal space. The sodium channel derangements lead to early after depolarizations from the right ventricular outflow tract epicardium, ultimately leading to oscillations of potential QRS depolarizations, which can exceed the threshold, which triggers a true ventricular event such as ventricular fibrillation or tachycardia [13]. This slows the upstroke of the phase 0 cardiac action potential, and the L-type inward calcium channels and transient dependent outward current during phase 1 have also been implicated as a substrate for Brugada morphology and arrhythmias [14]. Bradycardia exacerbates these findings and increases the potential for these dangerous rhythms to prevail.

Hyperkalemia is a frequently encountered and life-threatening diagnosis in the ED. Known for its wide variability of ECG findings, it is often referred to as "the syphilis of electrocardiography" [15]. The patient did not endorse any chest pain or presentation of sudden cardiac death. Additional features suggestive of hyperkalemia induced Brugada-like pattern ECG were the presence of hyperacute T wave, right axis deviation, widened QRS duration, the absence of P waves. This case was further confounded with the consumption of ethyl alcohol, hyperglycemia, and diabetic ketoacidosis, all of which can contribute to inducing a Brugada pattern. The acidosis present may contribute to the provocation of the Brugada pattern, which may alter and decrease the membrane potential by inhibiting the cardiac sodium ion channels, especially in the setting of hyperkalemia. Dreaded hyperkalemia changes can include sine wave induction and ultimately ventricular fibrillation as the hyperkalemia worsens. Luckily for our patient, these sequelae were not experienced. Recently, hyperkalemia- and acidemia-induced Brugada was thought to be due to depolarized resting membrane potential and reduced sodium-channel availability for activation. This is especially augmented and amplified if there is fibrosis at the right ventricular outflow tract. When the fibrosis is present, this increases the activation delay and slows the conduction velocity while fractionating the QRS complex, setting up the milieu for reentry arrhythmias [16]. This pathologic state then creates the Brugada pattern on the ECG, creating the Brugada mimic pattern found in leads V1 and V2. This shortening of the action potential during pathologic levels of hyperkalemia increases the sensitivity to reentry arrhythmias due to shortening of the plateau and early repolarization phase, setting up a unidirectional block originating from the right ventricular outflow tract, which may contribute to the arrhythmias that can develop in patients with hyperkalemic, especially if they exhibit as Brugada pattern on the ECG [16].

This case report adds to the literature an example of diabetic ketoacidosis and severe hyperkalemia producing a Brugada type I ECG pattern initially thought to be a myocardial infarction, which resolved with management of his electrolyte and metabolic derangements.

Conclusions

Distinguishing Brugada syndrome from Brugada patterns or mimics can be extremely difficult, especially when patients present to the ED with severe underlying conditions. Several factors can be used to direct clinical suspicion towards one or the other, but confirmation may require EP studies and further tests to be completed. In our case, the following findings were suggestive of BrP: presence of an identifiable underlying abnormality with other findings suggestive of hyperkalemia such as QRS widening, and loss of P waves. The transient nature of the Brugada pattern with the correction of the underlying condition and resolution as determined by the ECG and the absence of family history of sudden cardiac death or family proband identification argues against Brugada syndrome. The patient did not fit the classic definition of syncope, and the acute encephalopathy was deemed metabolic in nature and not arrhythmogenic, arguing against a cardiac origin. The patient was referred to Electrophysiology for further provocative testing for completeness. Genetic testing would be indicated if the provocative testing was positive. There is no current indication for ICD implantation, consideration for experimental EP ablation of RVOT given the lack of identification of ventricular tachycardia, or medication consideration at this time, such as quinidine.

Conflict of Interest

None.

This work is licensed under Creative Common Attribution-NonCommercial-NoDerivatives 4.0 International (CC BY-NC-ND 4.0)

Indexed in: [PMC] [PubMed] [Emerging Sources Citation Index (ESCI)] [Web of Science by Clarivate]

References:

1. Brugada J, Campuzano O, Arbelo E, et al. Present status of Brugada syndrome: JACC state-of-the-art review. J Am Coll Cardiol. 2018;72(9):1046-59
2. Baranchuk A, Nguyen T, Ryu MH, et al. Brugada phenocopy: New terminology and proposed classification. Ann Noninvasive Electrocardiol. 2012;17(4):299-314
3. Thygesen K, Alpert JS, Jaffe AS, et al. Third universal definition of myocardial infarction. Circulation. 2012;126:2020-35
4. O'Gara PT, Kushner FG, Ascheim DD, et al; American College of Cardiology Foundation/American Heart Association Task Force on Practice Guidelines. 2013 ACCF/AHA guideline for the management of ST-elevation myocardial infarction: A report of the American College of Cardiology Foundation/American Heart Association Task Force on Practice Guidelines. Circulation. 2013;127(4):e362-425
5. Ibanez B, James S, Agewall S, et al; ESC Scientific Document Group. 2017 ESC Guidelines for the management of acute myocardial infarction in patients presenting with ST-segment elevation: The Task Force for the management of acute myocardial infarction in patients presenting with ST-segment elevation of the European Society of Cardiology (ESC). Eur Heart J. 2018;39(2):119-77
6. Meyers HP, Bracey A, Lee D, et al. Comparison of the ST-elevation myocardial infarction (STEMI) vs. NSTEMI and occlusion MI (OMI) vs. NOMI paradigms of acute MI. J Emerg Med. 2021;60(3):273-84
7. Pollak P, Brady W. Electrocardiographic patterns mimicking ST segment elevation myocardial infarction. Cardiol Clin. 2012;30(4):601-15
8. Tewelde SZ, Huis in't veld M. ACS mimics part I: Non-ACS causes of ST-segment elevation. In: Mattu A, Tabas J, Brady W. Electrocardiography in emergency, acute, and critical care. 2nd ed. 2019;141-58
9. Abella BS, Chelluri J. Inherited syndromes of sudden cardiac death. In: Mattu A, Tabas J, Brady W. Electrocardiography in emergency, acute, and critical care. 2nd ed. 2019;199-203
10. Nable JV, Lawner BJ. Chameleons: Electrocardiogram imitators of ST-segment elevation myocardial infarction. Emerg Med Clin North Am. 2015;33(3):529-37
11. Haseeb S, Kariyanna PT, Jayarangaiah A, et al. Brugada pattern in diabetic ketoacidosis: A case report and scoping study. Am J Med Case Rep. 2018;6(9):173-79
12. Ameen M, Akbar G, Abbas N, Mirrani G. Hyperkalemia induced brugada phenocopy: A rare ECG ,anifestation. Case Rep Cardiol. 2017;2017:9464728
13. Pfirman KS, White CA, Kelil A, Modi HC. Brugada syndrome manifesting only during fever in patient with septic shock secondary to post-obstructive pneumonia. Am J Case Rep. 2018;19:1311-16
14. Doty B, Kim E, Phelps J, Akpunonu P. Pathophysiology of hyperkalemia presenting as brugada pattern on electrocardiogram (ECG). Am J Case Rep. 2020;21:e923464
15. Saad SM, Yasin S, Jain N, LeLorier P. Cardiac manifestations in a case of severe hyperkalemia. Cureus. 2021;13(3):e13641
16. Rivera-Juárez A, Hernández-Romero I, Puertas C, et al. Clinical characteristics and electrophysiological mechanisms underlying Brugada ECG in patients with severe hyperkalemia. J Am Heart Assoc. 2019;8(3):e010115

This work is licensed under Creative Common Attribution-NonCommercial-NoDerivatives 4.0 International (CC BY-NC-ND 4.0)

Indexed in: [PMC] [PubMed] [Emerging Sources Citation Index (ESCI)] [Web of Science by Clarivate]