

Received: 2013.03.18
Accepted: 2013.05.07

Endovascular embolization of varicoceles using n-butyl cyanoacrylate (NBCA) glue

Radosław Pietura¹, Michał Toborek¹, Aneta Dudek¹, Agata Boćkowska¹,
Joanna Janicka¹, Paweł Piekarski²

¹ Department of Radiography, Medical University of Lublin; Department of Interventional Radiology and Diagnostic Imaging, Independent Public Clinical Hospital No. 1 in Lublin, Lublin, Poland

² Provincial Specialist Hospital in Radom, Radom, Poland

Author's address: Radosław Pietura, Department of Interventional Radiology and Diagnostic Imaging, Independent Public Clinical Hospital No. 1 in Lublin, Lublin, Poland, e-mail: radoslawpietura@poczta.onet.pl

Summary

Background:

Varicoceles are abnormally dilated veins within the pampiniform plexus. They are caused by reflux of blood in the internal spermatic vein. The incidence of varicoceles is approximately 10–15% of the adolescent male population. The etiology of varicoceles is probably multifactorial. The diagnosis is based on Doppler US. Treatment could be endovascular or surgical.

The aim of the study was to describe and evaluate a novel method of endovascular embolization of varicoceles using n-butyl cyanoacrylate (NBCA) glue.

Material/Methods:

17 patients were subjected to endovascular treatment of varicoceles using NBCA. A 2.8 Fr microcatheter and a 1:1 mixture of NBCA and lipiodol were used for embolization of the spermatic vein.

Results:

All 17 procedures were successful. There were no complications.

Discussion:

Embolization of varicoceles using NBCA glue is efficient and safe for all patients. The method should be considered as a method of choice in all patients. Phlebography and Valsalva maneuver are crucial for technical success and avoidance of complications.

Conclusions:

Endovascular treatment of varicoceles using NBCA glue is very effective and safe.

Key words:

varicoceles • embolization • n-butyl cyanoacrylate

PDF file:

<http://www.polradiol.com/download/index/idArt/889181>

Background

Varicoceles are abnormally dilated veins comprising the pampiniform plexus and main trunks of the spermatic vein. The dilation is caused by reflux of blood towards the testicles. The incidence of varicoceles is 10–15%, mostly in young male population (15–35 years) [1]. Varicoceles are virtually not observed before the age of 10; in the subpopulation of males suffering of infertility, the rate can be as high as 45% [2]. The lesions are most frequently located on the left side (10:1); with bilateral location observed in ca. 10% of patients, and solely right-sided location observed in 1–2% [3,4].

The etiology of varicoceles is multifactorial. Most authors highlight the role of congenital defects of the spermatic vein, congenital insufficiency of spermatic valves as well as compression of left renal vein between the aorta and the superior mesenteric artery ("nutcracker syndrome") [5,6].

Clinical symptoms of varicoceles include scrotal pain, discomfort within the scrotal region, perceptible thickening of scrotum, as well as sperm abnormalities (a drop in the number and motility of sperm, increase in abnormal forms). The relationship of varicoceles with the reduction in sperm quality is rationalized by increased temperatures within the testicle, increased levels of vasoactive hormones and increased oxidative stress [7].

The diagnostics of varicoceles is based mainly on clinical examination and Doppler ultrasound imaging. The importance of Color-coded blood flow ultrasound imaging in standing position and of the Valsalva maneuver should be highlighted. A typical symptom is the reflux of blood within the spermatic vein, lasting at least 2 seconds. A three-grade classification of clinical and ultrasound lesions is commonly accepted [8]. Phlebography continues to be considered a gold standard as it provides the best imaging of the entire network of venous outflow of blood from the scrotum; however, being an invasive procedure, it should be performed only at the initial stage of endovascular treatment or for diagnosing disease recurrence following earlier invasive treatment.

Symptomatic varicoceles are treated by interrupting the reflux within the spermatic vein and its branches above the pampiniform plexus. The two main treatment modalities include surgical treatment (including laparoscopic procedures) and endovascular treatment (embolization). The endovascular method allows for full diagnosis of venous bed, shorter work absence, lower treatment costs and technical efficacy of nearly 100% [9,10]. The most common endovascular embolization materials for closing the pathological veins are metal coils and liquid sclerosing agents. Endovascular placement of metal coils inside the spermatic vein results in foreign bodies being left in large amounts within the body for the rest of patient's life, as well as is cost-consuming. Injection of a sclerosing agent in the form of a foam generated by mixing the liquid with air followed by a 10-minute manual compression of the vein do not ensure full control of the sclerosing agent, extending the duration of the procedure and reducing its efficacy [11]. In early 1980s, the use of iso-butyl cyanoacrylate (IBCA) glue in vein embolization was reported [12]. Due to its carcinogenic properties, ICBA was replaced by the more safe n-butyl cyanoacrylate (NBCA) [13]. NBCA embolization appears to be a fast, efficient and cost-effective method of embolization of the spermatic vein [14].

The aim of the study is to describe a method of endovascular treatment of varicoceles and to preliminarily assess efficacy and safety of this method.

Material and Methods

Seventeen males aged 19 through 41 years were subjected to endovascular treatment of varicoceles between July 2011 and January 2013. The patients were proposed this solution by physicians of the following specialties: urologist (9), vascular surgeon (3), gynecologist (5). All patients reported scrotal pain, scrotal thickening and discomfort in the scrotal region. The lesions were grouped according to modified Dubin and Amelar scale: grade 1 (small) – 3 patients; grade 2 (moderate) – 8 patients; grade 3 (large) – 6 patients [15]. A pre-requirement for the treatment was ultrasound scan that determined the morphology of lesions, complete with determination of the duration of reflux within the spermatic vein in during the Valsalva maneuver in standing position (reflux of ≥ 2 seconds). Similar examination was made 3 months after the procedure in order to determine the technical efficacy. In 14 out of 17 patients had sperm tests performed, revealing sperm counts and mobility below the

normal levels as well as an increased number of abnormal forms. Three patients did not agree to undergo sperm tests. The remaining 14 patients stated fertility problems as the main reason for seeking treatment. In all 17 men, the lesions were located on the left side. In 10 out of 17 patients, segmental doubling of spermatic vein or additional, narrow branches extending to renal veins, iliac veins, or inferior caval vein. Two out of 17 patients had been previously treated surgically to no effect. One patient referred by a gynecologist was not subjected to embolization due to the efficiency of left spermatic vein as detected upon phlebographic examination (small varicoceles in ultrasound scans and abnormal sperm tests). Blood type and coagulation profile (INR) were determined before the procedure.

Embolization was performed under local lidocaine infiltration anesthesia in Trendelenburg position. In our opinion, 11 out of 17 patients required sedation with hydroxyzine. During the Valsalva maneuver, right common femoral vein was punctured and a 4 Fr central venous port (11 cm in length) was introduced. Heparin (3000 units) was administered into the femoral vein through the port. Next, a Cobra 2 selective catheter (4 Fr) was introduced into the inferior caval vein using a 0.035" hydrophilic guide wire for selective catheterization of left renal artery (at the L1/L2 vertebral trunk level). Depending on the anatomy, the Cobra 2 catheter was introduced either into the renal vein (9) or into the proximal segment of left spermatic vein (8). Leaving the catheter tip in the left renal vein allowed to avoid potential contracture of the spermatic vein but reduced the overall stability of the system. Next, a 2.7 Fr hydrophilic microcatheter (Progreat, Terumo) was introduced coaxially into the spermatic vein using a 0.018" hydrophilic micro wire. Initially, the microcatheter was introduced into the proximal part of the spermatic vein and phlebographic examination was performed to assess the reflux (confirm the incompetence of the valves) and to assess any anatomical variants (Figure 1) The images were grouped according to Bahren's classification [16]. In the study group, type I variant was detected in 10 patients, type III was detected in 6 patients while type IV was detected in 1 patient. Next, the microcatheter was inserted distally into the spermatic vein up to the crural arch level and selective phlebography was performed during Valsalva maneuver (Figure 2). Instructing the patient about proper performance of the Valsalva maneuver was very important. The maneuver allowed for significant reduction or complete blocking of the blood flow within the spermatic vein, which was crucial for the safety of the procedure. In addition, phlebographic examination allowed to assess the quantity of the administered contrast agent which corresponded to the approximate quantity of glue required. Next, a mixture of NBCA glue and lipiodol was prepared at a separate, sterile table following replacement of sterile gloves with new ones. A dry, sterile, small vessel was charged with 1 mL of the glue (2 tubes) and 1 mL of lipiodol and the contents were mixed carefully. Thus obtained blue solution was aspirated into a 2.5 mL or 3 mL screw cap syringe. Phlebographic examination was performed again upon Valsalva maneuver in order to confirm the location of the catheter and to assess patient's capability to remain breathless. Microcatheter was washed twice with 5% glucose (non-ionized) solution to prevent glue polymerization

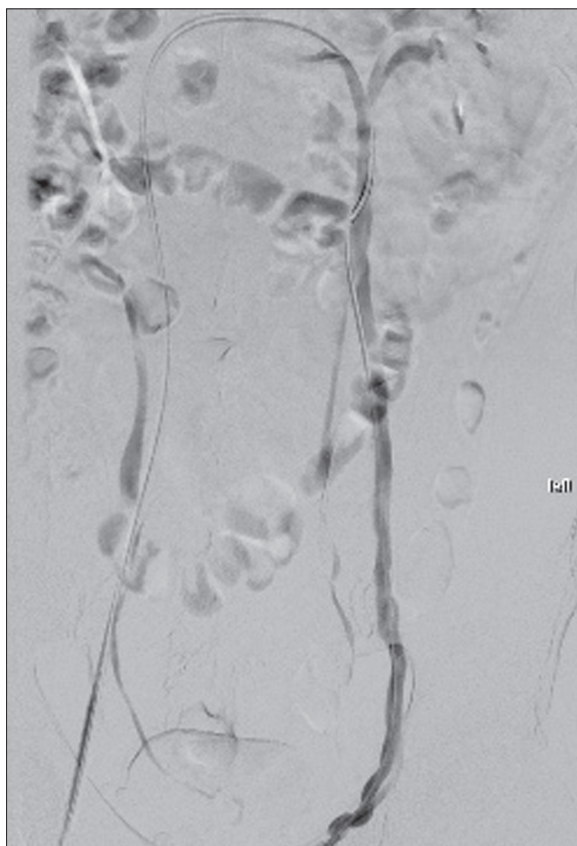


Figure 1. Phlebography (DSA) of spermatic vein. Contrast media injected by microcatheter.

in the catheter lumen. The next stage of the procedure was the injection of the glue into the spermatic vein from the inguinal canal to the upper end plate of L3 vertebral trunk. Administration of glue was initiated upon Valsalva maneuver at the inguinal canal level; next, the microcatheter was withdrawn proximally to the L3 trunk level. Upon moving the catheter near the junctions of additional branches, catheter withdrawal was slowed down and the glue was administered at higher rates so as to embolize the additional branches of the spermatic vein as well. The NBCA glue flowing off the microcatheter underwent polymerization upon contact with ionized blood. The reaction led to high temperature that led to vein obliteration and was perceived by the patient as mild, transient pain. Upon withdrawing the distal tip of the catheter to the level of the upper end plate of the L3 trunk, the glue was rapidly aspirated around the microcatheter tip and the microcatheter was removed using a rapid movement from the 4 Fr catheter so as to avoid the adhesion of the microcatheter tip to the vein. Next, an attempt of blood aspiration was made using the Cobra catheter. In case of the lack of patency due to the presence of glue particles within the catheter, it was removed from the patient's body without rinsing. Follow-up angiography was not performed and the vein closure level was visualized upon fluoroscopic examination by the contrasting NBCA glue. After the procedure, the central venous port was removed from the femoral artery and the punctured region was compressed manually for 10–15 minutes. In order to determine the stability of the glue in the spermatic vein after completing the compression and

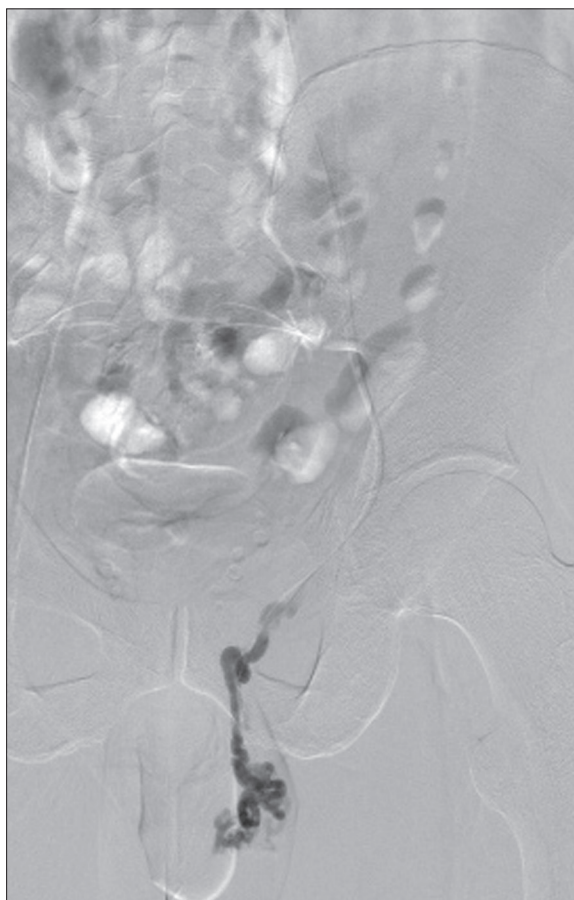


Figure 2. Phlebography (DSA) of pampiniform plexus. Contrast media injected by microcatheter.

before changing the patient's position, a single image was taken using the angiographic camera (Figure 3). Text, a sterile gauze pad compressed by a small sand bag was left in the groin for 3 hours. Patients remained in supine position for 4 hours. After 6 hours, patients were discharged with recommendations to avoid increases in abdominal pressure and adherence to light diet for 7 days. Follow-up ultrasound scan was performed after 3 months by the same method as before the procedure.

Results

Embolization of spermatic vein and its additional branches was achieved in all 17 procedures. The administered quantity of 1:1 mixture of NBCA and lipiodol ranged from 0.8 mL to 1.5 mL depending on the number of additional branches or vein trunk doubling. At the initial stage of administration, lower stability and higher tendency of the glue to move in reciprocal and central direction was observed. Also at the final state of administration, upon aspiration of the glue and the removal of the microcatheter from the spermatic vein, higher instability of the glue was observed in central direction. Pain discomfort was experienced upon polymerization by all patients and reported to be of moderate intensity. The total time of the procedure ranged from 32 to 61 minutes depending on anatomical condition and patient's cooperation. Glue particles were found in the lumen of the 4 Fr Cobra catheter in 14 out

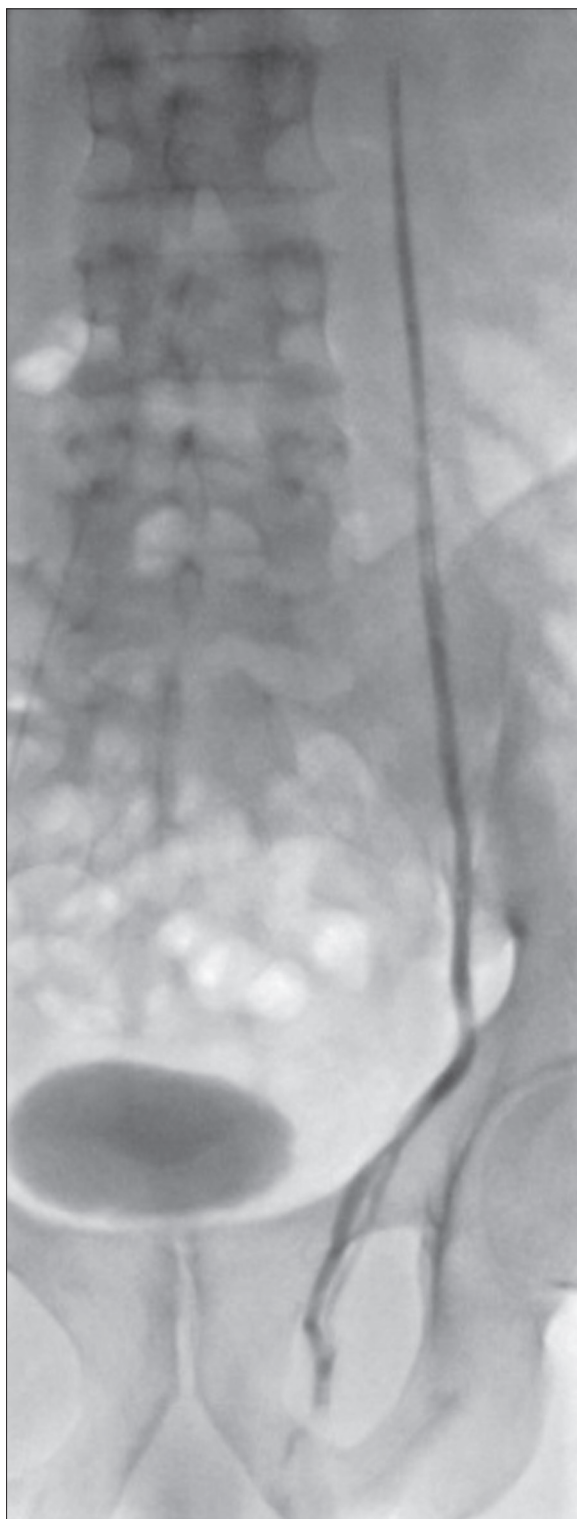

Figure 3. Final control, single shot of glue in occluded vessels.

of 17 patients, preventing save follow-up phlebographic examination. Single images taken after the compression of the puncture site revealed no migration of glue within the spermatic vein compared to the images obtained immediately after glue injection. No periprocedural complications were reported. Three patients reported discrete pain in the region of a palpable, elongated thickening within up to 72

hours after the procedure. For the next 2–3 days, patients contacted the study site by phone, describing in details the feeling of discomfort being resolved.

All patients reported for a follow-up ultrasound scan three months after embolization. Reduction in the diameter of pathological veins was observed in ultrasound images of all patients. No spermatic vein reflux of ≥ 1.5 seconds was observed upon Valsalva maneuver in standing position.

The cost of the procedure in the Department of Radiological Procedures Imaging Diagnostics in the Independent Public Clinical Hospital No. 1 in Lublin is estimated at PLN 3,500, and consists of the following items: PLN 1,000 – average lab/procedure costs (depreciation of angiographic equipment, salaries, facilities, general hospital costs, etc); PLN 350 – basic angiographic kit (lining, needle, 4 Fr port, 4 Fr catheter, hydrophilic guide wire, gauze pads, etc); PLN 50 – contrast agent (50 mL), PLN 1,400 – hydrophilic catheter; PLN 500 – NBCA glue + lipiodol; PLN 200 – other costs. The requirement to obtain Voivodship Consultant's consent for the targeted purchase of glue components is of some inconvenience. No periprocedural complications were observed in the study material.

Discussion

Endovascular embolization of varicoceles using NBCA glue is an efficient and safe treatment method.

The 100% efficacy of the procedure is impressive; however, the condition and prerequisite to achieve such efficacy is a very precise phlebographic diagnostics. Being aware of all branches of the spermatic vein, we are able to embolize all of them, preventing collateral circulation and recurrence of the condition. Since the 100% efficacy of the method is also reported by other authors, one may conclude that provided appropriate training of the operators, the method is very reliable [17,18]. However, some doubts may be raised by the lack of follow-up phlebography in method description. The described methodology is based on many years of experience and has been used since 2007. After injection of the glue and upon detecting glue particles within the microcatheter and the 4 Fr Cobra catheter, a new 4 Fr Cobra catheter was introduced into the proximal, patent segment of the spermatic vein, since the follow-up phlebography performed from the renal vein was ineffective. Due to anatomical configuration of inferior caval vein, renal vein and the spermatic vein junction, the Cobra catheter may slip out of the spermatic vein, while deeper placement is impossible due to the impossibility of deeper introduction of the guide wire. The aforementioned reasons led to elongated procedure times and, in two cases, to non-significant dissection of vein wall and extravascular injection of the contrast medium. In one case, this was due to an overly strong injection of the contrast agent into the patent spermatic vein over a short segment; in the other, the Cobra catheter sprang back to another position, with the catheter tip damaging the vascular wall. Combined with the observed lack of glue migration, the aforementioned events led to a change in treatment efficacy follow-up methods. The analysis of our study material confirmed the lack of evidence for relocation of embolization materials in

the spermatic vein. N-butyl cyanoacrylate glue has been used for many years in neuroradiological procedures. Limitations of this embolization agent are also known, consisting mainly of limited control of the injected glue, irreversibility of instantaneous polymerization and long learning curves. However, embolization of varicoceles is markedly different from embolization of vascular malformations within the brain. The major difference consists in different blood flow characteristics. In cerebrovascular malformations, immanently characterized by numerous fistulas, high arteriovenous flow is predominant, making the glue difficult to control. The blood flow within the spermatic vein in Trendelenburg position and during Valsalva maneuver is nearly stagnant, allowing for easy control of polymerization of the "dense" 1:1 mixture of NBCA and lipiodol. Of course, the method is not recommended for individuals not experienced in handling NBCA glue; compared to neuroradiology procedures, however, hemodynamic conditions of varicocele embolization are very favorable. No periprocedural complications were observed in the study material.

Compared to embolization procedures using liquid substances administered as foams, the use of NBCA glue allows to precisely define the scope of embolized veins. The

administered glue is well visible and can be visualized on a single image. The comparison of glue location with the preliminary phlebography allows precise determination of the number of embolized vessels. Upon administration of foams, final phlebography illustrates the embolization of the proximal segment of the spermatic vein. Combination of the foam and the spiral methods is an attempt to improve the efficacy of the procedure; the only results, however, are higher treatment costs and higher satisfaction of the operator, as the procedure does not improve the control of the embolized vessel region.

Earlier demonstrative reports suggested that NBCA should be used mainly upon recurrence of varicoceles after surgical treatment [12]. However, as the number of physicians trained at handling microcatheters and NBCA glue, the method described in this article has a growing number of supporters who use it as the method of choice in all patients suffering of varicoceles.

Conclusions

Endovascular embolization of varicoceles using NBCA glue is exceptionally effective (100%) and safe.

References:

- Baazeem A, Belzile E, Ciampi A et al: Varicocele and male factor infertility treatment: a new meta-analysis and review of the role of varicocele repair. *Eur Urol*, 2011; 60(4): 796-808
- Jarow JP, Coburn M, Sigman M: Incidence of varicoceles in men with primary and secondary infertility. *Urology*, 1996; 47(1): 73-76
- Belloli G, D'Agostino S, Pesce C et al: Varicocele in childhood and adolescence and other testicular anomalies: an epidemiological study. *Pediatr Med Chir*, 1993; 15(2): 159-62
- Oster J: Varicocele in children and adolescents. An investigation of the incidence among Danish school children. *Scand J Urol Nephrol*, 1971; 5(1): 27-32
- Braedel HU, Steffens J, Ziegler M et al: A possible ontogenic etiology for idiopathic left varicocele. *J Urol*, 1994; 151(1): 62-66
- Mali WP, Oei HY, Arndt JW et al: Hemodynamics of the varicocele. Part II. Correlation among the results of renocaval pressure measurements, varicocele scintigraphy and phlebography. *J Urol*, 1986; 135(3): 489-93
- Agarwal A, Sharma RK, Desai NR et al: Role of oxidative stress in pathogenesis of varicocele and infertility. *Urology*, 2009; 73(3): 461-69
- Sakamoto H, Saito K, Shichizyo T et al: Color Doppler ultrasonography as a routine clinical examination in male infertility. *Int J Urol*, 2006; 13: 1073-8
- Dewire DM, Thomas AJJ, Falk RM et al: Clinical outcome and cost comparison of percutaneous embolization and surgical ligation of varicocele. *J Androl*, 1994; 15: 38S-42S
- Reyes BL, Trerotola SO, Venbrux AC et al: Percutaneous embolotherapy of adolescent varicocele: results and long-term follow-up. *J Vasc Interv Radiol*, 1994; 5(1): 131-34
- Klamut M, Szczerbo-Trojanowska M: Embolizacja żyły jądrowej w żyłkach powrózka nasiennego. *Radiologia t. III, PZWL*; 1993: 424-25 [in Polish]
- Kunnen M: New techniques for embolisation of the internal spermatic vein: intravenous tissue adhesive. *Rofo*, 1980; 133(6): 625-29
- Brothers MF, Kaufmann JC, Fox AJ et al: n-Butyl 2-cyanoacrylate-substitute for IBCA in interventional neuroradiology: histopathologic and polymerization time studies. *AJNR Am J Neuroradiol*, 1989; 10(4): 777-86
- Sze DY, Kao JS, Frisoli JK et al: Persistent and recurrent postsurgical varicoceles: venographic anatomy and treatment with N-butyl cyanoacrylate embolization. *J Vasc Interv Radiol*, 2008; 9(4): 539-45
- Dubin L, Amelar RD: Varicocele size and results of varicocelectomy in selected subfertile men with varicocele. *Fertil Steril*, 1970; 21(8): 606-9
- Bahren W, Lenz M, Porst H et al: Side effects, complications and contraindications for percutaneous sclerotherapy of the internal spermatic vein in the treatment of idiopathic varicocele. *Rofo*, 1983; 138(2): 172-79
- Heye S, Maleux G, Wilms G: Pain experience during internal spermatic vein embolization for varicocele: comparison of two cyanoacrylate glues. *Eur Radiol*, 2006; 16(1): 132-36
- Vanlangenhove P, De Keukeleire K, Everaert K et al: Efficacy and Safety of Two Different n-Butyl-2-Cyanoacrylates for the Embolization of Varicoceles: A Prospective, Randomized, Blinded Study. *Cardiovasc Intervent Radiol*, 2012; 35: 598-606