

Three-Dimensional Cone-Beam Computed Tomography Assessment of Additional Canals of Permanent first Molars: A Pinocchio for Successful Root Canal Treatment

Rayan Alswilem¹, Anas Abouonq¹, Azhar Iqbal², Sarah Sulaiman Alajlan³, Mohammad Khursheed Alam⁴

¹College of Dentistry, Al Jouf University, Departments of
²Restorative Dentistry and
³Orthodontic, College of
Dentistry, Al Jouf University,
Sakaka, ⁴College of Dentistry,
University of Ha'il, Ha'il,
Saudi Arabia

Received : 02-01-18.

Accepted : 25-03-18.

Published : 17-05-18.

INTRODUCTION

Root and root canal morphology plays the key role of successful outcome of root canal treatment therapy. During root canal therapy, canals could be left untreated if clinicians do not detect properly the presence of additional root canal in the tooth.^[1] Therefore, clinicians need to be always conscious of the normal as well as abnormal anatomical or structural disparities in root canal morphology. Lack of consideration of the root canal morphology may result in unsuccessful treatment. Maxillary first molar is the largest tooth in size having the most complexity of root canal morphology. Thus, the failure rate of endodontic treatment is also high in the maxillary first molar tooth.^[2] Commonly acceptable

anatomical form of the permanent maxillary first molar has three roots with four canals and two roots with three canals for the permanent mandibular first molar.^[3] However, the variation of number of roots and the number of canals in a root is also frequent. Moreover, the root canal morphology is quite complex and highly variable.^[4] These variations may occur due to ethnic background, age, and gender of the population.^[5,6]

Address for correspondence: Dr. Rayan Alswilem,
College of Dentistry, Al Jouf, University,
Sakaka, Saudi Arabia.
E-mail: rayan.alswilem@jodent.org

This is an open access journal, and articles are distributed under the terms of the Creative Commons Attribution-NonCommercial-ShareAlike 4.0 License, which allows others to remix, tweak, and build upon the work non-commercially, as long as appropriate credit is given and the new creations are licensed under the identical terms.

For reprints contact: reprints@medknow.com

How to cite this article: Alswilem R, Abouonq A, Iqbal A, Alajlan SS, Alam MK. Three-dimensional cone-beam computed tomography assessment of additional canals of permanent first molars: A pinocchio for successful root canal treatment. J Int Soc Prevent Communit Dent 2018;8:259-63.

ABSTRACT

Aims and Objectives: The objective of this study was to estimate the prevalence of additional canals in the first permanent molars of the participants of Saudi, Jordanian, and Egyptian population using cone-beam computed tomography (CBCT).

Materials and Methods: In this retrospective study, CBCT scans of 139 patients were collected who were implant treated at College of Dentistry, Al Jouf University, Saudi Arabia, from October 2016 to March 2017. The images were analyzed using On-Demand 3D software. A pilot study was done to prevent intra-examiner error, and two calibrated examiners independently assessed 20% randomly selected CBCT images. Gender and racial disparities were analyzed using Chi-square test. $P < 0.05$ was considered statistically significant.

Results: The prevalence of additional canal in U16, U26, L36, and L46 of Saudi population was 41.80%, 41.80%, 17.30%, and 19.10%, respectively. In Jordanian participants, no additional canals were found in both mandibular first molars whereas only one participant from Egypt had additional canal in both mandibular first molars. Moreover, significant associations were found between L36 ($P = 0.015$) and L46 ($P = 0.008$) with gender.

Conclusion: In conclusion, the results of this study provide the information about the prevalence of additional canal in the first permanent molars, which will help and guide the clinicians while performing root canal treatment and also may help them increase the success rate of root canal treatment of the first permanent molars.

KEYWORDS: Additional root canal, cone-beam computed tomography, Egypt, Jordan, Saudi

Access this article online

Quick Response Code:



Website: www.jispcd.org

DOI: 10.4103/jispcd.JISPCD_3_18

In dentistry, radiographs are one of the most important and reliable diagnostic apparatus of observation and determination of the oral structures. Especially in the field of endodontics, most of the diagnosis and treatment procedures are dependent on radiographic findings.^[7] There are different types of radiographs such as conventional radiographs and digital radiographs and more recently computed tomography (CT), spiral CT, micro-CT, and cone-beam CT (CBCT) techniques by which we can detect and analyze the root canal morphology.^[8]

Tachibana and Matsumoto first introduced the use of CBCT in endodontic field in 1990.^[9] CBCT is a cone-shaped beam of radiation and produces a three-dimensional (3D) image of the object which gives a clear idea about the object to the clinician. CBCT revealed itself as a reliable and efficient method to determine the root morphology compared with the gold standard of physical sectioning of the specimen.^[9-11]

In recent years, many studies have been done to determine the prevalence of additional canal in molar teeth in different populations worldwide. However, most of these studies indicate the prevalence of additional canal of one tooth.^[2,7,8,12-16] Kim *et al.*^[17] observed 976 participants of the mandibular first molar and found that 50.36% of participants had additional canals. Recently, Zhang *et al.*^[2] sectioned 1008 maxillary first molars and reported that 85.4% of the maxillary first molars had additional canal in the mesiobuccal root. A few studies have been conducted alike our study among Taiwanese and Chile people in very recently.^[18,19] However, no study has been done three population together. We have, therefore, given particular attention to evaluating additional canals in mesiobuccal root (MB2) of all four permanent first molars using CBCT. Based on this, the prime objectives of this study were to:

1. Evaluate the prevalence of MB2 of U16, U26, L36, and L46 of Saudi, Jordanian, and Egyptian populations
2. Determine the prevalence of MB2 of U16, U26, L36, and L46 between males and females
3. Present the global data and present study of MB2 of the first permanent molar tooth.

MATERIALS AND METHODS

This study was approved by the Ethics Committee of the College of Dentistry, Al Jouf University [CODS11/7/2016].

Written consent was taken from each patient before taking CBCT. In this retrospective study, we evaluated MB2 of the first molars from the CBCT

scans of 139 patients who were treated at College of Dentistry, Al Jouf University, from October 2016 to March 2017. Identification of patients was not exposed, only the information (age, sex, and race) was provided. The samples were chosen using systematic random sampling technique. Among the sample group, 92 were male and 47 were female. In regard to race, 110 patients were Saudis, 15 Jordanians, and 14 Egyptians, with the age range of 34.42 ± 12 years (mean \pm standard deviation).

SAMPLE SIZE CALCULATION

To study the prevalence of MB2 canal using CBCT,

$$n = (Z/\Delta)^2 \times P(1 - P)$$

where $Z = 1.96$ (level of significance = 0.05); absolute precision $\Delta = 0.10$ (10%); anticipated population proportion $P = 0.36$.

If the absolute precision is 10%, the sample size required is 139.

INCLUSION CRITERIA

1. Age between 20 and 65 years old
2. Root formation has been completed.

EXCLUSION CRITERIA

1. Metallic restoration
2. Intra-radicular post or endodontic filling
3. Rehabilitated using fixed prosthesis
4. Canal calcification, evidence of radectomy, or periapical surgery
5. Maxillary molars with developmental anomalies.

THREE-DIMENSIONAL ASSESSMENT OF MB2 IN FIRST MOLARS

The carefully chosen 139 images were analyzed using On-Demand 3D software [Figure 1].

STATISTICAL ANALYSIS

Data were statistically analyzed using IBM Statistical Package for the Social Science (SPSS), Version 22.0 (SPSS, Chicago, IL, USA). Gender disparities and racial disparities were analyzed using Chi-square test. $P < 0.05$ was considered statistically significant.

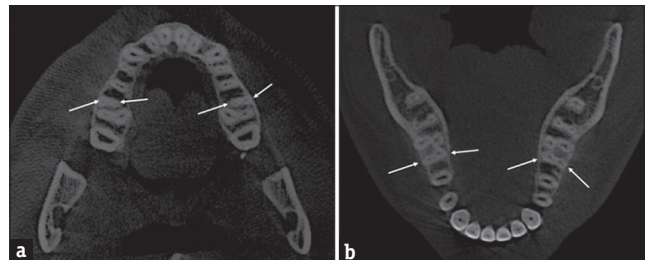


Figure 1: Three-dimensional cone-beam computed tomography showing (a) extra canal in the upper molars and (b) extra canal in the lower molars

A pilot study was done to prevent intra-examiner error. Randomly selected 20% CBCT images were evaluated by two researchers, 2 weeks after the initial survey to determine the reliability of diagnosis of MB2. Kappa statistics were used to determine intra- and inter-examiner agreements. There was 100% intra- and inter-examiner agreement between the investigators.

RESULTS

ERROR OF THE STUDY

Intra-class correlation coefficients were performed to assess the reliability of the measurements, and the coefficients of reliability of the measurements were between 0.91 and 0.98.

DISTRIBUTION OF MB2 IN SAUDI POPULATION

Table 1 shows the distribution of MB2 in the maxillary first permanent molar in Saudi population. The frequency of presence of U16, U26, L36, and L46 in participants was 41.80%, 41.80%, 17.30%, and 19.10%, respectively.

DISTRIBUTION OF MB2 IN JORDANIAN POPULATION

In Jordanian population, 33.30% of participants have MB2 in U16 and U26, whereas no MB2 was found in L36 and L46 [Table 2].

DISTRIBUTION OF MB2 IN EGYPTIAN POPULATION

Table 3 shows the distribution of MB2 in the maxillary first permanent molar in Egyptian population. The frequency of MB2 of U16 was found in 35.70% of participants. On the other hand, 92.90% of participants had no MB2 in U26, L36, and L46. Only one participant (7.10%) had MB2 in each tooth of U26, L36, and L46.

No significant associations were found among races in all molars.

DISTRIBUTION MB2 BETWEEN MALES AND FEMALES

Figure 2 shows the distribution of MB2 in the maxillary first permanent molar according to gender. Significant associations were found between L36 ($P = 0.015$) and L46 ($P = 0.008$) between males and females. However, there was no significant association found between upper first molars.

DISCUSSION

In this study, we analyzed CBCT images which is one of the most recent radiographic methods by which we can procure 3D images of an object with a relatively lower dose of radiation. We evaluated the prevalence of MB2 of U16, U26, L36, and L46 in this study. One hundred and thirty-nine CBCT images were taken from the archive of College of Dentistry, Al Jouf University. Among them,

Table 1: Distribution of additional canal in the maxillary and mandibular first permanent molar in Saudi population

Number of tooth	Present, n (%)	Absent, n (%)
U16	46 (41.80)	64 (58.20)
U26	46 (41.80)	64 (58.20)
L36	19 (17.30)	91 (82.70)
L46	21 (19.10)	89 (80.90)

U16=Upper right first molar, U26=Upper left first molar, L36=Lower left first molar, L46=Lower right first molar, n=Number of participants

Table 2: Distribution of additional canal in the maxillary and mandibular first permanent molar in Jordanian population

Number of tooth	Present, n (%)	Absent, n (%)
U16	5 (33.30)	10 (66.70)
U26	5 (33.30)	10 (66.70)
L36	0 (0.00)	15 (100)
L46	0 (0.00)	15 (100)

U16=Upper right first molar, U26=Upper left first molar, L36=Lower left first molar, L46=Lower right first molar, n=Number of participants

Table 3: Distribution of additional canal in the maxillary and mandibular first permanent molar in Egyptian population

Number of tooth	Present, n (%)	Absent, n (%)
U16	5 (35.70)	9 (64.30)
U26	1 (7.10)	13 (92.90)
L36	1 (7.10)	13 (92.90)
L46	1 (7.10)	13 (92.90)

U16=Upper right first molar, U26=Upper left first molar, L36=lower left first molar, L46=Lower right first molar, n=Number of participants

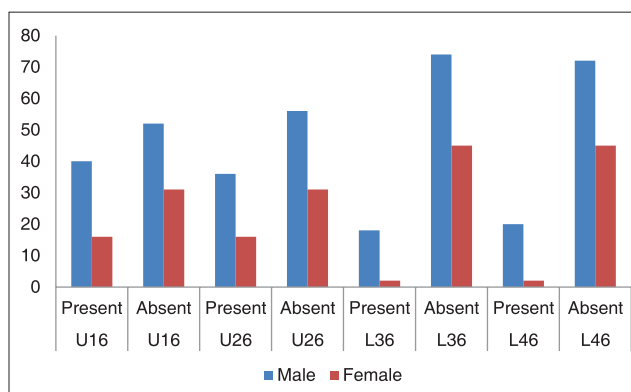


Figure 2: Distribution of additional canal in the maxillary first permanent molar according to gender

92 participants were male and 47 participants were female. The patients ranged in age from 15 to 75 years. Regarding Saudi population, 46 participants had MB2 in U16 and U26 separately. Nineteen participants had MB2 in L36, while 21 participants had MB2 in L46. However, no additional canal was found on L36 and L46 in Jordanian population and 5 participants had

MB2 in U16 and U26 separately. On the other hand, only one participant showed MB2 in U26, L36, and L46 separately and five participants showed MB2 in U16. This observation supports the hypothesis that the prevalence of MB2 in U16, U26, L36, and L46 varies in different populations.

In a study, Oboro-Onuora *et al.*^[12] analyzed the presence of additional canal in Nigerian population. Among 50 participants, they found that 34% of patients had MB2 in U16 and U26. Not only that, they also confirmed in *in vitro* study and finally concluded that the incidence of additional canal is comparatively higher in their population than the previous study. Studies performed in different populations demonstrate that the presence of additional canal is common phenomenon.

Anatomical variation in the root morphology of molar teeth is quite common in dentistry. Especially in the field of endodontics, knowledge of anatomic variations and detection of additional root canal are must for satisfactory treatment outcome because untreated root canal leads to the treatment failure. A canal may be left untreated due to the lack of proper identification of its presence. Most of the previous studies have been done by analyzing only single tooth or single jaw like only the upper molars or the lower molars. Zheng *et al.*^[8] found that more than 50% of participants had MB2 in U16 and U26 in a Chinese population study. Guo *et al.*^[13] revealed that 68.2% of participants had MB2 in U16 and U26 in

a North American population study. Similar results were reported by Peeters *et al.*^[14] in an Indonesian population. They also found that 68.8% of participants had MB2 in U16 and U26. However, our results showed that 41.8% and 33.3% of participants had MB2 in U16 and U26 in Saudi and Jordan, respectively. On the other hand, among the Egyptian participants, 35.7% showed MB2 in U16 and only 1% showed MB2 in U26. Another study done on Saudi subpopulation found that 55.6% of participants had MB2 in U16 and U26.^[15]

Regarding the mandibular first molars, in an Indian population, 36% of participants showed MB2.^[16] In our study, percentage of the presence of MB2 is comparatively low. However, the prevalence of MB2 in our study was higher on maxillary first molars than mandibular first molars among all the three populations. Similar findings were reported by Kim *et al.*^[20] Their results also revealed the higher prevalence of MB2 in the upper first molars like our study. Table 4 shows the prevalence of MB2 in different population groups. In this study, the presence of MB2 was higher in males compared to females [Figure 1]. However, significant association was only found in the mandibular first molars L36 ($P = 0.015$) and L46 ($P = 0.008$) between males and females. However, a study done in the South Korean population reported no significant association in the mandibular first molars between males and females.^[20] Similar findings also reported by Zhang *et al.*^[2] On the

Table 4: Global prevalence of additional canal in different population groups

Author	Population	Method used	Tooth	Outcome
Chen <i>et al.</i> , 2009 ^[7]	Taiwan Chinese	Clearing	L36, L46	20% of participants had additional canal
Zheng <i>et al.</i> , 2010 ^[8]	Chinese	CBCT	U16, U26	Additional canals are detected 52.24% in MB, 1.12% in DB, and 1.76% in palatal root
Oboro-Onuora <i>et al.</i> , 2012 ^[12]	Nigerian	Dental loupes and gentle troughing for <i>in vivo</i> study Impregnation with a dye and magnifying glass for <i>in vitro</i> study	U16, U26	34.0% of participants had additional canal <i>in vivo</i> study Sectioning at the cemento-enamel junction revealed that 5.7% and 1.9% of the MB and palatal roots had additional canals. Sectioning at the furcation and middle of the MB, DB, and palatal roots revealed that 71.1% and 75.5% of the MB roots, respectively, had additional canals
Guo <i>et al.</i> , 2014 ^[13]	North American	CBCT	U16, U26	Additional canals are detected 68.2%
Peeters <i>et al.</i> , 2011 ^[14]	Indonesian	Clearing	U16, U26	Additional canals are detected 68.5%
Al-Shehri <i>et al.</i> , 2017 ^[15]	Saudi	CBCT	U16, U26	55.6% of participants had additional canal
Chourasia <i>et al.</i> , 2012 ^[16]	Indian	Clearing	L36, L46	36% of participants had additional canal
Kim <i>et al.</i> , 2013 ^[17]	South Korean	CBCT	U16, U26, L36, L46	56% and 42.7% of participants had additional canal on U16, U26, L36, and L46, respectively
Hasan and Raza Khan, 2014 ^[21]	Pakistani	Magnification loupes (×3.5)	U16, U26	50.9% of participants had additional canal
Silva <i>et al.</i> , 2014 ^[22]	Brazilian	CBCT	U16, U26	42.63% of participants had additional canal
Lee <i>et al.</i> , 2011 ^[23]	Korean	CBCT	U16, U26	71.8% of participants had additional canal

U16=Upper right first molar, U26=Upper left first molar, L36=Lower left first molar, L46=Lower right first molar, CBCT=Cone-beam computed tomography, MB=Mesiobuccal, DB=Distobuccal

other hand, Hasan and Raza Khan^[21] found the difference between males and females; the presence of MB2 was higher in males compare to females in Pakistani population.

In a prospective study, larger sample size would deliver better depth to the current hypothesis and results which might provide clinicians a better understanding about the presence of additional canal in the first molar teeth and on root canal treatment of these teeth. More longitudinal studies including participants from several institutions are also recommended to issue standardized guidelines.

CONCLUSIONS

The present results showed that

- The prevalence of MB2 in U16, U26, L36, and L46 of Saudi population is 41.80%, 41.80%, 17.30%, and 19.10%, respectively
- The prevalence of MB2 of U16, U26, L36, and L46 of Jordanian population is 33.30%, 33.30%, 0%, and 0%, respectively
- The prevalence of MB2 of U16, U26, L36, and L46 of Egyptian population is 35.70%, 7.10%, 7.10%, and 7.10%, respectively
- Significant associations were found between L36 ($P = 0.015$) and L46 ($P = 0.008$) between males and females.

FINANCIAL SUPPORT AND SPONSORSHIP

Nil.

CONFLICTS OF INTEREST

There are no conflicts of interest.

REFERENCES

1. Slowey RR. Radiographic aids in the detection of extra root canals. *Oral Surg Oral Med Oral Pathol* 1974;37:762-72.
2. Zhang Y, Xu H, Wang D, Gu Y, Wang J, Tu S, *et al.* Assessment of the second mesiobuccal root canal in maxillary first molars: A cone-beam computed tomographic study. *J Endod* 2017;43:1990-6.
3. Walton R, Torabinejad M. *Principles and Practice of Endodontics*. 2nd ed. Philadelphia: W.B Saunders Co.; 1996.
4. Barbizam JV, Ribeiro RG, Filho MT. Unusual anatomy of permanent maxillary molars. *Int Endod J* 2004;30:668-71.
5. Weine FS, Hayami S, Hata G, Toda T. Canal configuration of the mesiobuccal root of the maxillary first molar of a Japanese sub-population. *Int Endod J* 1999;32:79-87.
6. Ozcan G, Sekerci AE, Cantekin K, Aydinbelge M, Dogan S. Evaluation of root canal morphology of human primary molars by using CBCT and comprehensive review of the literature. *Acta Odontol Scand* 2016;74:250-8.
7. Chen G, Yao H, Tong C. Investigation of the root canal configuration of mandibular first molars in a Taiwan Chinese population. *Int Endod J* 2009;42:1044-9.
8. Zheng QH, Wang Y, Zhou XD, Wang Q, Zheng GN, Huang DM, *et al.* A cone-beam computed tomography study of maxillary first permanent molar root and canal morphology in a Chinese population. *J Endod* 2010;36:1480-4.
9. Tachibana H, Matsumoto K. Applicability of X-ray computerized tomography in endodontics. *Endod Dent Traumatol* 1990;6:16-20.
10. Kiarudi AH, Eghbal MJ, Safi Y, Aghdasi MM, Fazlyab M. The applications of cone-beam computed tomography in endodontics: A review of literature. *Iran Endod J* 2015;10:16-25.
11. Aktan AM, Yildirim C, Culha E, Demir E, Ertugrul Ciftci M. Detection of second mesiobuccal canals in maxillary first molars using a new angle of cone beam computed tomography. *Iran J Radiol* 2016;13:e31155.
12. Oboro-Onuora HO, Onuora OI, Sede MA. Determination of additional canals in maxillary first permanent molars in adult Nigerian population: Using *in vivo* and *in vitro* technique. *Eur J Gen Dent* 2012;1:166-9.
13. Guo J, Vahidnia A, Sedghizadeh P, Enciso R. Evaluation of root and canal morphology of maxillary permanent first molars in a North American population by cone-beam computed tomography. *J Endod* 2014;40:635-9.
14. Peeters HH, Suardita K, Setijanto D. Prevalence of a second canal in the mesiobuccal root of permanent maxillary first molars from an Indonesian population. *J Oral Sci* 2011;53:489-94.
15. Al-Shehri S, Al-Nazhan S, Shoukry S, Al-Shwaimi E, Al-Sadhan R, Al-Shemmary B. Root and canal configuration of the maxillary first molar in a Saudi subpopulation: A cone-beam computed tomography study. *Saudi Endod J* 2017;7:69-76.
16. Chourasia HR, Meshram GK, Warhadpande M, Dakshindas D. Root canal morphology of mandibular first permanent molars in an Indian population. *Int J Dent* 2012;2012:745152.
17. Kim SY, Kim BS, Woo J, Kim Y. Morphology of mandibular first molars analyzed by cone-beam computed tomography in a Korean population: Variations in the number of roots and canals. *J Endod* 2013;39:1516-21.
18. Su CC, Wu YC, Chung MP, Huang RY, Cheng WC, Tsai YW, *et al.* Geometric features of second mesiobuccal canal in permanent maxillary first molars: A cone-beam computed tomography study. *J Dent Sci* 2017;12:241-8.
19. Betancourt P, Navarro P, Muñoz G, Fuentes R. Prevalence and location of the secondary mesiobuccal canal in 1,100 maxillary molars using cone beam computed tomography. *BMC Med Imaging* 2016;16:66.
20. Kim S, Choi MR, Yoo JJ. Concurrent relationship between additional canals of mandibular first molars and maxillary first molars using cone-beam computed tomography. *Oral Radiol* 2013;29:146-50.
21. Hasan M, Raza Khan F. Determination of frequency of the second mesiobuccal canal in the permanent maxillary first molar teeth with magnification loupes (×3.5). *Int J Biomed Sci* 2014;10:201-7.
22. Silva EJ, Nejaim Y, Silva AI, Haiter-Neto F, Zaia AA, Cohenca N, *et al.* Evaluation of root canal configuration of maxillary molars in a Brazilian population using cone-beam computed tomographic imaging: An *in vivo* study. *J Endod* 2014;40:173-6.
23. Lee JH, Kim KD, Lee JK, Park W, Jeong JS, Lee Y, *et al.* Mesiobuccal root canal anatomy of Korean maxillary first and second molars by cone-beam computed tomography. *Oral Surg Oral Med Oral Pathol Oral Radiol Endod* 2011;111:785-91.