

CASE REPORT

Case report: false positive elevated serum-galactomannan levels after autologous hematopoietic stem cell transplantation caused by oral nutritional supplements

Tobias Rachow¹, Sebastian Dornaus¹, Herbert G. Sayer¹, Beate Hermann², Andreas Hochhaus^{1,3} & Marie von Lilienfeld-Toal^{1,3,4}

¹Klinik für Innere Medizin II, Universitätsklinikum Jena, Hämatologie und Internistische Onkologie, Jena, Germany

²Institut für Medizinische Mikrobiologie, Universitätsklinikum Jena, Jena, Germany

³Centre for Sepsis Control and Care, Universitätsklinikum Jena, Jena, Germany

⁴Leibniz-Institut für Naturstoff-Forschung und Infektionsbiologie, Hans-Knöll-Institut, Jena, Germany

Correspondence

Tobias Rachow, Klinik für Innere Medizin II, Universitätsklinikum Jena, Hämatologie und Internistische Onkologie, Erlanger Allee 101, Jena, 07747, Germany.
Tel: +4936419324201;
Fax: +4936419324202;
E-mail: tobias.rachow@med.uni-jena.de

Funding Information

No sources of funding were declared for this study.

Received: 16 June 2015; Revised: 4 January 2016; Accepted: 28 January 2016

Clinical Case Reports 2016; 4(5): 505–508

doi: 10.1002/ccr3.516

Introduction

Immunocompromised patients are at high risk for invasive fungal infections (IFI) like invasive pulmonary aspergillosis. Detection of galactomannan (GM) levels in the serum has been found to be a valid surrogate parameter for early diagnosis of IFI. Nevertheless, several clinical circumstances may influence serum GM levels. Here, we present a 68-year old male patient with an angioimmunoblastic T cell lymphoma with aberrant expression of CD20 who was admitted for high-dose chemotherapy with consecutive autologous stem cell transplantation. Initial laboratory tests did not show any significant abnormalities. High-dose chemotherapy containing rituximab, thiotepa, etoposide, cytarabine, and melphalan (R-TEAM) was administered and autologous stem cells were retransfused without any problems. During the neutropenic phase, the patient developed severe mucositis, presenting as persistent diarrhea (CTC-grade 3) and diminished appetite. He consumed sev-

Key Clinical Message

Positive galactomannan tests in patients who underwent chemotherapy without any clinical signs of a fungal infection should lead the clinician to consideration of a false-positive test result. Oral nutritional supplements may be a cause, especially in the case of concomitant disturbance of the gastrointestinal mucosal barrier because of mucositis.

Keywords

Autologous stem cell transplantation, enteral nutrition, galactomannan, invasive fungal infection.

eral energy drinks per day as nutritional supplements. Routinely performed serum tests showed a GM level of 1.5 (norm < 0.5). CT scans showed no signs of IFI. A calculated antifungal therapy was initiated. However, during the course of neutropenia and after engraftment the GM levels increased without any signs of IFI. Testing for GM in the energy drinks revealed a high positive result for GM. Hence, the patient was advised to stop consuming these drinks and the GM level decreased and normalized eventually. The same drink given to individuals without mucositis did not lead to an increase in GM levels. We thus assume a disturbed intestinal mucosal barrier because of the treatment-induced diarrhea as a cause of false positive GM results. This case report indicates a potential source of false positive results for serum GM tests. Energy drinks can be an important support in the diet of hematologic patients. A disturbed intestinal mucosal barrier may lead to the transfer of ingested sugar-molecules into the patients' blood and thereby affect serum GM levels.

Immunocompromised patients are at risk for opportunistic infections like invasive fungal infections (IFI), invasive aspergillosis (IA), or invasive candidiasis (IC). Furthermore, underlying hematologic malignancies or intensive chemotherapy regimens often make invasive diagnostic procedures impossible [1]. Fungal cell wall components like aspergillus galactomannan (GM) or candida mannan (CM) can be found in the patients' blood in the case of IFI [2–5]. Hence, they have been found to be a good surrogate parameter for early diagnosis of IFI and immediate preemptive antifungal therapy. Current guidelines recommend performing serum-galactomannan tests at least twice a week in patients at risk of invasive fungal infections [6]. In contrast, several studies suggest potential causes for false-positive GM tests. Enteral supplemental nutrition might be a source for positive test results in the condition of allogeneic stem cell transplantation and intestinal graft versus host disease [7–10]. Our case suggests a potential enteral cause of false-positive serum-GM tests in the context of autologous stem cell transplantation and therapy-induced mucositis.

Case Presentation

A 69-year old male patient was electively admitted to our hospital for high-dose chemotherapy and autologous stem cell transplantation. On admission, the patient reported to be in his usual health. No clinical signs of infection (like fever, coughing, sneezing, or dysuria) had occurred in the weeks prior to admission. Nine months earlier a rare variant of an angioimmunoblastic T-cell non-Hodgkin lymphoma with aberrant expression of CD20-stage IVB had been diagnosed. After diagnosis, an immunochemotherapy with six cycles of the R-CHOP-protocol (rituximab, cyclophosphamide, doxorubicine, vincristin, prednisolone) and two consolidating cycles of rituximab had been administered. The first cycle of chemotherapy had been complicated by acute renal failure due to tumor lysis, a central venous line infection and a stomatitis due to reactivation of *herpes simplex virus*. Subsequent cycles could be administered without any complication. A restaging examination after six cycles of chemotherapy showed a good partial remission, thus, consolidation with high-dose chemotherapy and autologous stem cell transplantation was planned. Since diagnosis, there had never been any suspicion of invasive fungal infections. Routine laboratory testing showed no noticeable problems except from slightly elevated serum-creatinine levels and the diagnostic work-up was unremarkable apart from arterial hypertension. An exercise stress test showed no electrocardiographic signs of a relevant ischemic heart disease.

After excluding potential contraindications, we administered a myeloablative chemotherapy following the R-TEAM-protocol (rituximab, thiotepa, etoposide, cytar-

bine, and melphalan) [11]. On the day of stem cell retransfusion, the patient developed severe diarrhea (CTC-grade 3) most probably caused by chemotherapy [12]. Tests for infectious enteritis showed no positive result. Thus, the diarrhea was assumed to be chemotherapy induced and hypercaloric drinks were offered to the patient because of weight loss and reduced appetite. The patient consumed one to three of these drinks per day. On the day of stem cell retransfusion, elevated body temperatures could be measured and fever occurred from day +2 until day +9 after stem cell transplantation, and was accompanied by an increase in the C-reactive protein (the clinical course after the stem cell transplantation is depicted in Fig. 1). Blood cultures indicated a central line infection with *Staphylococcus epidermidis*, thus, antibiotic treatment with teicoplanin was initiated. Also, stool cultures showed the presence of multiresistant *E. coli* and meropenem was added. Repeatedly performed routine-tests for serum-galactomannan showed a marked elevation after the period of neutropenia, after resolution of fever and despite decreasing levels of C-reactive protein (see Fig. 1), whereas serum candida-antigen tests stayed in the normal range. GM levels were tested using the Platelia™ Aspergillus Ag kit (Bio-Rad) and candida-antigen levels using the Platelia™ Candida Ag plus kit (Bio-Rad Laboratories GmbH, Munich, Germany). Because of a suspected invasive aspergillosis, a calculated antifungal therapy with voriconazole was initiated although CT-imaging showed no signs of invasive pulmonary fungal infection. No adequate explanation could be found with respect to the laboratory results. For further investigation of the inconsistent findings regarding the positive serum aspergillus-GM tests and the missing clinical evidence for an invasive aspergillosis, the patients' environment was examined. The consumed hypercaloric drinks were tested with the same diagnostic fungal tests as for the patients' blood samples. Both, aspergillus-GM and candida-antigen could be detected in high levels (5.35 and 700 pg/mL, respectively). In order to test for accuracy, two healthy volunteers consumed the same drinks and blood samples at baseline and 4 h after the ingestion of the drink were tested for aspergillus-GM. As expected, the tests showed negative results throughout. The patient was advised to stop the consumption of the drinks and serum-GM levels decreased (see Fig. 1). On day 30 after retransfusion of stem cells, the patient could be discharged from the hospital. Four weeks later, the patient was readmitted because of dyspnea and coughing. Serum-galactomannan levels were normal and CT-imaging still showed no signs of invasive pulmonary fungal infection. After antibiotic treatment all clinical signs of infection resolved. Regular follow-up investigations showed no relapse of the lymphoma after 12 months.

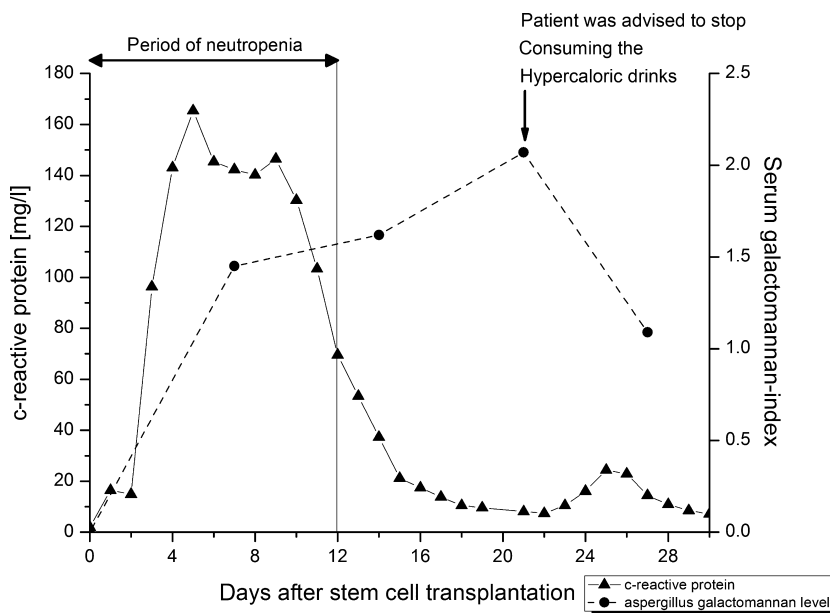


Figure 1. Trends of C-reactive protein (triangle-symbols and solid line) and serum-galactomannan (dots and broken line) after stem cell retransfusion: the C-reactive protein levels increased with fever in neutropenia and normalized after initiation of an effective antibacterial therapy; the level of serum-galactomannan increased even after neutropenic reconstitution (on day 12) and fell after advising the patient to quit consuming the hypercaloric drinks.

Discussion

Malnutrition and weight loss are frequent complications of high-dose conditioning and autologous peripheral blood stem cell transplant and supportive enteral nutrition might be beneficial [13]. In the presented case, the patient received high-caloric drinks containing galactooligosaccharides as well as gluconate, which has been reported to cause elevated galactomannan levels [14]. The consumed products were tested for aspergillus-GM and candida-antigen. The tests showed markedly positive results. The food industry uses complex sugar molecules like galactomannans for stabilizing and thickening of many products [15]. Tests for aspergillus-GM lead to positive results in many foods [16]. In this context, they might affect diagnostic procedures in case of passing over from the intestine into the bloodstream. It should also be kept in mind, that galactomannan levels in blood can be elevated due to intravenous antibiotic administration.

Occurrence of aspergillus-GM in the blood is thought to be caused by angioinvasion of growing aspergillus hyphae. The most widely used biomarker for invasive aspergillosis is an EIA-based procedure and uses a monoclonal antibody for the detection of the 1–5 galactofuranose side chain of the galactomannan molecule (Bio-Rad, Platelia™ Aspergillus Ag kit). Although positivity of the

biomarkers preceded clinical signs of IFI in several cases, a drawback is the rate of false-positive results in up to 15% [17, 18]. Therefore, repeated measurements are recommended in current guidelines.

Diarrhea is one of the most commonly occurring side effects of chemotherapy and may indicate a dysfunction in the intestinal mucosal barrier. The TEAM conditioning protocol contains melphalan, which is known to be a potential cause of severe diarrhea as a known side effect [19]. We hypothesize that the dysfunction of the intestinal mucosal barrier in the context of stem cell transplantation was the reason for the false-positive serum-galactomannan results. Several case reports about different false-positive aspergillus tests were published in the setting of allogeneic stem cell transplantation and graft-versus-host disease. To the best of our knowledge there are no reports about false-positive GM-tests in recipients of autologous stem cell transplantation due to enteral supplemental nutrition agents.

In addition, we tested the drinks and the patients' serum for candida mannan (Bio-Rad, Platelia™, Candida Ag plus). While the drink was tested positive, candida antigen could not be detected in the patient's serum. The reason for this finding remains unclear. We assume a different intestinal processing and absorption of the antigens in the context of chemotherapy-associated disturbed mucosal barrier function.

Conclusion

Diagnosis of invasive fungal infection remains a challenge for clinicians, especially in the context of stem cell transplantation. Surrogate parameters like antigen detection in the patients' serum are an essential diagnostic element. Test results should be critically interpreted in the clinical context with respect to potential causes of false-positive findings in order to prevent unnecessary antimycotic treatment. In our case, aspergillus-GM but not candida-antigen could be detected in the patients' blood, whereas both molecules could be detected in the potential source of the false-positive test results. Thus, the exact mechanisms of disturbed intestinal barrier function as a cause for false-positive findings in the context of stem cell transplantation remain unclear.

Conflict of Interest

None declared.

References

- Ostrosky-Zeichner, L. 2012. Invasive mycoses: diagnostic challenges. *Am. J. Med.* 125(1 Suppl):S14–S24.
- Maertens, J. A., R. Klont, C. Masson, K. Theunissen, W. Meersseman, K. Lagrou, et al. 2007. Optimization of the cutoff value for the Aspergillus double-sandwich enzyme immunoassay. *Clin. Infect. Dis.* 44:1329–1336.
- Arendrup, M. C., O. J. Bergmann, L. Larsson, H. V. Nielsen, J. O. Jarlov, and B. Christensson. 2010. Detection of candidaemia in patients with and without underlying haematological disease. *Clin. Microbiol. Infect.* 16:855–862.
- Ellis, M., B. Al-Ramadi, R. Bernsen, J. Kristensen, H. Alizadeh, and U. Hedstrom. 2009. Prospective evaluation of mannan and anti-mannan antibodies for diagnosis of invasive Candida infections in patients with neutropenic fever. *J. Med. Microbiol.* 58(Pt 5):606–615.
- Herbrecht, R., V. Letscher-Bru, C. Oprea, B. Lioure, J. Waller, F. Campos, et al. 2002. Aspergillus galactomannan detection in the diagnosis of invasive aspergillosis in cancer patients. *J. Clin. Oncol.* 20:1898–1906.
- Ruhnke, M., A. Bohme, D. Buchheidt, O. Cornely, K. Donhuijsen, H. Einsele, et al. 2012. Diagnosis of invasive fungal infections in hematology and oncology—guidelines from the Infectious Diseases Working Party in Haematology and Oncology of the German Society for Haematology and Oncology (AGIHO). *Ann. Oncol.* 23:823–833.
- Guigue, N., J. Menotti, and P. Ribaud. 2013. False positive galactomannan test after ice-pop ingestion. *N. Engl. J. Med.* 369:97–98.
- Ng, T. Y., M. L. Kang, B. H. Tan, and C. C. Ngan. 2014. Case report: Enteral nutritional supplement as a likely cause of false-positive galactomannan testing. *Med. Mycol. Case Rep.* 3:11–13.
- Murashige, N., M. Kami, Y. Kishi, G. Fujisaki, and R. Tanosaki. 2005. False-positive results of Aspergillus enzyme-linked immunosorbent assays for a patient with gastrointestinal graft-versus-host disease taking a nutrient containing soybean protein. *Clin. Infect. Dis.* 40:333–334.
- Millon, L., F. Grenouillet, J. Crouzet, F. Larosa, S. Loewert, A. P. Bellanger, et al. 2010. False-positive Aspergillus real-time PCR assay due to a nutritional supplement in a bone marrow transplant recipient with GVH disease. *Med. Mycol.* 48:661–664.
- Pester, F., A. Klink, S. Scholl, K. Schilling, L. Muegge, K. Höffken, et al. TEAM (Thiotepa, Etoposide, Cytarabine, Melphalan) is an effective high-dose chemotherapy consolidation regimen with autologous stem cell transplantation for patients with relapsed lymphoma in complete remission. 34th Annual Meeting of the European Group for Blood and Marrow Transplantation; 34th Annual Meeting of the European Group for Blood and Marrow Transplantation, Florence2008.
- US Department of Health and Human Services NIOH, National Cancer Institute. Common Terminology Criteria for Adverse Events (CTCAE) Version 4.02009 January 19, 2010.
- Hung, Y. C., J. Bauer, P. Horsley, M. Waterhouse, J. Bashford, and E. Isenring. 2013. Changes in nutritional status, body composition, quality of life, and physical activity levels of cancer patients undergoing autologous peripheral blood stem cell transplantation. *Support. Care Cancer* 21:1579–1586.
- Petratiene, R., V. Petraitis, J. R., III Witt, M. M. Durkin, J. D. Bacher, L. J. Wheat, et al. 2011. Galactomannan antigenemia after infusion of gluconate-containing Plasma-Lyte. *J. Clin. Microbiol.* 49:4330–4332.
- Cheng, Y., K. M. Brown, and Prud'homme, R. K. 2002. Preparation and characterization of molecular weight fractions of guar galactomannans using acid and enzymatic hydrolysis. *Int. J. Biol. Macromol.* 31:29–35.
- Ansorg, R., R. van den Boom, and P. M. Rath. 1997. Detection of Aspergillus galactomannan antigen in foods and antibiotics. *Mycoses* 40:353–357.
- Swanink, C. M., J. F. Meis, A. J. Rijs, J. P. Donnelly, and P. E. Verweij. 1997. Specificity of a sandwich enzyme-linked immunosorbent assay for detecting Aspergillus galactomannan. *J. Clin. Microbiol.* 35:257–260.
- Foy, P. C., J. A. van Burik, and D. J. Weisdorf. 2007. Galactomannan antigen enzyme-linked immunosorbent assay for diagnosis of invasive aspergillosis after hematopoietic stem cell transplantation. *Biol. Blood Marrow Transplant.* 13:440–443.
- Sharma, S. K., A. Handoo, D. Choudhary, G. Dhamija, and N. Gupta. 2013. Severe gastrointestinal mucositis following high dose melphalan therapy for multiple myeloma. *World J. Gastroenterol.* 19:784–785.