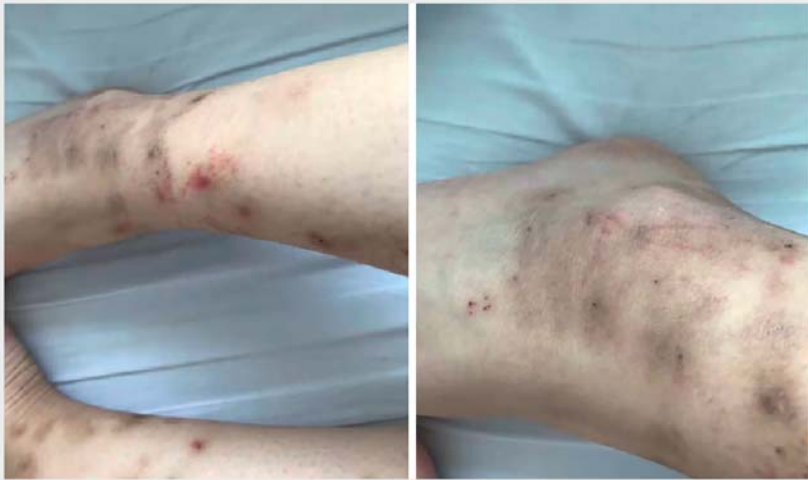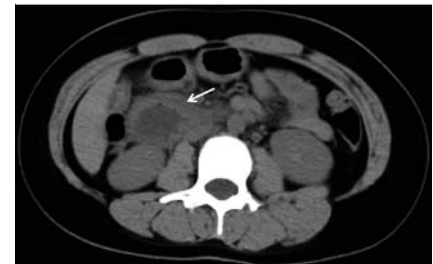


Capsule endoscopy successfully diagnosed Henoch-Schönlein Purpura in a patient with small intestine involvement

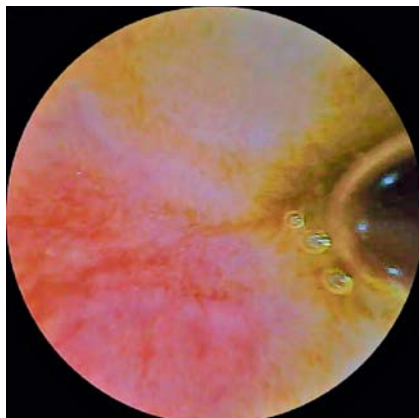
OPEN
ACCESS



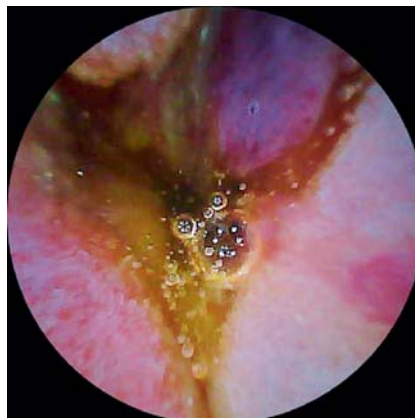► **Fig. 1** Petechiae, ecchymoses, and palpable rashes were observed in the distal part of both her lower limbs.



► **Fig. 2** Abdominal computed tomography showed diffuse thickening and edema in the horizontal part of the duodenum with dilated lumen.



► **Fig. 3** Capsule endoscopy revealed multiple areas of purpuric erythema.



► **Fig. 4** Purpuric lesions fusing with each other to form large hemorrhagic blisters in the proximal small bowel.

A young woman presented with vomiting after eating shrimp and abdominal pain predominantly around the umbilicus and upper abdomen. Physical examination revealed epigastric and periumbilical tenderness without rebound tenderness. Petechiae, ecchymoses, and palpable rashes were observed in the distal part of both lower limbs (► **Fig. 1**). Laboratory tests revealed an increase in

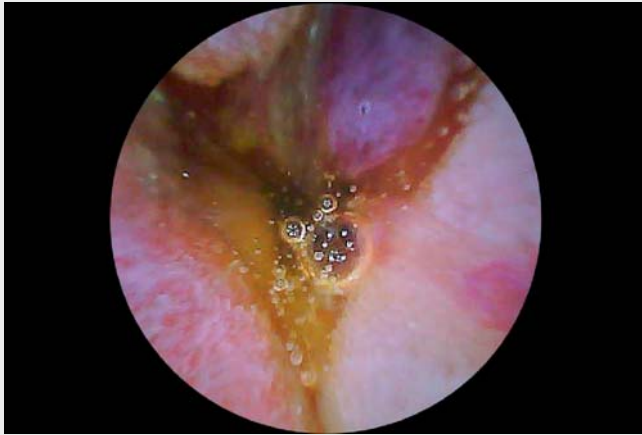CRP (38.1 mg/L), ESR (38 mm/h), and IgE (872.0 IU/ml), while the other relevant tests and physical examinations were unremarkable.

Abdominal computed tomography (CT) showed diffuse thickening and edema in the horizontal part of the duodenum with dilated lumen (► **Fig. 2**). Gastroscopy and colonoscopy did not reveal any detailed abnormalities. Capsule endos-

copy was performed, which revealed multiple areas of purpuric erythema throughout the small intestine (► **Fig. 3**) and notably purpuric lesions fusing with each other to form large hemorrhagic blisters in the proximal small bowel, which had not been reported previously (► **Fig. 4**, ► **Video 1**).

A diagnosis of Henoch-Schönlein purpura was adopted after ruling out other diseases. The patient was treated with methylprednisolone and achieved a good therapeutic outcome. Seven days later, the patient's abdominal symptoms and palpable rashes fully disappeared. A second examination with abdominal CT and capsule endoscopy performed 8 weeks after the start of treatment showed that the previously identified lesions had completely resolved.

Henoch-Schönlein purpura is an IgA-mediated systemic vasculitis with clinical manifestations including non-thrombocytopenic palpable purpura, abdominal pain, arthritis, and renal disease [1]. Gastrointestinal symptoms occur in about 50% to 85% of patients and the lesions can involve the entire gastrointestinal tract, with small intestine involvement being the most common [2, 3]. Therefore, capsule endoscopy has a unique value in the diagnosis of small intestine involvement in Henoch-Schönlein purpura, allowing a comprehensive view of



Video 1 Capsule endoscopy successfully diagnosed Henoch-Schönlein purpura in a patient with small intestine involvement.

the entire small intestinal mucosa to assess the extent and severity of the vasculitis by detecting the typical petechiae, erythema, sporadic purpura, or diffuse purpura that may not be detected by upper gastrointestinal endoscopy, colonoscopy, or abdominal CT.

Endoscopy_UCTN_Code_CCL_1AC_2AB

Competing interests

The authors declare that they have no conflict of interest.

The authors

Shao-xiong Zeng^{*}, **Han-lin Chen**^{*}, **Xiao-fei Yin**, **Chun-sheng Cheng**

Department of Gastroenterology and Endoscopy Center, Huazhong University of Science and Technology Union Shenzhen Hospital (Nanshan Hospital) and The 6th Affiliated Hospital of Shenzhen University Health Science Center, Shenzhen, Guangdong, China

^{*} S-X Zeng and H-L Chen contributed equally to this work.

Corresponding author

Chun-sheng Cheng, MD

Department of Gastroenterology and Endoscopy Center, Huazhong University of Science and Technology Union Shenzhen Hospital, The 6th Affiliated Hospital of Shenzhen University Health Science Center, No. 89 Taoyuan Road, Nanshan District, Shenzhen 518052, Guangdong Province, China

Fax: +86-755-26553111
chunsheng74@sina.com

References

- [1] Hetland LE, Susrud KS, Lindahl KH et al. Henoch-Schönlein purpura: A literature review. *Acta Derm Venereol* 2017; 97: 1160–1166
- [2] Esaki M, Matsumoto T, Nakamura S et al. GI involvement in Henoch-Schönlein purpura. *Gastrointest Endosc* 2002; 56: 920–923
- [3] Fang Y, Peng K, Zhao H et al. The characteristics of video capsule endoscopy in pediatric Henoch-Schönlein purpura with gastrointestinal symptoms. *Pediatr Rheumatol Online J* 2020; 18: 84

Bibliography

Endoscopy 2023; 55: E322–E323

DOI 10.1055/a-1974-9863

ISSN 0013-726X

published online 13.12.2022

© 2022. The Author(s).

This is an open access article published by Thieme under the terms of the Creative Commons Attribution-NonDerivative-NonCommercial License, permitting copying and reproduction so long as the original work is given appropriate credit. Contents may not be used for commercial purposes, or adapted, remixed, transformed or built upon. (<https://creativecommons.org/licenses/by-nc-nd/4.0/>)

Georg Thieme Verlag KG, Rüdigerstraße 14, 70469 Stuttgart, Germany



ENDOSCOPY E-VIDEOS

<https://eref.thieme.de/e-videos>



Endoscopy E-Videos is an open access online section, reporting on interesting cases and new techniques in gastroenterological endoscopy. All papers include a high quality video and all contributions are freely accessible online. Processing charges apply (currently EUR 375), discounts and waivers acc. to HINARI are available.

This section has its own submission website at <https://mc.manuscriptcentral.com/e-videos>