

# Site V Surgery for Temporal Migraine Headaches

Ilaria Baldelli, MD, PhD\*

Maria Lucia Mangialardi, MD†

Edoardo Raposio, MD, PhD, FICS\*

**Background:** Auriculotemporal nerve is demonstrated to contribute to migraine pain in temporal area. In particular, its relationship with the superficial temporal artery in the soft tissues superficial to the temporal parietal fascia has attracted researchers' attention for many decades. The objective of this review was to explore whether site V nerve surgical decompression is effective for pain relief in temporal area.

**Methods:** A literature search, according to Preferred Reporting Items for Systematic Reviews and Meta-Analysis guidelines, was conducted to evaluate the surgical treatment of auriculotemporal migraine. Inclusion was based on studies written in English, published between 2000 and February 2020, containing a diagnosis of migraine in compliance with the classification of the International Headache Society. The treatment must consist of surgical procedures involving the auriculotemporal nerve and/or arteries in site V, with outcome data available for at least 3 months.

**Results:** Three hundred twenty-four records were identified after duplicates were removed, 31 full-text articles were assessed for eligibility, and 2 records were selected for inclusion. A total of 77 patients were included in the review. A direct approach at the anatomical site identified with careful physical examination and confirmed with a handheld Doppler probe is generally performed under local anesthesia. Blunt dissection to the superficial temporal fascia to expose the auriculotemporal nerve and the superficial temporal artery is followed by artery cauterization/ligament and eventual nerve transection/avulsion. Site V surgery results in a success rate from 79% to 97%.

**Conclusions:** Despite the recent advances in extracranial trigger site surgery and a success rate (>50% improvement) from 79% to 97%, site V decompression is still poorly described. Elaborate randomized trials are needed with accurate reporting of patient selection, surgical procedure, adverse events, recurrences or appearance of new trigger points, quality of life outcome, and longer follow-up times. (*Plast Reconstr Surg Glob Open* 2020;8:e2886; doi: [10.1097/GOX.0000000000002886](https://doi.org/10.1097/GOX.0000000000002886); Published online 15 June 2020.)

## INTRODUCTION

Headache localized in the temporal region is characterized by dysfunction of both the zygomaticotemporal nerve (ZTN) and the auriculotemporal nerve (ATN). Although

ZTN has been identified as the most important trigger site of this area,<sup>1</sup> several studies underline ATN's contribution to migraine pain in the temporal area<sup>2</sup> due to a mutually dependent relationship between the 2 nerves.<sup>3-6</sup>

While ZTN is easily damageable during surgical procedure of the zygomatic area,<sup>7-9</sup> ATN dysfunction is generally linked to its complex anatomical connections in the infra-temporal fossa<sup>10</sup> and to its relationship with the superficial temporal artery (STA) in the soft tissues superficial to the temporal parietal fascia.<sup>11,12</sup>

Signs and symptoms of the dysfunction of these 2 nerves are easily distinguishable: ZTN injury causes dif-fused pain over the zygomatic arch and anterior temple near the lateral canthus,<sup>13</sup> and its irritation can be detected in the "hollow area" in the temple, about 2 cm lateral and 1 cm above the lateral canthus<sup>5</sup>; ATN entrapment can cause pain in the high temple, ear, temporomandibular joint, preauricular, and parotid areas.<sup>11</sup>

*From the \*Clinica di Chirurgia Plastica e Ricostruttiva, Ospedale Policlinico San Martino e Sezione di Chirurgia Plastica, Dipartimento di Scienze Chirurgiche e Diagnostiche Integrate-DISC, Università degli Studi di Genova, Genova, Italy; and †Istituto di Clinica Chirurgica, Università Cattolica del Sacro Cuore e Unità di Chirurgia Plastica, Dipartimento Scienze della Salute della Donna e del Bambino, Fondazione Policlinico Universitario A Gemelli IRCCS, Rome, Italy.*

*Received for publication March 29, 2020; accepted April 10, 2020.*

*Copyright © 2020 The Authors. Published by Wolters Kluwer Health, Inc. on behalf of The American Society of Plastic Surgeons. This is an open-access article distributed under the terms of the [Creative Commons Attribution-Non Commercial-No Derivatives License 4.0 \(CCBY-NC-ND\)](https://creativecommons.org/licenses/by-nc-nd/4.0/), where it is permissible to download and share the work provided it is properly cited. The work cannot be changed in any way or used commercially without permission from the journal.*

DOI: [10.1097/GOX.0000000000002886](https://doi.org/10.1097/GOX.0000000000002886)

**Disclosure:** The authors have no financial interest to declare in relation to the content of this article.

Endoscopic or open surgical approaches are described in literature to decompress the trapped nerves<sup>14-17</sup>; however, site V has been often considered a minor site with respect to site II.<sup>18</sup> However, in the past, STA has been the focus of many authors in managing migraine headache through periarterial procaine infiltration, as well by cutting it as proximally as possible.<sup>19</sup>

The objective of this review was to explore whether site V nerve surgical decompression is effective for pain relief in temporal area.

### MATERIALS AND METHODS

A literature search using PubMed, Cochrane, and Google Scholar database according to Preferred Reporting Items for Systematic Reviews and Meta-Analysis guidelines was conducted to evaluate the surgical treatment of auriculotemporal migraine. The following MeSH terms were used: “temporal migraine surgery,” “temporal headache surgery,” “temporal nerve decompression,” “temporal headache surgical treatment,” “temporal migraine surgical treatment,” “temporal headache surgical therapy,” “temporal migraine surgical therapy,” “auriculotemporal migraine surgery,” “auriculotemporal headache surgery,” “auriculotemporal nerve decompression,” “auriculotemporal headache surgical treatment,” and “auriculotemporal migraine surgical treatment” (period: 2000–2020; last search on 17 March 2020). Two-stage screening and

data extraction were performed by 2 independent reviewers. Abstracts were screened to identify eligible papers. Reference lists of relevant articles were searched for additional studies. The search strategy is shown in a flow chart (Preferred Reporting Items for Systematic Reviews and Meta-Analysis guidelines) (Fig. 1).<sup>20</sup>

### Inclusion and Exclusion Criteria

Studies were selected based on the following inclusion criteria:

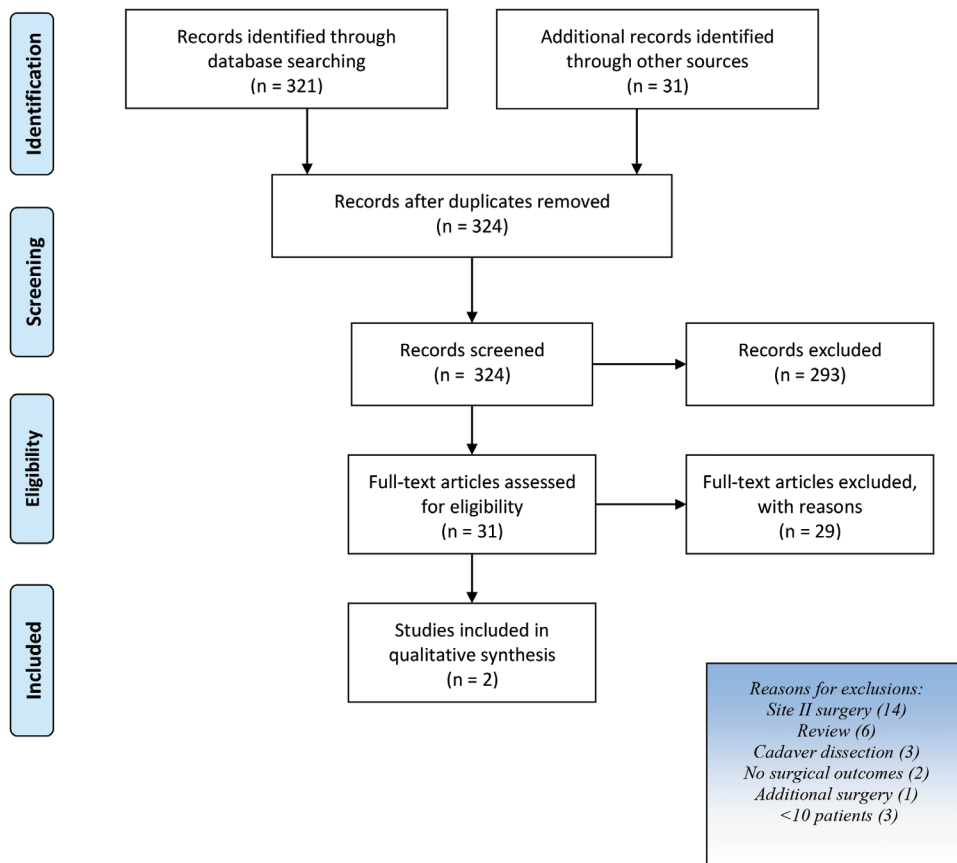
- (1) Studies selectively investigating surgical treatment of auriculotemporal headache (site V);
- (2) registration of outcomes after surgical treatment;
- (3) full text available in English;
- (4) studies published between 2000 and February 2020.

Studies were excluded due to any one of the following criteria:

- (1) review articles;
- (2) case report;
- (3) articles reporting only anatomic data and not surgical outcomes;
- (4) articles reporting only on surgical technique and not surgical outcomes;
- (5) articles describing studies that included fewer than 10 patients who underwent site V migraine headache surgery;
- (6) nonreferenced articles;
- (7) expert opinion (Level V).

### Data Collection

Extracted data included authors’ name, year of publication, number of patients included, sex, mean age, surgical



**Fig. 1.** The PRISMA flow diagram. PRISMA, Preferred Reporting Items for Systematic Reviews and Meta-Analysis.

strategy, mean follow-up time, method of outcome measurements used, results, and postoperative complication.

## RESULTS

After the exclusion of repeated items, 315 articles were identified. All the records were analyzed by title and abstract by 2 different reviewers. Twenty-two full-text articles were examined for eligibility. Two studies published in 2018 were considered eligible based on inclusion/exclusion criteria and were included in this systematic review.<sup>21,22</sup>

Both were retrospective studies. A total of 77 patients were included in the review (34 and 43, respectively). Only the second study reported patients' gender, showing a female prevalence (83.7%) and patients' age as median and as range (50 years; range 40–57 years) (Table 1). Regarding the side of surgical treatment, in both studies,

unilateral or bilateral decompression surgery was described (n = 9, 78%; n = 36, 84%, respectively).

All patients considered underwent decompression of the ATN through a direct approach (1.5 and 1 cm, respectively) under local anesthesia. Before surgery, a careful anamnestic and physical examination was done to identify patients' trigger points, which were confirmed with a handheld Doppler probe. Blunt dissection to the superficial temporal fascia was done in both studies to expose the ATN (and minor branches) and the superficial temporal artery. Bertozzi et al<sup>21</sup> described a 100% close relationship between ATN and STA (83.7% intersection and 16.3% helical intertwining) in patients treated with only site V nerve decompression. After dissection, Bertozzi et al<sup>21</sup> performed cauterization or artery ligation, while Long et al,<sup>22</sup> in addition, had the main nerve transected and its minor branches avulsed.

**Table 1. Studies Included in Qualitative Synthesis**

Study	Year	Type	Sample, points	Surgical Strategy	Outcome Measures	Follow-up, mo	Results	Complications
Bertozzi et al <sup>21</sup>	2018	Retrospective analysis	34	Direct approach to the trigger site after confirmation with the Doppler probe. Blunt dissection to expose ATN and STA (100% close relationship: 83.7% intersection, 16.3% helical intertwining). Cauterization or artery ligation.	Site-specific relief (complete relief, significant improvement, no improvement) was recorded at least 3 months after surgery.	21 (range 3–67)	97% positive surgical outcome, 3% onset of secondary trigger point. More detailed results referred to a larger group of patients who underwent simultaneous site II–site V decompression treatment, and it is not possible to extrapolate data referring to site V only.	—
Long et al <sup>22</sup>	2018	Retrospective analysis	43 (36 women, 7 men)	Direct approach to the trigger site after confirmation with the Doppler probe. Blunt dissection to expose ATN and STA. Cauterization or artery ligation and transection of the main nerve and/or avulsion of minor branches.	Migraine frequency (number of migraine-free days per month), duration (hours per day), severity (scale 1–10), anatomical location of pain (whether or not the specific surgical site continued to trigger migraines).	17.2	79% positive surgical outcome. Migraine parameters before and after surgery: migraine-free days per month (12.6 vs 25.1; $P < 0.005$ ), migraine intensity (8.3 vs 3.2; $P < 0.005$ ), migraine duration (1.2 vs 0.5; $P < 0.005$ ). Migraine parameters before and after surgery in patients with and without site V relief: migraine-free days per month (11.6 vs 27.2 and 16.2 vs 17.3), migraine intensity (8.4 vs 2.1 and 7.9 vs 7.4), migraine duration (1.1 vs 0.3 and 1.6 vs 1.1). Migraine parameters before and after surgery in patients underwent unilateral versus bilateral procedures: migraine-free days per month (15 vs 23 and 12 vs 25), migraine intensity (8.0 vs 5.3 and 8.3 vs 2.9), migraine duration (1.3 vs 0.7 and 1.2 vs 0.5).	—

Regarding outcome measures, a global migraine headache questionnaire to assess migraine frequency (number of migraine-free days per month), duration (hours per day), severity (scale 1–10), and anatomical location of pain (whether or not the specific surgical site continued to trigger migraines) was considered by Long et al, whereas only site-specific relief (complete relief, significant improvement, no improvement) was recorded by Bertozzi et al.

More in detail, a positive surgical outcome (>50% improvement) was present in 97% of patients of the first study<sup>21</sup> and in 79% of those of the second one.<sup>22</sup> Moreover, Long et al described a significant improvement in migraine-free days per month (12.6 versus 25.1;  $P < 0.005$ ), migraine intensity (8.3 versus 3.2;  $P < 0.005$ ), and migraine duration (1.2 versus 0.5;  $P < 0.005$ ) after surgery. Furthermore, migraine parameters before and after surgery were compared in patients with and without site V relief (migraine-free days per month, 11.6 versus 27.2 and 16.2 versus 17.3; migraine intensity, 8.4 versus 2.1 and 7.9 versus 7.4; migraine duration, 1.1 versus 0.3 and 1.6 versus 1.1) and in patients who underwent unilateral versus bilateral procedures (migraine-free days per month, 15 versus 23 and 12 versus 25; migraine intensity, 8.0 versus 5.3 and 8.3 versus 2.9; migraine duration, 1.3 versus 0.7 and 1.2 versus 0.5). Unfortunately, in Bertozzi's study, more detailed results refer to a larger group, including patients who underwent simultaneous site II–site V decompression treatment, and it is not possible to extrapolate data referring to site V only.

The onset of secondary trigger points is detected in only the 17% of patients by Bertozzi et al. Mean follow-ups for both these studies are 21 months (range 3–67 months) and 17.2 months, respectively. Neither study reported common postoperative complications of the case series described.

## DISCUSSION

Migraines are believed to be a neurovascular disorder, with evidence supporting a mechanism starting within the brain and then spreading to the extracranial blood vessels.<sup>23</sup> For this reason, recently, prophylactic medical treatment with only drugs has evolved in the treatment of the affected tissues.<sup>24</sup> Botulinum toxin, nerve blocks, and neurostimulation have been tested to support these theories.<sup>25</sup> Surgery has been introduced as a complementary treatment option for patients in whom pharmacological control of the disease could not be achieved. Decompression/avulsion of specific extracranial trigeminal branches or of the occipital nerves and cauterization/ligation of extracranial arteries represent the mainly described treatments in the literature.<sup>26–28</sup> Surgical decompression seems to guarantee a success rate ranging from 79% to 90%,<sup>29–31</sup> with a not negligible percentage of patients who remain refractory to the treatments. Research on other surgical techniques is ongoing. Fat grafting, for example, could represent a new slightly invasive surgical option for patients who have failed decompression surgery<sup>32</sup> in relation to the regenerative effect that has been shown on peripheral nerve regeneration<sup>33,34</sup> and myelination.<sup>35</sup>

Although some triggers like site I, site II, and site IV have been widely investigated,<sup>36,37</sup> our study underlines a lack of data for site V treatment. Both the chosen studies

involve a retrospective analysis of case series, and the total number of patients did not reach 100. However, there is a consensus on the importance of an accurate preoperative evaluation to identify the precise trigger sites and on the surgical technique, which consider the direct approach to expose the nervous and vascular structures involved, under local anesthesia. Moreover, Doppler probe is considered an important means for the preoperative localization of STA by all the authors. More in detail regarding the surgical technique, a partial disagreement is present on the management of the main nerve and its minor branches: Bertozzi et al do not include any procedure for the nervous structures (merely STA cauterizing or binding), while Long et al perform the transection or avulsion of them (plus STA arteriectomy). Guyuron et al<sup>15</sup> in a prospective, blinded randomized cohort study compare these 2 different techniques at site II without finding a statistically significant difference in reduction of frequency, migraine days, severity, and duration at 1-year follow-up. No differences in terms of sensation and 2-point discrimination are observed. However, in our opinion, anatomical peculiarities of the site where ZTN lies differ from those of ATN ones, and specific research should be done.

Regardless of the surgical technique, site V surgery results in a success rate from 79% to 97%, even if, in Long's study, despite the presence of a more detailed preoperative and postoperative assessment, it is not clear whether patients have undergone a prior migraine surgery in another more common site. In Bertozzi's study, authors comment on the onset of secondary trigger points in nonrespondent patients; so we can assume site V as the first site for migraine surgery.

Both the studies deal with bilateral migraine headache, but only Long et al compared the results between patients who underwent unilateral and bilateral surgery, without finding a significant association among laterality and migraine duration, migraine-free days, and intensity.

Finally, adverse events after surgery and the evaluation of the impact of migraine on the quality of life preoperatively and postoperatively are completely absent or are not referred to in the results of the literature.

## CONCLUSIONS

Our systematic review of the literature underlines the need of further research on auriculotemporal trigger site nerve decompression. Its relationship with the superficial temporal artery is, in fact, of particular interest in relation to the neurovascular disorder underlying migraine headache. Although there is a good degree of consensus on surgical technique, prospective studies on this specific trigger site would be useful in defining which patients can best benefit from this treatment.

**Edoardo Raposio, MD, PhD, FICS**

Plastic Surgery Division

Department of Surgical Sciences and Integrated Diagnostics

University of Genova

L.go R. Benzi 10

16132 Genova, Italy

E-mail: edoardo.raposio@unipr.it

## REFERENCES

- Guyuron B, Kriegler JS, Davis J, et al. Five-year outcome of surgical treatment of migraine headaches. *Plast Reconstr Surg*. 2011;127:603–608.
- Janis JE, Dhanik A, Howard JH. Validation of the peripheral trigger point theory of migraine headaches: single-surgeon experience using botulinum toxin and surgical decompression. *Plast Reconstr Surg*. 2011;128:123–131.
- Liu MT, Armijo BS, Guyuron B. A comparison of outcome of surgical treatment of migraine headaches using a constellation of symptoms versus botulinum toxin type A to identify the trigger sites. *Plast Reconstr Surg*. 2012;129:413–419.
- Davidge KM, van Furth WR, Agur A, et al. Naming the soft tissue layers of the temporoparietal region: unifying anatomic terminology across surgical disciplines. *Neurosurgery*. 2010;67(3 Suppl Operative):120–129; discussions on 129–130.
- Totonchi A, Pashmini N, Guyuron B. The zygomaticotemporal branch of the trigeminal nerve: an anatomical study. *Plast Reconstr Surg*. 2005;115:273–277.
- Raposo E. *Atlas of Surgical Therapy for Migraine and Tension-type Headache*. New York, N.Y.: Springer; 2019.
- Hwang K, Suh MS, Lee SI, et al. Zygomaticotemporal nerve passage in the orbit and temporal area. *J Craniofac Surg*. 2004;15:209–214.
- Loukas M, Owens DG, Tubbs RS, et al. Zygomaticofacial, zygomaticoorbital and zygomaticotemporal foramina: anatomical study. *Anat Sci Int*. 2008;83:77–82.
- Govsa F, Celik S, Ozer MA. Orbital restoration surgery in the zygomaticotemporal and zygomaticofacial nerves and important anatomic landmarks. *J Craniofac Surg*. 2009;20:540–544.
- Piagkou MN, Demesticha T, Piagkos G, et al. Mandibular nerve entrapment in the infratemporal fossa. *Surg Radiol Anat*. 2011;33:291–299.
- Janis JE, Hatef DA, Ducic I, et al. Anatomy of the auriculotemporal nerve: variations in its relationship to the superficial temporal artery and implications for the treatment of migraine headaches. *Plast Reconstr Surg*. 2010;125:1422–1428.
- Chim H, Okada HC, Brown MS, et al. The auriculotemporal nerve in etiology of migraine headaches: compression points and anatomical variations. *Plast Reconstr Surg*. 2012;130:336–341.
- Karl HW, Trescot AM. Nerve entrapment headaches at the temple: zygomaticotemporal and/or auriculotemporal nerve? *Pain Physician*. 2019;22:E15–E36.
- Caruana G, Bertozzi N, Boschi E, et al. Endoscopic forehead surgery for migraine therapy personal technique. *Ann Ital Chir*. 2014;85:583–586.
- Guyuron B, Harvey D, Reed D. A prospective randomized outcomes comparison of two temple migraine trigger site deactivation techniques. *Plast Reconstr Surg*. 2015;136:159–165.
- Raposo E. *Atlas of Endoscopic Plastic Surgery*. New York, N.Y.: Springer; 2015.
- Sannic K, Borsting E, Amirlak B. Decompression-avulsion of the auriculotemporal nerve for treatment of migraines and chronic headaches. *Plast Reconstr Surg Glob Open*. 2016;4:e678.
- Seyed Forootan NS, Lee M, Guyuron B. Migraine headache trigger site prevalence analysis of 2590 sites in 1010 patients. *J Plast Reconstr Aesthet Surg*. 2017;70:152–158.
- Kajtor F. Vascular headache caused by arterialgia of the superficial temporal artery and its surgical treatment. *Monatsschr Psychiatr Neurol*. 1949;118:1–10.
- Moher D, Liberati A, Tetzlaff J, et al; PRISMA Group. Preferred reporting items for systematic reviews and meta-analyses: the PRISMA statement. *PLoS Med*. 2009;6:e1000097.
- Bertozzi N, Simonacci F, Lago G, et al. Surgical therapy of temporal triggered migraine headache. *Plast Reconstr Surg Glob Open*. 2018;6:e1980.
- Long T, Ascha M, Guyuron B. Efficacy of surgical treatment of migraine headaches involving the auriculotemporal nerve (Site V). *Plast Reconstr Surg*. 2019;143:557–563.
- Burstein R, Blake P, Schain A, et al. Extracranial origin of headache. *Curr Opin Neurol*. 2017;30:263–271.
- Gfrerer L, Hulsen JH, McLeod MD, et al. Migraine surgery: an all or nothing phenomenon? prospective evaluation of surgical outcomes. *Ann Surg*. 2019;269:994–999.
- Olla D, Sawyer J, Sommer N, et al. Migraine treatment. *Clin Plast Surg*. 2020;47:295–303.
- Vincent AJPE, van Hoogstraten WS, Maassen Van Den Brink A, et al. Extracranial trigger site surgery for migraine: a systematic review with meta-analysis on elimination of headache symptoms. *Front Neurol*. 2019;10:89.
- Caruana G, Grignaffini E, Raposo E. Endoscopic forehead muscle resection for nerve decompression: a modified procedure. *Plast Reconstr Surg Glob Open*. 2015;3:e342.
- Polotto S, Simonacci F, Grignaffini E, et al. Surgical treatment of frontal and occipital migraines: a comparison of results. *Plast Reconstr Surg Glob Open*. 2016;4:e653.
- Kurlander DE, Punjabi A, Liu MT, et al. In-depth review of symptoms, triggers, and treatment of temporal migraine headaches (Site II). *Plast Reconstr Surg*. 2014;133:897–903.
- Raposo E, Bertozzi N. Trigger site inactivation for the surgical therapy of occipital migraine and tension-type headache: our experience and review of the literature. *Plast Reconstr Surg Glob Open*. 2019;7:e2507.
- Raposo E, Caruana G. Frontal endoscopic myotomies for chronic headache. *J Craniofac Surg*. 2015;3:e201–e203.
- Guyuron B, Pourtaheri N. Therapeutic role of fat injection in the treatment of recalcitrant migraine headaches. *Plast Reconstr Surg*. 2019;143:877–885.
- Zuk PA, Zhu M, Ashjian P, et al. Human adipose tissue is a source of multipotent stem cells. *Mol Biol Cell*. 2002;13:4279–4295.
- Aluigi MG, Coradeghini R, Guida C, et al. Pre-adipocytes commitment to neurogenesis 1: preliminary localisation of cholinergic molecules. *Cell Biol Int*. 2009;33:594–601.
- Murphy MB, Moncivais K, Caplan AI. Mesenchymal stem cells: environmentally responsive therapeutics for regenerative medicine. *Exp Mol Med*. 2013;45:e54.
- Janis JE, Barker JC, Javadi C, et al. A review of current evidence in the surgical treatment of migraine headaches. *Plast Reconstr Surg*. 2014;134(4 Suppl 2):131S–141S.
- Raposo E, Bertozzi N, Bordin C, et al. Surgical therapy of headaches: minimally invasive approaches. In: Kozubski W, ed., *Clinical Advances in Head & Neck Surgery*. Las Vegas, Nev.: Openaccess eBooks; 2018:1–23