

Rectal impalement with bladder perforation: A review from a single institution

El Bachir Benjelloun, Youness Ahallal¹, Khalid Khatala², Tarik Souiki, Iman Kamaoui³, Khalid Ait Taleb

Departments of General Surgery, ¹Urology, ²Pediatric Surgery, and ³Radiology, University Hospital Hassan II, Fez, Morocco

Abstract

Context: Impalement injuries of the rectum with bladder perforation have been rarely reported. Such lesions have been associated with increased postoperative morbidity. A well-conducted preoperative evaluation of the lesions tends to prevent such complications.

Aims: To increase awareness about patients with rectal impalement that involve bladder injuries and to examine the significance of thorough clinical examination and complementary investigation for these patients' management.

Materials and Methods: Retrospectively, we identified three patients with rectal impalement and bladder perforation treated in University Hospital Hassan II, Fez, Morocco. We recorded the symptoms, subsequent management, and further follow-up for each patient. All available variables of published cases were reviewed and analyzed.

Results: Evident urologic symptoms were present in only one patient. Bladder perforation was suspected in two other patients on the basis of anterior rectal perforation in digital exam. Retrograde uroscanner could definitely confirm the diagnosis of bladder perforation. Fecal and urine diversion was the basis of the treatment. No postoperative complications were noted. We have reviewed 14 previous reports. They are presented mainly with urine drainage through the rectum. Radiologic investigation (retrograde cystography and retrograde uroscanner) confirmed bladder perforation in 10 patients (71.4%). Unnecessary laparotomy was performed in six patients (42.8%). Fecal diversion and urinary bladder decompression using urethral catheter were the most performed procedures in bladder perforation [6/14 patients (42.8%)]. No specific postoperative complications were reported.

Conclusions: A high index of clinical suspicion is required to make the diagnosis of bladder perforation while assessing patients presenting with rectal impalement. Meticulous preoperative assessment is the clue of successful management.

Key Words: Bladder perforation, laparotomy, rectal impalement, retrograde-uroscanner

Address for correspondence:

Dr. El Bachir Benjelloun, Medical School of Fez. Sidi Hrazem Road 30000, Fez, Morocco. E-mail: benjelloun19@hotmail.com

Received: 25.06.2012, Accepted: 16.10.2012

INTRODUCTION

Impalement injuries of the rectum have been frequently

reported. They may be associated with intra- and extraperitoneal organ injuries. Combined rectal and bladder injuries after rectal impalement remain a rare condition because of the deep bladder position within the bony pelvis.^[1] This type of combined injuries may compromise postoperative outcome in these patients with risk of postoperative complications. Absence of specific symptoms such as hematuria or urine drainage through the rectum increases the risk of missing bladder perforation. This may lead to unnecessary morbidity in these patients due to mainly unrepaired rectovesical fistula. Radiologic investigations such as cystography and computed

Access this article online	
Quick Response Code:	Website: www.urologyannals.com
	DOI: 10.4103/0974-7796.120298

tomography (CT) are recommended whenever bladder or abdominal injuries are suspected.^[2] We present a series of three patients diagnosed and treated for combined rectal and bladder perforation due to rectal impalement. We have reviewed the pertinent literature with focused attention to the management of bladder perforation.

MATERIALS AND METHODS

Retrospectively, we identified three patients who had been treated in University Hospital Hassan II, Fez, Morocco, for combined rectal and bladder injuries after rectal impalement (2010-2012). A review of the patients' charts was performed along with a review of English/French-language articles using a PubMed search from 1970 to April 2012. We searched using the keywords: "Rectal impalement," "rectal perforation," and "bladder perforation," either singly or in combination. Patients with rectal impalement and bladder perforation reported in the series were excluded as they were mixed with other rectal injuries, and we could not identify the results of diagnosis, management, and outcomes for rectal impalement injuries with bladder perforation alone.

RESULTS

Case 1

A farmer, aged 57 years, fell down onto the cow horn, causing a penetrating injury of his anal area. Ten hours later, he came on the emergency unit complaining of rectal bleeding and one episode of hematuria. On examination, the abdomen was soft, non-tender, and non-surgical. Physical examination of the perineum showed a 3 cm left lateral perianal wound extending to the anal canal and involving internal anal sphincter. Rectal examination revealed a low sphincter tonus, but could not be completed because of the pain. Urine catheter placed in the bladder showed clear urine with some blood staining. Retrograde Uroscanner (RU) showed passage of contrast into rectum. No free air or intraperitoneal free contrast was noticed. Examination under anesthesia revealed a 1-cm-diameter hole in anterior rectal wall. It was about 7 cm from the anal verge. Elective loop colostomy was performed. Rectal wall was sutured through the anal canal with 3/0 vicryl, followed by rectal washout. The perianal wound with internal sphincter injury was sutured. The patient got an uncomplicated postoperative course. Foley catheter was removed on day 21 postoperatively. Two months later, a confirmatory cystogram showed no leak into the rectum. Endoanal ultrasound did not show a significant damage within anal sphincter. The colostomy was closed a month later.

Case 2

A 23-year-old man was admitted to the hospital 4 h after falling on a wooden stake. He was complaining of an

unbearable anal pain with rectal bleeding. He had neither hematuria nor abdominal pain. Physical examination showed a soft non-tender abdomen. Perineal examination could not be done as the patient refused any investigation without anesthesia. Nevertheless, we had been able to place a urine catheter which showed unclear urine without hematuria. RU was performed to exclude any bladder involvement. It showed passage of contrast into the extraperitoneal anterior wall of the rectum [Figure 1]. The patient was taken to the operative room. Examination under anesthesia showed a small laceration at the left anal margin extending into the anus. In the rectal exam, sphincter tonus was normal. At 7-8 cm from the anal verge, we found about 1-2 cm hole on the anterior wall of the rectum. Injection of the saline through the Foley catheter showed a leak through the posterior bladder wall into the rectum which confirmed the CT finding. There was no free air or contrast leak within the peritoneal cavity. Elective loop sigmoidostomy was performed. Rectum was sutured through the anal canal with 3/0 vicryl, followed by rectal washout. A large presacral drainage was also performed. The patient had an eventless postoperative course. The Foley catheter was removed on postoperative day 21. One month later, a control cystogram was performed showing no leak into the rectum. The colostomy was closed 2 months after the first surgery.

Case 3

A previously healthy 15-year-old boy presented to University Hospital Hassan II of Fez. Three hours ago, he had fallen onto the handlebar of the bicycle and sustained a penetrating injury of the rectum. The patient and his parents reported copious watery drainage expelled per rectum. No sign of hematuria was reported as he had not voided since the trauma. Upon arrival at our emergency room, the patient complained only of pelvic pain and inability to void. No abdominal

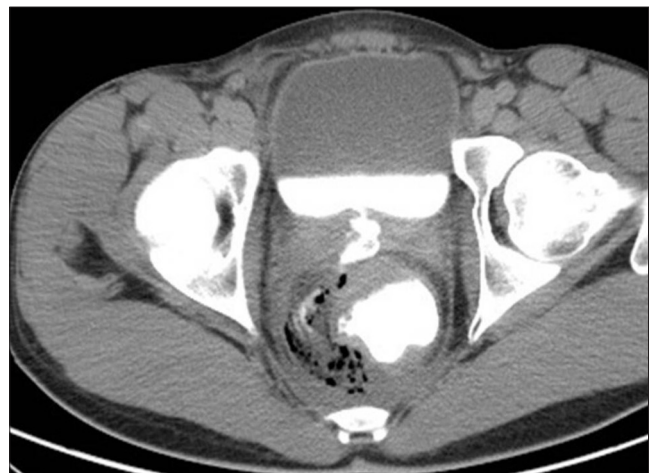

Figure 1: RU showing a connection between the anterior wall of the rectum and posterior wall of the urinary bladder

pain was reported by the patient. On physical examination, the abdomen was free of tenderness. Rectal exam revealed about 2-3 cm defect in the anterior rectal wall at 6-7 cm of the anal verge. RU demonstrated a communication between extraperitoneal posterior bladder wall and the anterior rectal wall. Foley catheter was inserted for bladder decompression. We temporarily decided to avoid diverting colostomy by the close surveillance of patient. During this period, no signs of hyperthermia, abdominal pain, or abnormal changes in the urine were observed. Two weeks after the injury, a control cystogram was performed, which showed no communication between the rectum and urinary bladder. Foley catheter was removed 1 week later.

Analysis including patients reported in the literature

A PubMed search of the literature found 11 reports with combined rectal and bladder injuries due to rectal impalement.^[3-10] Details of all the 11 cases along with the current patients are summarized in Table 1 and Table 2 summarizes the results of clinical symptoms, radiologic findings, treatment, and outcome data of the patients. The mean age of the patients was 28.1 years (range 9-57 years) and the male: female ratio was 12:2.

The main reported symptoms referring to bladder perforation were urine drainage through the rectum [5 patients (35.7%)], hematuria [3 patients (21.4%)], and inability to void [2 patients (14.3%)], while 4 patients (28.6%) did not declare any urinary symptoms at admission. Radiologic investigations were used in 10 patients (71.4%). Diagnosis of bladder perforation was definitely confirmed by retrograde cystography in five patients (35.7%), RU in three patients (21.4%), cystoscopy in one patient (7.1%), gastrografin enema in one patient (7.1%), and exam under anesthesia in three patients (21.4%). Bladder perforation was extraperitoneal in 10 patients (71.4%) and combined extra- and intraperitoneal in 4 patients (28.6%). Exploratory laparotomy was performed in 10 patients (71.4%). Among these cases, only in two patients laparotomy was indicated on the basis of radiologic finding highly suspecting intraperitoneal organ injuries (intraperitoneal contrast leak, free air). Exploratory laparotomy was performed with no finding in six cases (42.8%). Fecal diversion and urinary bladder decompression using urethral catheter were the most performed treatments in extraperitoneal bladder perforation [6 patients (42.8%)]. Intraperitoneal bladder perforations were managed by bladder suture [4 patients (28.6%)]. Only one case of combined bladder and ileal perforation was reported. Transanal rectal suture was performed in seven patients (50%), while suprapubic catheter was used in three patients (21.4%). Before removing the urethral catheter, control cystogram

was used in all patients. No postoperative complications were reported.

DISCUSSION

Rectal impalement involves foreign body trauma which may enter directly or through the perineal region, resulting in intra- or extraperitoneal rupture of the rectum and other organs, mainly of the genitourinary tract. Up to 95% of extraperitoneal bladder trauma is associated with pelvic fracture.^[11] Perforation of the bladder after rectal impalement, however, is extremely rare. Johnson has reported the first case of rectal impalement with perforation of the urinary bladder.^[3]

If rectal perforation may easily be diagnosed by rectal exam, the diagnosis of bladder perforation remains difficult mainly in the absence of specific urinary symptoms. Knowing the mechanism, nature of the impaling object, and direction of impact is important for predicting the potentially affected organs.^[12] It is mandatory to collect all necessary information including rectal bleeding, hematuria, and urine drainage through the rectum, which subsequently will lead to perform complementary radiologic and endoscopic investigations such as retrograde cystography, RU, or cystoscopy for detecting abnormal communication between bladder and rectum. When performing cystography, Carroll and MacAninch found that 100% accuracy could be achieved if 350 ml contrast was instilled or lesser amount if detrusor contraction occurred.^[13] However, lack of physical findings or absence of radiologic finding does not exclude intraabdominal injury or bladder perforation. It may be explained by the natural elasticity of the bladder wall and interlacing fibers of the detrusor which can prevent contrast extravasation.^[14] In case of complaints like abdominal pain and presence of tenderness in abdominal exam, an abdominal X-ray has to be performed to look for free gas under the diaphragm. A thorough perineal and rectal examination under anesthesia at operative room, as well as injection of saline through the Foley catheter in suspicion of bladder perforation may be helpful in detecting anomalies missed by clinical and radiologic investigation.

Treatment standards for surgical management of combined penetrating rectal and bladder injuries remain undefined. In a review of 17 cases of combined rectal and genitourinary injuries among 200 cases of penetrating rectal trauma, Franko *et al.* concluded that the standard treatment of penetrating rectal trauma is inadequate in combined penetrating rectal and genitourinary tract injuries.^[15]

If it is undeniable that diverting colostomy is highly recommended in the management of such type of injuries,

Table 1: Reported cases of rectal impalement with bladder perforation

Author	Age	Sex	Bladder perforation suspicion symptoms	Diagnosis of bladder perforation	Exploratory laparotomy		Rectal wound repair	Colostomy	Management of bladder perforation	Postop complications
					Indication	Finding				
Johnson ^[3]	9	F	No urinary symptoms	Physical exam	Yes. Abdominal pain	No	No	Urethral catheter	No	
Johnson ^[3]	31	F	Urine drainage through the rectum	Exam under anesthesia	Yes. Abdominal pain	No	No	Suture of bladder perforation	No	
Bouchet et al. ^[4]	53	M	Urine drainage through the rectum	Retrograde cystography	Yes. Abdominal pain	No	Yes	Urethral catheter	No	
Bensallah et al. ^[5]	15	M	Urine drainage through the rectum	Retrograde cystography	No	No	Yes	Suture of bladder perforation	No	
Bensallah et al. ^[5]	45	M	No urinary symptoms	Exam under anesthesia	Yes. Hypogastric tenderness	Yes. Intra-and extraperitoneal bladder perforation	No	Yes	Suture of bladder perforation	No
Bensallah et al. ^[5]	37	M	No urinary symptoms	Exam under anesthesia	Yes. Hypogastric tenderness	Yes. Intra-and extraperitoneal bladder perforation	No	Yes	Suture of bladder perforation+urethral catheter	No
Dartoy et al. ^[6]	12	M	No urinary symptoms	Retrograde cystography	Yes. Hypogastric tenderness	Yes. Hypogastric tenderness	Yes	Yes	Suture of bladder perforation+urethral catheter	No
Weber et al. ^[7]	9	M	Inability to void	Retrograde cystography	Yes. Hypogastric tenderness	Yes. Intra-and extraperitoneal 1 bladder perforation	Yes. Trans anal	Yes	Suture of bladder perforation	No
Tanuma et al. ^[8]	45	M	Hematuria	Retrograde cystography	Yes. Laparoscopy	No	No	Yes	Bilateral single J stents and a Foley catheter were placed at the same time	No
Kim et al. ^[9]	12	M	Urine drainage through the rectum	Cystoscopy	Yes. Abdominal pain	No	Yes. Trans anal	Yes	Urethral catheter	No
El-Ashaal et al. ^[10]	31	M	Hematuria	Abdominal computed tomography (free gas within the bladder)	Yes. CT scan free intraperitoneal gas	Yes. Intra-and extraperitoneal 1 bladder perforation	Yes. Trans anal	No	Suture of bladder perforations	No
Our report	57	M	Hematuria	Gastrografin enema	No	No	Yes. Trans anal	Yes	Urethral catheter	No
Our report	23	M	Inability to void	Retrograde uroscanner	No	No	Yes. Trans anal	Yes	Urethral catheter	No
Our report	15	M	Urine drainage through the rectum	Retrograde uroscanner	No	No	No	No	Urethral catheter	No

Table 2: Summary of results for all 14 cases

Age	28.1 years (9-57)
Sex (male/female), (male %)	12/2 (85.7%)
Urinary symptoms at admission	
Urine drainage through the rectum	5 (35.7%)
Hematuria	3 (21.4%)
Inability to void	2 (14.3%)
No	4 (28.6%)
Use of complementary investigation	
Retrograde cystography	5 (35.7%)
Retrograde	3 (21.4%)
Cystoscopy	1 (7.2%)
Not used	5 (35.7%)
Bladder perforation	
Extraperitoneal	10 (71.4%)
Combined intra-and extraperitoneal	4 (28.6%)
Laparotomy with negative finding	6 (42.8%)
Management of extraperitoneal bladder perforation	
Colostomy+urethral catheter	6 (42.8%)
Suture of perforation+colostomy+urethral catheter	2 (14.3%)
Suture of perforation+colostomy+suprapubic catheter	1 (7.2%)
Only urethral catheter	1 (7.2%)
Management of intra-and extraperitoneal bladder perforation	
Suture of perforation+colostomy+urethral catheter	2 (14.3%)
Suture of perforation+colostomy+suprapubic catheter	2 (14.3%)
Postoperative complications	0

the role of presacral drainage remains controversial. In a prospective randomized study comparing the management of civilian penetrating injuries with or without presacral drainage, Gonzalez *et al.* concluded that presacral drainage for penetrating rectal injuries has no effect on infectious complications associated with the rectal injuries.^[16] In the other study on treating combined penetrating rectal and genitourinary injuries, patients without presacral drainage had more risk to develop deep pelvic abscesses. However, this study has also included the patients with gunshot injuries who are more prone to develop postoperative complications such pelvic abscess and rectovesical fistula. In spite of being controversial, most authors recommend the use of presacral drainage in treating such kind of civilian trauma.^[17] The role of rectal washout has been shown to reduce the morbidity and mortality from penetrating rectal injuries, mainly in the patients with high-energy rectal injuries.^[18,19]

Other controversial issue is on the benefit of rectal wound repair. Some authors estimate than not repaired rectal defects usually heal spontaneously if adequately drained,^[20] while others reported an increasing rate of complications, mainly rectovesical fistula, in the absence of rectal wound repair.^[21]

Management of bladder perforation is not standardized. A Foley catheter for urinary decompression seems to be sufficient to treat extraperitoneal bladder perforation, while laparotomy with defect suture is indicated when the diagnosis of intraperitoneal bladder perforation is

maintained.^[22] The role of the suprapubic catheter has been declined by several authors. In the study of Crispen *et al.* concerning immediate postoperative complications of combined penetrating rectal and bladder injuries, it was clearly demonstrated that suprapubic catheter did not decrease fistula or urinoma formation in patients sustaining isolated bladder or combined injuries ($P = 1.00$).^[23] Control cystography should be performed after 10-14 days of urinary bladder drainage, and the catheter may be removed if there is no extravasation.

The role of exploratory laparotomy cannot be understood in the absence of evident clinical and radiologic finding. Nearly half of the reported cases sustained unnecessary laparotomy. This attitude was decreased in the last years with the regular use of radiological investigation.

Pelvic abscess, urinomas, and rectovesical fistula are the most frequent specific complications in combined rectal and bladder injuries. In a series of 17 combined rectal and genitourinary injuries, Franko *et al.* reported that the incidence of fistula formation was 15% when genitourinary injury was limited to the bladder.^[24]

The observed high rate of postoperative fistula formation in combined rectal and bladder injuries led some authors to advocate the interposition of an omental flap between the rectal and bladder repair sites.^[25,26] It is interesting to notice that all reports for rectal impalement with combined rectal and bladder perforation did not get any short- or long-term postoperative complications. It may be explained by the mechanism and nature of injury (impalement, gunshot, sexual abuse, blunt trauma) which may differ between the patients.

In summary, to our knowledge, this is the first study that summarizes the largest series of combined rectal and bladder injuries due to rectal impalement reported in literature. We have proposed a scheme for evaluation and management of rectal impalement with combined rectal and bladder perforation [Figure 2].

A high index of clinical suspicion is required to make the diagnosis of bladder perforation while assessing patients presenting with rectal impalement. Painstaking preoperative assessment is the clue of successful management.

ACKNOWLEDGMENTS

We would like to thank Dr. Reda Z Mahfouz, MD, PhD (Cleveland Clinic, Ohio, USA) for his critical revision and help to finalize this work.

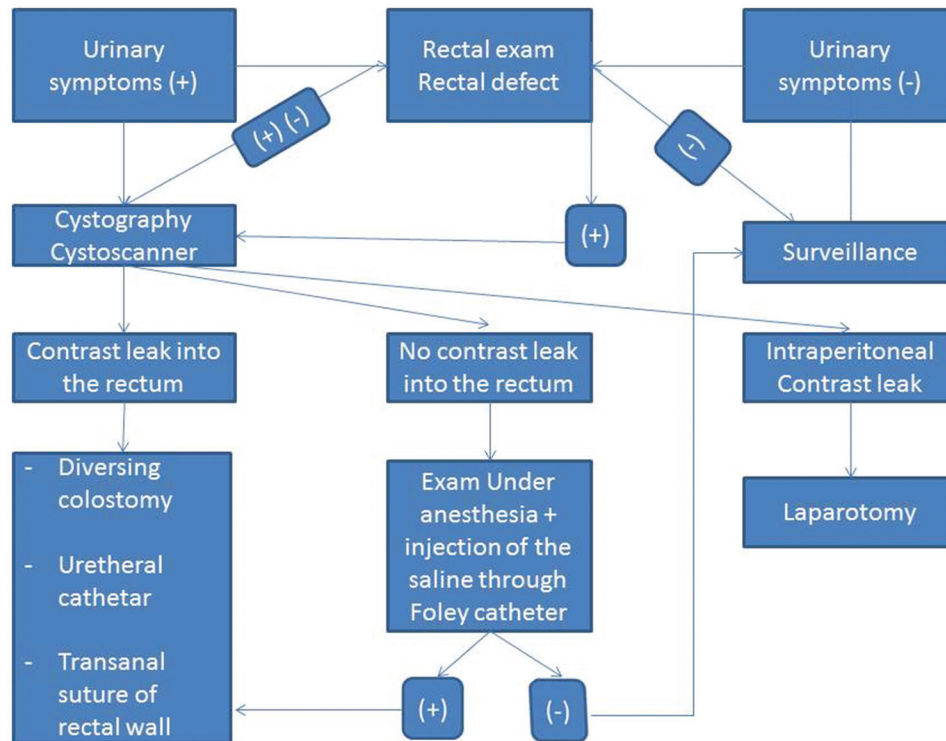


Figure 2: Proposed scheme for evaluation and management of rectal impalement with combined rectal and bladder perforation

REFERENCES

- Brosman SA, Paul JG. Trauma of the bladder. *Surg Gynecol Obstet* 1976;143:605-8.
- Rehm CG, Mure AJ, O'Malley KF, Ross SE. Blunt traumatic bladder rupture: The role of retrograde cystogram. *Ann Emerg Med* 1991;20:845-7.
- Johnson PA. Rectal impalement with perforation of the bladder. *Br Med J* 1971;2:748-9.
- Bouchet P, Truong P. A case of rectovesical injury caused by impalement. *Ann Chir* 1984;38:62-4.
- Ben Salah K, Khereddine T, Bouchoucha S, Zaouche A, Ennabli E. Rectal and bladder injuries by impalement. 3 cases. *Tunis Med* 1991;69:161-5.
- Dartoy C, Guibal MP, Fenoll B, Thoma M, Jehannin B. Anorectal traumas by impalement in children. Apropos of 3 cases. *J Chir* 1994;131:413-6.
- Weber S, Mauch W, Kalayoglu M, Moon TD. Intraperitoneal and extraperitoneal bladder rupture secondary to rectal impalement. *J Trauma* 1995;38:818-9.
- Tanuma Y, Horita H, Kadono M. Extraperitoneal bladder rupture secondary to rectal impalement. *Int J Urol* 2001;8:634-6.
- Kim S, Linden B, Cendron M, Puder M. Pediatric anorectal impalement with bladder rupture: Case report and review of the literature. *J Pediatr Surg* 2006;41:E1-3.
- El-Ashaal YI, Saadeldin YA, Abu-Zidan FM. Rectovesical tract caused by trans-anal metallic rod impalement. *J Trauma* 2010;68:1265.
- Rehm CG, Mure AJ, O'Malley KF, Ross SE. Blunt traumatic bladder rupture: The role of retrograde cystogram. *Ann Emerg Med* 1991;20:845-7.
- Jona JZ. Accidental anorectal impalement in children. *Pediatr Emerg Care* 1997;13:40-3.
- Carroll PR, McAninch JW. Major bladder trauma: The accuracy of cystography. *J Urol* 1983;130:887.
- Reiser C, Nicholas E. Rupture of the bladder: Unusual features. *Urology* 1963;90:53.
- Franko ER, Evatary RR, Schwalb DM. Combined penetrating rectal and genitourinary injuries: A challenge in management. *J Trauma* 1993;34:347-53.
- Gonzalez RP, Falimirski ME, Holevar MR. The role of presacral drainage in the management of penetrating rectal injuries. *J Trauma* 1998;45:656-61.
- Biriukov IuV, Volkov OV, Radzhabov AS, Borisov Elu, AnVK. Surgical treatment of extraperitoneal rectal and perineal injuries. *Khirurgia* 2000;6:37-40.
- Shannon FL, Moore EE, Moore FA, McCroskey BL. Value of distal colon washout in civilian rectal trauma – reducing gut bacterial translocation. *J Trauma* 1988;28:989-94.
- Burch JM, Feliciano DV, Mattox KL. Colostomy and drainage of civilian rectal injuries: Is that all? *Ann Surg* 1989;209:600-10.
- Brunner RG, Shatney CH. Diagnostic and therapeutic aspects of rectal trauma. Blunt versus penetrating. *Am Surg* 1987;53:215-9.
- Tuggle D, Huber PJ Jr. Management of rectal trauma. *Am J Surg* 1984;148:806-8.
- Corriere Jr JN, Sandler CM. Management of the ruptured bladder: Seven years of experience with 111 cases. *J Trauma* 1986;26:830-3.
- Crispen PL, Kansas BT, Pieri PG, Fisher C, Gaughan JP, Pathak AS, et al. Immediate postoperative complications of combined penetrating rectal and bladder injuries. *J Trauma* 2007;62:325-9.
- Franko ER, Ivatary RR, Schwalb DM. Combined penetrating rectal and genitourinary injuries: A challenge in management. *J Trauma* 1993;34:347-53.
- Topor B, Acland RD, Kolodko V, Galandiuk S. Omental transposition for low pelvic anastomoses. *Am J Surg* 2001;182:460-4.
- Wein AJ, Malloy TR, Greenberg SH, Carpinello VL, Murphy JJ. Omental transposition as an aid in genitourinary reconstructive procedures. *J Trauma* 1980;20:473-7.

How to cite this article: Bachir Benjelloun EI, Ahallal Y, Khatala K, Souiki T, Kamaoui I, Taleb KA. Rectal impalement with bladder perforation: A review from a single institution. *Urol Ann* 2013;5:249-54.

Source of Support: Nil, **Conflict of Interest:** None.