

Combination of 1064 nm Long-Pulsed and Q-Switched Nd:YAG Laser for Facial Hypertrophic Scar and Hyperpigmentation Following Burn Injury

Kartika Ruchiatan ¹, Kamelia Utami Suhada ¹, Reti Hindritiani ¹, Diah Puspitosari ¹, Rani Seprina ²

¹Department of Dermatology and Venereology, Faculty of Medicine, Universitas Padjadjaran - Dr. Hasan Sadikin Hospital, Bandung, Indonesia;

²Department of Plastic Surgery and Reconstruction, Faculty of Medicine, Universitas Padjadjaran - Dr. Hasan Sadikin Hospital, Bandung, Indonesia

Correspondence: Kartika Ruchiatan, Department of Dermatology and Venereology, Faculty of Medicine, Universitas Padjadjaran - Dr. Hasan sadikin hospital, Jl. Pasteur 38, Bandung, West Java, 40161, Indonesia, Tel +62811247932, Email kartika.ruchiatan@unpad.ac.id

Abstract: Burn injury is a common type of trauma which causes significant morbidity and mortality. Wound healing following burns can be complicated by the formation of hypertrophic scars and the occurrence of post-inflammatory hyperpigmentation (PIH). Neodymium:yttrium aluminum garnet (Nd:YAG) laser might become one of the treatments of choice for hypertrophic scars and PIH. We report a case of post-burn hypertrophic scars and hyperpigmentation in a 20-year-old man. The patient was consulted from the Department of Plastic Surgery and Reconstruction after scar revision. He was treated with 1064 nm long-pulsed Nd:YAG laser therapy, spot size 6 mm, fluence 55 J/cm², pulse duration 3 millisecond (ms), for three sessions with one month interval, followed by 1064 nm Q-switched (QS) Nd:YAG, spot size 4 mm, fluence 2.5 J/cm², frequency 2 Hz for two sessions with one month interval. Clinical improvement was observed after five sessions, characterized by scar thinning as assessed using Vancouver scar scale and increased skin tone brightness also reduced redness assessed using a spectrophotometer with no significant side effects. The management of post-burn facial scars and hyperpigmentation remains a challenge. Aside from surgery, the treatment strategy for hypertrophic scar is laser, one of which is the long-pulsed Nd:YAG laser which reduces the production of collagen. In hyperpigmented lesions, QS Nd:YAG laser destructs the melanosome. Combination of 1064 nm long-pulsed and QS Nd:YAG laser therapy provide significant improvement. These therapeutic strategies can be considered as a treatment option for post-burn hypertrophic scars and hyperpigmentation.

Keywords: hypertrophic scars, Nd:YAG laser, post-inflammatory hyperpigmentation

Introduction

Hypertrophic scars are a major complication of burns.^{1,2} Pigmentary disorders that develop in injured skin will result in dyspigmentation in the scar, rendering the scar more visible.³ Dyspigmentation usually develops after deep partial or full-thickness burns.⁴ Post-inflammatory hyperpigmentation (PIH) is a problem that persists for quite some time after the injury.³

Treatment of hypertrophic scars is aimed at relieving tension. One of the most frequently used methods is Z-plasty^{2,5} which is useful for thinning and softening scars.⁵ Another strategy for treating hypertrophic scars is light amplification by stimulated emission of radiation (laser) therapy.² The Neodymium:yttrium aluminum garnet (Nd:YAG) laser is reported to have good results in treating deep vascular diseases such as hypertrophic scars.^{6,7} It has been suggested that it acts by suppressing neovascularization in these pathological scars that are characterized by vessel overgrowth that results in nerve fibers and collagen in the reticular layer of the dermis.⁶ Nd:YAG laser is also effective for PIH.⁸⁻¹⁰ Its advantage lies in its ability to penetrate more deeply in the skin.⁸

We report a case of a 20-year-old man with post-burn hypertrophic scars and hyperpigmentation. This case report aims to present a report on the effectiveness of Nd:YAG laser as a treatment for post-burn hypertrophic scars and hyperpigmentation.

Case

A 20-year-old man was referred from the Department of Plastic Surgery and Reconstruction with chief complaint of post-burn hypertrophic scars and hyperpigmentation three months after scar revision on the face. He suffered from burn injury due to gas explosion 19 years ago. Dermatological status showed hypertrophic scars and hyperpigmented macules on his forehead, nose, cheek, perioral area, (Figure 1). He was treated with 1064 nm long-pulsed Nd:YAG laser, spot size 6 mm, fluence 55 J/cm², pulse duration 3 millisecond (ms), for three sessions with one month interval, followed with 1064 nm Q-switched Nd:YAG, spot size 4 mm, fluence 2.5 J/cm², frequency 2 Hz, for two sessions with one month interval. He received *Centella asiatica* cream for post-laser treatment. Scar thinning was assessed using Vancouver scar scale (VSS) and skin tone brightness was assessed using a spectrophotometer, both showed good improvements following laser therapy (Figure 2). In this patient, the degree of hypertrophic scar was assessed on the forehead, nose, right and left cheeks, upper lip, and chin. The patient's total VSS score was decreased from five points to four in the forehead nose, right cheek, left cheek, and upper lip area, with one point decrease in the softness parameter. In the chin area, the patient's total VSS score was decreased from seven points to five, with two points decrease each in the softness and thinning parameters. Improvement was observed in the patient's scar after three administrations of laser therapy, as indicated by thinning and softening, without any significant side effects. Based on the results of the spectrophotometer examination as shown on Table 1, the patient's skin became brighter with increased L* value and reduced redness with decreased a* value in all areas of his face. Improvement was observed after five sessions of laser treatment and the patient also feels satisfied. There were no significant side effects.

Discussion

Burn injury is a significant cause of morbidity and mortality worldwide which also affects the patients' mental health and quality of life.³ Trauma caused by burn injury can develop into scar.¹¹ The prevalence of post-burn hypertrophic scars varies from 32% to 72%.² Hypertrophic scar is a common pathologic scar that develops after burn trauma¹ and becomes the main complication of burn. Risk factors that contribute to the development of hypertrophic scar are the wound's depth, skin color, and wound healing time.² Wound healing consists of four phases, namely coagulation, inflammation, proliferation, and remodeling.¹² Recent research suggested that lasers can be an option over surgery in minimizing the appearance of scars.¹³ Hypertrophic scar responded well to laser therapy.⁶

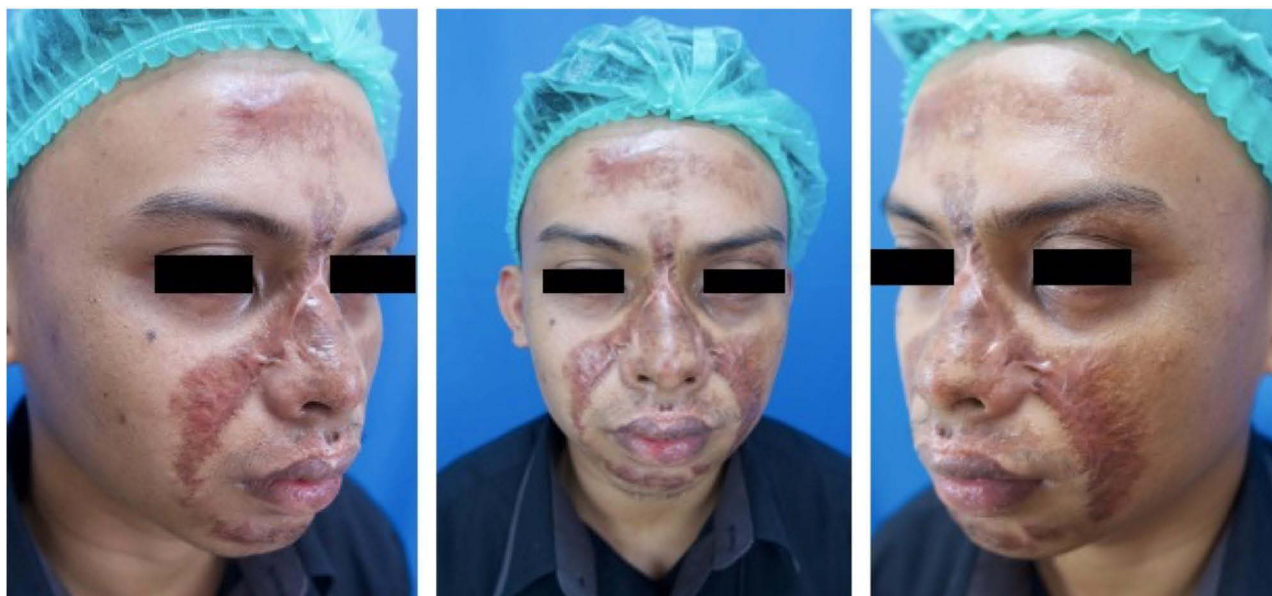

Figure 1 The patient's clinical photograph at the first visit.

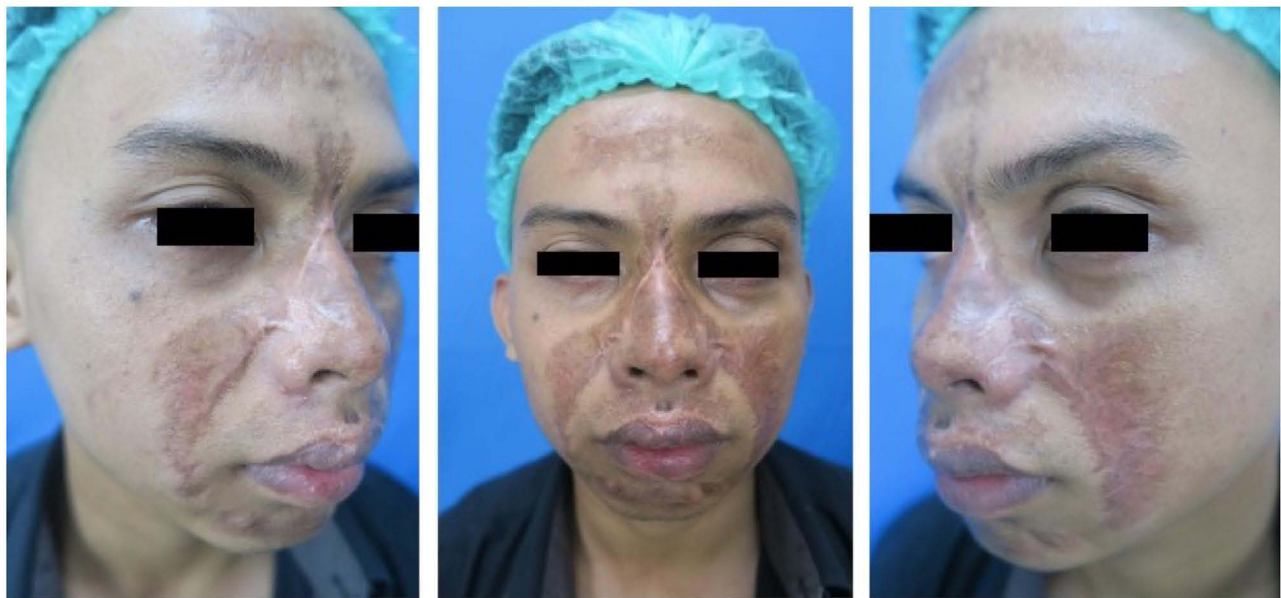


Figure 2 Improvement observed 5 months following laser therapy.

Laser is a coherent monochromatic light source with high intensity.⁸ Laser parameters include wavelength, fluence, pulse duration, and spot size, all of which are adjustable for delivering energy to the skin safely in order to achieve the desirable therapeutic effect.¹⁴ The depth achieved is determined by spot size, laser power, and fluence. The bigger the spot size and fluence, the deeper the laser can get through.⁶ One of the laser used on hypertrophic scar is non-ablative laser, such as Nd:YAG.¹³ Mohamady et al¹³ concluded that the use of long-pulsed Nd:YAG laser showed good results in treating scars by reducing the production of collagen. Our patient's hypertrophic scars were treated with 1064 nm long-pulsed Nd:YAG laser, with spot size 6 mm, fluence 55 J/cm², pulse duration 3 ms, and erythema endpoint for three sessions with one month interval. The Vancouver scar scale (VSS) is a useful assessment for grading scar to evaluate the risk of scar development and evaluate therapeutic response. Parameters assessed on VSS are pigmentation, vascular, softness, and the scar's height.¹⁵

Disruption of normal melanogenesis in injured skin can render the dyspigmentation of scar more visible. Scars with dyspigmentation are an undesirable effect of skin wound healing and become a risk for every individual worldwide.³ To date, hyperpigmentation remains a challenge for doctors due to the lack of definite treatment choices.^{3,8} Laser therapy can provide a good and satisfying result in PIH cases but requires several sessions, especially if the affected area is extensive. Melanosome is broken down by laser, preventing further melanogenesis, and melanin transfer.³ Cho et al¹⁰ conducted a study related to PIH treated with a QS Nd:YAG laser. In our patients, the hyperpigmentation was treated with 1064 nm QS Nd:YAG laser, spot size 4 mm, fluence 2.5 J/cm², frequency 2 Hz, and erythema endpoint for two

Table 1 Spectrophotometer Before and After 5 Months Following Laser Therapy

	L*		a*	
	Before	After	Before	After
Forehead	44.80	46.34	13.60	10.33
Nose	31.80	34.21	12.63	11.97
Right cheek	41.89	43.12	14.72	13.88
Left cheek	38.56	41.32	14.40	12.75
Chin	47.14	48.24	13.06	10.85

Notes: L* (luminance: black and white) to assess the level of skin brightness, a* (green and red) to assess erythema which will increase if erythema occurs.

sessions with one month interval. To assess the therapeutic response in pigmentary disorders, it is necessary to evaluate color changes with a spectrophotometer.¹⁶ Three parameters are assessed objective in the spectrophotometer examination, namely: L* (luminance: black and white) to assess the level of skin brightness, a* (green and red) to assess erythema which will increase if erythema occurs, and b* (blue and yellow) to assess hyperpigmentation disorders.^{16,17}

Conclusion

In post-burn cases, wound healing may result in hypertrophic scars and post-inflammatory hyperpigmentation. This case showed clinical improvement after five sessions laser therapy, characterized by scar thinning, increased skin tone brightness, and reduced redness with no significant side effects. Combination of 1064 nm long-pulsed and QS Nd: YAG laser may be considered as treatment of choice for these lesions.

Consent for Publication

The patient has signed the consent forms for the use of case details, images for publication, and for scientific purposes. Institutional approval from The Research Ethic Committee of Dr. Hasan Sadikin General Hospital Bandung, Indonesia has been obtained to publish the case details (approval number: LB.02.01/X.6.5/363/2021).

Acknowledgments

The authors would like to thank the staff of Department of Dermatology and Venereology, Faculty of Medicine, Universitas Padjadjaran, Bandung, West Java, Indonesia.

Funding

The authors declare that this study has received no financial support.

Disclosure

The authors report no conflicts of interest in this work.

References

1. Finnerty CC, Jeschke MG, Branski LK, Barret P, Dziewulski P, Herndon DN. Hypertrophic scarring: the greatest unmet challenge following burn injury. *Lancet*. 2016;388:1427–1436. doi:10.1016/S0140-6736(16)31406-4
2. Levi B, Wang S. Burns. In: Kang S, Amagai M, Bruckner AL, Enk AH, Margolis DJ, McMichael AJ, editors. *Fitzpatrick's Dermatology in General Medicine*. 9th ed. New York: McGraw-Hill; 2019:1679–1691.
3. Chadwick S, Heath R, Shah M. Abnormal pigmentation within cutaneous scars: a complication of wound healing. *Indian J Plast Surg*. 2012;45(2):403–411. doi:10.4103/0970-0358.101328
4. Tyack ZF, Pegg S, Ziviani J. Postburn dyspigmentation: its assessment, management, and relationship to scarring – a review of the literature. *J Burn Care Rehabil*. 2017;18:435–440. doi:10.1097/00004630-199709000-00012
5. Donelan MB, Parrett BM, Sheridan RL. Pulsed dye laser therapy and Z-plasty for facial burn scars - the alternative to excision. *Ann Plast Surg*. 2008;60(5):480–486. doi:10.1097/SAP.0b013e31816fcad5
6. Koike S, Akaishi S, Nagashima Y, Dohi T, Hyakusoku H, Ogawa R. Nd:YAG laser treatment for keloids and hypertrophic scars: an analysis of 102 cases. *Plast Reconstr Surg Glob*. 2014;2:1–9.
7. Ogawa R. Long-pulsed 1064 nm Nd: YAG laser treatment for keloids and hypertrophic scars. In: *Textbook on Scar Management*. Cham: Springer; 2020:271–278.
8. Arora P, Sarkar R, Garg VK, Arya L. Lasers for treatment of melasma and post-inflammatory hyperpigmentation. *J Cutan Aesthet Surg*. 2012;5(2):93–103. doi:10.4103/0974-2077.99436
9. Orringer JS. Nonablative laser and light-based therapy: cosmetic and medical indications. In: Kang S, Amagai M, Bruckner AL, Enk AH, Margolis DJ, McMichael AJ, editors. *Fitzpatrick's Dermatology in General Medicine*. New York: McGraw-Hill; 2019:3846–3854.
10. Cho S, Park S, Kim J, Kim M, Bu T. Treatment of post-inflammatory hyperpigmentation using 1064-nm Q-switched Nd:YAG laser with low fluence: report of three cases. *J Eur Acad Dermatol Venereol*. 2009;23(10):1206–1207. doi:10.1111/j.1468-3083.2009.03123.x
11. Aarabi S, Longaker MT, Gurtner GC. Hypertrophic scar formation following burns and trauma: new approaches to treatment. *PLoS Med*. 2007;4(9):1464–1470. doi:10.1371/journal.pmed.0040234
12. Alavi A, Kirsner RS. Wound healing. In: Kang S, Amagai M, Bruckner AL, Enk AH, Margolis DJ, McMichael AJ, editors. *Fitzpatrick's Dermatology in General Medicine*. 9th ed. New York: McGraw-Hill; 2019:2700–2717.
13. Al-Mohamady AE, Ibrahim SM, Muhammad MM. Pulsed dye laser versus long pulsed Nd:YAG laser in the treatment of hypertrophic scars and keloid: a comparative randomized split-scar trial. *J Cosmet Laser Ther*. 2016;18:208–212.
14. Ibrahim O, Dover JS. Fundamentals of laser and light-based treatments. In: Kang S, Amagai M, Bruckner AL, Enk AH, Margolis DJ, McMichael AJ, editors. *Fitzpatrick's Dermatology in General Medicine*. 9th ed. New York: McGraw-Hill; 2019:3820–3833.

15. Thompson CM, Sood RF, Honari S, Carrouger GJ, Gibran NS. What score on the Vancouver Scar Scale constitutes a hypertrophic scar? Results from a survey of North American burn-care providers. *Burns*. 2015;41(7):1442–1448. doi:10.1016/j.burns.2015.04.018
16. Ly BC, Dyer EB, Feig JL, Chien AL, Del Bino S. Research techniques made simple: cutaneous colorimetry: a reliable technique for objective skin color measurement. *J Invest Dermatol*. 2020;140(1):3–12. doi:10.1016/j.jid.2019.11.003
17. Taylor S, Westerhof W, Im S, Lim J. Non-invasive techniques for the evaluation of skin colour. *J Am Acad Dermatol*. 2006;54:282–290. doi:10.1016/j.jaad.2005.12.041

International Medical Case Reports Journal

Dovepress

Publish your work in this journal

The International Medical Case Reports Journal is an international, peer-reviewed open-access journal publishing original case reports from all medical specialties. Previously unpublished medical posters are also accepted relating to any area of clinical or preclinical science. Submissions should not normally exceed 2,000 words or 4 published pages including figures, diagrams and references. The manuscript management system is completely online and includes a very quick and fair peer-review system, which is all easy to use. Visit <http://www.dovepress.com/testimonials.php> to read real quotes from published authors.

Submit your manuscript here: <https://www.dovepress.com/international-medical-case-reports-journal-journal>