

# Reconstruction of “unreconstructable” critical limb ischemia with hybrid techniques

John R. Power, BA, Christine Chung, MD, Paul S. Lajos, MD, Peter L. Faries, MD, Michael L. Marin, MD, and Rami O. Tadros, MD, *New York, NY*

This case describes the surgical repair of critical limb ischemia in a patient with diffuse multilevel peripheral arterial disease. It demonstrates the value of patient-specific approaches that employ hybrid endovascular and open surgical techniques to reconstruct blood flow in patients who are not ideal candidates for traditional revascularization. We detail a technique that combines endarterectomy, femoropopliteal bypass, angioplasty, and stenting. This case suggests that innovative hybrid approaches can be used to achieve limb salvage in some patients with multilevel peripheral vascular disease who would otherwise undergo primary amputation. (*J Vasc Surg Cases* 2016;2:10-3.)

As the global population ages and prevalence of cardiovascular disease rises, critical limb ischemia (CLI) is anticipated to be a growing problem.<sup>1</sup> A cause of high morbidity, CLI can result in major amputation should revascularization prove impossible. Fortunately, modern vascular surgeons have at their disposal a bevy of endovascular techniques that have revolutionized the treatment of peripheral arterial disease.<sup>2,3</sup> Correctly applied, these endovascular techniques can facilitate revascularization with lower morbidity and mortality than in open procedures.<sup>4</sup> However, isolated surgical or endovascular treatments are suboptimal for a small subset of patients who are not candidates. Hybridizing surgical and percutaneous procedures may offer improved options for limb salvage.

This case describes the application of open and endovascular techniques to revascularize the right lower extremity (RLE) of a patient with CLI. Initially, an outside institution had recommended that the patient undergo a primary amputation. After a second opinion, a hybrid approach aimed at limb salvage was performed. After revascularization, the patient needed only a partial hallux amputation instead of a major amputation. The patient described in this case report has consented to publication of this manuscript.

From the Division of Vascular Surgery, Department of Surgery, The Icahn School of Medicine at Mount Sinai.

Author conflict of interest: M.M. has been paid a consulting fee by Gore. Correspondence: Rami O. Tadros, MD, Division of Vascular Surgery, Department of Surgery, The Icahn School of Medicine at Mount Sinai, 1425 Madison Ave, 4th Fl, New York, NY 10029 (e-mail: [rami.tadros@mountsinai.org](mailto:rami.tadros@mountsinai.org)).

The editors and reviewers of this article have no relevant financial relationships to disclose per the Journal policy that requires reviewers to decline review of any manuscript for which they may have a conflict of interest.

2352-667X

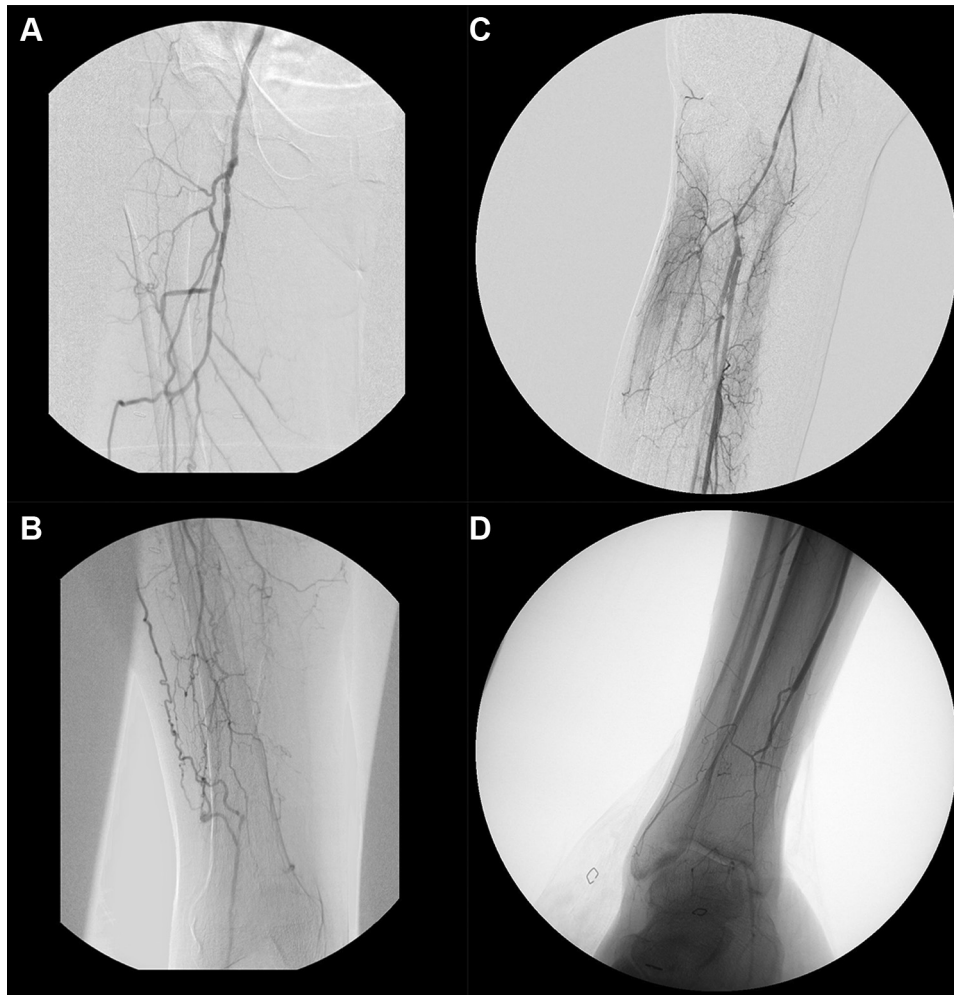
Copyright © 2016 The Authors. Published by Elsevier Inc. on behalf of the Society for Vascular Surgery. This is an open access article under the CC BY-NC-ND license (<http://creativecommons.org/licenses/by-nc-nd/4.0/>).

<http://dx.doi.org/10.1016/j.jvsc.2016.01.001>

## CASE REPORT

A 55-year-old woman with a history of sarcoidosis, hypertension, hyperlipidemia, and a 40-pack-year smoking history presented with right first toe gangrene and 1 month of progressive RLE rest pain. Examination demonstrated a weak right femoral pulse with absent popliteal, dorsalis pedis, and posterior tibial (PT) pulses. RLE ankle-brachial index was measured to be 0.74, but pulse volume recording suggested severely decreased perfusion at the metatarsal level. Evaluation of the right foot revealed interdigital ulceration between the first and second toes and a first toe ulcer with early distal gangrene. RLE angiography revealed severe multilevel peripheral arterial occlusive disease (Fig 1). A flush chronic total occlusion extending the entire length of the superficial femoral artery prevented a percutaneous attempt at revascularization. Reconstitution of the popliteal artery below the knee was seen, although it was diffusely stenosed along its length. Furthermore, there was a chronic total occlusion of the entire anterior tibial artery, the peroneal artery below the midcalf, and the PT artery from the distal calf to the ankle joint with collateralization of the plantar arc. Vein mapping revealed that the saphenous and upper extremity veins were inadequate for use as a bypass conduit. Whereas pedal bypass with a distal vein patch or arteriovenous fistula was considered, it was deemed unlikely to succeed, given the distal location of the outflow and the lack of autogenous conduit. Furthermore, the patient was very thin, and tissue cover was a concern because of increased risk for complications such as wound breakdown and surgical site infection, especially in the setting of prosthetic conduit.

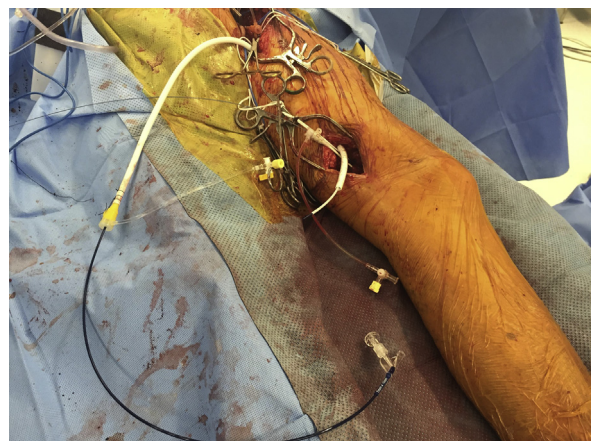**Surgical technique.** Femoral and above-knee popliteal cut-downs were performed. The popliteal artery was directly accessed and a 5F vascular sheath was placed. The popliteal artery and tibioperoneal trunk stenoses were traversed. A Quick-Cross catheter (Spectranetics, Colorado Springs, Colo) and Whisper guidewire (Abbott, Chicago, Ill) were used to cross the peroneal and PT occlusions. This allowed angioplasty of the peroneal artery and PT artery with 2.5-mm balloons over a 0.014-inch ASAHI Grand Slam guidewire (Abbott). An intraoperative angiogram showed patent vessels with improved outflow to the foot. Next, an exchange was made for a 7F sheath over a Bentson guidewire. Then, a 6- × 80-mm ringed Propaten (Gore, Newark, Del)



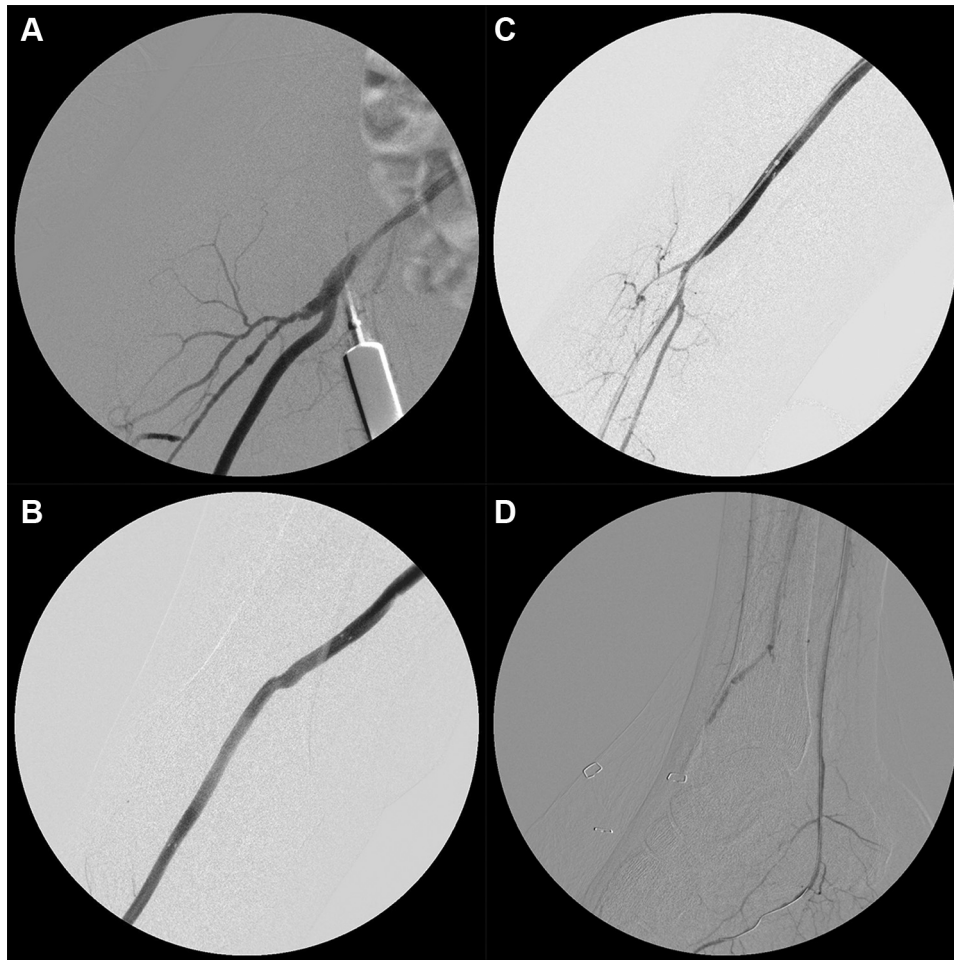
**Fig 1.** Preoperative right lower extremity (RLE) angiograms. **A**, Groin; **B**, Femur; **C**, Knee; **D**, Ankle.

polytetrafluoroethylene (PTFE) graft was tunneled from the femoral to the popliteal incision using a Kelly-Wick tunneler (Bard, Murray Hill, NJ). An 11F sheath was connected to the proximal end of the graft and secured with several 0 silk ties. Through this, a 7- × 10-cm Viabahn stent graft (Gore) was positioned through the bypass graft and placed outside the diffusely diseased popliteal artery (**Fig 2**).

The 0.035-inch wire in the popliteal artery was back-loaded into the Viabahn, and the Viabahn was advanced through the popliteal artery such that it was both in the popliteal artery and partially within the tunneled PTFE graft. This stent graft was deployed and angioplastied throughout to 6 mm. Several interrupted 6-0 Prolene sutures were then used to secure the PTFE graft to the popliteal artery. Care was taken to avoid puncture of the Viabahn as the PTFE coat is thin, making hemostasis difficult. Next, femoral endarterectomy was performed with patch angioplasty. The proximal graft was then sewn in a standard fashion to the patch. Completion angiography demonstrated excellent inflow with inline flow to the popliteal artery with a patent PTFE graft-popliteal Viabahn stent graft.



**Fig 2.** This representative image from a similar case illustrates the technique of loading a Viabahn stent graft through a tunneled polytetrafluoroethylene (PTFE) bypass conduit.



**Fig 3.** Completion right lower extremity (RLE) angiograms. **A**, Groin; **B**, Femur; **C**, Knee; **D**, Ankle.

The previously stenosed tibioperoneal trunk and the previously occluded PT and peroneal arteries were now patent with direct flow to the foot (Fig 3). Total anesthesia time was 6 hours and 3 minutes. The patient was discharged 3 days postoperatively with aspirin, clopidogrel (Plavix), and home physical therapy.

One week after discharge, the patient presented with RLE foot pain. On inspection, the RLE was warm with no signs or symptoms of infection or ischemia. The PT pulse was 2+ palpable. Confirmatory computed tomographic angiography showed a patent bypass with inline flow through the PT artery to the right foot. The peroneal artery also appeared patent.

Two weeks after discharge, she underwent a successful partial right hallux amputation, which later fully healed. Five weeks after operation, the ankle-brachial index was 0.89 in the RLE, and the pulse volume recording suggested only mild decrease in arterial perfusion. Duplex ultrasonography demonstrated a patent right PT artery. Wounds were healing expectedly.

## DISCUSSION

This case demonstrates the importance of combined expertise in endovascular and open surgical procedures

when treating CLI. Alternatives such as amputation and pedal bypass would have resulted in increased morbidity and risk for complications, respectively. Although patients with CLI often have comorbidities that decrease tolerance for open surgery, a purely endovascular approach was impossible in this case because of long-segment occlusion and flush occlusion at the popliteal and superficial femoral artery, established risk factors for technical failure.<sup>5,6</sup> Moreover, lower extremity bypass has been shown to be associated with improved amputation-free survival and overall survival compared with balloon angioplasty.<sup>2,7,8</sup> Whereas this patient's relatively good health and young age reinforced the indication for an open bypass procedure, a traditional approach was not optimal in the absence of venous conduit and adequate tissue cover at the PT artery. Instead, inflow was optimized with an endarterectomy as femoral endarterectomy has high technical success and durability with little morbidity.<sup>9</sup> Outflow was then optimized with angioplasty. Finally, inline flow to the leg was achieved by a bypass in conjunction with a stent graft deployed in the popliteal artery.

We chose a standard Viabahn and PTFE graft over the Gore hybrid graft because in our opinion, the Viabahn's tapered nosecone allows facilitated delivery of the stent graft. Efficient delivery was especially challenging in this case because the target vessel was small and diffusely diseased. Unlike the Viabahn, the hybrid graft is designed for venous application and has a nontapered end intended for delivery into larger, more compliant vessels. Even peel-away hybrid grafts can traumatize smaller arteries and cause bleeding or dissection, risks that we did not want to take in the diffusely diseased popliteal artery.

Although the described surgical technique was successful in this case, it is applicable only to a subset of pedal bypass candidates in whom stenosis of the PT artery and popliteal artery is limited enough for angioplasty to be successful. Furthermore, the Viabahn and PTFE graft described in this paper is optimal only in those patients in whom autologous venous conduit is unavailable.

## CONCLUSIONS

Although standard revascularization techniques remain a good option, select patients with CLI may benefit from innovative revascularization strategies similar to the one described in this report. For this cohort, hybrid approaches tailored to the patient's disease distribution can enable limb salvage and minimize complications. During these cases, maintaining the tenants of inflow, outflow, and conduit is indispensable.<sup>10</sup>

## REFERENCES

1. Burns P, Gough S, Bradbury AW. Management of peripheral arterial disease in primary care. *BMJ* 2003;326:584-8.

2. Liberati A, Altman DG, Tetzlaff J, Mulrow C, Gotzsche PC, Ioannidis JP, et al. The PRISMA statement for reporting systematic reviews and meta-analyses of studies that evaluate healthcare interventions: explanation and elaboration. *BMJ* 2009;339:b2700.
3. Ansel GM, Lumsden AB. Evolving modalities for femoropopliteal interventions. *J Endovasc Ther* 2009;16(Suppl 2):II82-97.
4. Rogers JH, Laird JR. Overview of new technologies for lower extremity revascularization. *Circulation* 2007;116:2072-85.
5. Bechara CF, Barshes NR, Pisimisis G, Bates JT, Lin PH, Kougiaris P. Short- and midterm results of iliac artery stenting for flush occlusion with the assistance of an occlusive contralateral iliac artery balloon. *Ann Vasc Surg* 2014;28:59-64.
6. Krishnamurthy VN, Eliason JL, Henke PK, Rectenwald JE. Intravascular ultrasound-guided true lumen reentry device for recanalization of unilateral chronic total occlusion of iliac arteries: technique and follow-up. *Ann Vasc Surg* 2010;24:487-97.
7. Bradbury AW, Adam DJ, Bell J, Forbes JF, Fowkes FG, Gillespie I, et al; BASIL Trial Participants. Bypass versus Angioplasty in Severe Ischaemia of the Leg (BASIL) trial: an intention-to-treat analysis of amputation-free and overall survival in patients randomized to a bypass surgery-first or a balloon angioplasty-first revascularization strategy [erratum in: *J Vasc Surg* 2010;52:1751. Bhattacharya, V (corrected to Bhattacharya, V)]. *J Vasc Surg* 2010;51(Suppl):5S-17S.
8. Bradbury AW, Adam DJ, Bell J, Forbes JF, Fowkes FG, Gillespie I, et al. Multicentre randomised controlled trial of the clinical and cost-effectiveness of a bypass-surgery-first versus a balloon-angioplasty-first revascularisation strategy for severe limb ischaemia due to infrainguinal disease. The Bypass versus Angioplasty in Severe Ischaemia of the Leg (BASIL) trial. *Health Technol Assess* 2010;14:1-210. iii-iv.
9. Nishibe T, Maruno K, Iwahori A, Fujiyoshi T, Suzuki S, Takahashi S, et al. The role of common femoral artery endarterectomy in the endovascular era. *Ann Vasc Surg* 2015;29:1501-7.
10. Aho PS, Venermo M. Hybrid procedures as a novel technique in the treatment of critical limb ischemia. *Scand J Surg* 2012;101:107-13.

Submitted Oct 21, 2015; accepted Jan 14, 2016.