

Primary clear cell adenocarcinoma of prostate: A diagnostic challenge

Che-Wei Chang^{1,2,3}, Hsin-Ling Yin⁴, Ching-Chia Li^{2,3,5}

¹Department of Urology, Kaohsiung Municipal Siaogang Hospital, Departments of ²Urology and ⁴Pathology, Kaohsiung Medical University Hospital, ³Department of Urology, School of Medicine, College of Medicine, Kaohsiung Medical University, ⁵Department of Graduate Institute of Clinical Medicine, College of Medicine, Kaohsiung Medical University, Kaohsiung, Taiwan

Abstract

Clear cell adenocarcinoma (CCA) rarely occurs in men, not to mention in prostate. We reported a 44-year-old male patient who suffered from recurrent dysuria and frequency for 6 months. Transurethral resection of the prostate was performed to relieve bladder outlet obstruction. However, CCA of the prostate was confirmed through pathological examination. A thorough checkup was performed to distinguish it from metastatic clear cell carcinoma from other primary origins. Currently, no consensus for the treatment of CCA of the prostate has been reached. After discussing with the patient, he decided to receive immunotherapy with pembrolizumab. Herein, we reported this rare case of CCA in the prostate.

Keywords: Clear cell adenocarcinoma, immunotherapy, prostate

Address for correspondence: Dr. Ching-Chia Li, Department of Urology, School of Medicine, College of Medicine, Kaohsiung Medical University, Kaohsiung, Taiwan.

E-mail: u101000011@gap.kmu.edu.tw

Received: 21.12.2020, **Accepted:** 07.04.2021, **Published:** 02.09.2021

INTRODUCTION

Clear cell adenocarcinoma (CCA) usually presents in female genital tracts with a poor prognosis. In men, CCA is an extremely rare tumor that resembles prostate adenocarcinoma, metastatic clear cell renal cell carcinoma (CCRCC), and renal-type clear cell carcinoma (RTCCC). Typical complaints include urinary retention, gross hematuria, and urinary tract infection. Herein, we presented a rare case of CCA in the prostate which was the second documented case in the English literature.

CASE REPORT

A 44-year-old man without any underlying diseases suffered from dysuria and frequency for several months.

He first went to a local hospital for help where pelvic computed tomography, transurethral resection of the prostate, and cystostomy were done. The pelvic computed tomography revealed an enlarged prostate with heterogeneous densities and abscess formation [Figure 1]. He was then referred to our hospital for a second opinion. In the outpatient department, digital rectal examination showed marked enlargement with bilateral firmness. Prostate-specific antigen level was 2.81 ng/mL. Thus, magnetic resonance image examination was done, and it showed T2WI increasing signal intensity over prostate mass lesion with urinary bladder invasion and metastatic lymphadenopathy at bilateral internal iliac, external iliac, and the para-aortic spaces [Figure 2]. The bone scan indicated a low probability of metastasis. A thorough

This is an open access journal, and articles are distributed under the terms of the Creative Commons Attribution-NonCommercial-ShareAlike 4.0 License, which allows others to remix, tweak, and build upon the work non-commercially, as long as appropriate credit is given and the new creations are licensed under the identical terms.

For reprints contact: WKHLRPMedknow_reprints@wolterskluwer.com

How to cite this article: Chang CW, Yin HL, Li CC. Primary clear cell adenocarcinoma of prostate: A diagnostic challenge. *Urol Ann* 2021;13:434-7.

Access this article online	
Quick Response Code:	Website: www.urologyannals.com
	DOI: 10.4103/UA.UA_187_20

review of radiologic imaging studies did not reveal the presence of renal tumor. Therefore, the impression and clinical stage of this patient would be prostate CCA, T4N1M1a, stage IVB.

Nevertheless, a repeated transurethral biopsy was suggested. The cystoscopy was done, and it revealed a necrotic prostate mass with bladder invasion [Figure 3]. The resected specimen measured 1.6 cm × 0.4 cm × 0.3 cm in size and 20.4 g in weight. Grossly, it was grayish and elastic. A microscopic examination revealed tubulocystic or papillary structures lined by cuboidal or hobnail cells with clear to eosinophilic cytoplasm [Figure 4]. The immunohistochemical study suggested negative staining of prostate-specific antigen (PSA) (-), P501S (-), and GATA-3 (-) but positive staining of paired box 8 (PAX-8) (+), CD10 (+), and AMACR (+) [Figure 5].

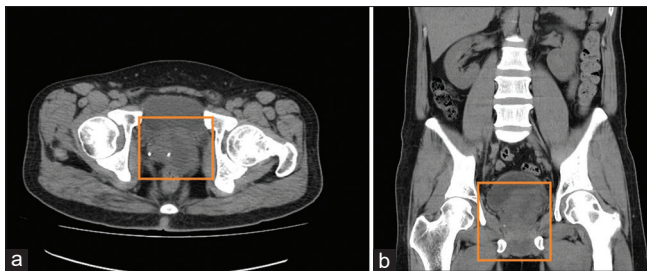


Figure 1: Computed tomography. A computed tomography image reveals prostate enlargement with calcification and heterogeneous enhancement rule out abscess and prostate cancer. (a) transverse view and (b) coronal view

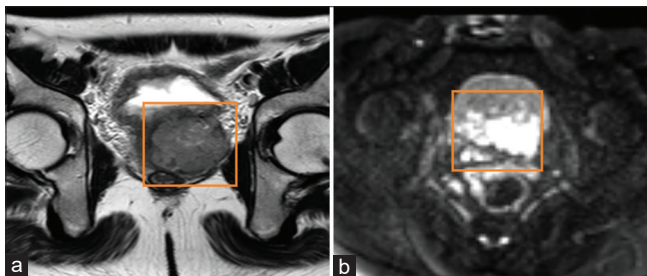


Figure 2: Magnetic resonance image: mass lesion beneath the urinary bladder and suspicious invasion of the seminal vesical. (a) T2 weighted and (b) diffuse-weighted imaging

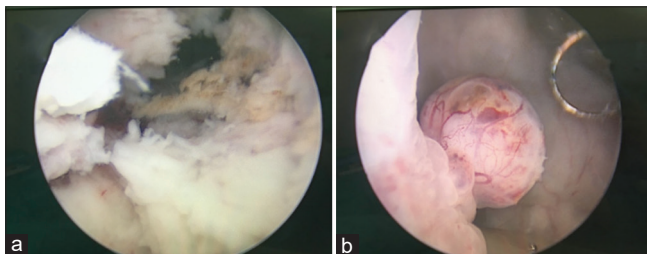


Figure 3: Transurethral resection of prostate. Pale and necrotic tissue over prostate urethral (a), a hypervascular mass over right bladder neck (b)

The patient chose immunotherapy as the subsequent treatment because of the advanced stage of CCA based on pathologic similarities of metastatic CCRCC. Hence, he received two courses of anti-progressive disease (PD)-1 antibody, pembrolizumab. Nevertheless, the disease progressed rapidly as the lung and bone metastases were discovered after 4 months of treatment. He died 10 months after the diagnosis.

DISCUSSION

CCA usually presents in female genitourinary tracts such as diverticulum but rarely occurs in male.^[1] Most of the previous cases of CCA were found in urinary bladder, testis, and urethra.^[1-3] However, the prostate origin of CCA is an even rarer histologic diagnosis. To the best of our knowledge, there was only one case documented on PubMed.^[4] We also reviewed other cases of CCA in men, listed in Table 1.^[4-12]

It could be easily misdiagnosed with CCRCC^[13,14] and RTCCC.^[15] Since these tumors have similar histopathological characteristics, it is difficult to differentiate based on clinical and laboratory tests.

To confirm the diagnosis of CCA, tissue proof is extremely important. Most of the previous cases showed negative staining of PSA except one positive for PSA^[10] and two showed positive for PAX-8.^[4,12]

PAX-8, a transcription factor, is a marker that indicates the differentiation of the tumor from kidney, thyroid, and Mullerian origin. According to a previous literature review, PAX-8 seems to be negative in RTCCC and in CCRCC.^[15] Thus, it is a crucial marker to distinguish CCA from these two types of tumors.

As for PSA, most of the cases have negative staining of PSA except one case^[10] and all the cases have normal serum PSA levels. This indicates that CCA is different from typical prostate adenocarcinoma.

In our case, immunostaining for GATA-3 was negative, which indicated that it did not originate from urothelial or neuroendocrine cells. In addition, the immunohistochemical staining did show positive staining of AMACR (P504S), confirming the prostate origin.

To date, there has been no standard treatment of CCA because of its scarce clinical evidence. However, if it is confined to local or regional area, radical cystoprostatectomy with ileal conduit is an option. However for metastatic diseases, there is no definite treatment. One of the cases

Table 1: Clinical summaries of reported clear cell adenocarcinoma in men

Author	Age (years)	Symptoms	Serum PSA at diagnosis	Location	IHC	Treatment	Follow-up (months)
Present case (2020)	44	LUTs	2.81 (ng/mL)	Prostate	Positive: PAX-8, CD 10, AMACR Negative: PSA, P501S, GATA-3	TUR-P, immunotherapy-pembrolizumab	DOD (10)
Cantrell <i>et al.</i> (1981)	68	Gross hematuria	N/A	Urethra	N/A	Radiation	DOD (28) with lung metastasis
Olivia <i>et al.</i> (1996)	N/A	Urinary retention	N/A	N/A	N/A	N/A	N/A
Seske <i>et al.</i> (2001)	57	Urinary retention	N/A	Urethra	N/A	Urethrectomy	DOD (29)
Gogus <i>et al.</i> (2003)	44	Urinary retention	0.15 (ng/mL)	Bladder neck-urethra	N/A	Radical CP + PLND, followed by chemotherapy	DOD (10)
Sun <i>et al.</i> (2008)	69	Dysuria, hematuria	WNL	Bladder	Positive: AMACR, LMWCK, K903 Negative: p63	TUR-P	N/A
Gandhi <i>et al.</i> (2012)	55	Urinary tract infection	0.4 (ng/ml)	Membranous, bulbous and penile	Positive: PSA, PSAP and CA-125 Negative: p63, CK20	radical CP + PLND	N/A
Klaassen <i>et al.</i> (2014)	42	Gross hematuria	0.18 (ng/mL)	Prostate	Positive: LMWCK, PAX-8 Negative: PSA, CD-20, CEA, p63	Radical CP + PLND, followed by PLND and urethrectomy	PD (3) with LN and local recurrence
Lewis <i>et al.</i> (2015)	36	LUTs	N/A	Prostatic urethra	N/A	Brachytherapy	NED (10)
Sugimura <i>et al.</i> (2018)	56	Gross hematuria	0.599 (ng/ml)	Urethra	Positive: CK7, PAX-8, CK20, HMWCK Negative: p63, PSA	Radical CP + urethrectomy	NED (5)

N/A: Not applicable, LUTs: Lower urinary tract symptoms, WNL: Within normal limits, PSA: Prostate-specific antigen, TUR-P: Transurethral resection of the prostate, CP: Cystoprostatectomy, PLND: Pelvic lymph node dissection, LMWCK: Low molecular weight cytokeratin, HMWCK: High molecular-weight cytokeratin, Pan-CK: Pan cytokeratin EMA: Epithelial membrane antigen, PSAP: Prostatic specific acid phosphatase, CEA: Carcinoembryonic antigen, PLAP: Placental alkaline phosphatase, VIM: Vimentin, PAX-8: Paired box 8, NED: No evidence of disease, PD: Progressive disease, DOD: Die of disease, IHC: Immunohistochemistry

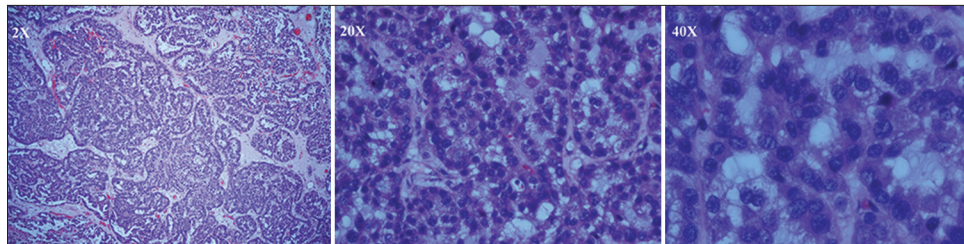


Figure 4: The H and E staining. Tubulocystic or papillary structures lined by cuboidal or hobnail cells with clear to eosinophilic cytoplasm

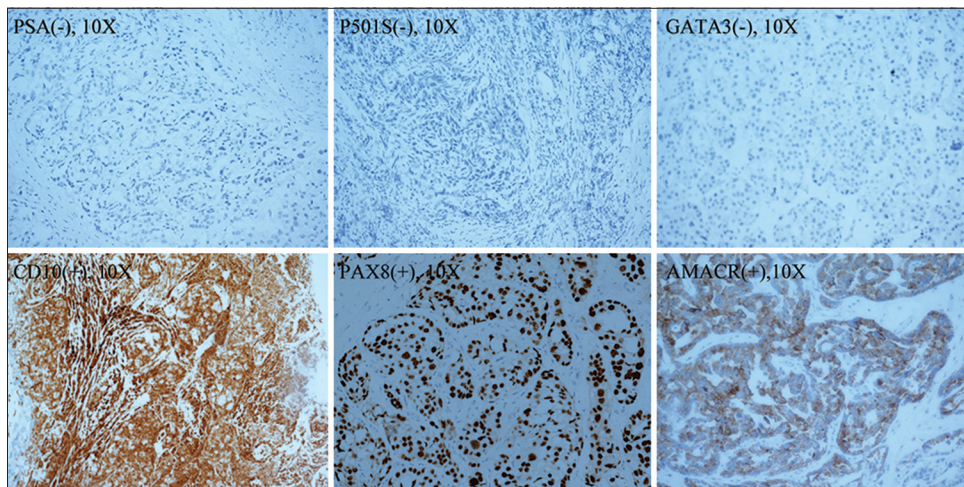


Figure 5: The immunohistochemical staining. The immunohistochemical study revealed positive findings of PAX-8 (+), CD10 (+), and AMACR(+).

received radical cystoprostatectomy with pelvic lymph node dissection but the tumor recurred afterward, so the

patient received chemotherapy^[8] and the other case received brachytherapy.^[11]

Our patient had a prostate tumor with bladder invasion and lymph node metastasis in iliac and para-aortic regions at initial diagnosis. After two courses of pembrolizumab treatment, the follow-up computed tomography suggested PD with lung and bone metastases.

The prognosis is dismal in advanced or metastatic stages at initial diagnosis according to Table 1. Further follow-up information is required to evaluate the prognosis of CCA in men.

In all, CCA in male prostate is an extremely rare cancer that could present with a normal level of PSA levels. CCRCC and RTCCC should be included in differential diagnosis; however, primary CCA of prostate should be kept in mind when no evidence of kidney lesions was found in the image study.

Informed consent

Informed consent was obtained from the patient for the publication.

Declaration of patient consent

The authors certify that they have obtained all appropriate patient consent forms. In the form, the patient has given his consent for his images and other clinical information to be reported in the journal. The patient understands that name and initials will not be published and due efforts will be made to conceal identity, but anonymity cannot be guaranteed.

Acknowledgments

The authors would like to acknowledge the Department of Pathology and the Statistical Analysis Laboratory in the Department of Medical Research at Kaohsiung Medical University Hospital.

Financial support and sponsorship

Nil.

Conflicts of interest

There are no conflicts of interest.

REFERENCES

1. Venyo AK. Clear cell adenocarcinoma of the urethra: review of the literature. *Int J Surg Oncol.* 2015;2015:790235.
2. Kosem M, Sengul E. Clear cell adenocarcinoma of the urinary bladder. *Scand J Urol Nephrol* 2005;39:89-92.
3. Lin M, Awalt H, Ayala AG, Ro JY. Clear cell carcinoma of testis: A review. *Ann Diagn Pathol* 2019;40:26-9.
4. Klaassen Z, Cleveland C, McCraw CO, Burnette JO, Franken A, Wilhelm S, *et al.* Clear cell adenocarcinoma of the prostate: A rare oncologic entity in a 42-year-old African American man. *Urology* 2014;84:997-1000.
5. Cantrell BB, Leifer G, DeKlerk DP, Eggleston JC. Papillary adenocarcinoma of the prostatic urethra with clear-cell appearance. *Cancer* 1981;48:2661-7.
6. Oliva E, Young RH. Clear cell adenocarcinoma of the urethra: A clinicopathologic analysis of 19 cases. *Mod Pathol* 1996;9:513-20.
7. Seseke F, Zoller G, Kunze E. Clear cell adenocarcinoma of the male urethra in association with so-called nephrogenic metaplasia. *Urol Int* 2001;67:104-8.
8. Göğüs C, Baltacı S, Orhan D, Yaman O. Clear cell adenocarcinoma of the male urethra. *Int J Urol* 2003;10:348-9.
9. Sun K, Huan Y, Unger PD. Clear cell adenocarcinoma of urinary bladder and urethra: Another urinary tract lesion immunoreactive for P504S. *Arch Pathol Lab Med* 2008;132:1417-22.
10. Gandhi JS, Khurana A, Tewari A, Mehta A. Clear cell adenocarcinoma of the male urethral tract. *Indian J Pathol Microbiol* 2012;55:245-7.
11. Lewis S, Pal M, Bakshi G, Ghadi YG, Menon S, Murthy V, *et al.* High-dose-rate brachytherapy – A novel treatment approach for primary clear cell adenocarcinoma of male urethra. *J Contemp Brachyther* 2015;7:248-51.
12. Sugimura R, Kawahara T, Noguchi G, Takamoto D, Izumi K, Miyoshi Y, *et al.* Clear cell adenocarcinoma of the prostatic urethra: A case report. *IJU Case Rep* 2019;2:19-22.
13. Greene GF, Gokden N, Hutchins LF, Williams RC. Metastatic renal cell carcinoma to prostate. *Urology.* 2005;65:1227.
14. Cihak RW, Haas R Jr., Koenen CT, Chinchinian H. Metastatic renal carcinoma to the prostate gland: Presentation as prostatic hypertrophy. *J Urol* 1980;123:791-2.
15. Han SI, Lim SC. Rare case of renal-type clear cell carcinoma of the prostate and review of the literature. *In vivo* 2020;34:2751-6.