

RESEARCH ARTICLE

Open Access



A new factor predicting excessive femoral anteversion in patients with recurrent patellar dislocation

Conglei Dong[†], Kuo Hao[†], Chao Zhao and Fei Wang^{*}

Abstract

Purpose: Determining a new imaging method on full-leg standing lower limb radiographs to predict excessive femoral anteversion in patients with patellar dislocation.

Methods: This study included 119 patients with patellar dislocation from January 2014 to January 2021. The femoral anteversion and tibial torsion were measured by CT scanning. The medial condylar angle was measured by the full-leg standing lower limb radiographs. Pearson correlation coefficient was used to evaluate the correlation between rotation parameters and medial condylar angle.

Results: Included patients were divided into DFO group and control group according to whether they received derotational femoral osteotomy (DFO) operation or not. DFO group had significantly higher femoral anteversion ($29.8^\circ \pm 7.2^\circ$ vs $23.1^\circ \pm 6.5^\circ$, $P < 0.05$), higher tibial torsion ($28.6^\circ \pm 6.9^\circ$ vs $24.7^\circ \pm 7.9^\circ$, $P < 0.05$), lower medial condylar angle ($154.8^\circ \pm 4.7^\circ$ vs $157.5^\circ \pm 6.7^\circ$, $P < 0.05$) than control group. Correlation analysis showed that the values of femoral anteversion were significantly correlated with medial condylar angle ($r = -0.719$, $P < 0.001$).

Conclusion: This study showed that medial condylar angle had a negative correlation with excessive femoral anteversion on the full-leg standing lower limb radiographs. The medial condylar angle can be a good predictor of femoral anteversion and can be used to guide the performance of DFO to treat patellar dislocation in clinical practice.

Keywords: Patellar dislocation, Patellar instability, Femoral anteversion, Derotational femoral osteotomy, Medial condylar angle

Introduction

Patellar dislocation is a common condition, which is often seen in children and adolescents [1]. Many factors are related to patellar dislocation, which includes anatomical factors, such as trochlear dysplasia, patellar tilt, patella alta, increased Q angle (due to femoral anteversion and tibial torsion), and generalized ligament relaxation [2–4]. Biomechanics has proved that femoral anteversion is an

independent risk factor of patellar dislocation [5]. Excessive femoral anteversion can lead to abnormal patellofemoral load and the tendency of lateral subluxation [6]. It is also a risk factor of medial patellofemoral ligament reconstruction (MPFLR) failure [7–11]. Therefore, derotational femoral osteotomy (DFO) has been considered as a better option for patellar dislocation with excessive femoral anteversion, and good clinical results have been achieved during follow-up [12].

The values of femoral anteversion is traditionally measured by computed tomography (CT) or magnetic resonance imaging (MRI) of hip, knee, and ankle joints, which extend from the anterosuperior iliac spine to toes [13]. Although there are many different measurement

[†]Conglei Dong and Kuo Hao contributed equally to this paper

*Correspondence: doctorwfei@163.com

Department of Orthopaedic Surgery, Third Hospital of Hebei Medical University, Ziqiang Road 139, Shijiazhuang 050051, Hebei, China



methods, the standard measurement of femoral anteversion angle in a healthy adult population is highly dependent on the identified markers and imaging technology used, which may lead to differences between different measurement results [14–17]. In addition, the risks of exposure to excessive and unexpected radiation and the high costs cannot be ignored [17]. Therefore, determining a new imaging method to predict excessive femoral anteversion may be beneficial for surgical treatment of patellar dislocation.

It is still unknown whether the morphology of the distal femoral condyle is related to femoral anteversion. To show this relationship, this study introduced the concept of medial condylar angle on the full-leg standing lower limb radiographs, which is a new predictive value to predict excessive femoral anteversion. Full-leg standing lower limb radiographs are the simplest and most direct imaging method for patients with patellar dislocation, which is convenient to obtain both in outpatient and ward work [18].

Therefore, this study was performed assessing the predictive role of medial condylar angle on femoral anteversion in patients with patellar dislocation on the full-leg standing lower limb radiographs. This study hypothesized that excessive femoral anteversion may lead to the decreased medial condylar angle in patients with patellar dislocation and medial condylar angle may be a guiding factor to instruct the performance of DFO to treat patellar dislocation.

Materials and methods

Patients selection

This study was approved by our Institutional Review Board, and informed written consent was obtained from all patients. The patients with patellar dislocation from January 2014 to January 2021 were analyzed retrospectively. The inclusion criteria were as follows: (1) patients who developed patellar dislocation at least once or patients with clinical and imaging diagnosis of patellar dislocation which needed surgical treatment; (2) patients with mature bones; (3) patients who had CT scans and full-leg standing lower limb radiographs within one week before the operation; (4) the interval between CT and full-leg standing lower limb radiography was within one weeks. Patients were excluded if they had traumatic dislocation, previous knee surgery, previous fractures involved knees or no appropriate imaging examination. The surgical protocol was determined by the surgeon in accordance with the medical history, physical examination, and imaging data. Among the patients who met the inclusion criteria, the patients who received DFO operation were classified as the DFO group, otherwise the control group.

Image evaluation

CT scans and full-leg standing lower limb radiographs were performed within one week before the operation as a part of preoperative planning. A CT scanner (Siemens Somatom Perspective, Germany) was used to obtain CT scans ranging from the anterosuperior iliac spine to the toes with patients in a supine position with their knees fully extended and feet facing upward. The field of view (FOV) was ranging from 220 to 450 mm, according to the size of the patients. Other parameters were as follows: tube voltage, 130kVp; Tube current, 110-140mAs; Slice thickness, 0.5 mm; Matrix, 512 × 512 pixels. The full-leg standing lower limb radiographs were taken when patients stood straight with both knees fully extended and feet facing forward, and evenly distribute their body weight between both limbs.

All measurement data were collected from the Picture Archiving and Communication System (PACS) workstation and measured by one experienced researchers blindly and randomly at the same time (CD). The mean value measured by two researchers was the final data (CD and KH). If there were abnormal values, another independent researcher would re-measure them (FW). To determine the reliability of inter-observer and intra-observer measurements, the intra-class correlation values (ICC) were calculated.

Femoral anteversion

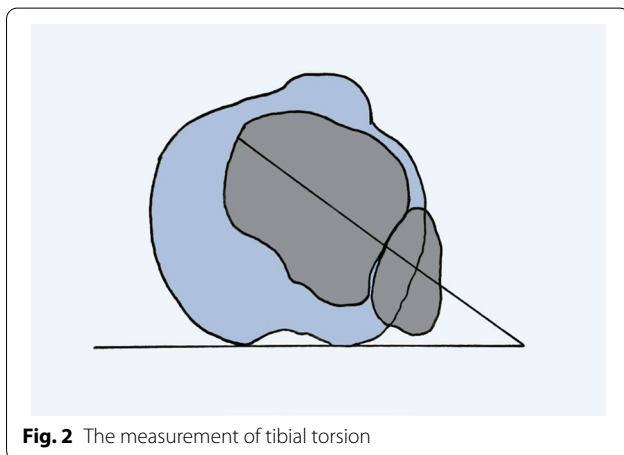
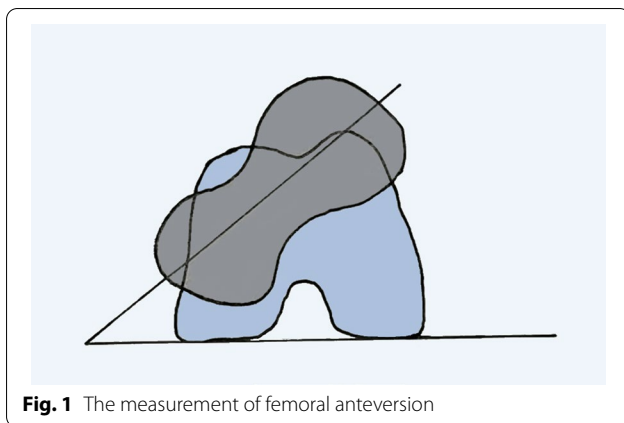
The femoral anteversion was defined as the angle between the posterior condyle line and the projection of the femoral neck axis [19]. The posterior condyle line was the line passing through the posterior point of the medial and lateral femoral condyle [19, 20]. The femoral neck axis was the line connecting the center of the femoral head and the center of the femoral neck base [20]. The positive angle indicated femoral anteversion and the negative angle referred to femoral retroversion (Fig. 1).

Tibial torsion

The tibial torsion was defined as the angle between the tangent line of posterior edge of tibial plateau and the intermalleolar axis, which was the line passing through the center of the medial and lateral malleolus [21] (Fig. 2).

Medial condylar angle

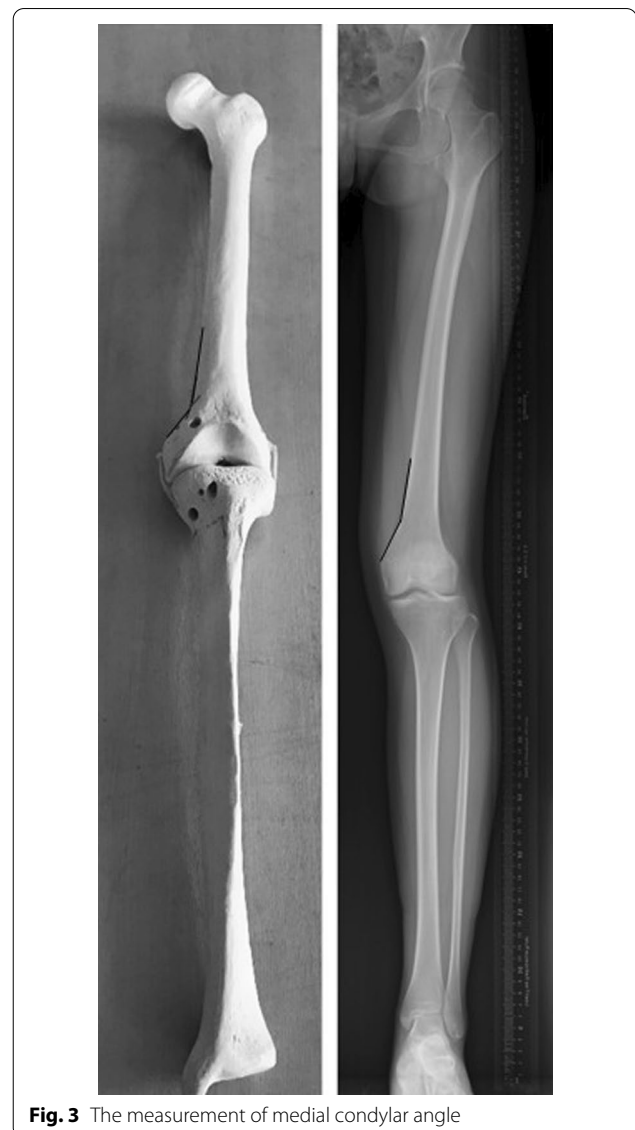The medial condylar angle was defined as the angle between a straight line along the surface of the medial femoral condyle and another straight line along the medial distal femur extending to the transition between



femoral shaft and medial femoral condyle on the full-leg standing lower limb radiographs (Fig. 3).

Statistical analysis

Descriptive analyses were presented by mean and standard deviation (SD) for continuous variables and frequencies with percentages for discrete variables. The independent-samples *t*-test was used to analyze the differences between the DFO group and the control group and Levene's test was used to examine the homogeneity of the data. Pearson correlation coefficient was used to evaluate the correlation between rotation parameters and medial condylar angle. The intra-class correlation coefficient (ICC) was calculated to evaluate the reliability of medial condylar angle. The measurement series of 30 patients (15 from the DFO group and 15 from the control group) were randomly selected and either repeated by 1 researcher at intervals of 2 weeks or independently measured by 2 different researchers. An ICC greater than 0.80 indicated good consistency. All analyses were conducted



using SPSS software (version 21.0, SPSS Inc, Armonk, NY). $P < 0.05$ was defined as statistically significant.

Results

278 patients with patellar dislocation hospitalized in our department from January 2014 to January 2021 were selected. According to the inclusion and exclusion criteria, 119 patients consisted of 41 males and 78 females were included in the study, of which 27 underwent DFO and 92 not (Fig. 4). Demographic characteristics are shown in Table 1. No significant difference in sex or age was found between the two groups ($P > 0.05$).

In the DFO group, femoral anteversion was $29.8^\circ \pm 7.2^\circ$, tibial torsion was $28.6^\circ \pm 6.9^\circ$, the medial condylar angle was $154.8^\circ \pm 4.7^\circ$. In the control group,

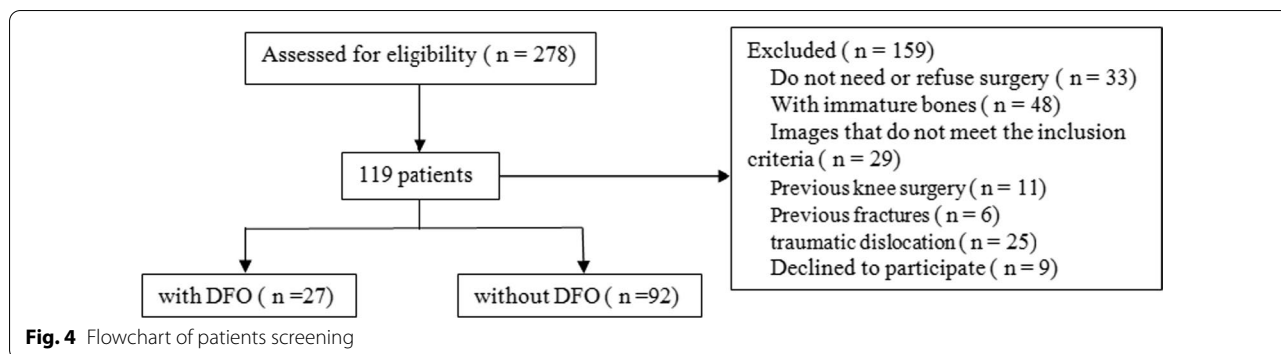


Table 1 Demographic characteristics

	DFO group	Control group	P
Gender ratio	20 women: 7 men	68 women: 24 men	>0.05
Age, y	32.9 ± 9.5	31.3 ± 9.9	>0.05
BMI	22.8 ± 2.5	23.1 ± 3.0	>0.05
Sides, n	15 left: 12 right	44 left: 48 right	>0.05

Table 2 Descriptive statistics for measurements of lower limb rotational parameters

	DFO group		Control group		P
	Mean	SD	Mean	SD	
Femoral anteversion, °	29.8	7.2	23.1	6.5	<0.05
Tibial torsion, °	28.6	6.9	24.7	7.9	<0.05
medial condylar angle, °	154.8	4.7	157.5	6.7	<0.05

SD Standard deviation

femoral anteversion was $23.1^{\circ} \pm 6.5^{\circ}$, tibial torsion was $24.7^{\circ} \pm 7.9^{\circ}$, the medial condylar angle was $157.5^{\circ} \pm 6.7^{\circ}$ (Table 2). The inter-observer and intra-observer ICC were 0.912 and 0.924 for femoral anteversion, 0.899 and 0.914 for tibial torsion, 0.925 and 0.917 for medial condylar angle, respectively. This indicated that the medial condylar angle showed a good inter-observer and intra-observer consistency.

There were significant statistical differences in femoral anteversion, tibial torsion and medial condylar angle between DFO group and control group ($P < 0.05$). This showed that there was a smaller medial condylar angle in patients undergoing DFO operation. Correlation analysis showed that the values of femoral anteversion were significantly correlated with medial condylar angle ($r = -0.719$, $P < 0.001$). However, tibial torsion ($r = 0.058$, $P = 0.334$) showed no significant correlation with the medial condylar angle.

Discussions

The most important finding in this study was to establish a new angle, which can be used to predict excessive femoral anteversion in patients with patellar dislocation. The medial condylar angle was smaller in patients undergoing DFO than control group, with statistical difference. Correlation analysis showed that the values of femoral anteversion were significantly correlated with medial condylar angle.

The femoral anteversion can be measured by MRI or CT. Although these two methods provide reliable measurement, they have some limitations, such as cost, moving artifacts, and measurement complexity. For example, CT scanning may bring disturbing radiation exposure risks, especially for young patients [17]. Botser et al. compared the measurement methods of femoral anteversion between CT and MRI. They reported that compared with MRI, the value measured by CT was larger, with an average difference of 8.9° [13]. However, due to the complex three-dimensional shape of the femur, the measurement of femoral anteversion can not be accurately obtained in the two-dimensional model, which leads to its limited value in a preoperative plan for DFO. Therefore, it is necessary to guide patients with patellar dislocation to undergo DFO by simple full-leg standing lower limb radiographs.

Although many studies measured femoral anteversion in different ways, no studies have evaluated this angle in full-leg standing lower limb radiographs of patients with patellar dislocation according to an easy-to-use imaging parameter [14, 15, 20, 21]. A smaller medial condylar angle means higher possibility of DFO operation in patients with patellar dislocation, because excessive femoral anteversion was associated with smaller medial condylar angle. Therefore, medial condylar angle can be used as an alternative method to screen patients undergoing DFO surgery. The full-leg standing lower limb radiographs may be helpful for

surgeons to clinically evaluate and screen patients who may meet the indications of DFO.

Because of the excessive femoral anteversion, the rotation of the femur leads to the morphological changes of distal femur. Due to the natural anatomical features of lower limbs, the position of medial femoral condyle in healthy individuals was in good alignment. Tear of ligament, deformity of bone structure, and other factors that may affect the force vector of the knee joint may lead to change of distal femur [20]. The disorder of internal biomechanical structure may lead to the loss of good rotational alignment of the knee joint. In patients with patellar dislocation, the rotational deformity was one of the factors, which may lead to the disorder of medial femoral condyle. In patients with mild rotational deformity, the internal ligament structure can compensate for the abnormality of bone structure, to avoid abnormal image examination and clinical symptoms.

There are some limitations to this study. Firstly, there are some errors in the measurement method of medial condylar angle. Because the transition between the distal femur and the medial femoral condyle is an arc, the medial condylar angle is only a parameter to preliminarily judge the femoral anteversion. The purpose of this study was to establish a parameter that can be easily visualized on the full-leg standing lower limb radiographs and can be used to evaluate the rotational deformity. Secondly, the parameter proposed in this study does not include all the factors that lead to the patellar dislocation, because only a few landmarks were analyzed. Further research will be conducted to analyze other factors. Third, this study is a case series study without a control group of normal knee joints without patellar instability. Although there are few patients with abnormal medial condylar angle without patellar instability, the control group may be an important assistant.

Conclusions

This study showed that medial condylar angle had a negative correlation with excessive femoral anteversion on the full-leg standing lower limb radiographs. The medial condylar angle can be a good predictor of femoral anteversion and can be used to guide the performance of DFO to treat patellar dislocation in clinical practice.

Abbreviations

DFO: Derotational femoral osteotomy; MPFLR: Medial patellofemoral ligament reconstruction; CT: Computed tomography; MRI: Magnetic resonance imaging; ICC: Intra-class correlation coefficient.

Acknowledgements

Not applicable.

Author contributions

FW contributed to the conceptualization and project administration of the study; CD performed the data analyses and manuscript preparation; KH contributed significantly to analysis and draft manuscript; CZ also made a great contribution to the article. All authors commented on previous versions of the manuscript. All authors read and approved the final manuscript.

Funding

Funded by The National Natural Science Foundation of China (Grant No.81873983).

Availability of data and materials

All of the data and materials are available.

Declarations

Ethics approval and consent to participate

This study was performed in line with the principles of the Declaration of Helsinki. Approval was granted by the Ethics Committee of Third Hospital of Hebei Medical University (Number: Z2020-051-2). Informed consent was obtained from all individual participants included in the study.

Consent for publication

All patients provided their informed consent for publication.

Competing interests

The authors declare that they have no competing interests.

Received: 20 April 2022 Accepted: 15 July 2022

Published online: 28 July 2022

References

- Atkin DM, Fithian DC, Marangi KS, et al. Characteristics of patients with primary acute lateral patellar dislocation and their recovery within the first 6 months of injury. *Am J Sports Med.* 2000;28(4):472–9. <https://doi.org/10.1177/03635465000280040601>.
- Diederichs G, Köhlitz T, Kornaropoulos E, et al. Magnetic resonance imaging analysis of rotational alignment in patients with patellar dislocations. *Am J Sports Med.* 2013;41(1):51–7. <https://doi.org/10.1177/0363546512464691>.
- Wolfe S, Varacallo M, Thomas JD, et al. Patellar Instability. StatPearls. Treasure Island (FL): StatPearls Publishing Copyright © 2021, StatPearls Publishing LLC. 2021.
- Zaffagnini S, Previtali D, Tamborini S, et al. Recurrent patellar dislocations: trochleoplasty improves the results of medial patellofemoral ligament surgery only in severe trochlear dysplasia. *Knee Surg Sports Traumatol Arthrosc Off J ESSKA.* 2019;27(11):3599–613. <https://doi.org/10.1007/s00167-019-05469-4>.
- Kaiser P, Schmoelz W, Schoettle P, et al. Increased internal femoral torsion can be regarded as a risk factor for patellar instability—a biomechanical study. *Clin Biomech (Bristol, Avon).* 2017;47:103–9. <https://doi.org/10.1016/j.clinbiomech.2017.06.007>.
- Eckhoff DG, Montgomery WK, Kilcoyne RF, et al. Femoral morphometry and anterior knee pain. *Clin Orthop Relat Res.* 1994;302:64–8.
- Nelitz M, Williams RS, Lippacher S, et al. Analysis of failure and clinical outcome after unsuccessful medial patellofemoral ligament reconstruction in young patients. *Int Orthop.* 2014;38(11):2265–72. <https://doi.org/10.1007/s00264-014-2437-4>.
- Frosch KH, Schmeling A. A new classification system of patellar instability and patellar maltracking. *Arch Orthop Trauma Surg.* 2016;136(4):485–97. <https://doi.org/10.1007/s00402-015-2381-9>.
- Migliorini F, Eschweiler J, Betsch M, et al. Prognostic factors for isolated medial patellofemoral ligament reconstruction: a systematic review. *Surg J R Coll Surg Edinburgh Ireland.* 2021. <https://doi.org/10.1016/j.surge.2021.03.003>.

10. Vetrano M, Oliva F, Bisicchia S, et al. IS Mu. LT first-time patellar dislocation guidelines. *Muscles Ligaments Tendons J.* 2017;7(1):1–10. <https://doi.org/10.11138/mltj/2017.7.1.001>.
11. Panni AS, Cerciello S, Maffulli N, et al. Patellar shape can be a predisposing factor in patellar instability. *Knee Surg Sports Traumatol Arthrosc Off J ESSKA.* 2011;19(4):663–70. <https://doi.org/10.1007/s00167-010-1329-4>.
12. Zhang Z, Song G, Li Y, et al. Medial patellofemoral ligament reconstruction with or without derotational distal femoral osteotomy in treating recurrent patellar dislocation with increased femoral anteversion: a retrospective comparative study. *Am J Sports Med.* 2021;49(1):200–6. <https://doi.org/10.1177/0363546520968566>.
13. Botser IB, Ozoude GC, Martin DE, et al. Femoral anteversion in the hip: comparison of measurement by computed tomography, magnetic resonance imaging, and physical examination. *Arthroscopy.* 2012;28(5):619–27. <https://doi.org/10.1016/j.arthro.2011.10.021>.
14. Nelitz M. Femoral derotational osteotomies. *Curr Rev Musculoskelet Med.* 2018;11(2):272–9. <https://doi.org/10.1007/s12178-018-9483-2>.
15. Beebe MJ, Wylie JD, Bodine BG, et al. Accuracy and reliability of computed tomography and magnetic resonance imaging compared with true anatomic femoral version. *J Pediatr Orthop.* 2017;37(4):e265–70. <https://doi.org/10.1097/bpo.0000000000000959>.
16. Buddenbrock B, Wissing H, Müller RD, et al. Radiological determination of femoral rotation deformity—computerized tomography, optimized measurement accuracy and exposure dosage. *Z Orthop Ihre Grenzgeb.* 1997;135(1):9–16. <https://doi.org/10.1055/s-2008-1039548>.
17. Xu Z, Zhang H, Guo M, et al. Malalignment sign on knee magnetic resonance imaging: a new predictor for excessive femoral anteversion in patients with patellar dislocation. *Knee Surg Sports Traumatol Arthrosc Off J ESSKA.* 2021;29(4):1075–82. <https://doi.org/10.1007/s00167-020-06080-8>.
18. Scorcelletti M, Reeves ND, Rittweger J, et al. Femoral anteversion: significance and measurement. *J Anat.* 2020;237(5):811–26. <https://doi.org/10.1111/joa.13249>.
19. Tayton E. Femoral anteversion: a necessary angle or an evolutionary vestige? *J Bone Jt Surg Br.* 2007;89(10):1283–8. <https://doi.org/10.1302/0301-620x.89b10.19435>.
20. Murphy SB, Simon SR, Kijewski PK, et al. Femoral anteversion. *J Bone Jt Surg Am.* 1987;69(8):1169–76.
21. Zhang Z, Zhang H, Song G, et al. A high-grade j sign is more likely to yield higher postoperative patellar laxity and residual maltracking in patients with recurrent patellar dislocation treated with derotational distal femoral osteotomy. *Am J Sports Med.* 2020;48(1):117–27. <https://doi.org/10.1177/0363546519884669>.

Publisher's Note

Springer Nature remains neutral with regard to jurisdictional claims in published maps and institutional affiliations.

Ready to submit your research? Choose BMC and benefit from:

- fast, convenient online submission
- thorough peer review by experienced researchers in your field
- rapid publication on acceptance
- support for research data, including large and complex data types
- gold Open Access which fosters wider collaboration and increased citations
- maximum visibility for your research: over 100M website views per year

At BMC, research is always in progress.

Learn more biomedcentral.com/submissions

