

Acquired tracheoesophageal fistula in a pregnant patient with COVID-19 pneumonia on prolonged invasive ventilation

Patricia Maria Gregoria Mina Cuaño ¹, John Christopher Agsalud Pilapil,¹
Ramon Jr Bagaporo Larrazabal ¹, Ralph Elvi Villalobos ²

¹Department of Medicine, Philippine General Hospital, University of the Philippines Manila, Manila, Philippines

²Division of Pulmonary Medicine, Department of Medicine, University of the Philippines Manila, Manila, Philippines

Correspondence to

Dr Patricia Maria Gregoria Mina Cuaño; pmgvmina@gmail.com

Accepted 15 August 2021

SUMMARY

A previously healthy pregnant woman was diagnosed with COVID-19 pneumonia and was subsequently intubated. Throughout the course of her illness, the patient was treated for recurrent bouts of pneumonia. A high-resolution chest and neck CT scan confirmed the presence of a tracheoesophageal fistula (TEF), which may have been caused by the presence of the overinflated endotracheal cuff, prolonged steroid use, hypoxic injury and possible direct injury of the tracheal mucosa from COVID-19 itself. A temporising procedure, involving tracheostomy with an extended-length tracheal tube, was performed. Unfortunately, the patient succumbed to infection prior to definitive repair. This case highlights the importance of keeping a high index of suspicion for tracheal injury in patients who experience prolonged periods of intubation. It also underlies the high morbidity and mortality rate associated with TEF, although being a rare disease.

BACKGROUND

A tracheoesophageal fistula (TEF) is identified by an abnormal connection between the oesophagus and the trachea. Patients with TEF generally have poor quality of life, and without adequate intervention, their life expectancy can be measured in weeks.¹ TEF can occur as a congenital anomaly or secondary to a pathological injury from other diseases. In adults, TEFs are mostly acquired and are rarely congenital. Approximately 50% of acquired TEFs are caused by malignancy, with the largest contributions from oesophageal or lung cancer. Even fewer cases are attributed to benign conditions such as endoscopic or surgical intervention, trauma, prolonged endotracheal (ET) intubation or tracheostomy and infectious diseases such as tuberculosis.^{2–5}

TEF is a morbid, potentially lethal, but truly rare (0.3%–3%) sequelae of prolonged invasive ventilation.^{6–8} Due to reasons that have yet to be fully elucidated, however, the ongoing COVID-19 pandemic has ushered an increased incidence of lung and tracheal complications, including TEF.⁹ Here, we report a young woman with no comorbidities who was intubated after developing COVID-19 pneumonia compounded with acute respiratory distress syndrome (ARDS). After 6 weeks of intubation inclusive of multiple counts of reintubation, she developed TEF.

CASE PRESENTATION

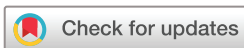A woman with no known comorbidities was admitted for a 1-week history of intermittent fever,

associated with non-productive cough, dyspnoea, malaise and diarrhoea. The patient reported to be a non-cigarette smoker and non-alcoholic beverage drinker, as well as having no food and drug allergies. She eventually tested positive for the SARS-CoV-2 virus by a nasopharyngeal swab reverse transcriptase (RT) PCR. At this time, she was 36 weeks pregnant. She was initially managed as a case of community-acquired pneumonia—moderate risk—and COVID-19 pneumonia. She was started on an antibiotic regimen of piperacillin–tazobactam and azithromycin and given dexamethasone and remdesivir (of which the full 10 days were completed). Her dyspnoea progressed, however, and she was intubated. Three days into her admission, she underwent an emergency caesarean section for non-reassuring fetal status. The baby tested negative for the SARS-CoV-2 virus and was then isolated from her mother.

Over the next 5 weeks, she was treated for repeated bouts of ventilator-associated pneumonia (including *Acinetobacter baumannii* and *Burkholderia cepacia* pneumonia). She would self-extubate a total of eight times following episodes of agitation (despite sedation with midazolam), followed by prompt re-intubation for respiratory distress and desaturations.

She was ventilated with relatively low positive end-expiratory pressures (PEEP) ranging from 5 to 8 cm H₂O. On arrival at our institution, recorded peak airway pressures ranged from 30 to 43 cm H₂O, mostly coinciding with periods of agitation (ie, where she would bite the ET tube) despite administration of midazolam, fentanyl and propofol drips. She was referred to the anaesthesiology service for assistance on sedation. During periods of light to deep sedation, however, recorded peak airway pressures were in an acceptable range of 12–25 cm H₂O. Plateau pressures were within a range of 19–25 cm H₂O, and PEEP was maintained within a range of 5–8 cm H₂O.

On transfer to our institution, review of her chest imaging showed marked dilatation of the trachea (likely caused by a hyperinflated ET cuff) at the level of C7–T1, along with a pneumothorax on the right hemithorax (6% in volume). The cuff was deflated slightly, and the patient was referred to the thoracic and cardiovascular surgery service for their opinion on the pneumothorax. The consideration of the service at the time was a possible tracheomalacia versus prestenotic tracheal dilatation



© BMJ Publishing Group Limited 2021. No commercial re-use. See rights and permissions. Published by BMJ.

To cite: Cuaño PMGM, Pilapil JCA, Larrazabal RJB, et al. *BMJ Case Rep* 2021;**14**:e244016. doi:10.1136/bcr-2021-244016

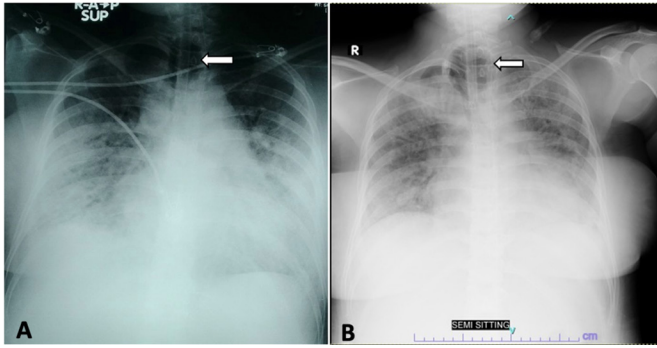


Figure 1 Chest radiographs taken on day 18 (A) and day 35 (B) of intubation, where the patient was being treated for recurrent episodes of pneumonia. Note the hyperinflated endotracheal cuff (represented by the arrow) seen as a cystic lucency at the level of the trachea. Alveolointerstitial opacities throughout both lungs, with peripheral predominance—characteristic of COVID-19 pneumonia, were also noted. A thin visceropleural line was seen along the periphery of the right mid-to-upper lung fields (B) representing a small volume pneumothorax.

secondary to prolonged intubation (at this point, the patient has been intubated for a total of 36 days). No surgical intervention was warranted by the service at the time due to the small volume of the pneumothorax; hence, they opted for close observation. Intestinal ileus was also documented in the investigation for a distended abdomen, initially attributed to high doses of opioids used for sedation, as well as her postoperative status.

On her 42nd day of intubation, she was referred to the general surgery service for tracheostomy. On review of the chest high-resolution CT scan, however, a possible tracheal rupture was considered (to tie together the presence of the tracheal dilatation and adjacent pneumothorax). An emergency neck CT scan with intravenous contrast was done, and the ET cuff deflated slightly. During the procedure, however, the patient experienced sudden hypotension and desaturations. The scan showed a new-onset pneumothorax on the left and a TEF at the proximal trachea, 1.4 cm in length and 1.5 cm in diameter. The sudden hypotension may be explained by tension pneumothorax; needling was attempted, but there was considerable difficulty in inserting the cannula. An emergency chest tube thoracotomy was performed on the left hemithorax, and the lung subsequently re-expanded.

INVESTIGATIONS

A chest radiograph obtained at the previous institution (figure 1A) shows bilateral reticular opacities in the periphery of the middle lobe—a pattern characteristic of COVID-19 pneumonia. As early as day 18 of intubation, it appears as if the ET cuff had been overinflated.

A repeat radiograph taken at our institution (figure 1B) shows the same cystic dilatation on chest imaging, representing the ET cuff. There was persistence of the alveolointerstitial opacities throughout both lungs, with peripheral predominance. A thin visceropleural line was seen along the periphery of the right mid-to-upper lung fields, representing a small volume pneumothorax (approximately 6%). The service chose to manage this conservatively.

A high-resolution chest CT scan and CT pulmonary angiogram was done to evaluate for any other pathology that would explain why a previously healthy woman would be unable to tolerate weaning from the ventilator (ie, pulmonary embolism or fibrosis). This test confirmed the latter, with findings of bilateral

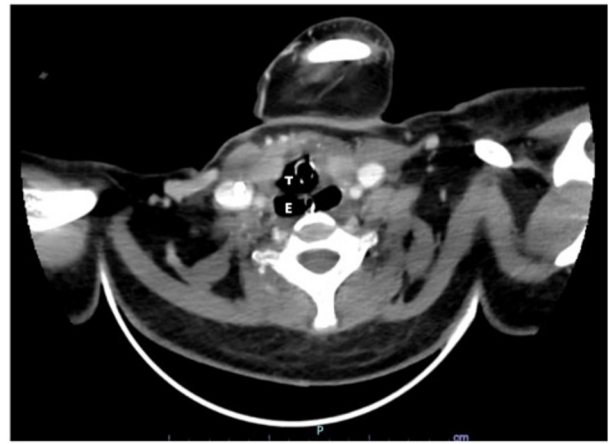


Figure 2 Axial tomographic sections of the neck with intravenous contrast showing a defect in the posterior tracheal wall (T) and/or anterior oesophagus (E), measuring 1.5×1.4 cm (Craniocaudal×Width), along with a new pneumothorax on the left upper hemithorax and compression atelectasis of the left upper lobe. The proximal oesophagus also appeared distended.

ground glass opacities, consolidation and septal thickening. A pneumothorax at the anterior pleural space of the right hemithorax (seen on chest radiograph) was also confirmed, as well as paraseptal emphysema with cystic and tubular bronchiectatic changes. No filling defects indicative of pulmonary thromboembolism were seen.

To rule out an underlying immunocompromised state, a rapid HIV test was done, which yielded a negative result. ET aspirates were also sent for acid fast bacilli smears, which all yielded negative results.

An emergency neck CT scan with intravenous contrast was done to evaluate the possible tracheal rupture (figure 2), which would explain the pneumothorax and pneumomediastinum, in the setting of a dilated trachea. A defect in the posterior tracheal wall and/or anterior oesophagus was seen, measuring 1.5×1.4 cm (Craniocaudal×Width), along with a new pneumothorax on the left upper hemithorax and accompanying compression atelectasis of the left upper lobe.

DIFFERENTIAL DIAGNOSIS

Initially, the repeated bouts of ventilator-associated pneumonia were attributed to unfortunate breaches in asepsis during care, as well as complications of underlying pulmonary fibrosis. The pneumothorax initially encountered on day 39 of illness was initially attributed to lung fibrosis, as a sequelae of ARDS. The ileus, on the other hand, was thought to be either opioid-induced (from the high doses of fentanyl required to sedate this patient) and/or postoperative. The latter is less likely though, as the symptoms appeared 34 days post-caesarean section.

The findings of a communication between the trachea and the oesophagus, with an accompanying tracheal rupture, tie all of these events together. The recurrent bouts of pneumonia could have been from recurrent aspiration episodes through the fistula. The ileus, likewise, could have arisen from passage of air through the fistula into the stomach and bowels. The pneumothorax and pneumomediastinum may have also been caused by the defect in the trachea.

The previous stable haemodynamic status and improving oxygenation of the patient, despite the TEF, may be explained by the overinflated ET cuff tamponading the fistula. Deflation

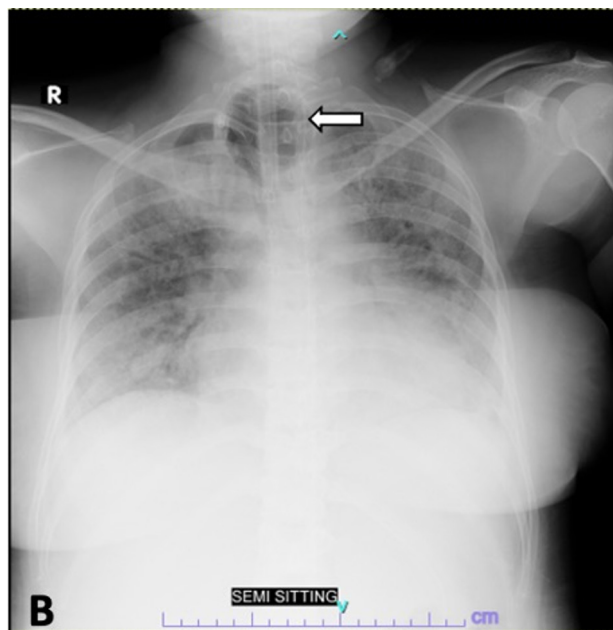


Figure 3 A chest radiograph taken on day 51 of admission, 1 week after tracheostomy. An extended-length tracheal tube (white arrows) is seen extending past the tracheal dilatation, approximating the location of the tracheoesophageal fistula. The black arrow outlines the chest tube inserted into the left hemithorax.

of the cuff prior to the next CT scan may have reversed this temporary blockade, causing the expansion of the tension pneumothorax on the left.

TREATMENT

An intraoperative bronchoscopy, followed by tracheostomy with an extended-length tracheal tube, was performed. Intraoperatively, the TEF was confirmed via bronchoscopy, located at the proximal trachea (at the 7 o'clock position), distal to the tip of the ET tube. The tracheostomy tube was strategically inserted below this communication, at a 1 cm distance (as seen in figure 3). The proximal trachea was easily collapsible and severely inflamed. No fistula was seen in the distal trachea.

To facilitate eventual feeding, a simultaneous tube jejunostomy was performed. This procedure was meant to be a temporary measure, with the goal of definitive TEF repair following nutritional upbuilding of the patient.

OUTCOME AND FOLLOW-UP

The patient tolerated the procedure well, with minimal intraoperative blood loss. She was placed on diet progression via tube jejunostomy. Weaning from the ventilator was difficult, however, due to the recurrent bacterial pneumonia and advanced lung fibrosis from COVID-19.

The definitive plan of all services involved was to resolve all infection, wean this patient from the ventilator and nutritionally upbuild her, prior to planning repair of the TEF. Unfortunately, after several more episodes of nosocomial pneumonia, coupled with gram-positive bacteraemia and sepsis, the patient succumbed after a total of 53 days of intubation.

DISCUSSION

TEF may be either congenital or acquired; in adults, about half of these cases (50%) are secondary to malignancies. Less

common etiologies include prolonged intubation and surgical or endoscopic interventions.

The pathogenesis of TEF in our patient may be explained by the chronic trauma brought about by a prolonged period of tracheal intubation, as well as repeated attempts at reintubation. The pressure that the inflated cuff of the ET tube exerts on the posterior membranous wall (usually against a rigid nasogastric tube) results in the ischaemic necrosis of that area as well as the anterior wall of the oesophagus. This then brings about an abnormal communication.¹⁰ The following are known risk factors associated with TEF: prolonged ET intubation, high ET cuff pressure (>40 cm H₂O), treatment with steroids, poor nutritional status, high airway pressure during mechanical ventilation, sepsis and the female gender.^{10 11}

A retrospective study by Fiacchini *et al* noted a significant increase in full-thickness tracheal lesions (including TEF) in patients with COVID-19 (14 of 30 patients, 47%) in comparison to uninfected controls (1 of 45 patients, 2%), despite both groups being intubated for a similar amount of time (more than 14 days). Of the affected patients with COVID-19, the following complications were also noted: 10 had pneumomediastinum, and 6 had pneumothorax, while 13 had subcutaneous emphysema. The authors speculated on several factors, which have led to this surprising finding. Among these are the prothrombotic and antifibrinolytic condition of affected patients, which may have affected the microvasculature of the mucosa (enough to cause necrosis); hypoxic injury (manifested by a low PaO₂/FiO₂ ratio); viral replication within the tracheal mucosa; high-dose steroids that may have caused mucosal atrophy and impaired healing of injury; and even caregiver fatigue on the part of the healthcare provider, which may make the patient more prone to management error.⁹

All the above points are pertinent and may explain how a TEF may have occurred in our patient. Though many conditions are difficult to reverse (ie, hypoxic injury from a severely damaged lung), we believe some are still avoidable, such is the issue with the overinflated cuff. In general, ET cuff pressure should be kept below 25 mm Hg to prevent unnecessary compression of the tracheal structures, which in turn could compromise blood flow and inadvertently cause tissue hypoxia and necrosis.^{11 12} An ET cuff manometer is an essential tool that should be part of every intensive care unit. Unfortunately, in most settings, adequacy of cuff inflation is still determined by palpation of the pilot balloon—a practice that has been proven to be largely unreliable and prone to errors. In a study by Sengupta *et al* among anaesthetised patients in the USA, only 27% of ET cuff pressures (balloons were inflated and adjusted via palpation) were within the target of 20–30 cm H₂O.¹³

Unfortunately, there are no consensus guidelines as to the optimal timing of tracheostomy in patients with COVID-19 requiring prolonged mechanical ventilation. Although a consensus statement released in the journal CHEST in 2020 strongly suggests tracheostomy for patients with COVID-19 who are expected to be on prolonged mechanical ventilation, the panel stopped short of recommending a specific time period.¹⁴ Furthermore, a review of 19 guidelines on tracheostomy performed by Chiesa-Estomba *et al* presented varied views on optimal timing, with some societies opting to wait at least 14 days after intubation (and with a negative SARS-CoV-2 RT-PCR) for elective cases and others advocating for earlier tracheostomy.¹⁵

At present, there are no consensus guidelines on the optimal management for TEF. In general, a multidisciplinary approach together with a team of surgeons, interventional pulmonologists and gastroenterologists, reviews the underlying cause, location

and anatomy before deciding on a course of action. In cases of malignancy, a palliative approach is usually employed. Otherwise, should the aetiology be a non-malignant one, corrective surgery is undertaken as an elective procedure.⁷ The procedure in itself is a complex one, and preparation may take weeks to months.⁷ In general, patients are ideally weaned off the ventilator in order to minimise the high airway pressures that may inadvertently cause suture dehiscence.⁷ The patient should also be optimised nutritionally, in order to ensure adequate wound healing and recovery.⁷ In many cases, such as in ours, a temporising procedure is first employed in order to minimise further complications from the TEF: the patient is placed on nothing per ore, the head is elevated (to prevent aspiration) and the nasogastric tube is removed in order to minimise the pressure on the oesophagus against the trachea.^{7 16} A tube gastrostomy or jejunostomy is inserted both to facilitate drainage of secretions (and prevent reflux into the airways through the fistula)¹⁶ and to initiate enteral nutrition, bypassing the communication from the oesophagus.⁷ In cases where liberation from the ventilator is difficult, if not impossible, advancement of the ET tube or insertion of an extended tracheostomy tube (such as what was used for our patient) beyond the fistula may be done.^{7 16}

Learning points

- ▶ Patients with COVID-19 are at high risk for tracheal injury, including tracheoesophageal fistulas, stemming from direct effects of the virus to the mucosa and from secondary causes such as prolonged intubation and high-dose steroids.
- ▶ Further studies should be performed in determining the optimal timing for tracheostomy in intubated patients with COVID-19, in order to minimise iatrogenic tracheal injuries caused by prolonged intubation.
- ▶ In patients with recurrent bouts of pneumonia on prolonged mechanical ventilation, a high index of suspicion for tracheoesophageal fistulas and other tracheal injuries should be maintained.
- ▶ Periodic monitoring of ET cuff pressure (to target <25 cm H₂O) is an essential part of patient safety and care.
- ▶ A multidisciplinary approach, involving the pulmonologist, intensivist, surgeon, nursing and paramedical staff, is essential to achieve a holistic approach in caring for critical patients with COVID-19.

Acknowledgements We would like to acknowledge the contributions of the following individuals: Dr Kevin Val C. Bismark for providing his thoughts on the case, as well as playing a large role in the management of this patient; Dr Blessie Marie Perez for caring for the patient; and Dr Johnnel Pahila and Dr Carlo Miguel Perez for lending their time and expertise in the course of managing this patient.

Contributors PMGMC: conceptualisation; drafting of the work, including research; major editing; and writing. JCAP: conceptualisation; drafting of the work, including research; and gathered pertinent images (radiographs). RJBL: conceptualisation;

drafting of the work, including research; and gathering pertinent images (CT scans). REV: expertise in pulmonary medicine, part of conceptualisation of the work and provided final approval.

Funding The authors have not declared a specific grant for this research from any funding agency in the public, commercial or not-for-profit sectors.

Competing interests None declared.

Patient consent for publication Obtained.

Provenance and peer review Not commissioned; externally peer reviewed.

This article is made freely available for use in accordance with BMJ's website terms and conditions for the duration of the covid-19 pandemic or until otherwise determined by BMJ. You may use, download and print the article for any lawful, non-commercial purpose (including text and data mining) provided that all copyright notices and trade marks are retained.

ORCID iDs

Patricia Maria Gregoria Mina Cuaño <http://orcid.org/0000-0002-8392-3606>
 Ramon Jr Bagaporo Larrazabal <http://orcid.org/0000-0003-4538-416X>
 Ralph Elvi Villalobos <http://orcid.org/0000-0002-6941-9139>

REFERENCES

- 1 Ke M, Wu X, Zeng J. The treatment strategy for tracheoesophageal fistula. *J Thorac Dis* 2015;7:3389–97.
- 2 Reed MF, Mathisen DJ. Tracheoesophageal fistula. *Chest Surg Clin N Am* 2003;13:271–89.
- 3 Chen Y-H, Li S-H, Chiu Y-C, et al. Comparative study of esophageal stent and feeding gastrostomy/jejunostomy for tracheoesophageal fistula caused by esophageal squamous cell carcinoma. *PLoS One* 2012;7:e42766.
- 4 Balazs A, Kupcsulik PK, Galambos Z. Esophagorespiratory fistulas of tumorous origin. non-operative management of 264 cases in a 20-year period. *Eur J Cardiothorac Surg* 2008;34:1103–7.
- 5 Rodriguez AN, Diaz-Jimenez JP. Malignant respiratory-digestive fistulas. *Curr Opin Pulm Med* 2010;16:329–33.
- 6 Couraud L, Ballester MJ, Delaisement C. Acquired tracheoesophageal fistula and its management. *Semin Thorac Cardiovasc Surg* 1996;8:392–9.
- 7 Bibas BJ, Cardoso PFG, Minamoto H, et al. Surgery for intrathoracic tracheoesophageal and bronchoesophageal fistula. *Ann Transl Med* 2018;6:210
- 8 Green MS, J Mathew J, J Michos L, et al. Using bronchoscopy to detect acquired tracheoesophageal fistula in mechanically ventilated patients. *Anesth Pain Med* 2017;7:e57801.
- 9 Fiacchini G, Tricò D, Ribecchini A, et al. Evaluation of the incidence and potential mechanisms of tracheal complications in patients with COVID-19. *JAMA Otolaryngol Head Neck Surg* 2021;147:70–6.
- 10 Paraschiv M. Tracheoesophageal fistula—a complication of prolonged tracheal intubation. *J Med Life*;7.
- 11 Payne DK, Anderson WM, Romero MD, et al. Tracheoesophageal fistula formation in intubated patients. risk factors and treatment with high-frequency jet ventilation. *Chest* 1990;98:161–4.
- 12 Jain MK, Tripathi CB. Endotracheal tube cuff pressure monitoring during neurosurgery - Manual vs. automatic method. *J Anaesthesiol Clin Pharmacol* 2011;27:358–61.
- 13 Sengupta P, Sessler DI, Maglinger P, et al. Endotracheal tube cuff pressure in three hospitals, and the volume required to produce an appropriate cuff pressure. *BMC Anesthesiol* 2004;4.
- 14 Lamb CR, Desai NR, Angel L, et al. Use of tracheostomy during the COVID-19 pandemic: American College of chest Physicians/American association for Bronchology and interventional Pulmonology/Association of interventional pulmonology program directors expert panel report. *Chest* 2020;158:1499–514.
- 15 Chiesa-Estomba CM, Lechien JR, Calvo-Henriquez C, et al. Systematic review of international guidelines for tracheostomy in COVID-19 patients. *Oral Oncol* 2020;108:104844.
- 16 Chauhan SS, Long JD. Management of tracheoesophageal fistulas in adults. *Curr Treat Options Gastroenterol* 2004;7:31–40.

Copyright 2021 BMJ Publishing Group. All rights reserved. For permission to reuse any of this content visit <https://www.bmj.com/company/products-services/rights-and-licensing/permissions/>
BMJ Case Report Fellows may re-use this article for personal use and teaching without any further permission.

Become a Fellow of BMJ Case Reports today and you can:

- ▶ Submit as many cases as you like
- ▶ Enjoy fast sympathetic peer review and rapid publication of accepted articles
- ▶ Access all the published articles
- ▶ Re-use any of the published material for personal use and teaching without further permission

Customer Service

If you have any further queries about your subscription, please contact our customer services team on +44 (0) 207111 1105 or via email at support@bmj.com.

Visit casereports.bmj.com for more articles like this and to become a Fellow