

Surgical treatment of ventral and ventrolateral intradural extramedullary tumors of craniovertebral and upper cervical localization

Yuri P. Zozulya, Yevheniy I. Slynko, Iyad I. Al-Qashqish

Romodanov's Institute of Neurosurgery, Keiv, Ukraine

ABSTRACT

Background: Surgical treatment of extramedullary craniovertebral and upper cervical tumors differs essentially, depending on the peculiarities of their localization.

Materials and Methods: In the Spinal Department of the Institute of Neurosurgery during the period from 2000 to 2010, 96 patients with ventral and ventrolateral intradural extramedullary craniovertebral tumors and tumors of upper cervical localization were examined and operated.

Results: The patients were distributed as follows. Tumors of the craniovertebral localization: These are neoplasms spreading in rostral direction up to the boundary of the lower third of the clivus and in caudal direction up to the upper edge body of the axis (C0–C1) – 12 patients; tumors at the C1–C2 level: 28 patients; and tumors at the C1–C2–C3 level: 56 patients. The tumors were divided into ventral (60) and ventrolateral (36).

Conclusion: Therefore, the adequate choice of a surgical approach first depends on the localization of the tumor, its size and the extent to which it has spread. In most cases of extramedullary ventrolateral tumors of craniovertebral and upper cervical localization, far lateral and posterolateral approaches are the most optimum and the least traumatic. The extreme lateral approach is advisable in cases of big size ventral craniovertebral tumors.

Key words: Extreme lateral approach, far lateral, ventral tumor, ventrolateral tumor

Introduction

Surgical treatment of extramedullary craniovertebral and upper cervical tumors differs essentially, depending on the peculiarities of their localization. Surgical removal of the tumors located on the dorsal or dorsolateral surface of the spinal cord is usually performed by middle approach and does not arouse any special disagreement,^[1] whereas in cases of intradural extramedullary tumors, causing compression of ventrolateral or ventral surface of the spinal cord, surgical treatment becomes much more complicated. In these cases,

the choice of surgical approaches must depend on tumor localization and level, should provide optimum visual control of the tumor, spinal cord, spinal roots and nerves, and cause minimum displacement of spinal cord during surgical manipulations.^[2]

Materials and Methods

In the Spinal Department of the Institute of Neurosurgery during the period from 2000 to 2010, 96 patients with ventral and ventrolateral intradural extramedullary craniovertebral tumors and tumors of upper cervical localization were examined and operated. The patients' age varied from 30 to 80 years.

According to the level of tumor localization, the patients were distributed as follows. *Tumors of the craniovertebral localization:* These are neoplasms spreading in rostral direction up to the boundary of the lower third of the clivus and in caudal direction up to the upper edge body of the axis (C0–C1) – 12 patients; *tumors at the C1–C2 level:* 28 patients; and *tumors at the C1–C2–C3 level:* 56 patients.

The tumors were divided into ventral (60) and ventrolateral (36) [Table 1]. Regarding the histological structure, the tumors

Access this article online	
Quick Response Code:	Website: www.asianjns.org
	DOI: 10.4103/1793-5482.85629

Address for correspondence:

Dr. Yevheniy I. Slynko, Romodanov's Institute of Neurosurgery, P. Maiborodu 32, Keiv 04050, Ukraine. E-mail: eu_slynko@yahoo.com, eu.slynko@gmail.com

were distributed as follows: neurinomas in 36 patients; meningiomas in 48 patients; and neurofibromas in 12 patients [Table 2].

The tumor's location and size, the degree of spinal cord compression and displacement were determined according to the magnetic resonance tomography and computed tomography data. For quantitative estimation of the degree of spinal cord displacement caused by the tumor, we used the scheme of cross-section division of the spinal canal (e.g. at C1 level) and its content into 16 sectors, by which the positions of spinal cord in normal state and in case of its displacement by the tumor were estimated [Figure 1]. The size of the area of cross section of the spinal cord at C1 level (based on MRT axial sections) was on an average 123 mm² (varying from 84 to 146 mm²) and the size of the area of cross section of the dural sac was 321 mm² (varying from 290 to 350 mm²). The area was calculated by means of the formula of ellipsoid area $S = \pi ab$, where a and b are small and big radius of the ellipsoid, respectively (half of the sagittal and frontal dimensions of the spinal cord and dural bag). The ratio of the square spinal cord and dural sac cross-section areas was on average 1 to 3 (1/3). One-third was occupied by the spinal cord and two-thirds by the subarachnoid spaces, filled with liquor. At levels C2 and C3, the ratios were similar except for the area of subarachnoid spaces, which were less by 20–30%. Hence, to judge about the degree of spinal cord compression and displacement on the basis of MRT data, we divided our observations into three groups:

- I – Tumors with the cross-section area (at level C1) less than the cross section of the spinal cord [>1 (tumor) + 1 (spinal cord)/3 (dural sac)], compression was insignificant, practically there was no spinal cord displacement;
- II – Tumors with the cross-section area equal to that of the spinal cord ($1 + 1/3$), compression of the spinal cord was moderate, the spinal cord was displaced by one square, according to the scheme given in Figure 1; and
- III – Tumors with an area equal to two cross sections of the spinal cord ($2 + 1/3$), compression was pronounced, liquor spaces on the level of the tumor were absent, the spinal cord was displaced by two squares [Figure 1 and Table 3].

Results

Surgical approaches used on the craniovertebral and upper cervical levels are divided into posterior, posterolateral, far lateral and extreme lateral ones.

The choice of an approach depended on the tumor localization and its size estimated by the scheme as described above [Figure 1]. The posterolateral approach was used to remove tumors of type I, if they occupied sectors A on one side or sectors LA, LP, displaced the spinal cord to sectors LA, LP, PL of the opposite side, occupying sector SA. We used this approach in 16 patients [Table 4].

Table 1: Distribution of ventral and ventrolateral tumors depending on the level of localization

Level of localization	Ventral	Ventrolateral	All
Co–C1	12	0	12
C1–C2	16	12	28
C2–C3	32	24	56
Total	60 (24%)	36 (76%)	96

Table 2: Histological tumor types

Localization	Meningiomas	Neurinomas	Neurofibromas	Total
Co–C1	8	4	0	12
C1–C2	16	12	0	28
C2–C3	24	20	12	56
Total	48	36	12	96

Table 3: Degrees of displacement and compression of spinal cord by the tumor according to MRT data

Tumor localization	Ventral			Ventrolateral			Total
	I	II	III	I	II	III	
Co–C1	-	8	4	-	-	-	12
C1–C2	4	8	4	-	8	4	28
C2–C3	16	12	4	12	8	4	56
Total	20	28	12	12	16	8	96

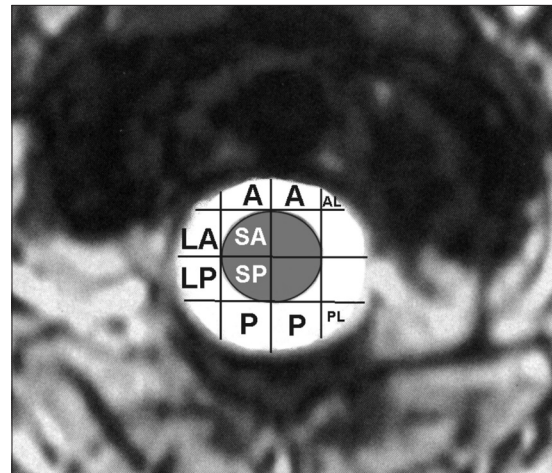


Figure 1: Scheme of spinal cord intradural spaces location. A – Anterior, AL – Anterolateral, LA – Later anterior, LP – Later posterior, SA – Spinal cord anterior, SP – Spinal cord posterior, P – Posterior, PL – Posterior lateral

The far lateral approach was used in cases when a tumor with a size of types II–III occupied sectors A on one or two sides, sector SA on one side or sector LA, displacing the spinal cord to the opposite side to sectors P, PL, LP of the opposite side [Figures 2 and 3]. We used this approach in 64 patients [Table 4].

The extreme lateral approach was used with the tumors of types II–III size in cases when they occupied sectors A on two sides, in addition, AL, and especially sectors A and SA on

Table 4: Operative approaches used for ventral and ventrolateral craniovertebral and upper cervical tumors

Approaches	Tumor localization			Total
	C0–C1	C1–C2	C2–C3	
Ventral tumors				
Posterolateral	-	-	-	
Far lateral	4	12	32	12 (80%)
Extreme lateral	8	4	0	3 (20%)
Total	12	16	32	60
Ventrolateral tumors				
Posterolateral	-	4	12	16 (44%)
Far lateral	-	4	12	16 (44%)
Extreme lateral	-	4	0	4 (12%)
Total	0	12	24	36

two sides, displacing the spinal cord exclusively backward into sectors P. We used this approach in 16 patients [Table 4].

The level of the tumor’s location and extent also played a role in the choice of optimum approach. The extreme lateral approach was used with the tumor located at levels C0–C1 and C1–C2. The far lateral approach was used at all levels C0–C1, C1–C2, and C2–C3. The posterolateral approach was used at levels C1–C2 and C2–C3.

Posterolateral surgical approach included C2–C3 hemilaminectomy and C2–C3 medial facetectomy. The vertebral artery and its venous plexus were not allocated and displaced.

With the far lateral approach, the “park bench” position was used [Figure 4]. A horseshoe-shaped incision was made along the middle line, 7–8 cm down from the occipital protuberance and it was proceeded upward, turning laterally above the occipital protuberance, and was continued above the upper nuchal line toward the mastoid process [Figure 4]. Along the posterior edge of the mastoid, the incision was turned downward and ended 3 cm below the top of the mastoid. We separated muscles together with the skin as a single whole layer from the occipital bone, spinous process and arches C1–C4. The flap was turned downward. The cardinal moment was the identification of the atlas transverse process. The suboccipital triangle was opened by careful separation of upper and lower oblique muscles from the atlas transverse process. In the depth of the triangle, the venous plexus, surrounding the vertebral artery, and the artery itself in its position behind the atlas – occipital joint and the upper edge of the C1 arch were located. The artery was detached by subperiosteal dissection together with the venous plexus. This minimized bleeding. If there was an intracranial spread of the tumor, first we resected the edge of the occipital foramen on one side and widened the zone of resection up to the edge of the sigmoid sinus. Then, C1–C2, and if necessary, C3 hemilaminectomy was

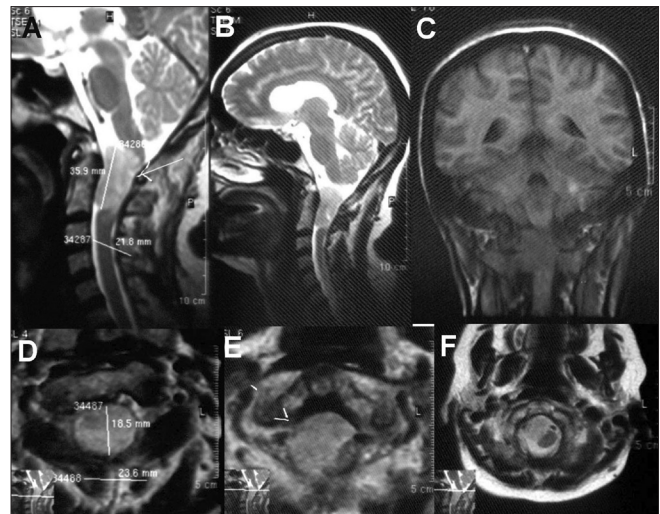


Figure 2: MRT of III-type ventrolateral tumor at C1–C2 level

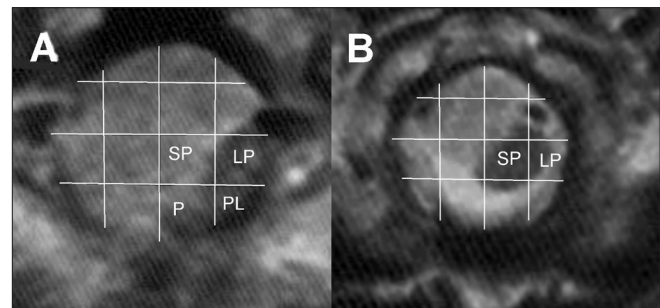


Figure 3: Schemes of spinal cord compression and displacement according to axial MRI sections of the tumor at C1–C2 level. (a) Axial MRI at C1 level (spinal cord displaced to LP, PL, P sectors) and (b) axial MRI at C2 level (spinal cord displaced to LP, SP sectors)

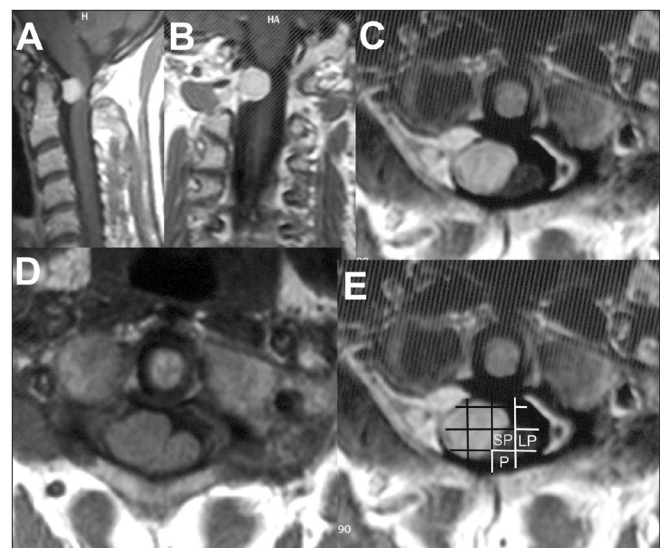


Figure 4: MRT of III-type ventrolateral tumor at C1 level: (a) sagittal, (b) frontal MP plane, (c and d) axial plane, (e) the scheme of spinal cord compression and displacement on the axial plane at C1 level (spinal cord displaced to SP, LP, P sectors)

performed. The C1 arch was removed up to the C1 transverse foramen, which was cut open [Figure 5]. If it was necessary,

the vertebral artery was transposed medially and caudally (medial transposition of the artery), and the remains of the C1 arch were removed up to the C1 lateral mass. Usually, with this approach, the condyles of the occipital bone and the C1 lateral masses were uncovered along the back surface, but were not resected. This being done, the dura was incised as a stick [Figure 6]. The spinal cord and lower brain stem, as a rule, were transposed dorsally and laterally to the opposite side from the tumor. In the first stage, we did not try to separate the vessels and nerves passing along the posterior surface of the tumor. The operative microscope with 8/16 magnification was used. First, the area of the posterior surface of the tumor without nerves and vessels was located. In this area, the tumor was sectioned and the central part was removed stage by stage (by cutting into pieces or by means of cavitron aspirator). Thus, after the tumor debulking, the volume of the tumor was reduced, adjacent nerves and vessels were allocated and displaced from the tumor surface. Without spinal cord

and lower brain stem traction, the lateral part of the tumor, adjacent to the dura mater, was removed. Then, the areas of the tumor, adjacent to the spinal cord and the lower brain stem, were removed [Figure 7].

In cases of extreme lateral approach, the patient was made to lie on the operation table on his side. The incision was started 6 cm lower from the top of the mastoid process, continued upward along the front edge of the sternocleidomastoid muscle, and at the level of the external auditory meatus, turned backward. Sternocleidomastoid muscle was sectioned and drawn forward. The approach was directed strictly to the C1–C3 side surface and the condyles of the occipital bone. M.m. splenius capitis, semispinalis capitis and longissimus capitis were transposed backward, and the sub-occipital triangle was uncovered. From the front, the jugular vein limited the operative approach. Muscles attached to the C1 transverse process were sectioned. The vertebral artery and

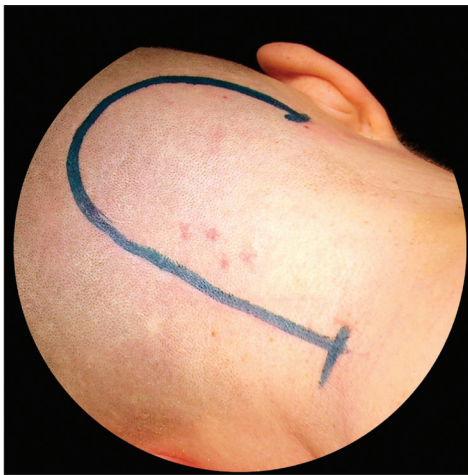

Figure 5: Line of skin incision, far lateral approach

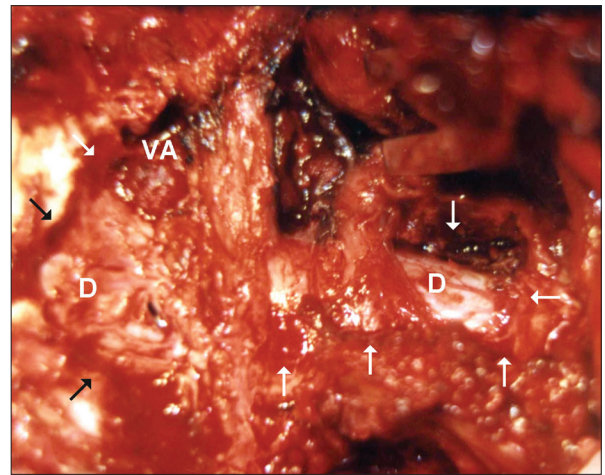


Figure 6: The approach stage after performing of osseous resections with far lateral approach. The zone of osseous resection is outlined by the arrows. D – Dura mater, VA – Vertebral artery

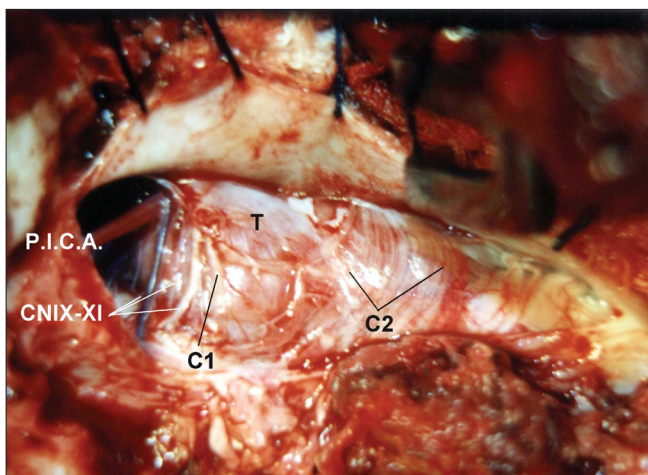


Figure 7: The approach stage after dura mater incision. PICA – Posterior inferior cerebellar artery, T – The tumor, CN IX–XI – The group of lower cranial nerves, C1 – C1 roots, C2 – C2 roots

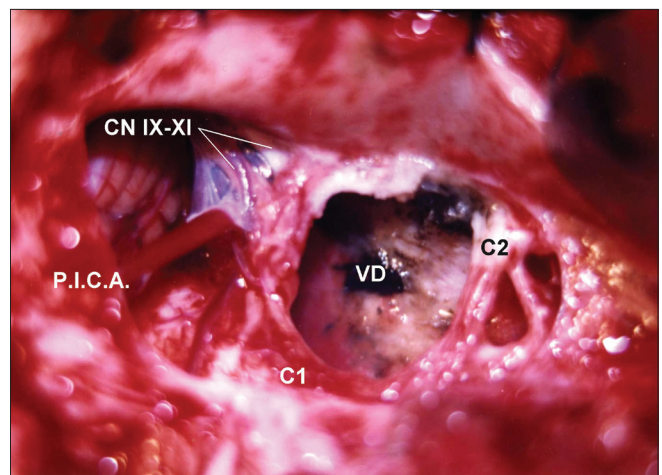


Figure 8: The stage after total removal of the tumor. PICA – Posterior inferior cerebellar artery, VD – Ventral dura mater, CN IX–XI – The group of lower cranial nerves, C1 – C1 roots, C2 – C2 roots

vein were uncovered in the groove on the upper surface of the C1 arch close to the area where it goes into the foramen of the C1 transverse process. The C1–C2–C3 (depending on tumor localization) hemilaminectomy was performed, the C1 transverse process was resected and its foramen was uncovered. The vertebral artery was transposed backward. Further, by means of a drill, partial resection of the occipital condyle and of the C1 lateral mass, and if necessary, medial facetectomy of the C2–C3 were performed. We have never resected entirely the lateral mass of the C1 vertebra and the occipital condyle. If it was necessary, the lower sectors of the occipital bone up to the posterior edge of the sigmoid sinus were resected. The dura mater was incised linearly. The dentoids were sectioned. The tumor was removed in the same way as in the far lateral approach. The extreme lateral approach provided better visualization of the ventral surface of the spinal cord, the lower brain stem, and vertebral arteries. Sometimes, we changed the far lateral approach into the extreme lateral one, if during operation it became clear that the vertebral artery was involved into the meningioma.

With the neurinomas of the C1 root, especially with extravertebral extension, we used the far lateral approach. This approach gave enough space to reach the extravertebral part of the tumor and to visualize the vertebral artery. Removal of the neurinoma began from its medial part and continued toward its lateral part. At first, the tumor was debulked and the vertebral artery allocated. Then, the tumor was separated from the dural sac, which was left intact for its further stitching and preventing liquorrhea. If it was impossible to stitch the dural sac, duroplasty was performed. In case of C2, C3 neurinomas, the dorsolateral approach with hemilaminectomy of C2 and medial facetectomy was applied.

In all the 24 patients, the tumors were removed totally [Figures 8–11]. The results of surgical intervention were affected by the size and the consistency of the tumor, the degree of compression and the direction of spinal cord displacement, the spread of the tumor along the axis (C0, C1, C2, C3), ventral or ventrolateral location of the tumor and the adequacy of surgical approach. During the surgical intervention in 21 patients, no technical complications and no additional damages of the nerves and vascular structures were observed. In two patients, the tumor removal was complicated because of inadequacy of the chosen approach (in one patient, instead of the posterolateral approach, the far lateral approach should have been chosen; in another patient, excessive traction and partial lesion of the nerves of caudal group were observed). In one patient, due to the dense tumor consistency, its separation from the lower brain stem and the spinal cord was traumatic.

For the estimation of the results of surgical treatment, the degree of clinical and functional recovery of the patients was taken into account. Several factors influenced the results of

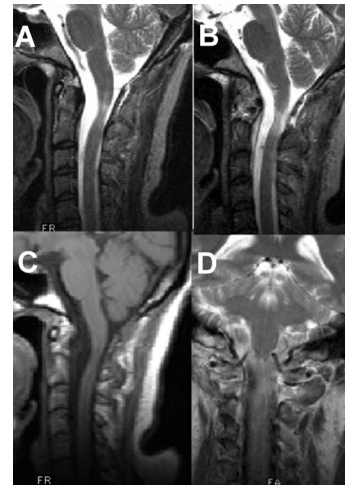

Figure 9: MRT after tumor removal

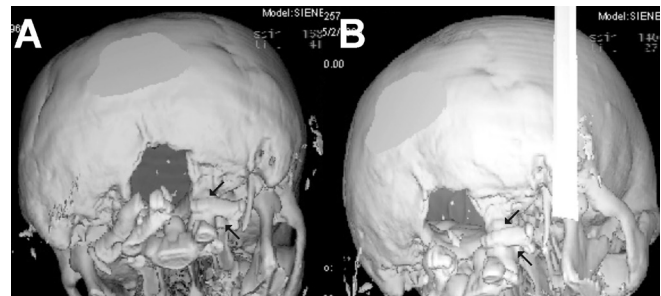


Figure 10: Spiral CT after the tumor removal; the zone of osseous resections is visualized. (a) CT plane at C1 level, (b) CT plane at C2 level

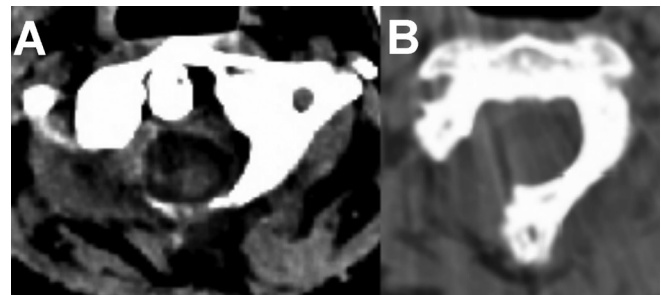


Figure 11: 3D reconstruction of the spiral CT (visible osseous resection zone). The zone of C1 hemilaminectomy extended up to the lateral mass of the C1. Arrows indicate lateral mass and foramen in transverse process C1

surgical treatment as follows: Pre-operative neurological disorders, patients' age, the degree of compression of spinal cord, the direction of spinal cord displacement (exceptionally dorsal, lateral or dorsolateral), adequate surgical approach and the traumatic effects on the tumor removal, connected with it. There were no deaths in our series. We obtained good, satisfactory and unsatisfactory results. In the patients with “good result” (63% in our studies), pain syndrome vanished, capacity for work restored, neurological disturbances regressed (according to Karnofsky performance status 80–100 points) [Table 5]. The patients from the “satisfactory

result” group (25% in our studies) usually had pronounced neurological disturbances before operation and big size tumors. In these patients after surgical intervention, capacity for work restored partially, although neurological deficits from light to moderate paresis, sensory disturbances, and bladder dysfunctions remained (Karnofsky performance status 60–80). In those patients who were hospitalized in a grave condition and in late terms, “unsatisfactory result” was observed (12% in our studies) [Table 5]. In these patients, as a rule, surgical intervention resulted in partial neurological symptoms’ resolution; however, gross neurological disturbances remained (Karnofsky performance status less than 60 points).

On the whole, with the tumors at C0–C1 level, the results of treatment were worse in comparison with those at C1–C2 and C3 levels. This is due to the fact that at the C0–C1 level, as a rule, big size tumors are diagnosed.

With ventrally located tumors, the clinical results were worse as compared with those of ventrolateral tumors [Table 6].

Positive results observed more often with the application of posterolateral and far lateral approaches [Table 7]. However, it should be noted that we applied these approaches to ventrolateral tumors, which can be removed technically easily as compared to ventral tumors.

Discussion

The compression of spinal cord, roots and vertebral artery on the upper cervical level presents a complicated problem. Previously, it was connected with the necessity of considerable transposition of spinal cord during the operation; very often, tumors were not radically removed owing to inadequate surgical approaches, which caused high mortality.^[3,4]

Among the tumors of craniovertebral and upper cervical localization, meningiomas are prevalent (75%). Their ratio to neurinomas is 3:1. At this level, dermoids, teratomas, lipomas, paragangliomas, intradural extraosseous chordomas are rare.^[3] In our studies, only meningiomas, schwannomas, and neurofibromas were found. Spinal neurinomas make up approximately 30% of all the primary spinal cord tumors.^[5] Hori and others reported that among 45 patients, neurinomas grew from sensory roots in 71.1% cases, from motor roots in 17.8% and from both the roots in 11.1% cases.^[6,7] As regards the dura, in 74% cases, neurinomas had intradural localization, 23% had intra-extradural localization and 15% had extradural localization.^[8] George and Lot reported that neurinomas of the C1 and C2 roots make up 5.3% of neurinomas of all levels of spinal cord and 18% of all neurinomas of cervical spine.^[1] The age of the patients with meningiomas varies from 31 to 73 years, and the age for neurofibromas varies from 12 to 57 years. The tumors of craniovertebral and upper cervical localization grow slowly and reach a large size before diagnosis is made.^[9]

Table 5: The results of surgical treatment depending on the level of tumor localization

Level of tumor localization	Operation result			Number of patients
	Good	Satisfactory	Unsatisfactory	
C0–C1	-	4	8	12
C1–C2	12	16	-	28
C2–C3	48	8	-	56
Total (%)	60 (62)	28 (30)	8 (8)	96

Table 6: The results of surgical treatment depending on the tumor relation to the spinal cord

Tumor's relation to spinal cord	Operation result			Number of patients
	Good	Satisfactory	Unsatisfactory	
Ventral	32	20	8	60
Ventrolateral	28	8	0	36
Total (%)	60 (62)	28 (30)	8 (8)	96

Table 7: The results of surgical treatment depending on operation approaches

Approaches	Operation result			Number of patients
	Good	Satisfactory	Unsatisfactory	
Posterolateral	12	4	0	16
Far lateral	40	20	4	64
Extreme lateral	8	4	4	16
Total (%)	60 (62)	28 (30)	8 (8)	96

For the surgical treatment of tumors of craniovertebral and upper cervical region, numerous approaches have been described. They may be conditionally divided into posterior, posterolateral, far lateral and extreme lateral, transcondylar approaches.^[2] The anterior transoral approach at this level is fraught with a number of complications such as vertebral arteries damage in case of too lateral allocation and a wide bone window, difficulties in dura suturing, and high frequency of liquorrhea and meningitis. The anterolateral approach at C0–C3 level requires massive osseous resection, considerable transposition of the vertebral artery, and acute angle of surgical operation. That is why, anterior and anterolateral approaches at C0–C3 level are more acceptable for the removal of extradural tumors of osseous structures and in cases of traumatic lesions.^[2,10,11]

Previous works have reported extremely bad results of the posterior approaches applied to ventral and ventrolateral tumors. Thus, Love *et al.* in 1954 reported that out of 74 operated patients, 34 died.^[12] According to Yasargil and co-authors, in 1980, the death rate was 13.2%, good results were obtained in 69.3%, satisfactory results in 7.9% and bad results in 9.6% of patients.^[13]

In an attempt to reduce the brain stem and spinal cord trauma during the operation and make a better vision of the

ventrolateral surface of spinal cord and medulla, the lateral approaches were offered. Thus, in 1986, Heros offered the far lateral approach, which allowed reaching the craniovertebral and upper cervical region laterally and achieving better visibility of the ventrolateral surface of spinal cord and lower brain stem. George and co-authors, in 1988, applied medial transposition of the vertebral artery. Transposition of the vertebral artery promoted safe removal of occipital condyles and C1 lateral masses with a drill and provided improvement of field of vision of the lower brain stem and spinal cord ventral surface. Sen and Sekhar in 1990 used the transcondylar extreme lateral approach, which made it possible to achieve sufficient ventral surface visibility of the medulla and the upper spinal cord (including the ventral surface of the opposite side), to make surgical manipulations aimed at tumor separation much easier, and to lessen the traction of nervous structures. These techniques have been lately supplemented with several modifications of extreme lateral and far lateral approaches.^[2,11,14,15,16]

At present, in the common opinion of many authors, the choice of approach should depend on factors such as tumor location, its histological structure, tumor density, relation of the tumor to the dura and nervous structures, and the aim of the operation (biopsy, decompression, radical removal).^[16,17]

The main surgical complications in the course of removal of such tumors are connected with trauma of the lower brain stem and the upper spinal cord, and disturbances of their blood supply. It generally occurs due to insufficiency in the surgical field of view, firm tumor density or its ossification. Cases of complications connected with the vertebral artery involvement into the tumor and the development of vasospasm after tumor removal are rare. The lesion of the IX–XI nerves may cause intraoperative bradycardia and low arterial pressure, and in the postoperative period, paresis of the vocal chords, cough and deglutition reflexes disorder. Usually, these disturbances gradually disappear.^[10,16,18]

Owing to the introduction of the extreme lateral approaches, it has become possible to improve the results of operative treatment essentially. Thus, according to Welling and co-authors, among 27 patients with the tumors of craniovertebral localization (18 meningiomas, 3 chordomas, 3 chondrosarcomas, 1 schwannoma, 1 paraganglioma, 1 neuroepithelial cyst), in which the authors applied exclusively extreme lateral transcondylar approach, there were no fatal cases. Transient paresis of vocal chords in four patients, deglutition reflex disorder in one patient, paresis of the hypoglossal nerve in one patient, and liquorrhea in three patients were noted.^[16] According to Parlato (2003), among 15 patients with craniovertebral and upper cervical tumors (7 meningiomas, 3 epidermoids, 3 C1 neurinomas and 2 neurinomas of the lower IX–XI nerves), in 11 patients the extreme lateral transcondylar

approach with partial resection of condyles was applied and in 4 patients the far lateral approach was used. Tumors were removed totally in 11 cases (73.3%) and subtotally in 4 cases (26.7%). The occipitocervical fusion was not applied.^[5]

Rhoton^[19] prefers the application of extreme lateral approach in cases of big craniovertebral meningiomas.^[5] Lot and George reported that the posterolateral approach is advisable with C1 and C2 neurinomas. With neurinomas of ventral localization below C3 level, the anterolateral approach is preferable.^[2]

At present, with the craniovertebral tumors, comparatively simple approaches, as well as the most complicated ones requiring massive osseous resections, transposition of vessels, nerves, subsequent careful plastic of dura mater are applied.^[7] Some authors have observed that methods such as the extreme lateral transcondylar one with extensive or total removal of condyles are too complicated and by themselves entail a danger of after-effects in the form of bleeding from the vertebral veins, lesions of vertebral arteries, traumatizing of the hypoglossal nerve, destabilization of the craniovertebral junction, ischemia of brain stem. The authors believe that it is necessary to choose the least traumatic approach, and in cases where it is possible, to confine to more sparing far lateral approach.^[18,20]

Boulton and Cusimano reported that with craniovertebral tumors of big size, the removal is more favorable than with small ones. It is explained by the fact that debulking of large tumors creates more space for surgical manipulation during the detachment of the remaining tumor capsule from brain stem and dura, with minimal displacement of spinal cord, nerves and vessels, as compared to smaller tumors.^[18,20] According to our data, it is corroborated only in cases with tumors of soft consistency, the volume of which decreases after the removal of their central part.

Conclusion

Therefore, the adequate choice of a surgical approach first depends on the localization of the tumor, its size and the extent to which it has spread. In most cases of extramedullary ventrolateral tumors of craniovertebral and upper cervical localization, far lateral and posterolateral approaches are the most optimum and the least traumatic.

The extreme lateral approach is advisable in cases of big size ventral craniovertebral tumors.

The factors increasing the risk of unsatisfactory functional outcome of a surgical intervention are dense consistency or ossification of the tumor, its big size, carrying out the operation in the presence of severe neurological disorders.

Financial Disclosure: None of the authors have any financial interest in the subject under discussion.

References

- George B, Lot G. Anterolateral and posterolateral approaches to the foramen magnum. *Skull Base Surg* 1995;5:9-19.
- Kawashima M, Tanriover N, Rhoton AL Jr, Ulm AJ, Matsushima T. Comparison of the far lateral and extreme lateral variants of the atlanto-occipital transarticular approach to anterior extradural lesions of the craniovertebral junction. *Neurosurgery*. 2003;53:662-74; discussion 674-5.
- Guidetti B, Spallone A. Benign extramedullary tumors of the foramen magnum. In: Symon L, editor. *Advances and Technical Standards in Neurosurgery*. Vol. 16. Vienna, Austria: Springer-Verlag; 1988. p. 83-120.
- Love JG, Thelen EP, Dodge HW. Tumors of the foramen magnum. *Int Coil Surg* 1954; 22:1-17.
- Parlato C, Tessitore E, Schonauer C, Moraci A. Management of benign craniovertebral junction tumors. *Acta Neurochir (Wien)* 2003;145:31-6.
- Heros RC. Lateral suboccipital approach for vertebral and vertebrobasilar artery lesions. *J Neurosurg* 1986;64:559-62.
- Lot G, George B. The extent of drilling in lateral approaches to the cranio-cervical junction area from a series of 125 cases. *Acta Neurochir (Wien)* 1999;141:111-8.
- Levy W. Spinal neurofibroma. A report of 66 cases and a comparison with spinal meningioma. *Neurosurgery* 1986;18:331-4.
- George B, Dematons C, Cophignon J. Lateral approach to the anterior portion of the foramen magnum. *Surg Neurol* 1988;29:484-90.
- Samii M, Klekamp J, Carvalho G. Surgical results for meningiomas of the craniocervical junction. *Neurosurgery* 1996;39:1086-95.
- Wen HT, Rhoton AL, Katsuta T, de Oliveira EP. Microsurgical anatomy of the transcondylar, supracondylar, and paracondylar extensions of the far-lateral approach. *J Neurosurg* 1997;87:555-85.
- Love JR, Adson AW. Tumors of the foramen magnum. *Trans Amer Neurol Assn* 1941;67:78-81.
- Yasargil MG, Mortara RW, Cureic M. Meningiomas of the basal posterior cranial fossa. In: Krayenbuhl H, editor. *Advances and Technical Standards in Neurosurgery*. Vol 7. Vienna, Austria: Springer-Verlag; 1980. p. 3-115.
- Sen CN, Sekhar LN. An extreme lateral approach to intradural lesions of the cervical spine and foramen magnum. *Neurosurgery* 1990;27:197-204.
- Sen CN, Sekhar LN. Surgical management of anteriorly placed lesions at the craniocervical junction. *Acta Neurochir (Wien)* 1991;108:70-7.
- Welling B, Park Y, Al-Mefty O. Primary extramedullary tumors of the craniovertebral junction. In *Surgery of the craniovertebral junction*. Dickman CA, Spetzler RF, Sonntag VK, editors. Thime, New York: Stuttgart; 1998. p. 239-52.
- Vishteh AG, David CA, Marciano FF, Coscarella E, Spetzler RF. Extreme Lateral Supracerebellar Infratentorial Approach to the Posterolateral Mesencephalon: Technique and Clinical Experience. *Neurosurgery* 2000;46:384-9.
- Suhardja A, Agur AM, Cusimano MD. Anatomical basis of approaches to foramen magnum and lower clival meningiomas: Comparison of retrosigmoid and transcondylar approaches. *Neurosurg Focus* 2003;14:e9.
- Rhoton AL. The far-lateral approach and its transcondylar, supracondylar, and paracondylar extensions. *Neurosurgery* 2000;47(Suppl 1):S195-209.
- Boulton MR, Cusimano MD. Foramen magnum meningiomas: Concepts, classifications, and nuances. *Neurosurg Focus* 2003;14:e10.

How to cite this article: Zozulya YP, Slynko YI, Al-Qashqish II. Surgical treatment of ventral and ventrolateral intradural extramedullary tumors of craniovertebral and upper cervical localization. *Asian J Neurosurg* 2011;6:18-25.

Source of Support: Nil, **Conflict of Interest:** None declared.