

# Prenatal Diagnosis of a Fetus with de novo Supernumerary Ring Chromosome 16 Characterized by Array Comparative Genomic Hybridization

**Pietro Cignini, M.D.,<sup>1</sup> Angela Dinatale, M.D.,<sup>2</sup> Laura D'Emidio, M.D.,<sup>1</sup> Annamaria Giacobbe, M.D.,<sup>2</sup> Elisa Maria Pappalardo, M.D.,<sup>3</sup> Santina Ermito, M.D.,<sup>1</sup> Domenico Bizzoco, Ph.D.,<sup>4</sup> Gianluca Di Giacomo, Ph.D.,<sup>4</sup> Ivan Gabrielli, Ph.D.,<sup>4</sup> Alvaro Mesoraca, Ph.D.,<sup>4</sup> Maurizio Giorlandino, Ph.D.,<sup>1</sup> and Claudio Giorlandino, M.D.<sup>1</sup>**

## ABSTRACT

A fetus with de novo ring chromosome 16 is presented. At 20 weeks' gestation, ultrasound examination demonstrated bilateral clubfoot, bilateral renal pyelectasis, hypoplasia of the corpus callosum, and transposition of the great vessel. Amniocentesis was performed. Chromosome analysis identified a ring chromosome 16 [47,XY,r(16)] and array comparative genomic hybridization (a-CGH) demonstrated that the ring included the euchromatic portion 16p11.2. Postmortem examination confirmed prenatal findings. This is the first case of de novo ring chromosome 16 diagnosed prenatally with a new phenotypic pattern and also reinforces the importance of offering amniocentesis with a-CGH if fetal anomalies are detected.

**KEYWORDS:** Ring chromosome, supernumerary-chromosome, fetal anomalies

The frequency of supernumerary marker chromosomes (SMCs) is estimated to be 0.075% during pregnancy, and ring chromosome represents a small percentage of these aberrations with a rate of 0.0075%.<sup>1</sup> The formation of ring chromosome is usually a de novo event, although cases with family transmission are also described.<sup>2</sup> Ring chromosome could arise from a breakage in the short and/or long arms of chromosome and a subsequent rejoining at the

ends with loss of the distal segment. In other cases, a telomere–telomere fusion mechanism was described without loss of chromosomal material.<sup>2</sup> Therefore, phenotypic abnormalities may result from genes loss following chromosome breakage or from duplication of the genetic material contained within the ring.<sup>2</sup> Due to the rarity of this condition, establishing the prognosis for an affected fetus poses a challenge to the geneticists and obstetricians.

<sup>1</sup>“Artemisia” Fetal–Maternal Medical Centre, Department of Prenatal Diagnosis, Rome; <sup>2</sup>Operative Unit of Obstetrics and Gynecology, Policlinico Universitario “G. Martino,” Messina; <sup>3</sup>Department of Gynaecology and Obstetrics, ARNAS, Garibaldi Nesima Hospital, Catania; <sup>4</sup>Department of Genetics and Molecular Biology, “Artemisia” Fetal–Maternal Medical Centre, Rome, Italy.

Address for correspondence and reprint requests: Pietro Cignini, M.D., Fetal–Maternal Medical Centre “Artemisia” Department of Prenatal Diagnosis, Viale Liegi, 45 00198 Rome, Italy (e-mail:

pietrocignini@fastwebnet.it).

Am J Perinatol Rep 2011;1:29–32. Copyright © 2011 by Thieme Medical Publishers, Inc., 333 Seventh Avenue, New York, NY 10001, USA. Tel: +1(212) 584-4662.

Received: November 3, 2010. Accepted after revision: November 21, 2010. Published online: March 18, 2011.

DOI: <http://dx.doi.org/10.1055/s-0031-1274512>.

ISSN 2157-6998.

**Table 1 Cytogenetic and Clinical Findings in the Nine Published Cases in Adult Life with a Supernumerary Chromosome 16**

Case	Adult Karyotype	Major Clinical Findings	Inheritance	Reference
1	46,xx,r(16)/45,xy, - 16/*	Growth retardation, low birth weight, mental retardation, microcephaly, broad flat nasal bridge, micrognathia, down-turned mouth corners	NA	7
2	46,xx,r(16)/45,xy, - 16	Growth retardation, mental retardation, microcephaly, broad flat nasal bridge, micrognathia, down-turned mouth corners	NA	8
3	46,xx,r(16)	Growth retardation, low birth weight, mental retardation, microcephaly, broad flat nasal bridge, down-turned mouth corners	De novo	6
4	46,xx,del(16)(pter → q11.1::q13 → qter) + r(16)	Broad flat nasal bridge, down-turned mouth corners	NA	9
5	46,xx,r(16)/45,xx, - r(16)	Growth retardation, mental retardation, microcephaly, broad flat nasal bridge, down-turned mouth corners	De novo	10
6	46,xx,r(16)/45,xx, - r(16)/(00)	Growth retardation, low birth weight, mental retardation, microcephaly, broad flat nasal bridge, micrognathia, down-turned mouth corners	De novo	3
7	46,xx,r(16)::(pter or p13 → qter::)/46xy	Speech delay, nonverbal child with autistic features	De novo	11
8	46,xx,r(16)::(p13.1 → q24.3::)	Growth retardation, microcephaly, dysmorphic features(hypertelorism, down-slanted palpebral fissures, bilateral telecanthus, low-set ears, high palate, retrognathia), bilateral cataracts	Maternal origin	4
9	46,XX,r(16)[16]/46,XX[4]	Transitional pre-B acute lymphoblastic leukemia	NA	5

\*Double-size rings and/or open rings and tetraploid cells were also observed.  
NA, not available.

Ring chromosome 16 [r(16)] is a very rare event and has been described only in nine case during adult life (Table 1).<sup>3-11</sup> All patients showed a peculiar phenotype (postnatal growth retardation, mental retardation, microcephaly, broad float nasal bridge, down-turned mouth corners, speech delay, dysmorphic ears). However, given the presence of mosaic cells line in all cases, it is very difficult to make genotype/phenotype correlations.

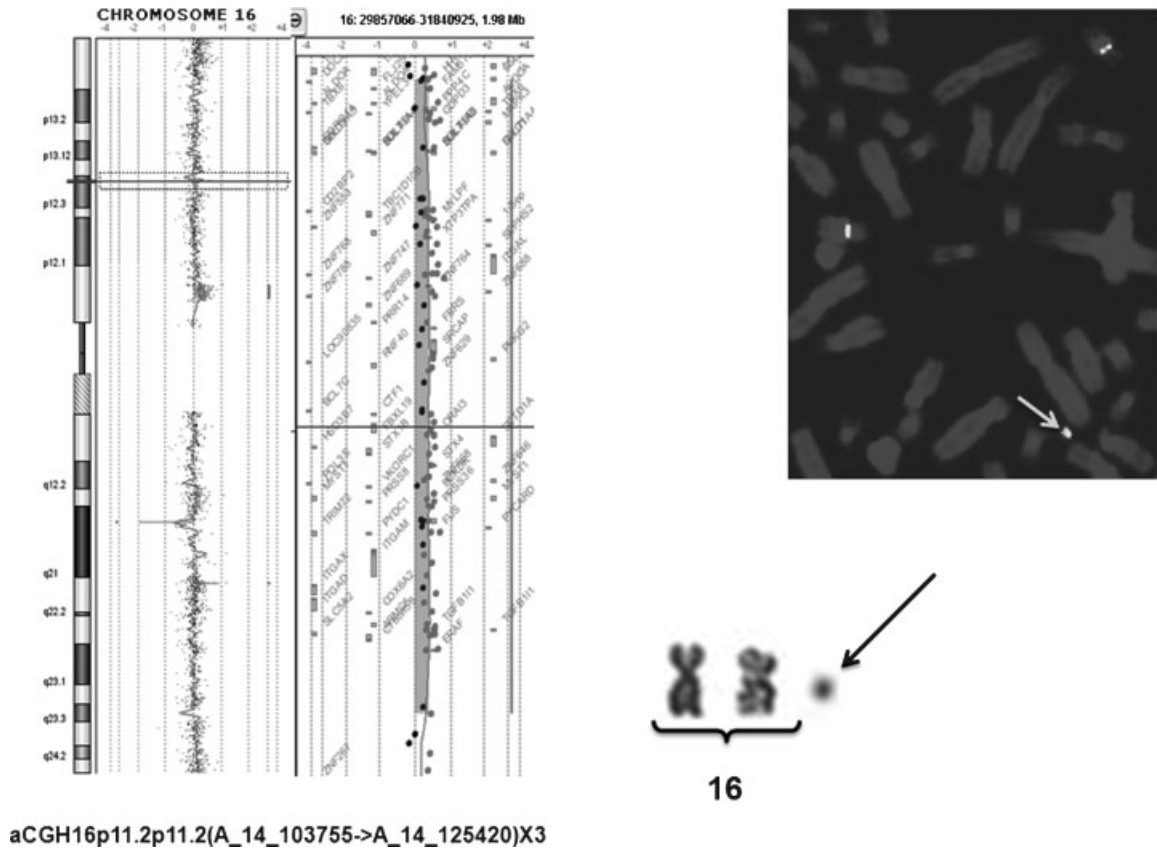
Until today no cases of [r(16)] have been described prenatally.

## METHODS

A 34-year-old nulliparous woman was referred to "Artemisia" Fetal-Maternal Medical Centre at 20 weeks of gestation due to a suspect of transposition of the great vessels in the fetus. The nuchal translucency at 13 weeks was 1.4 mm. The definitive risk for Down syndrome, including also serum analytes, was within normal range. Her past medical history was negative. Both parents were healthy and nonconsanguineous. The pregnancy was uncomplicated. Amniocentesis was not performed.

## RESULTS

Ultrasound examination showed regular fetal growth, bilateral clubfoot, bilateral renal pyelectasis of 9 mm, and hypoplasia of the corpus callosum with a length of 16.8 mm. The corpus callosum was measured in the midsagittal plane, and the length was calculated from the genu to the splenium. The fetal echocardiography confirmed the transposition of the great vessels. Because of the ultrasound findings and after genetic counseling, amniocentesis was performed. Metaphase analysis of amniocytes from three different in situ cultures revealed the presence of [r(16)] with a karyotype of 47,XY,r(16). There was cytogenetically no visible loss of chromosome 16 material. The karyotype of both parents on lymphocyte peripheral blood sample was negative for the [r(16)]. To confirm the findings of the classic cytogenetic, fluorescent in situ hybridization (FISH) was performed using chromosome enumeration probe (CEP) 13/21, CEP 14/22, CEP 15, CEP XY/18 probes to exclude the most frequent SMCs. Then Aquarius<sup>TM</sup> Liquid DNA Probes (Cytocell LED, Cambridge, UK)  $\alpha$  satellite 16 green, cytocell revealed the origin of the SMC (Fig. 1). To determine the exact amounts of euchromatin present in



**Figure 1** The arrows indicate the supernumerary marker chromosomes. (Top right) Results of fluorescent in situ hybridization with probe Aquarius™ Liquid DNA Probes α satellite 16 green, cytozell. (Bottom) Results of array comparative genomic hybridization.

the de novo ring SMC derived from chromosome 16 in due time, array comparative genomic hybridization (CGH) was performed on DNA extracted from amniocytes, using the Agilent Human Genome CGH Microarray Kit 44BX4 (Berkshire, UK) and elaborated by the CGH Analytics Software 4.0.73 (Santa Clara, CA). The result demonstrated that the ring SMC derived from the pericentromeric region of the short arm of a 16 chromosome included the euchromatic portion 16p11.2, having resulted as array CGH 16p11.2p11.2 (A\_14\_P103755 → A\_14\_P125420) × 3. The size of the duplication was estimated to be 1.98 Mb from 29,857,066 to 31,840,925 (Fig. 1).

The patient opted for the termination of pregnancy, and autopsy confirmed all the fetal malformations diagnosed at the ultrasound scan. On internal examination, all the organs were in regular position. No other abnormalities were found.

**DISCUSSION**

To our knowledge, this is the first case of prenatal diagnosis of de novo SMC [r(16)] with no mosaicism in the cell lines. Furthermore, FISH, and more specifically array CGH, revealed that the ring chromosome derived from a duplication of a region in the short arm.

In general, the prenatal diagnosis of a ring chromosome presents a great difficulty in genetic counseling. Particularly, [r(16)] was described only in nine adult cases reported in the literature, characterized mainly by microcephaly, mental and/or growth retardation, flat broad nasal bridge, and slightly down-slanting mouth, which resulted in [r(16)]<sup>4</sup> with adult transitional pre-B acute lymphoblastic leukemia.<sup>5</sup> The abnormalities of the cardiovascular system, central nervous system, and skeletal system present in our case have never been described in association with this chromosomal aberration. Consequently, the clinical correlation or the descriptions of risk groups based on [r(16)] alone or associated with other factors have not yet been demonstrated in these patients. Moreover, no correlation with these cases and ours is possible because of the absence of array CGH characterization.

Mosaicism was not present in our case, whereas it was present in all cases described in adults, making the correlation of a genotype with a specific phenotype very difficult. Only Quintana et al described a case without mosaicism presenting the peculiar symptoms of ring [(16)] syndrome where no genetic material was lost<sup>6</sup>; however, in this case, characterization by array CGH was not performed. Although today it is not yet clear which regions of chromosome 16 determine clinical consequen-

ces, the phenotypic abnormalities associated with ring chromosomes are variable as they depend on the size of the ring, the amount of deleted material, and the degree of aneuploidy.<sup>12</sup> In our case, the FISH revealed that the [r(16)] resulted from a telomere–telomere fusion of palindromic sequences and array CGH confirmed these findings, showing the genes present in this region.

The 16p11.2 is a critical position, associated with several neurodevelopment disorders, such as mental retardation, autism, and schizophrenia, with ~22 genes involved during the development of the fetal nervous system.<sup>13</sup> In our case, the presence of an unisolated hypoplasia of the corpus callosum could be related to a deregulation of this chromosome segment, although no known genes present in this region were directly associated with this malformation. However, because our case was diagnosed in uterus, it was not possible to investigate the mental retardation, but given the malformation of the corpus callosum and the absence of genomic loss during the formation of the ring, it could be speculated that these conditions would be present in the neonatal period. Considering the position in the 16p11.2, we found no known genes involved in the pathogenesis of the abnormalities present in our case. We indeed believe that the cardiac and the skeletal malformations were not directly related to the [r(16)] but could be considered as synchronous abnormalities.

The array CGH technique is an efficient and practical approach to the molecular characterization of chromosomal arrangement and permits to better describe the genes involved in this mechanism. In fact, in addition to conventional cytogenetic analyses and FISH, it permits an accurate identification of the origin and content of marker chromosomes, contributing to a more informed prenatal counseling and patient follow-up. In conclusion, we believe that the introduction of array CGH analysis when ring SMCs are found during the prenatal period will permit in the future a better identification of a genotype/phenotype correlation, providing for an efficient approach to identifying the origin and extent of deleted and duplicated material in chromosomal rearrangements.

## REFERENCES

- Liehr T, Weise A. Frequency of small supernumerary marker chromosomes in prenatal, newborn, developmentally retarded and infertility diagnostics. *Int J Mol Med* 2007;19:719–731
- Kosztolányi G. Does “ring syndrome” exist? An analysis of 207 case reports on patients with a ring autosome. *Hum Genet* 1987;75:174–179
- Vianello MG, Cottafava F, Bartoli D, Franzone G, Casazzava R, Gastaldi R. Ring chromosome 16: a new case. *Ann Genet* 1990;33:36–39
- He W, Tuck-Muller CM, Martínez JE, Li S, Rowley ER, Wertelecki W. Molecular characterization of a ring chromosome 16 from a patient with bilateral cataracts. *Am J Med Genet* 2002;107:12–17
- Callera F, Lopes CO, Rosa ES, Mulin CC. Adult transitional pre-B acute lymphoblastic leukemia associated with ring chromosome 16. *Cancer Genet Cytogenet* 2008;183:131–132
- Quintana A, Sordo MT, Estevez C, Ludena MC, San Marino C. 16 ring chromosome. *Clin Genet* 1983;23:243
- Pergament E, Pietra GC, Kadotani T, Sato H, Berlow S. A ring chromosome No. 16 in an infant with primary hypoparathyroidism. *J Pediatr* 1970;76:745–751
- Neidengard L, Sparkes RS. Ring chromosome 16. *Hum Genet* 1981;59:175–177
- Krauss CM, Caldwell D, Atkins L. Interstitial deletion and ring chromosome derived from 16q. *J Med Genet* 1987;24:308–312
- Chodirker BN, Ray M, McAlpine PJ, et al. Developmental delay, short stature, and minor facial anomalies in a child with ring chromosome 16. *Am J Med Genet* 1988;31:145–151
- Conte RA, Kleyman SM, Kharode C, Verma RS. Delineation of a ring chromosome 16 by the FISH-technique: a case report with review. *Clin Genet* 1997;51:196–199
- Melo JB, Matoso E, Polityko A, et al. Molecular cytogenetic characterization of two cases with de novo small mosaic supernumerary marker chromosomes derived from chromosome 16: towards a genotype/phenotype correlation. *Cytogenet Genome Res* 2009;125:109–114
- Bedoyan JK, Kumar RA, Sudi J, et al. Duplication 16p11.2 in a child with infantile seizure disorder. *Am J Med Genet A* 2010;152A:1567–1574