

# Revision of biliary sphincterotomy by re-cut, balloon dilation or temporary stenting: comparison of clinical outcome and complication rate (with video)



## Authors

Gianfranco Donatelli<sup>1</sup>, Jean-Loup Dumont<sup>1</sup>, Fabrizio Cereatti<sup>2</sup>, Thierry Tuszynski<sup>1</sup>, Bertrand Marie Vergeau<sup>1</sup>, Bruno Meduri<sup>1</sup>

## Institutions

- 1 Unité d'Endoscopie Interventionnelle, Ramsay Générale de Santé, Hôpital Privé des Peupliers, Paris, France
- 2 Digestive Endoscopy and Gastroenterology Unit, A.O. Istituti Ospitalieri di Cremona, Cremona, Italy

submitted 11.11.2016

accepted after revision 8.2.2017

## Bibliography

DOI <https://doi.org/10.1055/s-0043-106183> |  
Endoscopy International Open 2017; 05: E395–E401  
© Georg Thieme Verlag KG Stuttgart · New York  
ISSN 2364-3722

## Corresponding author

Gianfranco Donatelli, Unité d'Endoscopie Interventionnelle, Ramsay Générale de Santé, Hôpital Privé des Peupliers, 8 Place de l'Abbé G. Hénocque, 75013, Paris, France  
Fax: + 33 01 44 16 56 15  
[donatelligianfranco@gmail.com](mailto:donatelligianfranco@gmail.com)

## ABSTRACT

**Background and study aims** Revision of endoscopic retrograde cholangiopancreatography (ERCP) may be necessary following previous biliary endoscopic sphincterotomy for recurrent biliary symptoms related to biliary stone recurrence, cholangitis or post-biliary endoscopic sphincterotomy (bEST) papillary stenosis and cholestasis. The aim of this retrospective study was to evaluate the clinical outcome and complication rate associated with re-cut, balloon dilation and biliary metal stenting in revision ERCP.

**Patients and methods** From January 2010 to January 2015, 139 subjects with stigma of a previous sphincterotomy required a revision ERCP (64 Men/75 Women; mean age 71 years; range 32–101 years). The most appropriate technique (re-cut, balloon dilation or fully covered self-expandable metal stent [FCSEMS] placement) was tailored according to underlying pathologies and anatomical features. **Results** Technical success was achieved in all cases (100%). Clinical success (definitive clearance of common bile duct stones and liver test normalization) was achieved in 127 out of 139 patients (91.4%) with a mean follow up of 12 months.

12 clinical failures occurred: 11 patients required a new ERCP after an average of 9 months meanwhile 1 patient required surgery for definite treatment. The overall complication rate was 9% (13/139) with 5 acute complications (intra-procedural) and 8 short-term complications (before 1 month). Group specific overall complication rates were as follow: re-cut 11.5% (8 bleeds and 3 perforations), balloon dilation 25% (4 mild PEP [post-ERCP pancreatitis]), FCSEMS 14.3% (1 moderate PEP), re-cut+balloon dilation and re-cut+FCSEMS 0%. A statistically significant higher risk of post-ERCP pancreatitis was highlighted in the balloon dilation group meanwhile re-cut was burdened by a higher risk of bleeding and perforation.

**Conclusions** Revision ERCP following previous bEST is a feasible procedure enabling clinical success in most cases. Different approaches are available and must be considered according to underlying pathologies. Re-cut is burdened by a higher risk of perforation and bleeding compared to balloon dilation and SEMs meanwhile balloon dilation is associated to increased risk of PEP.

## Introduction

Endoscopic retrograde cholangiopancreatography (ERCP) coupled with biliary endoscopic sphincterotomy (bEST) is considered the gold standard treatment for choledocholithiasis and several other biliary disorders [1]. Specific bEST short-term complications, namely bleeding, perforation and pancreatitis

occur in up to 10% of the procedures [2, 3]. Long-term sequelae related to bEST include recurrent choledocholithiasis, papillary stenosis, cholangitis and less frequently cholecystitis and malignant degeneration [4].

Revision endoscopic retrograde cholangiopancreatography (ERCP) is needed in case of recurrent biliary symptoms related to recurrent lithiasis or cholestasis due altered biliary emptying.

Extension of a previous sphincterotomy (re-cut), balloon dilation or calibration with temporary plastic or fully covered self-expandable metal stent (FCSEMS) are the viable options to extend the size of the papillary orifice, dilate the distal common bile duct (CBD) and clear the biliary tree. The aim of this retrospective study is to compare the clinical outcome and complication rate of re-cut, balloon dilation and FCSEMS placement for revision of bEST in a single tertiary endoscopic center. Moreover complication rates of revision ERCP will be compared to those of ERCP in case of a naïve papilla.

## Patients and methods

Between January 2010 and January 2015 an average of 1800 ERCPs were performed annually in our Institution. One hundred ninety-one patients presented after a previous biliary sphincterotomy. One hundred thirty-nine of those patients (73%) required a reintervention of the previous bEST and were enrolled in the study (64 Men/75 Women; mean age 71 years; range 32–101 years).

Data were collected in a prospectively maintained database and retrospectively reviewed and analyzed. Informed consent was obtained from all patients. Institutional Review Board approved the study for Human Research (GDS-2010-01-016). Follow-up was performed at 3, 9, 12 and 24 months by means of medical examination or phone interview.

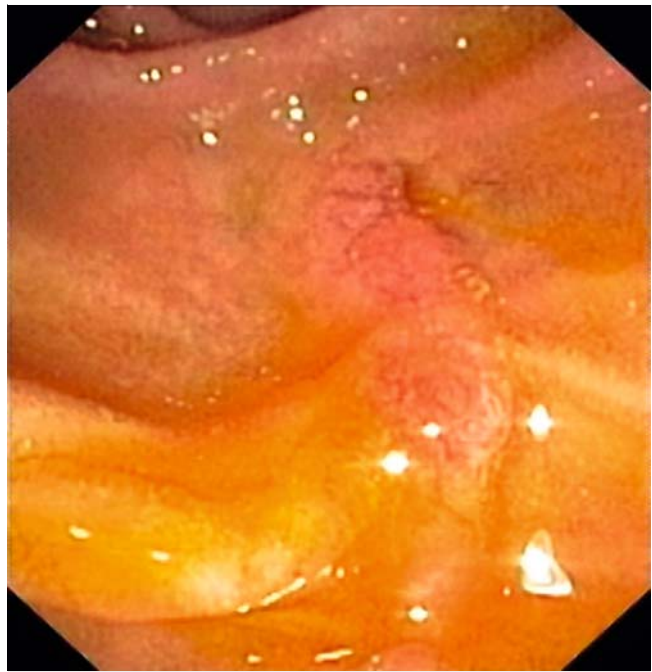The indications for revision ERCP were as follow: cholestasis in 59 patients, jaundice in 48 patients, cholangitis in 25, acute pancreatitis in 6 patients and biliary leak following cholecystectomy in 1 subject.

## Procedure

All procedures were performed under general anesthesia in the supine or left lateral decubitus by an expert endoscopist (GD, JLD, TT, BMV, BM). Prophylactic antibiotics were administered in all cases. Rectal Indomethacin was not routinely administered.

A standard duodenoscope (TJF160R, TJF160 VR, TJF180 V, Olympus®, Japan) was used. Stigma of previous sphincterotomy was defined as the presence of an open biliary orifice coupled with benign-appearing scar tissue (► Fig. 1). Selective cannulation was achieved by means of a standard sphincterotome (Ultratome™ XL, triple lumen, Boston Scientific®, Massachusetts, USA – Papillotome Knife, EndoTherapy™, Olympus®, Tokyo, Japan). Retrograde cholangiography was carried out to evaluate the following features: presence of stones, narrowing of the papillary region and its extension into the CBD, dilation of the proximal CBD and contrast agent flush out from the biliary tree across the bEST. The most appropriate technique (re-cut, balloon dilation or FCSEMS placement) was selected according to the following factors: amount of residual ampullary region (defined as the distance between biliary orifice and transverse fold of the duodenal wall), diameter of the intra-duodenal segment of the CBD and presence of a papillary stricture. A combination of 2 approaches was needed in some cases.

The following technique was adopted to judge the completeness of the previous sphincterotomy: after deep biliary can-



► Fig. 1 Stigma of previous sphincterotomy.

nulation the sphincterotome was retracted pulling the cutting wire halfway outside the papilla and radiologically evaluating its distance from the posterior wall of the CBD. We believe that such an approach is more precise than direct inspection alone allowing to tailor the proper treatment.

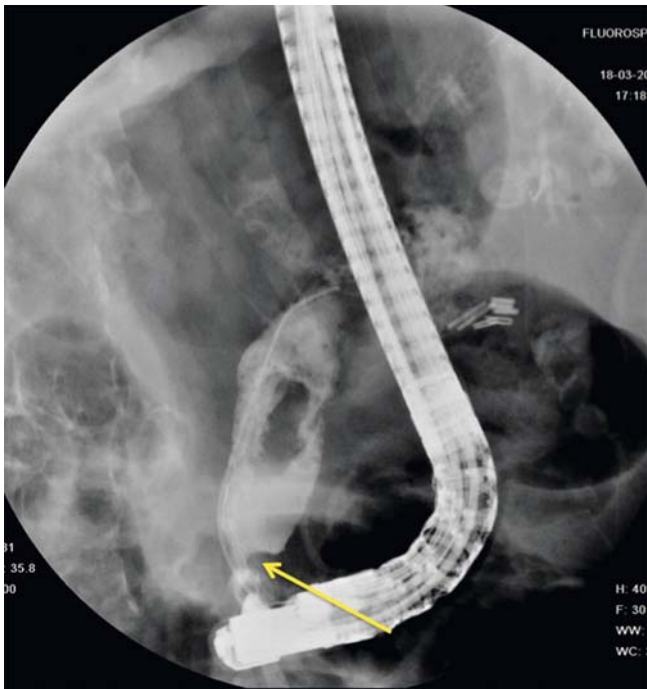
As a general rule if (under radiological view) the cutting wire was distant from the posterior wall of the CBD (► Fig. 2) a re-cut was preferred. This is because such distance was considered as a sign of incomplete sphincterotomy at previous ERCP. Meanwhile if no residual distance between the 2 structures was noted, balloon dilation or SEMS deployment was preferred.

FCSEMS insertion was chosen in the presence of long stricture involving both the papillary region and the distal part of the CBD. Before SEMS deployment, brush cytology was performed to rule out malignancy. Balloon dilation was preferred when a short fibrotic ring of the papilla coupled with stones was present.

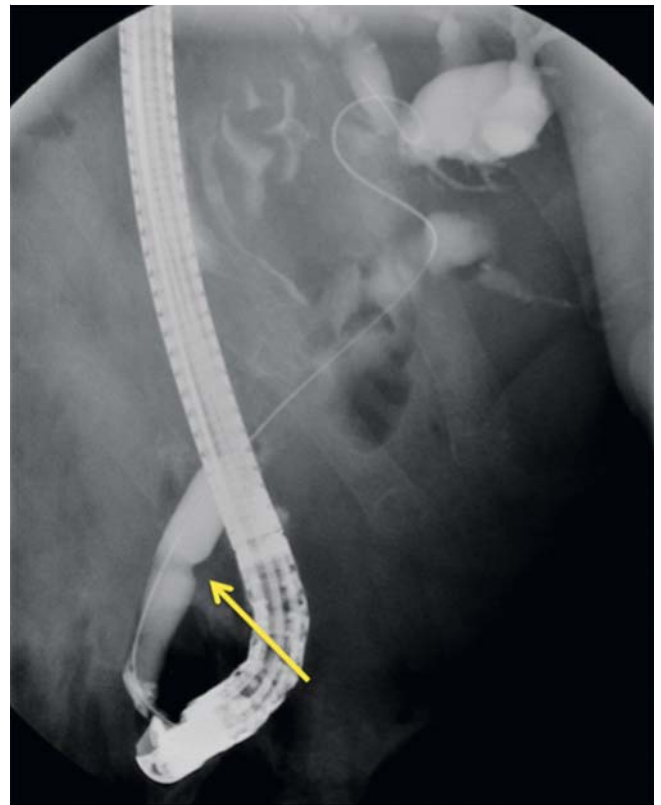
The cut was carried out from the roof of the papillary orifice to the transverse fold using an Endocut mode. Re-cut was considered complete if visualization of the CBD wall was achieved (► Video 1).

Balloon dilation (Hurricane™ or CRE™ Boston Scientific®, Massachusetts, USA) was performed only after placement of a guidewire into the intra-hepatic ducts. Dilation size (from a minimum of 10 mm to a maximum of 20 mm) was decided according to CBD diameter and the balloon was inflated with diluted contrast until the waist disappeared and the pressure then was maintained for at least 1 minute (► Fig. 3).

Fully Covered SEMS (Wallflex™, Boston Scientific®, Massachusetts, USA) was delivered according to standard technique. All stents were 10 mm in diameter and 40 mm or 60 mm in length. Whenever possible the stent was delivered below the



► **Fig. 2** Retracted sphincterotome pulling the cutting wire halfway outside the papilla and radiologically evaluating its distance from the posterior wall of the CBD.



► **Fig. 3** Hydrostatic dilation of fibrotic ring at the papillary region.

cystic duct in order to avoid its occlusion. The stent was kept in place from a minimum of 2 months to a maximum of 6 months (average 4 months) according to stricture degree and patient clinical status. Stent removal was performed in an outpatient setting without any complication. The concomitant need for a combination of 2 techniques was at endoscopist discretion.

### Outcome parameters

Technical success was defined as the ability to complete revision ERCP achieving a successful treatment of underlying pathologies.

► **VIDEO 1**

► Video 1: Revision of a previous sphincterotomy by re-cut  
 Online content viewable at: <https://www.thieme-connect.com/DOI/DOI?10.1055/s-0043-106183>

Complications were defined as any event occurring after revision ERCP that negatively influenced the health status of the patient and were divided in immediate (intra-procedural) and early complications (within 1 month)

Immediate and acute complications were recorded according to Cotton classification [5]. Post-ERCP pancreatitis (PEP) was defined as persistent abdominal pain for more than 24 hours with serum amylase at least 3 times normal. Cholangitis was defined as fever higher than 38°C for more than 24 hours that was thought to have a biliary cause. Hemorrhage was considered only in case of melena or hematemesis associated to a hemoglobin drop of at least 2 g/dL. Perforation was defined according to Stapfer et al. [6] classification and was always confirmed by radiological examination. Cholecystitis and stent migration were recorded as well. Clinical success was defined as the resolution of symptoms (abdominal pain or fever) and the normalization of functional liver tests assessed at 90 days after revision ERCP. Meanwhile clinical success of FCSEMS in the treatment of distal CBD strictures was evaluated at an average of 12 months after stent removal.

### Statistical analysis

Frequency, percentages, means ( $\pm$  SD), and medians were used for descriptive analysis. Categorical variables were compared using Chi-squared test (or Fischer's exact test when necessary). Freeman Halton extension of Fischer test was used as well when necessary.

A two tailed  $P$  value  $<0.05$  was considered statistically significant.

Statistical analyses were performed using IBM SPSS Statistics 20 (IBM Company, Armonk, New York, USA).

## Results

The timespan from index ERCP was known in 101 patients amounting to an average of 44.15 months (1–240). In 38 patients it was not possible to establish the exact timespan although the index ERCP had been performed more than 5 years before revision ERCP. Forty-three of 139 patients underwent index ERCP at our Institution whereas the remaining 96 patients underwent index ERCP elsewhere.

Biliary symptoms were associated with recurrent stones in 115 patients and with abdominal pain and CBD enlargement in 24 patients. A preoperative computed tomography (CT) scan was performed in 76 patients whereas 63 subjects underwent to endosonography (EUS) during the same session of revision ERCP. Demographics and pathological features are reported in

### ► Table 1.

Selective cannulation of CBD was achieved in all 139 patients. One hundred twenty-nine revision ERCs (93%) were performed applying 1 of the 3 techniques described whereas in 10 procedures (7%) a combination of 2 techniques was used. Re-cut was performed in 106 cases (76.5%), balloon dilation in 16 (11.5%) (mean dilation 12 mm; range 10–20mm), FCSEMS insertion in 7 (5%) whereas re-cut plus FCSEMS and re-cut plus balloon dilation respectively in 8 and 2 patients. Technical success was achieved in all 139 patients (100%). Clinical success was achieved in 127 out 139 patients (91.4%) with normalization of liver function test and symptoms resolution at a follow up of 12 months. No patients were lost at follow-up.

The overall complication rate amounted to 9% (13/139 patients). Group-specific overall complication rates were as follow: re-cut 11.5% (8 bleeds and 3 perforations), balloon dilation 25% (4 mild PEP), FCSEMS 14.3% (1 moderate PEP), re-cut +balloon dilation and re-cut+FCSEMS 0%. 5/13 immediate complications and 8/13 short-term complications were recorded. No mortality was observed at a 3 months follow-up.

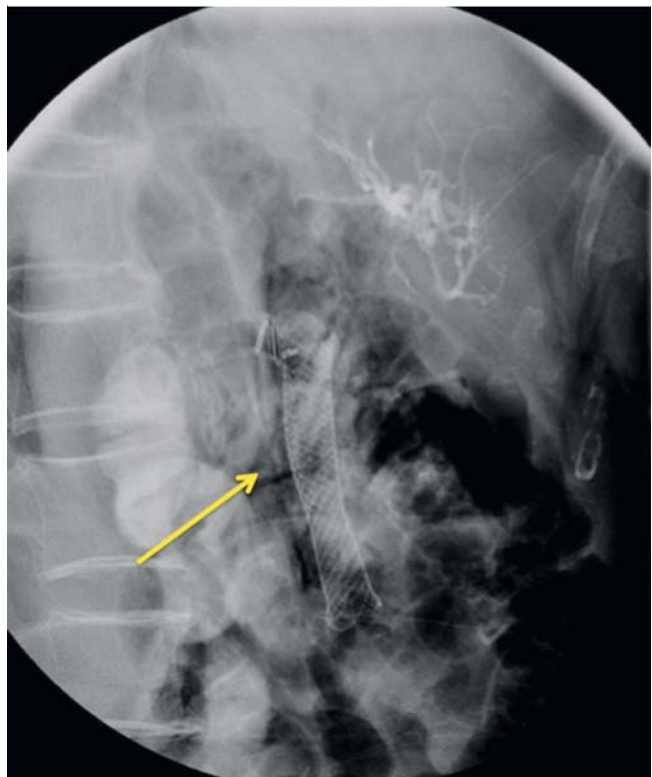
All immediate (intra-procedural) complications occurred in the re-cut group consisting of 3 retroperitoneal perforations (► Fig. 4) and 2 intraoperative bleeds that required FCSEMS deployment after failure of adrenalin injection. No patients needed blood transfusion or Intensive Care Unit admission. Differences in intra-procedural complication rate among the 3 techniques were not statistically significant.

All complications were successfully treated endoscopically, however, hospital stay was prolonged by a maximum of 5 days. The 2 perforations were managed with FCSEMS (10mm × 60mm) deployment. The stents were kept in place for 2 months before removal.

Eight short-term complications occurred: 5 pancreatitis (4 mild, 1 moderate), 2 bleeds (at postoperative day 1 and 4 respectively) and 1 cholangitis. Four of 5 cases of pancreatitis occurred in the balloon dilation group and 1 in the FCSEMS

► Table 1 Demographics and pathological features.

|                                                   |        |
|---------------------------------------------------|--------|
| Number of patients with previous sphincterotomy   | 191    |
| Number of patients enrolled in the study          | 139    |
| Male/female ratio                                 | 64/75  |
| Mean age (yrs)                                    | 71     |
| Range (yrs)                                       | 32–101 |
| Indication for revision ERCP (number of patients) |        |
| Cholestasis                                       | 58     |
| Jaundice                                          | 48     |
| Cholangitis                                       | 25     |
| Pancreatitis                                      | 6      |
| Biliary Leak                                      | 1      |
| Etiology (number of patients)                     |        |
| Recurrent Stones                                  | 114    |
| Papillary stenosis                                | 25     |
| Technique performed (number of patients)          |        |
| Recut                                             | 106    |
| Balloon dilation                                  | 16     |
| FCSEMS                                            | 7      |
| Recut + FCSEMS                                    | 8      |
| Recut + Balloon                                   | 2      |



► Fig. 4 Retroperitoneal perforation with free air (arrow).



► **Table 2** Data on acute and short-term complications

| Acute complications (intra-procedural)                                                                                   |          |             |             |          |
|--------------------------------------------------------------------------------------------------------------------------|----------|-------------|-------------|----------|
|                                                                                                                          | Bleeding | Perforation |             | Total    |
| Recut (%)                                                                                                                | 6 (5.8)  | 3 (2.9)     |             | 9 (8.7)  |
| Balloon dilation (%)                                                                                                     | 0        | 0           |             | 0        |
| FCSEMS (%)                                                                                                               | 0        | 0           |             | 0        |
| Recut + balloon                                                                                                          | 0        | 0           |             | 0        |
| Recut + FCSEMS                                                                                                           | 0        | 0           |             | 0        |
| Short-term complications (1 month)                                                                                       |          |             |             |          |
|                                                                                                                          | Bleeding | PEP         | Cholangitis | Total    |
| Recut (%)                                                                                                                | 2 (1.9)  | 0           | 1 (0.9)     | 3 (2.8)  |
| Balloon dilation (%)                                                                                                     | 0        | 4 (25)      | 0           | 4 (25)   |
| FCSEMS (%)                                                                                                               | 0        | 1 (14.3)    | 0           | 1 (14.3) |
| Recut + balloon                                                                                                          | 0        | 0           | 0           | 0        |
| Recut + FCSEMS                                                                                                           | 0        | 0           | 0           | 0        |
| FCSEMS, fully covered self-expandable metal stent; PEP, post-endoscopic retrograde cholangiopancreatography pancreatitis |          |             |             |          |

group. The cholangitis and the 2 bleeds occurred in the re-cut group (► **Table 2**).

Five of 8 short-term complications were successfully treated with medical treatment only. Meanwhile the PEP in the FCSEMS group required emergency endoscopy to remove the stent and the 2 delayed bleeds in the re-cut group needed blood transfusions and emergency endoscopy with FCSEMS insertion.

A statistically significant difference in PEP rate was highlighted comparing recut versus balloon dilation and FCSEMS placement. Even if not statistically significant a higher risk of perforation and bleeding was observed in the re-cut group.

After an average of 11 months (5–21) 11 out of 139 subjects (9%) required a new ERCP for cholestasis, abdominal pain and stones recurrence. In all cases stones were successfully removed without need for revision of the sphincterotomy. Of note 7 of 11 patients had a lithiasic gallbladder in whom surgical excision was not performed after CBD stone clearance due to poor general status.

One clinical failure was recorded (1/139–0.7%). The patient underwent 5 endoscopic procedures before being definitively treated by surgery.

The patient was a 59-year-old woman undergoing revision ERCP for cholangitis and recurrent biliary stones. Extension of the previous sphincterotomy and stone removal was performed. On postoperative day 4 a FCSEMS deployment was required to control massive post-bEST bleeding. Forty-five days after stent removal the patient presented with an increase in liver function tests. Endoscopic ultrasound examination did not show either stones in the CBD or biliary tree dilation; how-

ever an 8-mm nodule was detected just behind the papillary region, most probably due to extensive fibrosis. Two ERCPs failed to achieve deep biliary cannulation due to severe stenosis of the papillary region. A radiological-endoscopic rendezvous was performed, allowing access to the CBD. Re-cut extension coupled with FCSEMS deployment was carried out in an attempt to treat the stricture. After 10 days the patient was readmitted to the hospital due to abdominal pain and elevation of liver function tests. CT scan highlighted FCSEMS migration and CBD dilation. After multidisciplinary evaluation a hepatico-jejunostomy was performed with complete resolution of biliary symptoms.

## Discussion

Symptomatic papillary stricture and recurrent biliary stones are long-term complications of bEST occurring in 4 to 14% of cases [4, 7] and in most cases requiring a revision ERCP. Post-bEST strictures are a heterogeneous group of stenotic lesions occurring with a frequency of 0.3% to 4.2% [8, 9]. Some authors [10] have divided post-bEST strictures into 2 subtypes: type I when the stricture is confined to the intra-duodenal segment of the CBD and type II when the stenosis extends into the distal segment of the CBD. Although type I stricture may benefit from an extension of the previous bEST, type II stricture always requires dilation of the distal segment of the CBD.

The main risk factor for both type I and type II strictures is the length of bEST at index endoscopy. Several factors may prompt the endoscopist to reduce the extension of bEST, such as anatomical alterations (iuxta-diverticula or intra-diverticula papilla) or intraprocedural complications such as bleeding or suspected retroperitoneal duodenal perforation secondary to periampullary injury (type II according to Stapfer et al) [6]. Moreover bEST extension is often tailored according to the ERCP indication. A small incision is usually adequate for stent insertion and reduce the risk of PEP [11] whereas stone extraction may require larger incision. Moreover it is fundamental to keep in mind that the extension of bEST decreases over time [12].

As a general rule we applied the 3 different techniques according to symptom etiology and biliary anatomical condition highlighted during the diagnostic phase of revision ERCP. It is fundamental to correctly evaluate (both endoscopically and radiologically) the papillary region and the last segment of the CBD in order to adopt the most suitable strategy.

Recut was performed when the previous bEST was considered incomplete with persistence of intra-duodenal segment of the CBD especially if stones were reported. Balloon dilation was chosen when a short fibrotic papillary stricture was detected (type I stricture). Meanwhile FCSEMS was preferred for type II stricture [13].

Placement of temporary multiple large-bore plastic stents has become a standard endoscopic treatment for benign CBD stricture. Several studies have demonstrated the efficacy of the multiple plastic stents technique. A key feature of such a technique is to allow a gradual dilation of the CBD over a long period of time [14–16]. However multiple endoscopic sessions

are required to progressively increase the number of stents over a 1-year period, presumably increasing overall cost and reducing patient compliance. For such reasons we preferred to deploy a FCSEMS for management of type II stricture with a scheduled indwelling time of 4 months.

Several case series of revision ERCP are present in the literature [10, 17–9]; however, these studies evaluated the outcome of a single technique only. Veldkap et al [13] in 2007 reported for the first time the outcome of revision ERCP according to the different and currently adopted techniques (recut, balloon dilation or plastic biliary stenting). A total of 49 patients were treated for a type I or type II stricture with an overall complication rate of 16% requiring emergency surgical procedure in 2 out of the 8 complications.

We reported an overall complication rate of 9% for revision ERCP and none of the complications required surgery. This complication rate is comparable to the complication rates of ERCP in the setting of naïve papilla. [20]

Interestingly we showed that in contrast to index ERCP, the type of complication is partly related to the technique used to perform revision ERCP (recut, balloon dilation or FCSEMS).

Re-cut is considered at higher risk of bleeding, probably due to increased vascularization after previous sphincterotomy [21] and increased probability to dissect larger blood vessels close to the terminal part of CBD; similarly, due to the reduced length of intraduodenal segment of the CBD, re-cut is burdened by a higher risk of perforation.

Interestingly early recut (within 7 days) seems to be technically more demanding and associated with a higher complication rate [7, 19, 22].

In our study we experienced 4 (3.8%) bleeds (2 intra-procedural and 2 delayed) in the recut group and none in the remaining 2 groups (balloon dilation and FCSEMS deployment). However no statistically significant difference was highlighted in bleeding rate according to the technique applied ( $P=0.6390$ ) due to small sample size in 2 out of 3 techniques applied.

All bleeds were endoscopically treated with FCSEMS.

We believe FCSEMS placement is a useful “salvage therapy” to control post-bEST bleeding as first intention or after failure of conventional techniques (adrenalin injection or clipping). Although bleeding despite a FCSEMS placement has been anecdotally described [23] a covered stent in most cases allows a mechanical hemostasis guaranteeing long-term compression on the bleeding point.

The second most frequent complication in the study was PEP. Interestingly a statistically significant difference in PEP rate was highlighted between the 3 different technique (recut 0%; balloon dilation 25%; FCSEMS 14.3%;  $P<0.001$ ). This could be explained by the fact that when extending a previous b-EST (recut) the biliary and the pancreatic orifice are already divided whereas balloon dilation or FCSEMS may induce pancreatic traumatism or pancreatic orifice occlusion.

At last, 3 type II perforations (2.9%) were recorded in the recut group. No perforations were reported in the balloon dilation or FCSEMS groups but such different rates were not statistically significant ( $P<0.716$ ). All perforation were managed with FCSEMS placement. Fully covered stent placement is effective

to treat such perforation if no retroperitoneal fluid collection is present [24]. Early CT scan, Nil Per Mouth and antibiotics are mandatory when a post-ERCP perforation is suspected.

Our study has some limitations related to its retrospective design, the short follow-up and the inability to determine the indications for index ERCP. However it is the first study to evaluate, in a large study population, clinical outcomes of revision ERCP according to the different techniques adopted and to correlate them with the type and rate of complication.

## Conclusion

Our study demonstrated that recut, balloon dilation and FCSEMS are effective approaches in case of revision ERCP and associated with a complication rate similar to ERCP on naïve papilla. We believe that careful evaluation (both endoscopic and radiological) of the papillary region and of the last part of the CBD is mandatory to decide the most suitable technique.

When performing recut it is pivotal to correctly judge the length of the remaining intraduodenal CBD in order to reduce the risk of perforation and bleeding. Whereas in case of balloon dilation and FCSEMS placement attention must be paid to reduce the risk of PEP. Moreover early recognition of the different complications allows endoscopic management in most cases.

## Competing interests

None

## References

- [1] Williams EJ, Green J, Beckingham I et al. British Society of Gastroenterology Guidelines on the management of common bile duct stones (CBDS). *Gut* 2008; 57: 1004–1021
- [2] Christensen M, Matzen P, Schulze S et al. Complications of ERCP: a prospective study. *Gastrointest Endosc* 2004; 60: 721–731
- [3] Sherman S, Ruffolo TA, Hawkes RH et al. Complications of endoscopic sphincterotomy: a prospective series with emphasis on increased risk associated with sphincter of Oddi dysfunction and non-dilated bile ducts. *Gastroenterology* 1991; 101: 1068–1075
- [4] Costamagna G, Tringali A, Shah SK et al. Long-Term Follow-Up of Patients After Endoscopic Sphincterotomy for Choledocholithiasis and Risk Factors for Recurrence. *Endoscopy* 2002; 34: 273–279
- [5] Cotton PB, Lehman G, Vennes J et al. Endoscopic sphincterotomy complications and their management: an attempt at consensus. *Gastrointest Endosc* 1991; 37: 383–393
- [6] Stapfer M, Selby RR, Stain SC et al. Management of duodenal perforation after endoscopic retrograde cholangiopancreatography and sphincterotomy. *Ann Surg* 2000; 232: 191–198
- [7] Testoni PA. Repeat Sphincterotomy: Does its safety depend on the interval from the initial procedure? *Am J Gastroenterol* 2003; 98: 1
- [8] Seifert E. Long-term follow up after endoscopic sphincterotomy (EST). *Endoscopy* 1988; 20: 232–235
- [9] Ikeda S, Tanaka M, Matsumoto S et al. Endoscopic sphincterotomy: long term results in 480 patients with complete follow up. *Endoscopy* 1988; 20: 13–17

- [10] Bourke MJ, Elfant AB, Scheider D et al. Sphincterotomy-associated biliary strictures: features and endoscopic management. *Gastroint Endosc* 2000; 52: 494–499
- [11] Cui PJ, Yao J, Zhao YJ et al. Biliary stenting with or without sphincterotomy for malignant biliary obstruction: a meta-analysis. *World J Gastroenterol* 2014; 20: 14033–14039
- [12] Geenen JE, Toouli J, Hogan WJ et al. Endoscopic sphincterotomy: follow up evaluation of effects on the sphincter of Oddi. *Gastroenterology* 1984; 87: 754–758
- [13] Veldkamp MC, Rauws EA, Dijkgraaf MG et al. Iatrogenic ampullary stenosis: history, endoscopic management, and outcome in a series of 49 patients. *Gastrointest Endosc* 2007; 66: 708–716
- [14] Costamagna G, Tringali A, Mutignani M et al. Endotherapy of post-operative biliary strictures with multiple stents: results after more than 10 years of follow-up. *Gastrointest Endosc* 2010; 72: 551–557
- [15] Dumonceau JM, Tringali A, Blero D et al. Biliary stenting: indications, choice of stents and results: European Society of Gastrointestinal Endoscopy (ESGE) clinical guideline. *Endoscopy* 2012; 44: 277–298
- [16] Fiocca F, Salvatori FM, Fanelli F et al. Complete transection of the main bile duct: minimally invasive treatment with an endoscopic-radiologic rendezvous. *Gastrointest Endosc* 2011; 74: 1393–1398
- [17] Maltz GS, Geenen JE. Is there an increased risk of complications from repeat endoscopic sphincterotomy? *Am J Gastroenterol* 1990; 85: 1253
- [18] Mavrogiannis C, Liatsos C, Papanikolaou IS et al. Safety of extension of a previous endoscopic sphincterotomy: a prospective study. *Am J Gastroenterol* 2003; 1: 72–76
- [19] Sugiyama M, Suzuki Y, Abe N et al. Endoscopic treatment of recurrent choledocholithiasis after sphincterotomy. *Gut* 2004; 53: 1856–1859
- [20] Andriulli A, Loperfido S, Napolitano G et al. Incidence rates of post-ERCP complications: a systematic survey of prospective studies. *Am J Gastroenterol* 2007; 102: 1781–1788
- [21] Leung JWC, Chan FKL, Sung JJY et al. Endoscopic sphincterotomy-induced hemorrhage: a study of risk factors and the role of epinephrine injection. *Gastroint Endosc* 1995; 42: 550–554
- [22] Stolte M, Wiessner V, Schaffner O et al. Vaskularization der papilla Vateri und blutungsgefahr bei der papillotomie. *Leber Magen Darm* 1980; 10: 293–301
- [23] Donatelli G, Cereatti F, Dumont JL et al. Post-biliary sphincterotomy bleeding despite covered metallic stent deployment. *SAGE Open Medical Case Reports* 2016; 4: 1–3
- [24] Canena J, Liberato M, Horta D et al. Short-term stenting using fully covered self-expandable metal stents for treatment of refractory biliary leaks, post-sphincterotomy bleeding, and perforations. *Surg Endosc* 2013; 27: 313–324