

SHORT REPORT

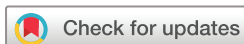MRI of psoriatic nail disease pre- and post-TNF inhibitor therapy shows persistent subclinical inflammation after 6 months despite good clinical response

Zoe Ash,^{1,2} Ai Lyn Tan,^{1,2} Richard J Hodgson,^{1,2} Andrew Grainger,^{1,2}
Helena Marzo-Ortega,^{1,2} Dennis G McGonagle^{1,2}

To cite: Ash Z, Tan AL, Hodgson RJ, *et al*. MRI of psoriatic nail disease pre- and post-TNF inhibitor therapy shows persistent subclinical inflammation after 6 months despite good clinical response. *RMD Open* 2018;**4**:e000599. doi:10.1136/rmdopen-2017-000599

This paper has been previously published online as part of a Doctor of Medicine Thesis, University of Leeds Ethos. ID: uk.bl.ethos.589288.

Received 13 October 2017
Revised 7 January 2018
Accepted 9 January 2018



¹Leeds Institute of Rheumatic and Musculoskeletal Medicine, University of Leeds, Leeds, UK
²NIHR Leeds Biomedical Research Centre, Leeds Teaching Hospitals NHS Trust, Leeds, UK

Correspondence to
Professor Dennis G McGonagle;
d.g.mcgonagle@leeds.ac.uk

Nail involvement is part of the clinical spectrum of psoriatic disease and is microanatomically associated with distal interphalangeal joint (DIPJ) entheses.¹ Tumour necrosis factor (TNF) inhibitors have shown efficacy for psoriasis, arthritis, enthesitis, dactylitis and nail disease.² Given the intimate links between psoriatic arthritis (PsA) and nail disease, it might be expected that nail disease improvement would be associated with resolution of the underlying arthropathic features.

All participants gave written consent. All cases fulfilled the Classification Criteria for Psoriatic Arthritis (CASPAR) criteria for PsA.³ All cases were due to start TNF inhibitor therapy for active PsA. A clinical and MRI assessment was performed at baseline and after 6 months of treatment.

High-resolution MRI was performed on one finger, with gadolinium contrast and Vaseline applied to the nail.⁴ The target finger for imaging was selected for current nail disease and active DIPJ arthritis. The MRIs were scored as previously reported.⁵ Seven patients were recruited. All patients had tenderness and swelling of the target finger's DIPJ at baseline. TNF inhibitor prescription was made according to the National Institute for Health and Care Excellence guidelines. Four patients received etanercept and three adalimumab.

Marked improvements were seen in clinical parameters at 6 months. No patients had residual clinical swelling in the target DIPJ and one had persistent tenderness (table 1). Onycholysis and pitting were the most frequent abnormalities at baseline. Two patients had completely normal nails in the target finger at 6 months, with no difference in nail clearance between nail matrix features and nail-bed abnormalities.

Key messages

What is already known about this subject?

- ▶ Nail involvement is part of the clinical spectrum of psoriatic arthritis and responds to tumour necrosis factor (TNF) inhibitors.

What does this study add?

- ▶ This small study assessed patients with psoriatic arthritis with nail disease and active distal interphalangeal (DIP) arthritis before and after 6 months of TNF inhibitor treatment.
- ▶ Persistent inflammatory changes in and around the DIP joint were seen on follow-up MRI scans despite a good clinical response.

How might this impact on clinical practice?

- ▶ Further studies are needed to see whether these inflammatory changes resolve with a longer duration of treatment or relate to radiographic progression of the arthritis.

Baseline MRI scans showed DIPJ enthesitis, bone marrow oedema (BMO) or synovitis in all patients (86%, 71% and 100%, respectively) (table 2). Collateral ligament enthesopathy was seen in 86%, flexor tendon enthesopathy in 71% and extensor tendon enthesopathy in 86%. Three patients with purely nail-bed nail disease at baseline also had marked underlying BMO, synovitis and enthesitis on MRI.

Follow-up MRI scans surprisingly showed persistent inflammatory changes in the DIPJ, distal phalanx and soft tissues around the nail (table 2, figure 1). No patient with baseline BMO showed complete resolution, and four of the five had no change in BMO score. All seven patients had synovitis at baseline; this resolved in two, improved in one, was unchanged in three and worsened in one patient. No patient

Table 1 Clinical assessments

	Baseline	6 months
PASI Median (range)	2.9 (0.2–7.3)	0.2 (0–1.8)
Swollen joint count Mean (SD)	11 (6)	1 (1)
Tender joint count Mean (SD)	12 (7)	1 (1)
SPARCC Enthesitis Index Mean (SD)	3.4 (2)	0.4 (1)
mNAPSI Mean (SD)	28 (15)	9 (6)
mNAPSI in the target finger Median (range)	3 (3–5)	1 (0–2)
Visual analogue score for nail pain Median (range)	12 (0–60)	0 (0–2)

PASI, Psoriasis Area and Severity Index; SPARCC, Spondyloarthritis Research Consortium of Canada Enthesitis Index; mNAPSI, modified Nail Psoriasis Severity Index.

had complete resolution of extensor tendon abnormalities. Collateral ligament abnormalities were largely unchanged. No relationship was seen between the MRI changes and clinical response to treatment.

Previous PsA MRI studies have shown conflicting data regarding the resolution of inflammation with TNF inhibitors, some reporting improvements or resolution,

Table 2 MRI scores for each patient

Patient	BMO score (0–3)		Synovitis score (0–2)		Comments
	Baseline	Follow-up	Baseline	Follow-up	
A	0	0	1	0	No enthesitis
B	2	2	2	2	Marked changes but overall improvement
C	3	3	1	2	Effusion resolved at follow-up
D	2	1	2	0	Flexor tendon changes resolved
E	0	0	1	1	Persistent enthesopathy collateral ligaments and extensor tendon
F	2	2	2	2	Overall improvement on follow-up scan despite persistent BMO
G	1	1	2	1	Marked improvement in collateral ligaments

BMO, bone marrow oedema.

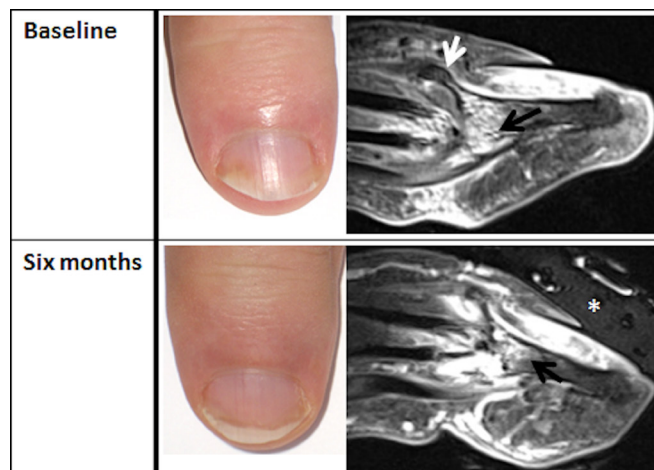


Figure 1 Nail photographs and MRI scans of a patient with psoriatic arthritis. Improvements in the nail appearances are seen on the photograph. Vaseline (asterisk) is seen overlying the nail on MRI. At baseline, a large enthesophyte is seen at the extensor tendon enthesis (white arrow) with diffuse bone marrow changes (black arrow). After 6 months of treatment with etanercept, persistent bone marrow changes are seen (black arrow), with a greater degree of synovitis.

others finding persistent inflammation.^{6–10} In one study, greater reductions in BMO volume were seen at 18 months than 6 months.¹⁰ Our data are limited by the small number of patients and short duration of follow-up. In conclusion, our study demonstrated persistent subclinical musculoskeletal inflammation on MRI despite a good clinical response. Further imaging in larger cohorts with a longer duration of follow-up is needed to demonstrate the natural history of inflammatory lesions under therapy and the potential link to disease progression.

Contributors All authors contributed to the design and data collection and analysis.

Funding This research is supported by the National Institute for Health Research (NIHR) Leeds Biomedical Research Centre. The views expressed are those of the authors and not necessarily those of the NHS, the NIHR or the Department of Health. ZA was supported by an unrestricted educational grant from Merck Sharp & Dohme.

Competing interests ZA: unrestricted educational research grant from Merck Sharp & Dohme, and funding to attend conferences and/or speaking fees from Abbott, Chugai, Pfizer and MSD. HM-O: honoraria and/or speaking fees from AbbVie, Celgene, Janssen, Lilly, MSD, Pfizer and UCB. DGM: honoraria and/or speaking fees from Abbott, MSD, Pfizer, UCB and Janssen.

Ethics approval Ethical approval for this small pilot study was obtained from Leeds Ethics.

Provenance and peer review Not commissioned; externally peer reviewed.

Data sharing statement No additional data are available.

Open Access This is an Open Access article distributed in accordance with the Creative Commons Attribution Non Commercial (CC BY-NC 4.0) license, which permits others to distribute, remix, adapt, build upon this work non-commercially, and license their derivative works on different terms, provided the original work is properly cited and the use is non-commercial. See: <http://creativecommons.org/licenses/by-nc/4.0/>

© Article author(s) (or their employer(s) unless otherwise stated in the text of the article) 2018. All rights reserved. No commercial use is permitted unless otherwise expressly granted.

REFERENCES

1. Tan AL, Benjamin M, Toumi H, *et al.* The relationship between the extensor tendon enthesis and the nail in distal interphalangeal joint disease in psoriatic arthritis—a high-resolution MRI and histological study. *Rheumatology* 2007;46:253–6.
2. Reich K, Ortonne JP, Kerkmann U, *et al.* Skin and nail responses after 1 year of infliximab therapy in patients with moderate-to-severe psoriasis: a retrospective analysis of the EXPRESS Trial. *Dermatology* 2010;221:172–8.
3. Taylor W, Gladman D, Helliwell P, *et al.* Classification criteria for psoriatic arthritis: development of new criteria from a large international study. *Arthritis Rheum* 2006;54:2665–73.
4. Scarpa R, Soscia E, Peluso R, *et al.* Nail and distal interphalangeal joint in psoriatic arthritis. *J Rheumatol* 2006;33:1315–9.
5. Tan AL, Grainger AJ, Tanner SF, *et al.* A high-resolution magnetic resonance imaging study of distal interphalangeal joint arthropathy in psoriatic arthritis and osteoarthritis: are they the same? *Arthritis Rheum* 2006;54:1328–33.
6. Bongartz T, Härle P, Friedrich S, *et al.* Successful treatment of psoriatic onycho-pachydermo periostitis (POPP) with adalimumab. *Arthritis Rheum* 2005;52:280–2.
7. Marzo-Ortega H, McGonagle D, Rhodes LA, *et al.* Efficacy of infliximab on MRI-determined bone oedema in psoriatic arthritis. *Ann Rheum Dis* 2007;66:778–81.
8. Antoni C, Dechant C, Hanns-Martin Lorenz PD, *et al.* Open-label study of infliximab treatment for psoriatic arthritis: clinical and magnetic resonance imaging measurements of reduction of inflammation. *Arthritis Rheum* 2002;47:506–12.
9. Anandarajah AP, Ory P, Salonen D, *et al.* Effect of adalimumab on joint disease: features of patients with psoriatic arthritis detected by magnetic resonance imaging. *Ann Rheum Dis* 2010;69:206–9.
10. Anandarajah AP, Schwarz EM, Totterman S, *et al.* The effect of etanercept on osteoclast precursor frequency and enhancing bone marrow oedema in patients with psoriatic arthritis. *Ann Rheum Dis* 2008;67:296–301.