



## Case Report

# Marked improvement in febrile infection-related epilepsy syndrome after lidocaine plus MgSO<sub>4</sub> treatment in a 12-year-old girl

I-Ching Chou<sup>a,b</sup>, Huan-Cheng Lai<sup>a</sup>, Fuu-Jen Tsai<sup>a,c</sup>, Yu-Tzu Chang<sup>a</sup>, Sheng-Shing Lin<sup>a</sup>, Syuan-Yu Hong<sup>a,\*</sup>, Inn-Chi Lee<sup>d,e,\*\*</sup>

<sup>a</sup> Department of Pediatrics, Children's Hospital, China Medical University Hospital, Taichung, Taiwan

<sup>b</sup> Graduate Institute of Integrated Medicine, College of Chinese Medicine, China Medical University, Taichung, Taiwan

<sup>c</sup> Department of Medical Research, China Medical University and Hospital, Taichung, Taiwan

<sup>d</sup> Division of Pediatric Neurology, Department of Pediatrics, Chung Shan Medical University Hospital, Taichung, Taiwan

<sup>e</sup> Institute of Medicine, School of Medicine, Chung Shan Medical University, Taichung, Taiwan



## ARTICLE INFO

## Article history:

Received 14 February 2016

Received in revised form 26 April 2016

Accepted 13 May 2016

Available online 2 June 2016

## Keywords:

Febrile infection-related epilepsy syndrome

FIRES

Status epilepticus

Lidocaine

MgSO<sub>4</sub>

## ABSTRACT

**Purpose:** This report sheds light on a successful treatment in febrile infection-related epilepsy syndrome (FIRES) with the combined use of lidocaine and MgSO<sub>4</sub>.

**Methods:** We report a 12-year-old previously healthy girl who experienced an upper respiratory infection with fever and headache for 2 days, then suddenly went into a coma followed by repetitive status epilepticus. All tests for CNS infection, metabolic and toxic diseases, and autoimmune encephalitis were negative. Hence, the diagnosis of FIRES was made. During 5 weeks of hospital treatment, various antiepileptic drugs were administered at different times without success. To achieve seizure control, we then attempted the use of lidocaine first, then followed by MgSO<sub>4</sub>.

**Results:** The SE was successfully controlled when lidocaine plus MgSO<sub>4</sub> was introduced. At follow-up, almost no neurological sequelae remained.

**Conclusion:** This is the first report describing the combined use of lidocaine and MgSO<sub>4</sub> with successful treatment outcomes. This experience has indicated that even FIRES can be controlled if treated promptly with certain agents. However, more studies are needed to explore the mechanisms and effects of lidocaine and MgSO<sub>4</sub> in FIRES.

© 2016 The Authors. Published by Elsevier Inc. This is an open access article under the CC BY-NC-ND license (<http://creativecommons.org/licenses/by-nc-nd/4.0/>).

## 1. Introduction

Febrile infection-related epilepsy syndrome (FIRES), also known as devastating epileptic encephalopathy in school-aged children or acute encephalitis with refractory repetitive partial seizures, is an acute and explosive-onset epileptic encephalopathy with a fatal outcome, which occurs in previously healthy children following a nonspecific febrile illness [1,2]. The precise etiology of this syndrome and the effective treatment options remain unclear. Herein, we present our experience in treating a 12-year-old girl with FIRES, who dramatically recovered from this devastating encephalitis after treatment with a combination of lidocaine and MgSO<sub>4</sub>.

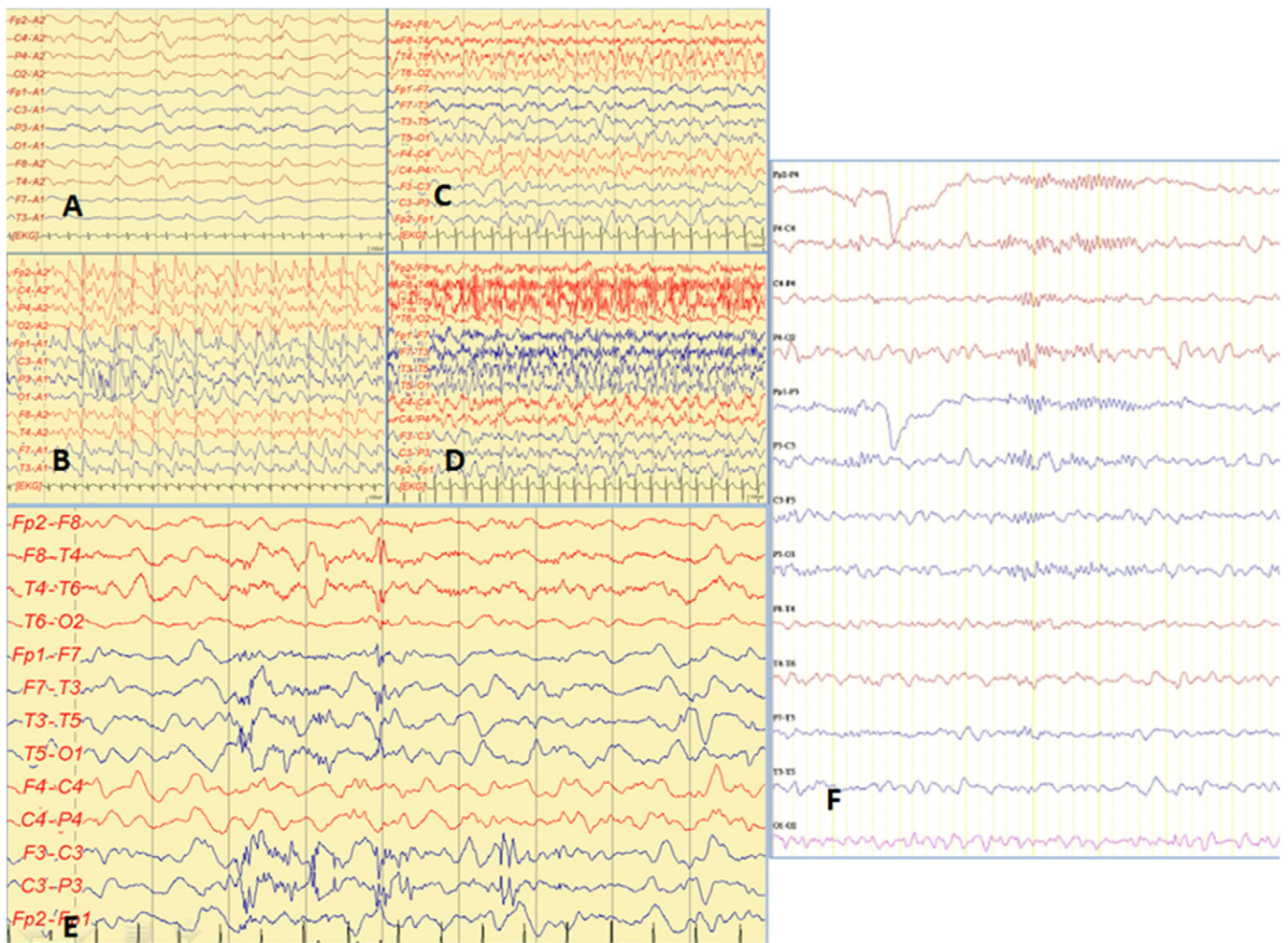
\* Correspondence to: S.-Y. Hong, Department of Pediatrics, China Medical University Hospital, 2 Yuh-Der Road, Taichung 404, Taiwan. Tel.: +886 4 2205 2121.

\*\* Correspondence to: I.-C. Lee, Division of Pediatric Neurology, Department of Pediatrics, Chung Shan Medical University Hospital, Taichung, Taiwan, No. 110, Sec. 1, Jianguo N. Rd., South Dist., Taichung City 402, Taiwan. Tel.: +886 4 2473 9595.

E-mail addresses: [dazingdog@hotmail.com](mailto:dazingdog@hotmail.com) (S.-Y. Hong), [y610@mercury.csmu.edu.tw](mailto:y610@mercury.csmu.edu.tw) (I.-C. Lee).

## 2. Case report

A 12-year-old girl was admitted to our emergency department with complaints of severe headache, dizziness, and fever (38 °C). Prior to her admission, she was healthy without any epileptic disorders and had normal development. The patient did not have a familial history of any epileptic or genetic metabolic disease. A week prior to admission, she experienced fever, sore throat, and fatigue and was treated for acute pharyngitis. On admission, she had a Glasgow Coma Scale (GCS) score of 12. On Day 2 of admission, her condition worsened rapidly, and she fell into a state of coma (GCS score of 3). She then manifested intractable status epilepticus (SE) with generalized tonic-clonic seizures, accompanied by tachycardia, respiratory compromise, and hypotension alternating with myoclonic jerks of both lower limbs. Although SE was temporarily stabilized by administration of BZD agents, the focal myoclonic seizures, involving both lower limbs alternatively, did not stop. Interictal electroencephalography (EEG) revealed diffuse slow delta activity (Fig. 1), distributed with frequent bouts of ictal fast activity. Initially, central nervous system infection was highly suspected, and so we initiated antibiotic and antiviral treatments; however, these were



**Fig. 1.** (A) On Day 1 of admission, the patient was in a state of deep coma; electroencephalography (EEG) background consisted of slow delta waves (3–4 Hz, 25–50  $\mu$ V). (B) On Day 2, the EEG pattern shifted to a slow background mixed with numerous spikes or sharp-wave activity from both hemispheres. (C and D) On Day 3, 8–9 s before the generalized seizure occurred, the EEG pattern in the right frontal–temporal region transformed into fast low-voltage activities (C) and quickly entered a state of generalized fast low-voltage activities. In the clinical setting, generalized tonic–clonic seizure appeared (D). (E) On Day 31 of admission (3 days of lidocaine use prior to the introduction of  $MgSO_4$ ), the EEG background consisted of a slow theta wave (4–5 Hz, 25–50  $\mu$ V) interspersed with paroxysmal spike activities. (F) On Day 35, after the introduction of lidocaine for 7 days and  $MgSO_4$  for 4 days, neither clinical seizures nor epileptiform activities on EEG were noted.

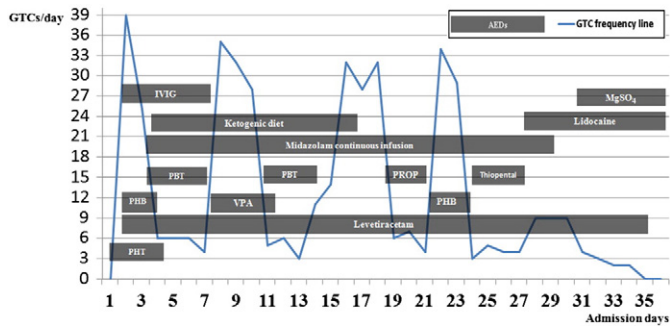
ineffective. Simultaneously, multiplex polymerase chain reaction, microarray, high-throughput sequencing, and molecular biological detection to detect encephalitis with unknown pathogens based on Taiwan Pathogenic Microorganism Genome Database were performed, but all test results were negative.

Unrevealing laboratory investigations included arterial blood gas analysis; complete blood count; blood glucose level; electrolyte panel; serum concentrations of blood urea nitrogen, creatinine, calcium, magnesium, phosphate, and liver enzymes (aspartate aminotransferase, alanine transaminase, coagulation studies, and serum concentrations of bilirubin and ammonia); and cultures of blood and cerebrospinal fluid. Specialized metabolic tests were also conducted including quantitative plasma amino acids, evaluation of plasma lactate and pyruvate levels, acylcarnitine profile, and qualitative urine organic acids. Drug testing using appropriate panels was performed on samples of blood and urine to determine the presence of drugs that can cause altered levels of consciousness, such as sedatives, salicylates, hallucinogenic agents, anticholinergic agents, opioids, monoamine oxidase inhibitors, acetaminophen, selective serotonin reuptake inhibitors, and tricyclic antidepressants and was negative. In addition, we examined for the presence of environmental toxins, such as organophosphates, lead or other heavy metals, and hydrocarbons in the aforementioned biological samples — all were

unremarkable. Screening for autoimmune and paraneoplastic panel in blood or cerebrospinal fluid [i.e., antibodies of anti-Hu, anti-Yo, anti-Ri (ANNA2), anti-MA2 (Ma2/Ta), anti-CV2/CRMP5, anti-amphiphysin, anti-NMDAR, anti-Caspr2, anti-AMPA, anti-LGI1] revealed negative results. Based on these test results, a diagnosis of FRES was made.

Status epilepticus (SE) was treated using various drugs at different time points, specifically using phenobarbital (PHB; 15 mg/kg for loading, 3 mg/kg/day for maintenance), phenytoin (15 mg/kg for loading, 5 mg/kg/day for maintenance), valproic acid (15 mg/kg/day gradually titrated to 60 mg/kg/day), levetiracetam (LEV, 1500 mg q12hr), intravenous immunoglobulin (1 g/kg; up to 3 courses), dexamethasone (7 days), midazolam (20 mg/kg/min continuous intravenous infusion), pyridoxine, and a ketogenic diet (stopped by gastrointestinal bleeding). The levels of all these drugs were closely monitored to ensure their effectiveness. However, SE occurred up to dozens of times a day (>30 times overall; Fig. 2).

Drug-induced comas were induced four times (two times with pentobarbital, one time with propofol, and one time with thiopental). Throughout the course of hospital admission, frequent EEG monitoring was performed. Electroencephalography showed burst-suppression features with suppression periods lasting 4–5 s and without electroclinical seizures. However, every time the dose of



**Fig. 2.** Timeline of clinically observed seizures and treatment with various intravenous-type AEDs. AEDs = antiepileptic drugs; GTCs = generalized tonic-clonic seizures; PBT = pentobarbital; PHB = phenobarbital; PHT = phenytoin; PROP = propofol; VPA = valproic acid.

anesthetics was tapered, SE relapsed (Fig. 1C and D). Brain magnetic resonance imaging was performed two times, which demonstrated abnormal hyperintensities bilaterally over the external capsules, medial temporal lobes, hippocampi, and posteromedial thalami (Fig. 3).

On Day 27 of admission, we started lidocaine therapy at a dose of 1.25 mg/kg/h. Over the next 2 days, the severity and frequency of her generalized-type SE were reduced a third. On Day 30, we added MgSO<sub>4</sub> at a dose of 20 mg/kg/h, which markedly improved the SE and EEG readings from Day 1 of administration (Fig. 2); her blood magnesium level was 3.3 mg/dL the next day. Therefore, we discontinued the barbiturate-induced coma and gradually lowered the dose of midazolam infusion over several days before stopping it completely. She was discharged from the intensive care unit (ICU) with intravenous lidocaine, MgSO<sub>4</sub>, and LEV. At this time, no clinical seizure had been noted.

An overview of the patient's seizure evolution is as follows: the ictal discharge in the right frontal-temporal region along with left-sided tonic seizure started approximately 8–10 s before the generalized seizure occurred, and when this was stopped by administering an anesthetic or BZD, the seizure transformed into clinical myoclonic jerks of both lower limbs (L > R) with EEG slow wave with/without visible epileptiform discharges. Fig. 1 shows the EEG tracings obtained at different time points.

She then received rehabilitation therapy to counteract the prolonged period during which she had been bedridden in the ICU. Gradually, she could walk stably, write smoothly, and respond fluently. She was

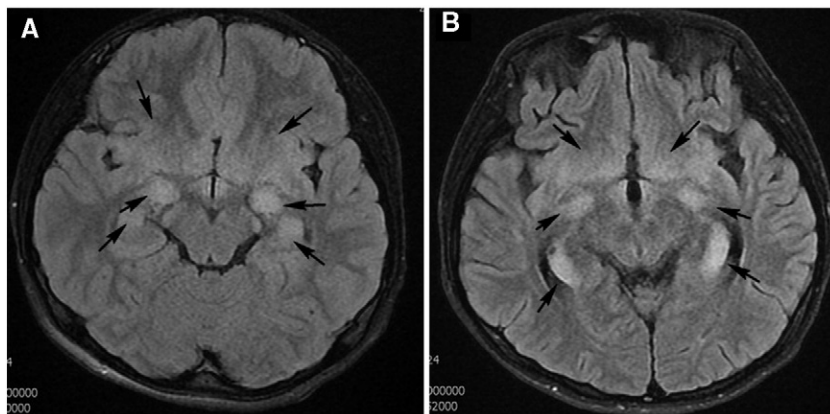
discharged after 39 days of admission. Although seizures did not occur when all intravenous-type antiepileptic drugs (AEDs) were stopped, the discharge medication was a prophylactic polytherapy with PB, LEV, topiramate, lorazepam, and pyridoxine. Two weeks after discharge, she returned for neurological and neuropsychological follow-up. Neither seizures nor significant neurological complications were observed during this period; however, her short-term memory was slightly impaired "by amnesia". Neuropsychological evaluation with the Wechsler Intelligence Scale for Children–IV revealed no difference in the four factor indices compared with expected values for her age.

### 3. Discussion

To most neurologists, treating FIERs is extremely problematic because its etiology and treatment remain unclear. Although the severe seizures can be controlled, the patient is usually left with a grave psychomotor impairment. In this case, we not only found that a combined regimen of lidocaine and MgSO<sub>4</sub> achieved a favorable control of SE but also found that it resulted in minimal psychomotor impairment.

With the exceptions of comas induced by anesthetics or barbiturates, most AEDs fail to stop the SE that results from FIERs. However, the significant danger is that the longer the burst-suppression coma is induced, the worse the cognitive outcome [3]. A review of the literature showed that few regimens have been proposed for this condition. Capizzi et al. [4] used lidocaine treatment and eventually controlled the refractory SE after 9 weeks of numerous ineffective AED treatments. Lin et al. [5] reported that moderate therapeutic hypothermia at 33 °C resulted in a sustained control of refractory SE. In another study on 12 patients with FIERs [6], immunoglobulin and a ketogenic diet were demonstrated to be a potentially efficacious treatment. In the present case, three courses of intravenous immunoglobulin (1 g/kg) were administered but were ineffective. The presence of voluminous amounts of coffee grounds and gastric juices in the nasogastric tube made it difficult to implement the ketogenic diet. After administering lidocaine for 2 days, the frequency of generalized seizures reduced to one-third, but when MgSO<sub>4</sub> was added, the number of seizures dropped markedly to no more than three per day within 3 days. After 3 days, the patient was seizure-free.

The mechanism that caused lidocaine and MgSO<sub>4</sub> to apparently work in our case is unclear. Capizzi et al. [4] assumed that lidocaine, being a local anesthetic drug as well as an antiarrhythmic drug (Class IB), has membrane-stabilizing effects and exhibits a central local anesthetic action on the inhibitory pathway fibers involved in direct cortical stimulation [4]. At present, lidocaine has been widely used in the control



**Fig. 3.** (A) Initial magnetic resonance imaging (MRI) images: T2-weighted (T2W) fluid-attenuated inversion recovery (FLAIR) images (taken on Day 3 of admission) showing symmetrical edema and hyperintensities of the bilateral external capsules and medial temporal lobes along with the hippocampi and posteromedial thalami (arrow). (B) Follow-up MRI images: T2W FLAIR images (taken on Day 21 of admission) showing mild remission of abnormal cortical swelling in the bilateral medial temporal lobes, hippocampi, thalami, basal ganglia, and external capsules (arrow).

of neonatal seizures [7]. Magnesium sulfate ( $\text{MgSO}_4$ ), a drug commonly used in eclampsia but rarely in FIRES, is a seizure prophylactic; its mechanism of action, however, remains unclear [8]. Zeiler et al. [9] reviewed 19 original articles and suggested a trend toward improved seizure control with the use of intravenous  $\text{MgSO}_4$  for noneclamptic refractory SE [9]. One hypothesis is that severe preeclampsia is a state of increased seizure susceptibility resulting from blood–brain barrier disruption and neuroinflammation, which lowers the seizure threshold [10]. Further,  $\text{MgSO}_4$  decreases seizure susceptibility by protecting the blood–brain barrier and preventing neuroinflammation. Although the pathophysiology of FIRES is undetermined, the mechanism that caused the combination of lidocaine and  $\text{MgSO}_4$  to apparently work successfully in our case provides a clue for FIRES research and understanding.

#### 4. Conclusion

This is the first report describing the combined use of lidocaine and  $\text{MgSO}_4$  with successful treatment outcomes. This experience provided a different treatment option for control of status epilepticus due to FIRES when all conventional AEDs failed. However, more studies are needed to explore the mechanisms and effects of lidocaine and  $\text{MgSO}_4$  in FIRES.

#### Conflicts of interest

The authors have no conflicts of interest to disclose.

#### References

- [1] Nabbout R. FIRES and IHHE: delineation of the syndromes. *Epilepsia* 2013;54(Suppl. 6):54–6.
- [2] Serrano-Castro PJ, Quiroga-Subirana P, Payán-Ortiz M, Fernandez-Perez J. The expanding spectrum of febrile infection-related epilepsy syndrome (FIRES). *Seizure* 2013;22:153–5.
- [3] Kramer U, Chi CS, Lin KL, Specchio N, Sahin M, Olson H, et al. Febrile infection-related epilepsy syndrome (FIRES): does duration of anesthesia affect outcome? *Epilepsia* 2011;52(Suppl. 8):28–30.
- [4] Capizzi G, Vittorini R, Torta F, Davico C, Rainò E, Conio A, et al. Lidocaine treatment in refractory status epilepticus resulting from febrile infection-related epilepsy syndrome: a case report and follow-up. *Neuropediatrics* 2015;46:65–8.
- [5] Lin JJ, Lin KL, Hsia SH, Wang HS, CHEESE Study Group. Therapeutic hypothermia for febrile infection-related epilepsy syndrome in two patients. *Pediatr Neurol* 2012;47:448–50.
- [6] Caraballo RH, Reyes G, Avaria MF, Buompadre MC, Gonzalez M, Fortini S, et al. Febrile infection-related epilepsy syndrome: a study of 12 patients. *Seizure* 2013;22:553–9.
- [7] Weeke LC, Toet MC, van Rooij LG, Groenendaal F, Boylan GB, Pressler RM, et al. Lidocaine response rate in aEEG-confirmed neonatal seizures: retrospective study of 413 full-term and preterm infants. *Epilepsia* 2016;57:233–42.
- [8] Häusler M, Schoberer M, Van Baalen A, Weis J, Orlikowsky T, Schmitt B, et al. FIRES (febrile infection-related epilepsy syndrome) partially responsive to magnesium and dextromethorphan treatment. *Neuropediatrics* 2012;43, - PS19\_06.
- [9] Zeiler FA, Matuszczak M, Teitelbaum J, Gillman LM, Kazina CJ. Magnesium sulfate for non-eclamptic status epilepticus. *Seizure* 2015;32:100–8.
- [10] Johnson AC, Tremble SM, Chan SL, Moseley J, LaMarca B, Nagle KJ, et al. Magnesium sulfate treatment reverses seizure susceptibility and decreases neuroinflammation in a rat model of severe preeclampsia. *PLoS One* 2014;9, e113670.