

Mycotic Aneurysm Treated with Aneurysm Trapping. Case Report

Sérgio Neto¹ Juan Castro Flores¹ Eberval Gadelha Figueiredo¹ José Guilherme Pereira Caldas²
Manoel Jacobsen Teixeira¹

¹ Division of Neurosurgery, University of Sao Paulo Medical School, Sao Paulo, Sao Paulo, Brazil

² Division of Interventional Radiology, Hospital das Clinicas, University of São Paulo Medical School, Sao Paulo, Sao Paulo, Brazil

Address for correspondence Dr. Sérgio Neto, MD, Division of Neurosurgery, University of Sao Paulo Medical School, Rua Eneas de Carvalho Aguiar 255, Sao Paulo 05403-000, SP, Brazil (e-mail: sgsnnc@gmail.com).

J Neurol Surg Rep 2016;77:e13–e16.

Abstract

Keywords

- ▶ mycotic aneurysm
- ▶ subarachnoid hemorrhage
- ▶ endocarditis

The authors describe a rare case of mycotic aneurysm (MA) associated with subarachnoid hemorrhage treated with aneurysm trapping. The literature on management and the surgical techniques are controversial due to lack of randomized trials.

Introduction

Mycotic cerebral aneurysm is one of many lesions due to infective endocarditis (IE) but still rare and potentially fatal complication. Medical treatment is based on antibiotics and in specific cases surgical treatment is required (craniotomy or endovascular). The absence of randomized trials generates a lack of consensus regarding the management of unruptured aneurysms. We present a case report of a patient diagnosed and treated surgically with improvement on follow-up with the trapping technique of the aneurysm.

Case Report

A 32-year-old man presented with sudden headache, high-grade fever with chills, and right hemiparesis. Sought medical attention and on the examination of admission, he was febrile (38°C). The pulse rate was regular (76 beats/min) and blood pressure was 130/70 mm Hg. Cardiac auscultation revealed soft first heart sound, normal aortic component, and a grade 3/6 mitral murmur. On neurologic examination he presented alert and conscious, with a right parietic gait and muscular strength grade I right-sided hemiparesis. After the new diagnosis of a febrile syndrome plus pyramidal syndrome the initial investigation was performed.

Investigations

Hemogram revealed leucocytosis (11,000/mm³) with predominant neutrophilia (70%) and normal platelet count (190,000). Urine examination, renal function test, and liver function test were normal. Transthoracic echocardiogram revealed a mitral thickening with perforation leading to severe mitral regurgitation with two jets.

Blood cultures (four samples) were positive after for *Abiotrophia defectiva* after 96 hour by the matrix-assisted laser desorption/ionization (MALDI TOF) MS method.

Computed tomographic (CT) angiogram and angiography revealed an M2 aneurysm with subarachnoid hemorrhage (SAH) (▶ Figs. 1 and 2).

Treatment

The patient was treated with antifailure medications along with injectable antibiotics for IE for 8 weeks.

The patient was submitted to surgery (pterional craniotomy) with trapping of the aneurysm with success.

Outcome and Follow-up

The patient was treated with antibiotics and close monitoring for eventual neurologic symptoms worsening. The patient became afebrile and the symptoms leading to heart failure improved with the medical therapy after 10 days. After

received
July 17, 2015
accepted
September 26, 2015
published online
November 16, 2015

DOI <http://dx.doi.org/10.1055/s-0035-1567864>.
ISSN 2193-6358.

© 2016 Georg Thieme Verlag KG
Stuttgart · New York

License terms



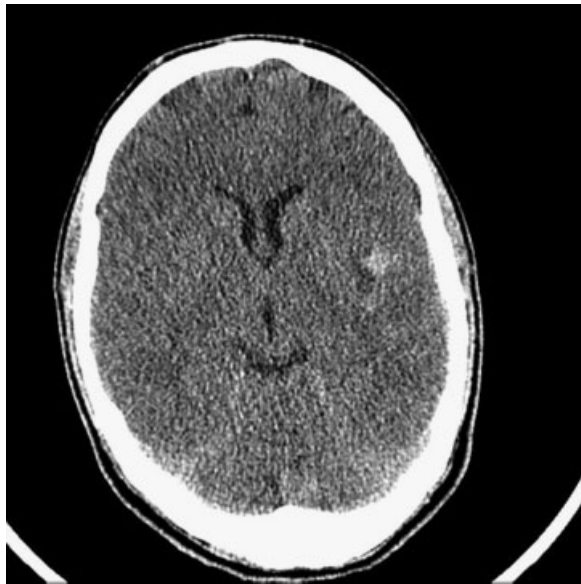

Fig. 1 CT of the head with Fisher IV subarachnoid hemorrhage (SAH).

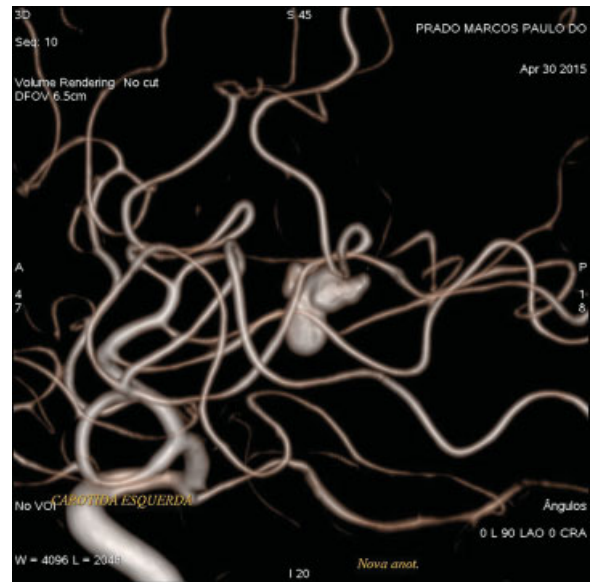


Fig. 3 Angiogram revealing increase of the lesion.

8 weeks we performed a control magnetic resonance imaging (MRI) angiogram who revealed that the previous lesion increased (► **Fig. 3**). After surgery the patient improved the previous deficit on 3 months follow-up (from grade I–IV hemiparesis) (► **Fig. 4**).

Discussion

The epidemiologic profile of IE has changed substantially over the last few years, especially in industrialized nations. Newer predisposing factors have emerged—valve prostheses, degenerative valve sclerosis, intravenous drug abuse—associated with increased use of invasive procedures at risk for bacteremia, resulting in health care–associated IE.¹

In developed countries, the incidence of IE ranges from 3 to 9 cases per 100,000 per year, and it is twice as common in men.¹

Staphylococcus aureus is the most common organism. Up to 30% of those having bacteremia with *Staphylococcus* will develop endocarditis and 75% of patients with IE have structural abnormalities on their hearts.^{1,2}

A. defectiva, a nutritionally variant *Streptococcus* (NVS), represents a rare but clinically important cause of IE initially described by Frenkel and Hirsch in 1961³ as fastidious gram-positive bacterium and modified by Bouvet et al in 1989⁴ who proposed the names *Streptococcus defectivus* and *Streptococcus adjacens*, following the use of DNA–DNA hybridization studies.^{1,5,6}

A. defectiva endocarditis is a rare cause of endocarditis with rates around 5% of all cases of streptococcal endocarditis. There are around 100 cases of *A. defectiva* endocarditis in the literature. It predominantly occurs in the setting of preexisting heart disease (90%); prosthetic heart valves are involved in 10% of patients. There are no published cases on adults

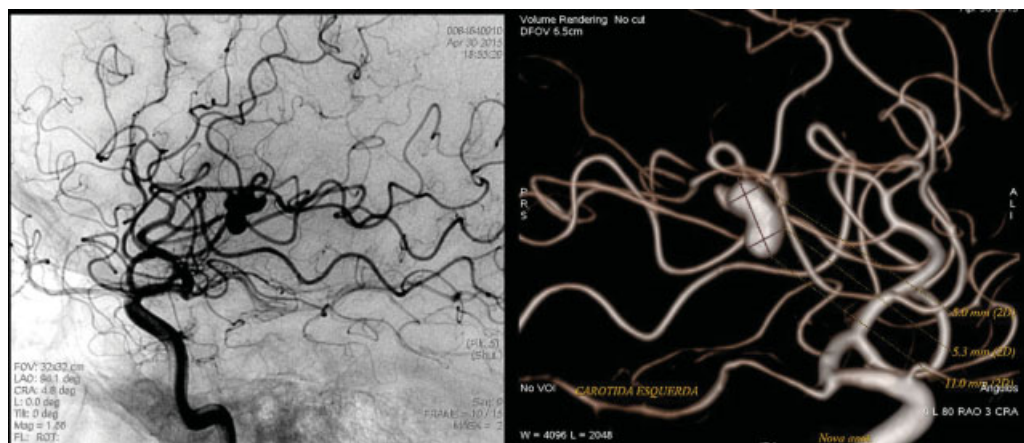


Fig. 2 MCA M2 segment aneurysm.

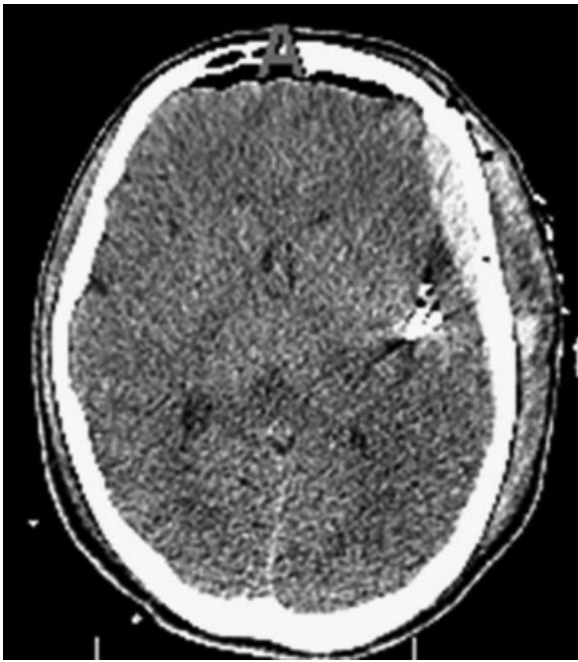

Fig. 4 Post-op CT.

without previously documented valvular heart disease developing.^{5,6}

The 1-year rate of IE mortality is around 30%. Neurologic complications, most commonly cerebral embolism, are seen in 20 to 40% of the patients and are associated with high morbidity and mortality. The reported incidence of mycotic cerebral aneurysms is 2 to 3% of all the patients with IE. This is possibly underestimated, because most patients remain asymptomatic and the aneurysm may resolve after antibiotic therapy.^{2,7}

The symptoms usually include headache (83%), fever (67%), vomiting (50%), ocular palsy (25%), seizures (21%), behavioral changes (21%), hemiparesis (21%), drowsiness (17%), and loss of consciousness (17%).^{1,7}

The clinical diagnosis of IE is usually made based on modified Duke criteria and the neurologic complications with CT and magnetic resonance angiography.^{1,7}

Authors such as Thuny et al⁸ reported that cerebral and thoracoabdominal CT revealed silent emboli in only 8% of patients. Cooper et al⁹ performed MRI of the brain in 40 patients with IE and found acute brain embolization in 80% of patients.¹⁰

Several authors have recommended the antimicrobial therapy tailored by culture for 6 to 8 weeks along with close follow-up as the first line of treatment for unruptured intracranial aneurysms and serial imaging. Invasive procedures (microsurgery/endovascular) are indicated for very large, enlarging, or ruptured aneurysm.^{1,10}

Surgical management of mycotic aneurysm (MA) depends on several factors, including size, location, expertise of the surgeon (on microsurgery or endovascular) (– **Table 1**), and if the aneurysm has ruptured. There are no data comparing microsurgery versus endovascular.^{11,12} Ruptured MAs are managed by either open or endovascular means, following which a 2- to 3-week delay is recommended prior to cardiac valve replacement. Microsurgery in this case is technically difficult, as MAs tend to be fusiform with poorly defined necks and friable walls. Proximal ligation is therefore often necessary. Anastomotic procedures that can spare distal vessels in eloquent areas are sometimes possible. Endovascular therapies are less invasive alternatives that may be more appropriate in patients who are unfit for surgery due to cardiac disease. Detachable coils are preferred for proximal aneurysms, whereas distal aneurysms that are not accessible to microcatheters can be managed with acrylic glue or autologous clot injections.^{2,11,12}

Conclusion

IE is a serious disorder very often in developing countries that is frequently complicated when associated with neurologic disease including ischemic and hemorrhagic stroke. The surgical management of the underlying disease still lacks of randomized trials and sets a new opportunity for new studies

Table 1 Presentation of reported patients treated with endovascular versus current patient (microsurgery)

Reference (year)	Age (y)	Clinical presentation	Etiology	Pathogen	Follow-up (mo)	Modified Rankin Scale score
Current patient, 2015	32	Fever, headache, and hemiplegia	Bacterial	<i>Abiotrophia defectiva</i>	3	0
Ding et al, 2014 ¹³	35	Diplopia	Bacterial endocarditis	<i>Streptococcus mitis</i>	3	0
Sugg et al, 2006 ¹⁴	47	Hemiplegia, headache	Bacterial endocarditis	Unknown	None	3
Yen et al, 2007 ¹⁵	46	Ophthalmoplegia	Meningitis	<i>Streptococcus constellatus</i>	6	1
Appelboom et al, 2007 ¹⁶	10	Ophthalmoplegia	Meningitis	<i>Streptococcus pneumoniae</i>	3	0

regarding the matter. A multidisciplinary collaborative approach is critical to optimizing outcomes.

Disclosures

The authors declared no potential conflicts of interest.

References

- 1 Habib G, Hoen B, Tornos P, et al; ESC Committee for Practice Guidelines; Endorsed by the European Society of Clinical Microbiology and Infectious Diseases (ESCMID) and the International Society of Chemotherapy (ISC) for Infection and Cancer. Guidelines on the prevention, diagnosis, and treatment of infective endocarditis (new version 2009): the Task Force on the Prevention, Diagnosis, and Treatment of Infective Endocarditis of the European Society of Cardiology (ESC). *Eur Heart J* 2009;30(19):2369–2413
- 2 Morris NA, Matiello M, Lyons JL, Samuels MA. Neurologic complications in infective endocarditis: identification, management, and impact on cardiac surgery. *Neurohospitalist* 2014;4(4):213–222
- 3 Frenkel A, Hirsch W. Spontaneous development of L forms of streptococci requiring secretions of other bacteria or sulphhydryl compounds for normal growth. *Nature* 1961;191:728–730
- 4 Bouvet A, Grimont F, Grimont P. *Streptococcus defectivus* sp. nov. and *Streptococcus adjacens* sp. nov., nutritionally variant streptococci from human clinical specimens. *Int J Syst Bacteriol* 1989;39:290–294
- 5 Kiernan TJ, O’Flaherty N, Gilmore R, et al. *Abiotrophia defectiva* endocarditis and associated hemophagocytic syndrome—a first case report and review of the literature. *Int J Infect Dis* 2008;12(5):478–482
- 6 Baddour LM, Wilson WR, Bayer AS, et al; Committee on Rheumatic Fever, Endocarditis, and Kawasaki Disease; Council on Cardiovascular Disease in the Young; Councils on Clinical Cardiology, Stroke, and Cardiovascular Surgery and Anesthesia; American Heart Association; Infectious Diseases Society of America. Infective endocarditis: diagnosis, antimicrobial therapy, and management of complications: a statement for healthcare professionals from the Committee on Rheumatic Fever, Endocarditis, and Kawasaki Disease, Council on Cardiovascular Disease in the Young, and the Councils on Clinical Cardiology, Stroke, and Cardiovascular Surgery and Anesthesia, American Heart Association: endorsed by the Infectious Diseases Society of America. *Circulation* 2005;111(23):e394–e434
- 7 Singla V, Sharma R, Nagamani AC, Manjunath CN. Mycotic aneurysm: a rare and dreaded complication of infective endocarditis. *BMJ Case Rep* 2013;2013;
- 8 Thuny F, Disalvo G, Belliard O, et al. Risk of embolism and death in infective endocarditis: prognostic value of echocardiography—a prospective multicenter study. *Circulation* 2005;112:69–75
- 9 Cooper HA, Thompson EC, Lauren R, et al. Subclinical brain embolization in left-sided infective endocarditis: results from the evaluation by MRI of the brains of patients with leftsided intracardiac solid masses (EMBOLISM) pilot study. *Circulation* 2009;120(7):585–591
- 10 Meshaal MS, Kassem HH, Samir A, Zakaria A, Baghdady Y, Rizk HH. Impact of routine cerebral CT angiography on treatment decisions in infective endocarditis. *PLoS ONE* 2015;10(3):e0118616
- 11 Bohmfalk GL, Story JL, Wissinger JP, Brown WE Jr. Bacterial intracranial aneurysm. *J Neurosurg* 1978;48(3):369–382
- 12 Gillinov AM, Shah RV, Curtis WE, et al. Valve replacement in patients with endocarditis and acute neurologic deficit. *Ann Thorac Surg* 1996;61(4):1125–1129, discussion 1130
- 13 Ding D et al. Endovascular stenting for treatment of mycotic intracranial aneurysms. *J Clin Neurosci* 2014;21:1163–1168
- 14 Sugg RM, Weir R, Vollmer DG, et al. Cerebral mycotic aneurysms treated with a neuroform stent: technical case report. *Neurosurgery* 2006;58:E381 [discussion E]
- 15 Yen PS, Teo BT, Chen SC, et al. Endovascular treatment for bilateral mycotic intracavernous carotid aneurysms. Case report and review of the literature. *J Neurosurg* 2007;107:868–872
- 16 Appelboom G, Kadri K, Hassan F, et al. Infectious aneurysm of the cavernous carotid artery in a child treated with a new-generation of flow-diverting stent graft: case report. *Neurosurgery* 2010;66:E623–E624 [discussion E4]