

## Case Report

# Cardiac rhabdomyosarcoma mimicking a mediastinal tumor and the role of endoscopic ultrasonography

Christian Pesenti<sup>1</sup>, Erwan Bories<sup>1</sup>, Fabrice Caillol<sup>1</sup>, Moutardier V<sup>2</sup>, Geneviève Monges<sup>2</sup>, Marc Giovannini<sup>1,\*</sup>

<sup>1</sup>Department of Endoscopy, Paoli-Calmettes Institute, Marseille, France; <sup>2</sup>Department of Surgery, Paoli-Calmettes Institute, Marseille, France; <sup>3</sup>Department of Anatomopathology, Paoli-Calmettes Institute, Marseille, France

### Abstract:

We report a case of cardiac rhabdomyosarcoma, with initial clinical features of “atrial rhythmic dysfunction,” which was concluded as a mediastinal tumor by computed tomography (CT) scan. Endoscopic ultrasonography (EUS) and EUS-FNA (fine needle aspiration) were initially conducted to diagnose the isolated mediastinal mass. In this case, EUS re-assessed the previous diagnosis as a cardiac tumor, and the patient eventually achieved a 17-month survival rate after chemotherapy. In this paper, EUS findings obtained in our case are described and a review of literatures is briefly discussed. We also describe the advantages and limitations of this technique compared with other image diagnosis alternatives.

### Keywords:

cardiac rhabdomyosarcoma; endoscopic ultrasonography; puncture (fine needle aspiration); mediastinal tumor; heart neoplasms/diagnosis

## Introduction

The incidence of primary cardiac tumors is very low, less than 0.3% of autopsies. Primary sarcomas of the heart are very rare and constitute less than 25% of primary cardiac tumors, among which rhabdomyosarcomas are the rarest.<sup>1</sup>

Clinical presentation, such as arrhythmia, precordial pain, and pericardial effusion, is not specific and depends on the location of the tumor and intracavitary obstruction to blood flow. Patients are sometimes asymptomatic until the appearance of metastasis, which leads to diagnosis.<sup>2</sup>

Despite different treatments (surgery, chemotherapy, or radiotherapy), the survival period for patients with cardiac sarcomas is limited from six months to two years.

We present a case of cardiac rhabdomyosarcoma, which was incorrectly presented as a mediastinal tumor by computed tomography (CT). The final diagnosis was conducted via endoscopic ultrasonography (EUS), which identified the lesion as a cardiac tumor. The diagnosis

was further confirmed histologically by EUS-fine needle aspiration (FNA). The subsequent evolution of the response to chemotherapy is also detailed.

## Case report

A 76-year-old woman was admitted to our institution because of a reported mediastinal tumor. She presented a three-month “atrial rhythmic dysfunction” treated by amiodarone. An electrocardiogram showed a first-degree auriculo-ventricular heart block. Standard biological examination results were normal.

Chest radiography and CT scan revealed a bulky mediastinal tumor, with a size of 77 mm x 44 mm x 40 mm (**Figure 1**). The tumor involved the hepatic dome and induced atelectasis in the lower right lung. Moreover, CT scan showed small cervical lymph nodes (less than 10 mm) but did not find hepatic or lung metastasis.

EUS (FG 36X, Pentax®, Japan) found a large mass above the cardia and revealed that the tumor developed from the left atrium (**Figure 2**), which explained the rhythm dysfunction. Three-dimensional reconstruction confirmed the cardiac origin of this mass. We performed a trans-esophageal puncture with a 19-G needle (Echotip, Cook Corporation®, Limerick, Ireland) during examination (**Figure 3**). We also found a tumoral lymph

\*To whom correspondence should be addressed.

E-mail: hdjchir@marseille.fnclcc.fr

Submitted: 2012-03-27; Received: 2012-03-28; Accepted: 2012-04-03

doi: 10.7178/eus.01.010

node close to the pulmonary artery.

Histological and immunohistochemical analyses of the sample revealed a cardiac rhabdomyosarcoma (positive vimentin and anti-myoglobin antibodies). Myxoma markers were negative (factor VIII, HMB 45).

The patient underwent chemotherapy (doxorubicin 50 mg/m<sup>2</sup> every 3 wk) and achieved a partial response (43% decrease in the tumor) after 8 cycles.

The patient remained in good condition for six months. She is still alive and without any arrhythmia 17 months after the discovery of the tumor. However, her health has deteriorated.

## Discussion

Cardiac rhabdomyosarcomas are very rare tumors (overall incidence less than 0.07%),<sup>3</sup> representing less than 25% of all primary malignant neoplasms of the heart.<sup>4</sup> The tumor produces a large variety of symptoms, such as arrhythmia and pericardial effusions, among others.<sup>5</sup> Its prognosis is very poor.<sup>1</sup> The diagnosis is primarily performed via trans-esophageal echocardiography and less frequently via CT scan,<sup>6</sup> but final diagnosis is obtained during surgery or autopsy.

Two-dimensional, Doppler, and standard trans-esophageal echocardiography can only describe the tumor's location and size, movements, ventricular function, and hemodynamic disorders.<sup>7</sup> However, difficulties arise in accessing the tumor extension in mediastinal structures to distinguish between a primary cardiac tumor and a mediastinal tumor infiltrating the heart or differentiate the tumor from a thrombus.

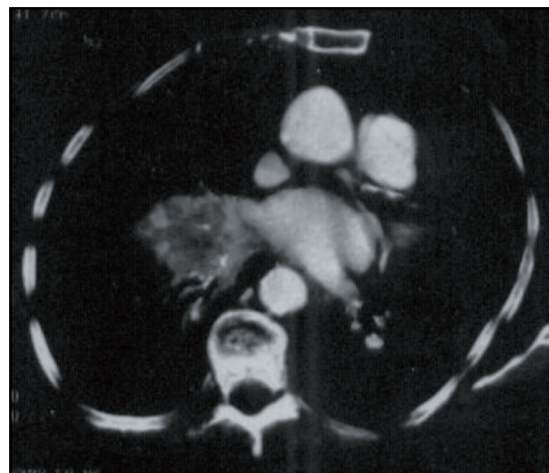
CT scan or magnetic resonance imaging (MRI) can precisely locate the tumor, but not in our case report. T2-weighted sequence MRI and/or the injection of contrast could only allow suggestions toward the histological nature in rare cases, such as lipomatous tumors. However, this method does not permit distinguishing between malignancy and benignity and the diagnosis.<sup>1</sup>

The main advantage of EUS and EUS-FNA is their ability to obtain, during the same procedure, a precise location and a histological characterization of the tumor. Although no similar case has been reported, the overall accuracy of EUS-FNA for mediastinal masses or lymph nodes is 90% to 95%. In our case report, we obtained histological samples, which permitted immunohistochemical studies, i.e., the vimentin and the anti-myoglobin antibodies.

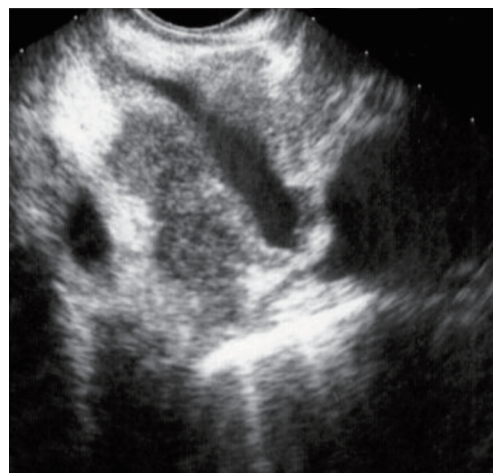
EUS-FNA of heart tumors is possible without any complication and can prevent the morbidity and mortality of a diagnostic thoracotomy.<sup>2</sup>

## Conclusion

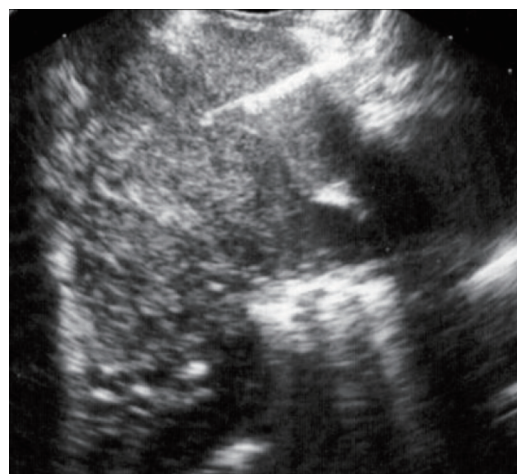An unusual indication of EUS resulted in a more precise diagnosis than CT scan that indicates the presence of



**Figure 1.** CT scan showing “a bulky mediastinal tumor (T)”.



**Figure 2.** EUS image showing the tumor that (T) developed from the left atrium (LA), below the pulmonary artery (PA).



**Figure 3.** EUS image showing the puncturing of the left atrium's tumor with a 19 G needle (Cook®).

a cardiac, but not a mediastinal, tumor. In addition, a histological diagnosis via EUS-FNA without need for surgery allows the patient to benefit from a fast and optimal medical treatment.

## References

1. Villacampa VM, Villarreal M, Ros LH, *et al.* Cardiac rhabdomyosarcoma: diagnosis by MR imaging. *Eur Radiol* 1999; 9:634-7.
2. Putnam JB Jr, Sweeney MS, Colon R, *et al.* Primary cardiac sarcomas. *Ann Thorac Surg* 1991; 51:906-10.
3. Chomette G, Auriol M, Cabrol C, *et al.* Primary malignant tumors of the heart. Anatom-clinical study of 12 cases. *Ann Med Intern* 1985; 136:301-5.
4. Castorino F, Masiello P, Quattrochi E, *et al.* Primary cardiac rhabdomyosarcoma of the left atrium: an unusual presentation. *Tex Heart Inst J* 2000; 27:206-8.
5. Vander Salm TJ. Unusual primary tumors of the heart. *Semin Thorac Cardiovasc Surg* 2000; 12:89-100.
6. Gross BH, Glazer GM, Francis IR. CT of intracardiac and intrapericardial masses. *AJR Am J Roentgenol* 1983; 140:903-7.
7. Norlindh T, Lilja B, Nyman U, *et al.* Left atrial myxoma demonstrated with CT. *AJR Am J Roentgenol* 1981; 137:153-4.