

# Comparison of the diagnostic accuracy of direct digital radiography system, filtered images, and subtraction radiography

WILTON MITSUNARI TAKESHITA, LILIAN CRISTINA VESSONI IWAKI<sup>1</sup>, MARILIANI CHICARELLI DA SILVA<sup>1</sup>, LIOGI IWAKI FILHO<sup>1</sup>, ALFREDO DE FRANCO QUEIROZ<sup>1</sup>, LUCAS BACHEGAS GOMES GERON<sup>2</sup>

## Abstract

**Background:** To compare the diagnostic accuracy of three different imaging systems: Direct digital radiography system (DDR-CMOS), four types of filtered images, and *a priori* and *a posteriori* registration of digital subtraction radiography (DSR) in the diagnosis of proximal defects. **Materials and Methods:** The teeth were arranged in pairs in 10 blocks of vinyl polysiloxane, and proximal defects were performed with drills of 0.25, 0.5, and 1 mm diameter. Kodak RVG 6100 sensor was used to capture the images. *A posteriori* DSR registrations were done with Regeemy 0.2.43 and subtraction with Image Tool 3.0. Filtered images were obtained with Kodak Dental Imaging 6.1 software. Images ( $n = 360$ ) were evaluated by three raters, all experts in dental radiology. **Results:** Sensitivity and specificity of the area under the receiver operator characteristic (ROC) curve (Az) were higher for DSR images with all three drills (Az = 0.896, 0.979, and 1.000 for drills 0.25, 0.5, and 1 mm, respectively). The highest values were found for 1-mm drills and the lowest for 0.25-mm drills, with negative filter having the lowest values of all (Az = 0.631). **Conclusion:** The best method of diagnosis was by using a DSR. The negative filter obtained the worst results. Larger drills showed the highest sensitivity and specificity values of the area under the ROC curve.

**Keywords:** Filtered images, digital radiology, digital subtraction radiography, digitized X-rays, interproximal caries

## Introduction

Caries is a dynamic process that develops due to biochemical and ultrastructural changes. It culminates in to typical signs and symptoms, affects approximately 95% of the population, and may lead to tooth loss. Early diagnosis of proximal caries is of great importance so that preventive actions can be taken instead of curative ones.<sup>[1,2]</sup>

Early diagnosis of proximal caries is noticeably assisted by radiographic examination. However, detection of tooth decay through radiographs, even with bitewing X-rays, can be difficult, given that, in its early stages, caries shows little

loss of mineralized tissue.<sup>[3]</sup> Digital radiology emerged due to the need for improvement in diagnostic imaging.<sup>[4]</sup>

The digital system offers features that provide greater dynamism to images, facilitates interpretation and diagnosis of proximal changes. Subtraction radiography is one of these features, which allows visualisation of changes between two images; these changes are usually impossible to see by naked eye.<sup>[3,5]</sup> However, the success of this method depends on the standardization of the radiographic images taken at different moments—the *a priori* and *a posteriori* registrations.<sup>[6-14]</sup>

In addition, the accuracy of diagnosis may also be enhanced by programs that filter the images. These programs can adjust the brightness and contrast, determine the gray level, invert the shades of gray, and apply pseudocolors.<sup>[15-17]</sup> Few studies compared different types of digital images in the diagnosis of changes in the tooth crown.<sup>[5,7,17]</sup>

The present study aimed to compare the diagnostic accuracy of a direct digital radiography (DDR) with complementary metal-oxide-semiconductor sensor (CMOS) system with four types of filtered images and with *a priori* and *a posteriori* registrations of digital subtraction radiography (DSR) for the diagnosis of artificially produced defects in a dental crown.

## Materials and Methods

The study was approved by the Ethics Committee on Human Research (Protocol 0469.0.093.000-10, Opinion 763/2010) at the State University of Maringá.

Department of Dentistry, Federal University of Sergipe, Aracaju, Brazil, <sup>1</sup>Department of Dentistry, State University of Maringá, Brazil, <sup>2</sup>DDS, Private practice in Orthodontics, Chapecó, Brazil

**Correspondence:** Prof. Wilton Mitsunari Takeshita, Department of Dentistry, Federal University of Sergipe, Av. Cláudio Batista, Aracaju, Sergipe, Brazil. E-mail: wmtakeshita2@gmail.com

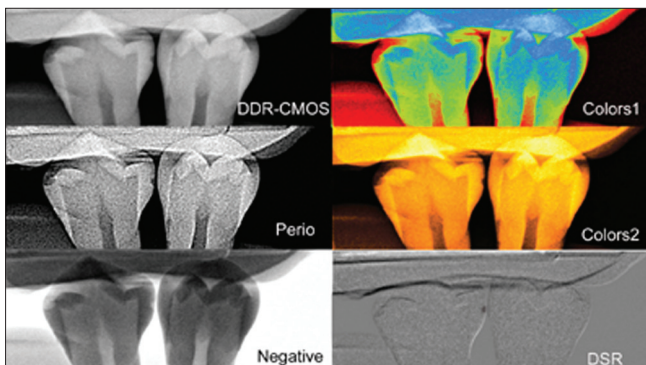
Access this article online	
Quick Response Code: 	Website: www.contempclindent.org
	DOI: 10.4103/0976-237X.118391

The study sample consisted of 20 healthy premolars extracted due to severe periodontal disease or orthodontic indication. The teeth were arranged in pairs in ten blocks of vinyl polysiloxane (Aquasil, Dentsply, USA), simulating the dental arch in the premolar region, with their proximal surfaces in contact.<sup>[16]</sup> This material was used to keep the teeth in place and, for being pliable, to permit their removal from the blocks to perform the drilling defects on the surfaces.

Each block was radiographed with dental X-ray equipment (70X, Dabi Atlante, São Paulo, Brazil), with exposure of 70 kVp, 8 mA, cylindrical locator, 40-cm focal length, and 0.4-s exposure time. A pilot test, in accordance with As Low As Reasonably Achievable (ALARA) principle, determined the lowest exposure time that provided an image with ideal brightness and contrast. Images were taken with a CMOS sensor (Kodak RVG 6100, Eastman Kodak, Rochester, NY, USA), positioner to the interproximal technique developed to adapt the digital sensor and a 2-cm thick block of wax. The block was placed between the radiation source and the tooth to simulate the soft tissues. Positioning standardization was done by tooth imprinting, with the impression material adhered to the positioner.<sup>[18]</sup>

Spherical carbide drills (KG Sorensen) were used to make the defects on the proximal surfaces, first with the 0.25-mm diameter bur, followed by 0.5-mm and 1-mm burs, all performed by the same operator.<sup>[19-21]</sup> The procedure consisted of removing the teeth from the block, positioning the drill perpendicularly to the surface, and producing the defects in high speed rotation and constant cooling. The teeth were then replaced in the block and radiographed once more.

All images were saved in Tagged Image File Format format. The *a posteriori* registration used the program Regeemy Image Registration and Mosaicking Version 0.2.43<sup>[22]</sup> (DPI-INPE São Jose dos Campos, SP, Brazil and Vision Lab, Electrical and Computer Engineering Department, University of California, Santa Barbara, USA), a free-download program developed by the National Institute for Space Research for remote sensing. Subtraction was performed with Image Tool 3.0 (University



**Figure 1:** Types of radiograph images used for diagnostic accuracy analysis

of Texas Health Sciences Center, San Antonio, Texas, USA), another free-download program.<sup>[23]</sup> Filtered images were generated with the algorithms of Kodak Dental Imaging 6.1 (Carestream Health, Rochester, NY, USA).

The resulting images for DDR-CMOS, filtered images (Perio, Negative, Colors 1, and Colors 2), and DSR with *a priori* and *a posteriori* registrations are given in Figure 1.

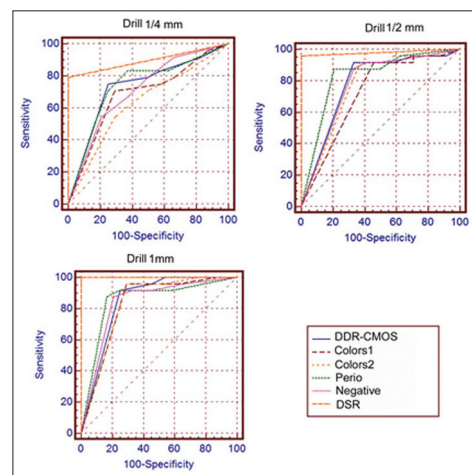
A total of 360 images were generated, which were randomized and evaluated by three dental radiologists. The specialists determined which radiographic method was more precise to detect the drilled defects. Inter- and intra-examiner reliability was verified by weighted Kappa test ( $K_w$ ). Inter-examiner coefficient was 0.699, and, for intra-examiner, the scores were 0.907 for examiner A, 0.951 for examiner B, and 0.869 for examiner C.

The images were presented on an Intel Core I3 computer (4-GHz RAM, 500-GB hard disk) with a 20-inch LCD monitor (model AOC), with brightness and contrast calibrated and standardized. The evaluators saw the images on a slide show presentation (Microsoft PowerPoint 2003, Microsoft Corp., Istanbul, Turkey), in a dimmed room and with set no time limit. They were asked to use a five-point scale to detect enamel defects, with numbers ranging as follows: (1) Definitely present, (2) probably present, (3) uncertain, (4) probably absent, and (5) definitely absent.<sup>[14]</sup> The examiners evaluated the images twice with an interval of 1 month between them.

The data were subject to statistical analysis with the use of Receiver Operator Characteristic (ROC) curves.

## Results

The 360 images were rated as follows in Table 1, while the



**Figure 2:** ROC curves for different imaging methods, with 0.25, 0.5, and 1 mm drills

**Table 1: Radiographic method, drill size, area under the ROC curve (Az) and standard error**

Method	Drill ¼		Drill ½		Drill 1	
	Az	SE	Az	SE	Az	SE
DDR-CMOS	0.733	0.073	0.780	0.067	0.850	0.057
Perio	0.685	0.077	0.721	0.074	0.829	0.060
Negative	0.631	0.081	0.767	0.069	0.833	0.060
Colors 1	0.740	0.072	0.828	0.060	0.852	0.056
Colors 2	0.710	0.075	0.774	0.068	0.839	0.059
DSR	0.896	0.048	0.979	0.021	1.000	0.000

DSR: Digital subtraction radiography; DDR: Direct digital radiography; CMOS: Complementary metal-oxide-semiconductor sensor; SE: Standard error

ROC curves for the different imaging methods are shown in Figure 2. DSR showed the highest values of sensitivity and specificity of the area under the ROC curve (Az): 0.896, 0.979, and 1.000 with drills of diameter 0.25, 0.5, and 1 mm, respectively. In contrast, the lowest values were found for perio filter (0.685, 0.721, and 0.829 with 0.25, 0.5, and 1 mm drills), and for negative filter (0.631, 0.767 and 0.833 with drills 0.25, 0.5, and 1 mm drills). The 1-mm drill showed the highest values, while the 0.25-mm drill showed the lowest values.

Pairwise comparisons between the areas under the ROC curves of the six imaging methods [Table 2] revealed that DSR differed significantly from almost all other methods: With 0.25-mm drill, it differed from the other methods except for DDR-CMOS and Colors 1. Significant differences were found between DSR and the other five methods with 0.5-mm drill, whereas, with 1-mm drill, no differences were found between DSR and perio filter.

## Discussion

Diagnosis of proximal caries is crucial in preventing dental loss,<sup>[1,2]</sup> radiographic examination being the best way to evaluate the problem, particularly with the use of bitewing technique.<sup>[24]</sup> This study used a digital radiography system to obtain X-ray images, given that its features provide greater dynamism to the images, which facilitates diagnosis and interpretation of proximal changes.<sup>[4,25]</sup>

Filters developed to help identification of changes<sup>[15-17]</sup> are one of the features that enhance the diagnosis of proximal caries. However, few studies have investigated whether filters are, in fact, a resource for diagnosis. This study compared perio filter with three other imaging tools-negative, colors 1, and colors 2, algorithms of Kodak Dental Imaging Software 6.01. In addition, the results of these four imaging methods were compared to those of DDR-CMOS and of *a priori* and *a posteriori* DSR registrations.<sup>[2,4,6,8]</sup>

The comparison between images with filters and DDR-CMOS revealed that colors 1 showed the best diagnostic accuracy.

**Table 2: Comparison between the areas under the ROC curves of different imaging methods**

Method	P values		
	Drill ¼	Drill ½	Drill 1
DDR-CMOS vs Perio	0.242	0.207	0.624
DDR-CMOS vs Negative	0.060	0.733	0.694
DDR-CMOS vs Colors 1	0.897	0.380	0.966
DDR-CMOS vs Colors 2	0.679	0.911	0.853
DDR-CMOS vs DSR	0.054	0.003*	0.008*
Perio vs Negative	0.268	0.401	0.865
Perio vs Colors 1	0.373	0.080	0.688
Perio vs Colors 2	0.664	0.372	0.843
Perio vs DSR	0.014*	0.000*	0.060
Negative vs Colors 1	0.090	0.219	0.739
Negative vs Colors 2	0.202	0.889	0.905
Negative vs DSR	0.003*	0.002*	0.005*
Colors 1 vs Colors 2	0.528	0.123	0.787
Colors 1 vs DSR	0.050	0.008*	0.009*
Colors 2 vs DSR	0.031*	0.001*	0.006*

\*P<0.05 statistical significance; DSR: Digital subtraction radiography; DDR: Direct digital radiography; CMOS: Complementary metal-oxide-semiconductor sensor; ROC: Receiver operator characteristic

Studies on the use of filters in the diagnosis of caries showed conflicting results. On one hand, Koob *et al.*,<sup>[26]</sup> and Kositbowornchai *et al.*,<sup>[27]</sup> found no evidence that digital radiography is more accurate for detecting proximal caries. On the other hand, Akarlan *et al.*,<sup>[28]</sup> and Sanden *et al.*,<sup>[29]</sup> found that filtered images had better results than digital images with no filters.

In the present study, DSR was performed with *a priori*<sup>[10,11,25]</sup> and *a posteriori* registrations. *A priori* registrations were taken using a method that could be used *in vivo*, that is, with a positioner to the bitewing technique and bite impression on vinyl polysiloxane attached to the positioner. For *a posteriori* registrations, the free-download program Regeemy 0.2.43<sup>[22]</sup> was used, a user-friendly program for dentistry researchers and clinicians.<sup>[14]</sup> Image Tool 3.0<sup>[23]</sup> was used for subtraction, which provided six sets of images [Figure 1].

According to Landis and Kock,<sup>[30]</sup> Kappa test ranges from <0 to 1.00, with almost perfect agreement varying between 1.00 and 0.81 and considerable agreement between 0.80 and 0.61. The results of intra-examiner agreement (examiner A:K<sub>w</sub> = 0.907; examiner B:K<sub>w</sub> = 0.951; examiner C:K<sub>w</sub> = 0.869) revealed that the use of three experts in radiology influenced positively in the evaluation.

ROC curve analysis showed that DSR reached the best results, with all three drills. The comparison between DDR-CMOS and DSR showed similar results to those of Ono *et al.*,<sup>[14]</sup> who reported more accuracy with DSR. The values of the area under the ROC curve for the DSR with 0.25, 0.5, and 1 mm

drills ( $Az = 0.896, 0.979, \text{ and } 1.000$ , respectively) were similar to those obtained by Ferreira *et al.*,<sup>[6]</sup> and Ricketts *et al.*<sup>[31]</sup>

For the DDR-CMOS images, the results were  $Az = 0.733, 0.780, \text{ and } 0.850$  for 0.25, 0.5, and 1 mm drills, respectively, which gave higher values than those reported by Botenberg *et al.*,<sup>[25]</sup> ( $Az = 0.58$ ). However, these authors used decayed tooth, that is, teeth with no pattern of defect. In contrast, the present study's results are similar to those of İlgüy *et al.*,<sup>[21]</sup> who also used teeth with artificially produced defects.

Concerning filtered images, colors 1 showed the best performance, whereas negative filters showed the worst results. DDR<sup>[32-34]</sup> and DSR typically showed better results and higher AZ values than images with filters.

Figure 2 shows that all imaging methods had values above the line that separates the graph, which indicates that all methods are appropriate. However, only DRS had values close to 1 [Table 2], values significantly different from the other methods. In addition, the difference between images with filters and DDR was not statistical, which is another indication that DSR is indeed the most accurate method for detecting proximal defects.

Therefore, the results showed that the smallest contribution to the diagnosis of proximal defects was provided by filtered images, whereas DSR contributed the most. However, whether DSR is the most accurate imaging method can be clarified by further *in vivo* research, particularly, by studies using the two free-download programs, one for DSR (Image Tool 3.0) and the other for *a posteriori* registrations (Regeemy); these programs can facilitate and broaden the use of DSR.

## Conclusion

Within the limitations of the present study, the best method of diagnosis was a DSR. The negative filter obtained the worst results. Larger drills showed the highest sensitivity and specificity values of the area under the ROC curve.

## References

1. Wenzel A. Digital imaging for dental caries. *Dent Clin North Am* 2000;44:319-38.
2. Wenzel A, Hintze H, Kold LM, Kold S. Accuracy of computer-automated caries detection in digital radiographs compared with human observers. *Eur J Oral Sci* 2002;110:199-203.
3. Janhom A, van Ginkel FC, van Amerongen JP, van der Stelt PF. Scanning resolution and the detection of approximal caries. *Dentomaxillofac Radiol* 2001;30:166-71.
4. van der Stelt P. Better Imaging: The advantages of digital radiography. *J Am Dent Assoc* 2008;139:7-13S.
5. Eberhard J, Hartman B, Lenhard M, Mayer T, Kocher T, Eickholz P. Digital subtraction radiography for monitoring dental demineralization. An *in vitro* study. *Caries Res* 2000;34:219-24.
6. Haiter-Neto F, Ferreira RI, Tabchoury CP, Bóscolo FN. Linear and logarithmic subtraction for detecting enamel subsurface demineralization. *Dentomaxillofac Radiol* 2005;34:133-9.

7. Bittar-Cortez JA, Passeri LA, Bóscolo FN, Haiter Neto F. Comparison of hard tissue density changes around implants assessed in digitized conventional radiographs and subtraction images. *Clin Oral Implants Res* 2006;17:560-4.
8. Haiter-Neto F, Wenzel A. Noise in subtraction images made from pairs of bitewing radiographs: A comparison between two subtraction programs. *Dentomaxillofac Radiol* 2005;34:357-61.
9. Bottenberg P, Truyen B, Boca C. Digital subtraction technique in dentistry. *Rev Belge Med Dent* 2007;62:25-32.
10. Hwang YJ, Fien MJ, Lee SS, Kim TI, Seol YJ, Lee YM, *et al.* Effect of scaling and root planning on alveolar bone as measured by subtraction radiography. *J Periodontol* 2008;79:1663-9.
11. Goren AD, Dunn SM, Wolff M, van der Stelt PF, Colosi DC, Golub LM. Pilot study: Digital subtraction radiography as a tool to assess alveolar bone changes in periodontitis patients under treatment with subantimicrobial doses of doxycycline. *Oral Surg Oral Med Oral Pathol Oral Radiol Endod* 2008;106:e40-5.
12. Güneri P, Göğüş S, Tuğsel Z, Ozturk A, Gungor C, Boyacıoğlu H. Clinical efficacy of a new software developed for dental digital subtraction radiography. *Dentomaxillofac Radiol* 2006;35:417-21.
13. Güneri P, Göğüş S, Tuğsel Z, Boyacıoğlu H. Efficacy of a new software in eliminating the angulation errors in digital subtraction radiography. *Dentomaxillofac Radiol* 2007;36:484-9.
14. Ono E, Medici Filho E, Faig Leite H, Tanaka JL, De Moraes ME, De Melo Castilho JC. Evaluation of simulated external root resorptions with digital radiography and digital subtraction radiography. *Am J Orthod Dentofacial Orthop* 2011;139:324-33.
15. Alves WE, Ono E, Tanaka JL, Medici Filho TE, de Moraes LC, de Moraes ME, *et al.* Influence of image filters on the reproducibility of measurements of alveolar bone loss. *J Appl Oral Sci* 2006;14:415-20.
16. Haiter-Neto F, dos Anjos Pontual A, Frydenberg M, Wenzel A. Detection of non-cavitated approximal caries lesions in digital images from seven solid-state receptors with particular focus on task-specific enhancement filters. An *ex vivo* study in human teeth. *Clin Oral Investig* 2008;12:217-23.
17. Zangooei Booshehry M, Davari A, Ezoddini Ardakani F, Rashidi Nejad MR. Efficacy of application of pseudocolor filters in the detection of interproximal caries. *J Dent Res Dent Clin Dent Prospects* 2010;4:79-82.
18. Behere RR, Lele SM. Reliability of Logicon caries detector in the detection and depth assessment of dental caries: An *in vitro* study. *Indian J Dent Res* 2011;22:362.
19. Chimello DT, Chinelatti MA, Ramos RP, Palma Dibb RG. *In vitro* evaluation of microleakage of a flowable composite in Class V restorations. *Braz Dent J* 2002;13:184-7.
20. Arias VG, Campos IT, Pimenta LA. Microleakage study of three adhesive systems. *Braz Dent J* 2004;15:194-8.
21. İlgüy M, Dinçer S, İlgüy D, Bayırlı G. Detection of artificial occlusal caries in a phosphor imaging plate system with two types of LCD monitors versus three different films. *J Digit Imaging* 2009;22:242-9.
22. Fedorov DV, Fonseca LM, Kenney C, Manjunath BS. Regeemy: Automatic image registration and mosaicking system. Available from: <http://regima.dpi.inpe.br/> [Last accessed on 2013 July].
23. Dove SB. UTHSCSA ImageTool: Version 3.0 Final is Here. Available from: <http://compdent.uthscsa.edu/dig/itdesc.html> [Last accessed on 2013 July].
24. White SC, Pharoah MJ. Oral radiology: Principles and interpretation, 6<sup>th</sup> ed. St. Louis: Mosby/Elsevier; 2009. p. 109-51.
25. Bottenberg P, Jacquet W, Stachniss V, Wellnitz J, Schulte AG. Detection of cavitated or non-cavitated approximal enamel caries lesions using CMOS and CCD digital X-ray sensors and conventional D and F-speed films at different exposure conditions. *Am J Dent* 2011;24:74-8.
26. Koob A, Sanden E, Hassfeld S, Staehle HJ, Eickholz P. Effect of digital filtering on the measurement of the depth of proximal caries under different exposure conditions. *Am J Dent* 2004;17:388-93.
27. Kositbowornchai S, Basiw M, Promwang Y, Moragorn H, Sooksuntisakoonchai N. Accuracy of diagnosing occlusal

- caries using enhanced digital images. *Dentomaxillofac Radiol* 2004;33:236-40.
28. Akarslan ZZ, Akdevelioğlu M, Güngör K, Erten H. A comparison of the diagnostic accuracy of bitewing, periapical, unfiltered and filtered digital panoramic images for approximal caries detection in posterior teeth. *Dentomaxillofac Radiol* 2008;37:458-63.
  29. Sanden E, Koob A, Hassfeld S, Staehle HJ, Eickholz P. Reliability of digital radiography of interproximal dental caries. *Am J Dent* 2003;16:170-6.
  30. Landis JR, Koch GG. The measurement of observer agreement for categorical data. *Biometrics* 1977;33:159-74.
  31. Ricketts DN, Ekstrand KR, Martignon S, Ellwood R, Alatsaris M, Nugent Z. Accuracy and reproducibility of conventional radiographic assessment and subtraction radiography in detecting demineralization in occlusal surfaces. *Caries Res* 2007;41:121-8.
  32. Erten H, Uçtaslı MB, Akarslan ZZ, Uzun O, Baspınar E. The assessment of unaided visual examination, intraoral camera and operating microscope for the detection of occlusal caries lesions. *Oper Dent* 2005;30:190-4.
  33. Kositbowornchai S, Basiw M, Promwang Y, Moragorn H, Sooksuntisakoonchai N. Accuracy of diagnosing occlusal caries using enhanced digital images. *Dentomaxillofac Radiol* 2004;33:236-40.
  34. Li G, Yoshura K, Welander U, Shi XQ, McDavid WD. Detection of approximal caries in digital radiographs before and after correction for attenuation and visual response. An *in vitro* study. *Dentomaxillofac Radiol* 2002;31:113-6.

**How to cite this article:** Takeshita WM, Iwaki LC, Da Silva MC, Filho LI, Queiroz AD, Geron LB. Comparison of the diagnostic accuracy of direct digital radiography system, filtered images, and subtraction radiography. *Contemp Clin Dent* 2013;4:338-42.

**Source of Support:** Nil. **Conflict of Interest:** None declared.

### Dispatch and return notification by E-mail

The journal now sends email notification to its members on dispatch of a print issue. The notification is sent to those members who have provided their email address to the association/journal office. The email alerts you about an outdated address and return of issue due to incomplete/incorrect address.

If you wish to receive such email notification, please send your email along with the membership number and full mailing address to the editorial office by email.