



Combined Double-Bundle Anterior Cruciate Ligament Reconstruction and Anterior Cruciate Ligament-Mimicking Anterolateral Structure Reconstruction

Jinzhong Zhao, M.D., Jiayu Qiu, M.D., Jiebo Chen, M.D., and Junjie Xu, M.D.

Abstract: The outcomes of double-bundle anterior cruciate ligament (ACL) reconstruction leave room for improvement. We hope to augment double-bundle ACL reconstruction with the reconstruction of an ACL-mimicking anterolateral structure (ALS). Thus, we would like to introduce a combined double-bundle ACL reconstruction and ACL-mimicking ALS reconstruction technique. The main indication for this technique is ACL injury with a high degree of pivot shift test, general laxity, or near critical value of the posterior tibial slope. The main steps in this technique include preparation of an isolated graft for the anteromedial bundle of the ACL and a combined graft for the posterolateral bundle of the ACL and ALS, creation of three tibial tunnels and two femoral tunnels, graft placement, and final graft fixation at an adjustable loop. We have obtained promising clinical outcomes with this technique and consider that this report will provide new options in ACL reconstruction.

Double-bundle anterior cruciate ligament (ACL) reconstruction outcomes reported in the past 2 decades leave room for improvement.^{1,2} Studies have suggested that one of the reasons for failure after ACL reconstruction is not taking note of knee anterolateral structure (ALS) deficiency.^{3,4} We consider that the addition of a special ALS with a route similar to that of the ACL may be more helpful. Thus, we developed a method to augment double-bundle ACL reconstruction with the reconstruction of an ACL-mimicking ALS, with a similar route to that of the ACL on the lateral aspect of the knee. The main indications of this

technique are ACL injuries with a high degree of pivot shift test, general laxity, or 12° to 15° posterior tibial slope.

Surgical Techniques

Graft Preparation

The patient is placed in the supine position. Through routine incisions, the semitendinosus tendon (ST), the gracilis tendon (GT), and the anterior half of the peroneus longus tendon (AHPLT)⁵ are harvested. A 4-stranded graft is made from the ST to reconstruct the anteromedial (AM) bundle. The GT and AHPLT are truncated to an equal length of over 24 cm, braided together at both ends with two no. 2 nonabsorbable sutures, and then folded at the junction of the middle and lateral thirds, to make a combined graft structure including a 4-stranded folded part to reconstruct the posterolateral (PL) bundle and a 2-stranded nonfolded part to reconstruct the ALS (Fig 1, Table 1).

Locating the Femoral Tunnel (With Video Illustration)

The knee is flexed at 90°. Through routine anteromedial and anterolateral portals, the inner orifices of the 2 bundles are marked at the center of the midpoint of the distal and proximal half of the ACL footprint with a radiofrequency probe (Fig 2A, Video 1).

From the Department of Sports Medicine, Shanghai Sixth People's Hospital, Shanghai Jiao Tong University, Shanghai, China.

The authors report the following potential conflicts of interest or sources of funding: Funded by the Project of Shenkang Hospital Development Center of Shanghai (grant no. 16CR3108B). Full ICMJE author disclosure forms are available for this article online, as [supplementary material](#).

Received February 20, 2020; accepted April 21, 2020.

Address correspondence to Jinzhong Zhao, M.D., Department of Sports Medicine, Shanghai Sixth People's Hospital, Shanghai Jiao Tong University, 600 Yishan Rd., Shanghai 200233, China. E-mail: zhaojinzhong@vip.163.com or jz Zhao@sjtu.edu.cn

© 2020 by the Arthroscopy Association of North America. Published by Elsevier. This is an open access article under the CC BY-NC-ND license (<http://creativecommons.org/licenses/by-nc-nd/4.0/>).

2212-6287/20272

<https://doi.org/10.1016/j.eats.2020.04.013>

Creating a Tibial Tunnel for ALS

A low anterolateral incision is made just medial to the Gerdy tubercle. The proximal orifice of the ALS tibial tunnel is located at the anterior edge of the tibial plateau, just medial to the Gerdy tubercle (Fig 3). The tunnel is created in an anterior medial distal direction toward the incision for hamstring tendon harvesting to result in a distal orifice just medial to the tibial tubercle.

Creating the Common Femoral Tunnel for ALS and ACL PL Bundle

A 2- to 3-cm longitudinal incision is made at the lateral side of the knee, just 5 mm posterior to the tip of the lateral femoral epicondyle. The iliotibial band is incised longitudinally to expose the lateral femoral epicondyle. A 1-cm deep socket is made with a Steinman pin at a point 5 mm posterior and 5 mm distal to the tip of the lateral femoral epicondyle. A 2.4-mm K-wire is placed into the socket.

A tibial tunnel-aiming device for PCL reconstruction (Smith & Nephew, Andover, MA) is placed into the joint through the anterolateral portal. The K-wire, which is placed into the socket in the lateral femoral condyle, and the tunnel-aiming pin are mounted into the device sequentially.

The arthroscope is placed into the joint through the anteromedial portal for observation. The K-wire is drilled in across the lateral femoral condyle to the center of the footprint of the PL bundle. A transverse femoral tunnel is created to the expected size (Fig 2B and Fig 4).

Creating 2 Tibial Tunnels for ACL Bundles

With the arthroscope placed into the joint through the anterolateral portal, the ACL tibial tunnel-aiming device (Aesculap, Tuttlingen, Germany) is placed. Two tibial tunnels for the AM and PL bundle, respectively, are created sequentially. The inner orifices of the AM and PL tibial tunnels are located at the midpoint of the anterior and posterior halves of the footprint,

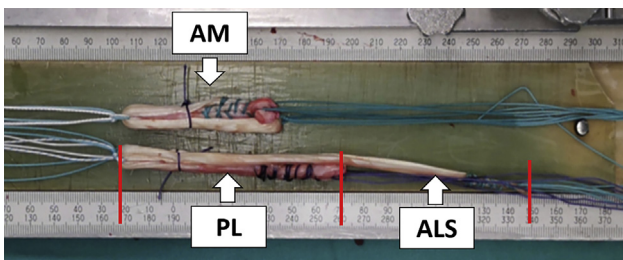


Fig 1. Graft preparation. A 4-stranded anteromedial bundle graft is made from the semitendinosus tendon. A combined graft for ACL posterolateral bundle and ALS is made from the gracilis tendon and the AHPLT. (ACL, anterior cruciate ligament; AHPLT, anterior half of the peroneus longus tendon; ALS, anterolateral structure; AM, graft for anteromedial bundle of ACL; PL, the 4-stranded part of the combined tendon for posterolateral bundle of ACL.)

Table 1. Step-by-Step Procedure

1. The semitendinosus tendon, gracilis tendon, and the AHPLT are harvested.
2. A 4-stranded graft is made from the semitendinosus tendon to reconstruct the AM bundle. A combined graft including a 4-stranded folded part for PL bundle reconstruction and a 2-stranded nonfolded part for ALS reconstruction is made.
3. The location of the femoral tunnels for the 2 ACL bundles are marked.
4. The tibial tunnel for the ALS is created from the anterior edge of the tibial plateau, just medial to the Gerdy tubercle to the anterior medial side of the tibia, in a distal direction.
5. The common femoral tunnel for the PL bundle and ALS is created in an outside-in manner from a point 5 mm posterior and 5 mm distal to the tip of the lateral femoral epicondyle, to the center of the PL bundle footprint.
6. The AM and PL bundle tibial tunnels are created from the anteromedial side of the proximal tibia to the midpoint of the anterior and posterior halves of ACL footprint.
7. The AM bundle femoral tunnel is created from the AM bundle tibial tunnel.
8. The ACL part of the combined graft is placed from the common femoral tunnel into the joint, and then into the PL bundle tibial tunnel.
9. An interference screw is placed into the common femoral tunnel.
10. The ALS graft part is passed underneath the iliotibial band to the lower anterolateral incision, and then pulled into its tibial tunnel.
11. The AM bundle graft is placed into the joint. Proximal suspension fixation is completed.
12. An interference screw is placed into the AM bundle tibial tunnel.
13. A transverse tibial tunnel is created. An adjustable loop with mini-plate is placed through this tunnel. Half of the sutures from each of the graft ends are passed through the adjustable loop.
14. The mini-plate is pulled laterally across the tunnel and flipped over the lateral orifice. The sutures from the grafts are fixed at the adjustable loop by tying to their counterparts.

ACL, anterior cruciate ligament; AHPLT, anterior half of the peroneus longus tendon; ALS, anterolateral structure; AM, anteromedial; PL, posterolateral.

respectively. The outer orifice AM tibial tunnel is located approximately 2 cm below the tibial plateau and 3 cm medial to the tibial tubercle. The outer orifice of the PL bundle is located at the anterior edge of the medial collateral ligament and approximately 5 cm below the tibial plateau.

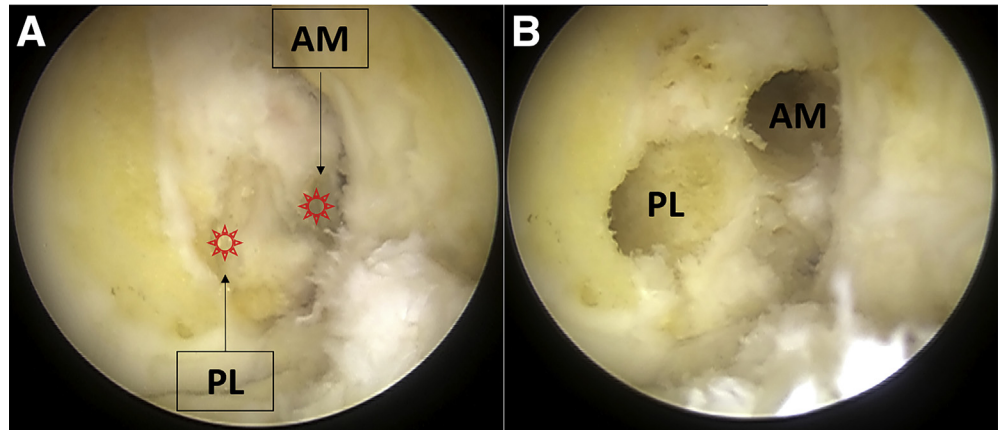
Creating Femoral Tunnel for AM Bundle

A tubular femoral tunnel-aiming device (Aesculap) is placed through the AM bundle tibial tunnel to the marked point of the AM bundle femoral tunnel. The AM bundle femoral tunnel is created sequentially with a K-wire and a drill (Fig 2B).

Placement of the Combined Graft

The ACL part of the combined graft is pulled from the common femoral tunnel to the PL tibial tunnel till the entire ACL part of the graft is pulled into the lateral orifice of the femoral tunnel. An obturator is placed under the graft as a pulley (Fig 5). An interference screw is placed into the common femoral tunnel.

Fig 2. Intra-articular view of the location of the femoral tunnel (right knee viewed from anteromedial portal). (A) Marked points of the 2 femoral tunnels. (B) Two femoral tunnels created. (AM, anteromedial bundle. PL, posterolateral bundle.)



A hemostat is placed into the low anterolateral incision, through the underside of the iliotibial band, and out of the lateral incision. The knee is then moved from flexion to extension several times to create a soft tissue tunnel for the future reconstructed ALS. The ALS part of the combined graft is pulled through this soft tissue tunnel to the low anterolateral incision and then into the ALS tibial tunnel.

Placement of the AM Bundle Graft

The AM bundle graft is placed into the joint through the tibial tunnel (Fig 6). Proximal suspension fixation is completed by tying the sutures from the proximal end of the graft onto a mini-plate that lies over the outer orifice of the AM bundle femoral tunnel.

Graft Fixation on the Tibial Side

With the knee in full extension, an interference screw is placed into the AM bundle tibial tunnel. A

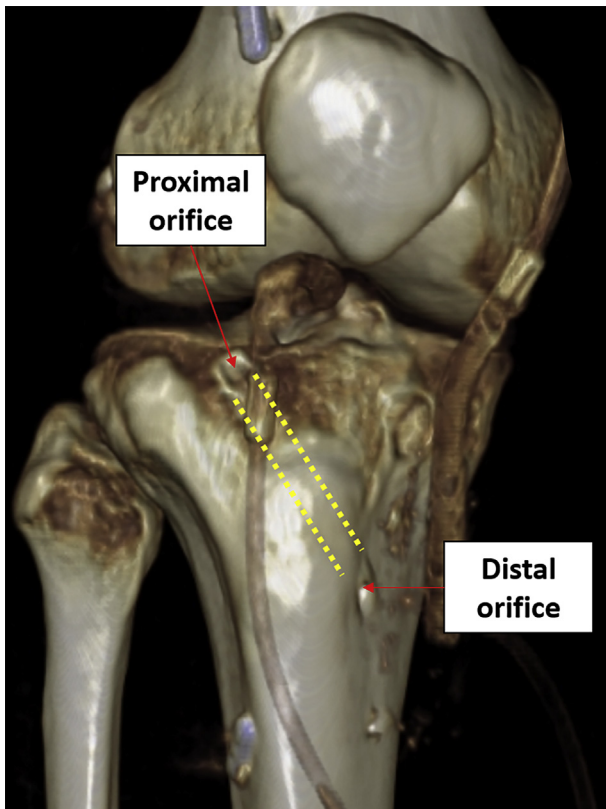


Fig 3. Location of the tibial tunnel for ALS reconstruction. The tibial tunnel for ALS reconstruction is located at the anterior edge of the lateral tibial plateau, just medial to the Gerdy tubercle. (ALS, anterolateral structure.)

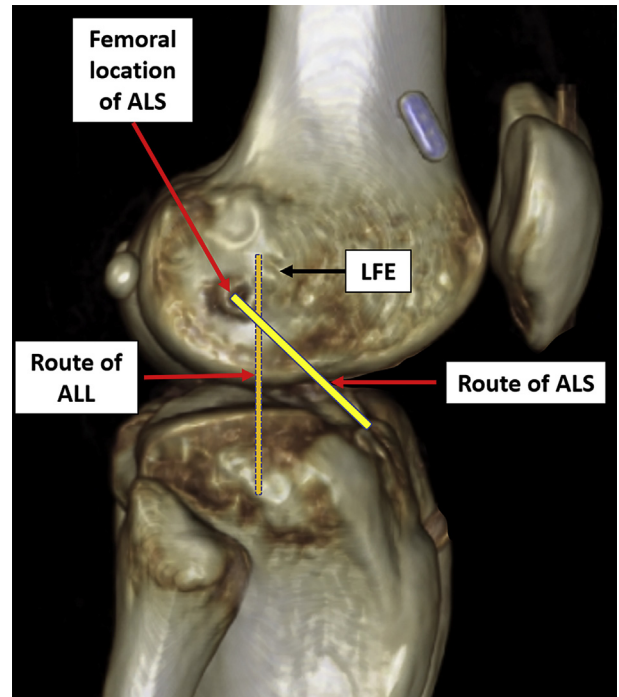


Fig 4. Location of the common femoral tunnel for ACL PL bundle and ALS and the routes of the ALL and ALS. A great difference can be found between the routes of the ALL and ALS. (ACL, anterior cruciate tendon; ALL, anterolateral ligament; ALS, anterolateral structure; LFE, lateral femoral epicondyle; PL, posterolateral.)

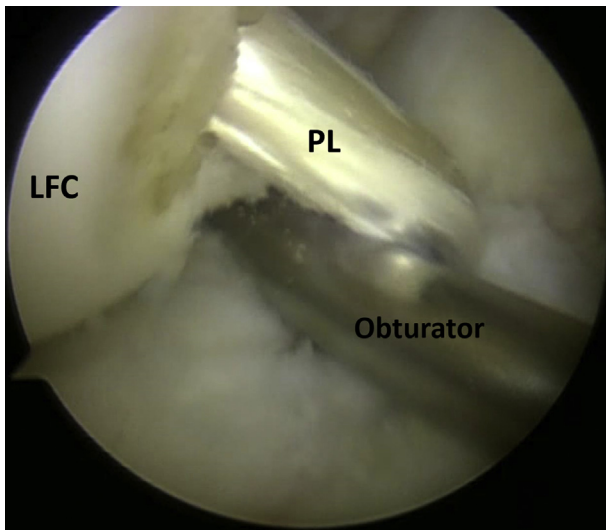


Fig 5. Placement of the PL bundle (right knee viewed from anterolateral portal). An obturator is placed under the graft as a pulley. (LFC, lateral femoral condyle; PL, posterolateral.).

2-mm incision is made approximately 1 cm lateral to the anterior tibial ridge at a transverse plane distal to the distal orifices of the 3 tibial tunnels for ACL and ALS reconstruction. A 4.5-mm transverse tibial tunnel is created. A mini-plate-adjustable loop set (Arthrex, Naples, FL) is pulled through this tunnel from the medial to the lateral side. Half of the sutures from each graft end are pulled through the adjustable loop. The mini-plate is pulled through the transverse tibial tunnel and flipped over the lateral orifice, after which the sutures from each graft end are tied to their counterparts (Fig 7) to suspend the grafts to the adjustable loop. The adjustable loop is reduced for final graft tensioning.

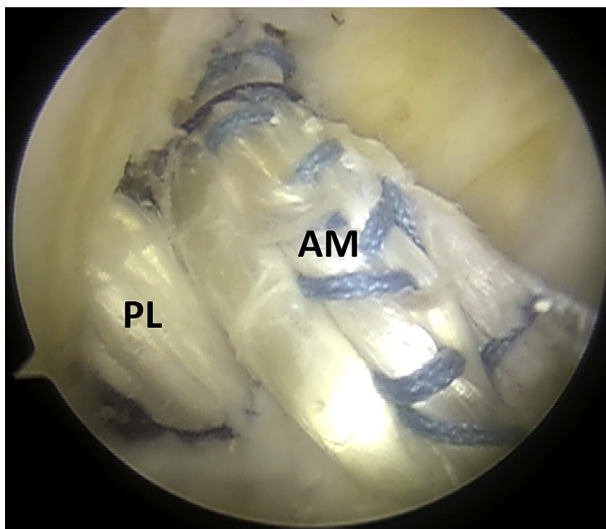


Fig 6. Arthroscopic view following placement of the AM bundle (right knee viewed from anterolateral portal). (AM, anteromedial bundle. PL, posterolateral bundle.)

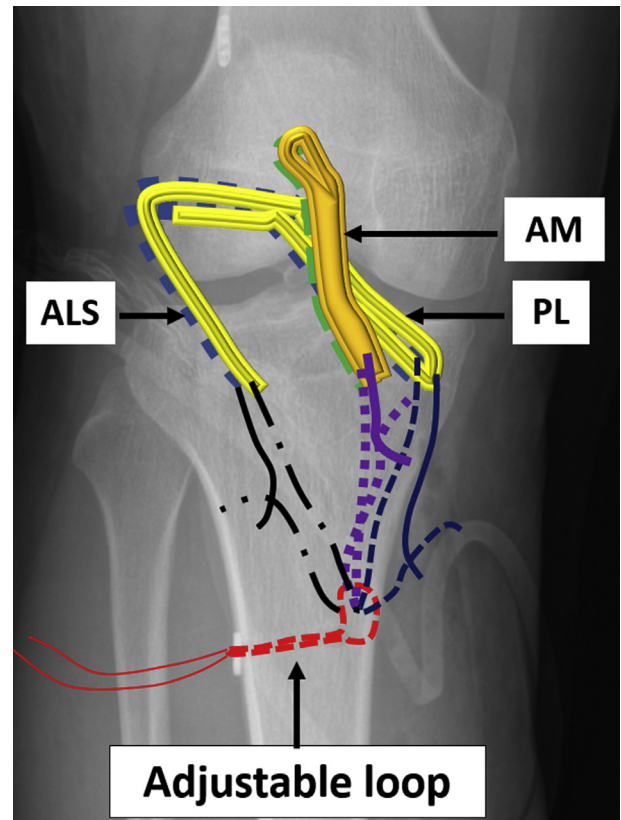


Fig 7. Distal suspension fixation of the 2 ACL bundles and ALS. The sutures from the grafts are tied to an adjustable loop, which is placed through a transverse tibial tunnel. (ALS, ACL-mimicking anterolateral structure; AM, anteromedial bundle of ACL; PL, posterolateral bundle of ACL.).

Discussion

It is our opinion that there are 3 unique aspects to this combined reconstruction technique. First, through this technique we build a new ALS that is ACL-mimicking instead of anterolateral ligament-mimicking. Second, the distal fixation of the graft is at an adjustable loop, instead of at a screw post. Third, we perform ultra-strong ACL reconstruction with a total of 10 strands of tendons, namely 4 strands of ST for the AM bundle, 2 strands of GT, and 2 strands of AHPLT for the PL bundle, and 1 strand of GT and 1 strand of AHPLT for the ALS.

The current reconstruction technique is a response to the concept of augmentation of the anterolateral complex instead of the anterolateral ligament of the knee.⁶⁻⁸ During creation of an ALS that mimics the route of the ACL, it is important to create a common femoral tunnel that is perpendicular to the sagittal plane. Our pilot study revealed that the anatomic center of the femoral footprint of the PL bundle corresponds to a point approximately 5 mm posterior and 5 mm distal to the tip of the lateral femoral epicondyle in the lateral aspect of the knee (unpublished data). Thus, starting from this point

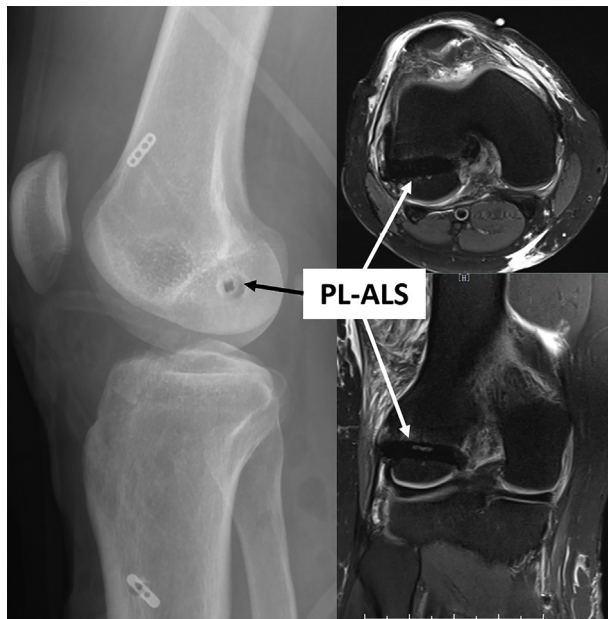


Fig 8. Direction of the femoral tunnel. A femoral tunnel perpendicular to the sagittal plane results in concentric locations of the ACL and ALS insertions. (ACL, anterior cruciate ligament; ALS; anterolateral structure; PL, posterolateral; PL-ALS, common femoral tunnel for the PL bundle of ACL and the ALS.)

medially to the PL bundle footprint, we can create the desired femoral tunnel in most cases (Fig 8). On the tibial side, the insertion of the ALS is slightly anterior to that of the ACL. Through the desired location for the

Table 2. Pearls and Pitfalls

1. In creation of the tibial tunnel for the ALS, drill a small distance posteriorly into the tibial edge initially, then change the drilling direction to the anterior, medial, and distal side. Direct drilling to distal medial direction may lead to K-wire slippage and result in a too-shallow tunnel.
2. During creation of the common femoral tunnel, make sure the direction of the tunnel is perpendicular to the sagittal plane, to make the femoral insertions of the PL bundle of the ACL and ALS concentric in the lateral view. The tunnel should not be too proximal or too distal. Otherwise, it may result in fracture of the femoral condyle.
3. When the graft fits the common femoral tunnel well, interference screw fixation on the femoral side can be omitted. When interference screw fixation is applied, do not use too large a screw, as this may result in cutting of the graft at the orifice.
4. Creating a straight soft-tissue tunnel for the ALS under the iliotibial band is critical at positions from knee flexion to extension. Placing the ALS superior to the iliotibial band will result in reciprocal disturbance between the ALS and the iliotibial band and finally affect knee movement. A curved soft-tissue tunnel will result in a curved or loose ALS, which may affect its function of stabilization.
5. All grafts are fixed in full extension and neutral rotation of the knee to prevent extension limitation. Graft fixation at high degree flexion may result in fixation failure when the knee is extended.

ACL, anterior cruciate ligament; ALS, anterolateral structure; PL, posterolateral.

Table 3. Risks and Limitations of Combined Double-Bundle ACL Reconstruction and ACL Mimicking-ALS Reconstruction

1. The main limitation of this technique is irritation of the ALS to the iliotibial band. Creating a soft-tissue tunnel under the iliotibial band for the ALS is important to avoid irritation.
2. This is a complicated ACL reconstruction–related procedure. The operator should be familiar with hamstring tendon and AHPLT harvesting. The optimal time taken to harvest the hamstring tendon and the AHPLT are less than 10 and 5 minutes, respectively.
3. The operator should be familiar with double-bundle ACL reconstruction and the combined single-bundle ACL reconstruction and ACL-mimicking ALS reconstruction at first, and finally master this technique.
4. Creating the AM bundle femoral tunnel through the tibial tunnel is demanding. When the tibial tunnel is not appropriately fabricated, the anatomical femoral position cannot be reached through the tibial tunnel. Femoral tunnel creation through AM portal must be taken.
5. Harvesting the AHPLT is easier than harvesting the hamstring tendons. However, sometimes it is difficult to push the tendon stripper across the tendon–muscle junction because the muscle part lay inside and enclosed by the outside tendon part. In this case, an additional proximal incision is always needed to complete the harvesting.

ACL, anterior cruciate ligament; AHPLT, anterior half of the peroneus longus tendon; ALS, anterolateral structure; AM, anteromedial.

ALS on both femoral and tibial sides, we can create a structure that mimics the route of ACL PL bundle. The pearls and pitfalls of this technique are listed in Table 2. The risks and limitations of this technique are listed in Table 3. The main limitation of this technique is irritation of the ALS to the iliotibial band. Creating a soft-tissue tunnel under the iliotibial band for the ALS is important to avoid irritation.

References

1. Chen H, Chen B, Tie K, Fu Z, Chen L. Single-bundle versus double-bundle autologous anterior cruciate ligament reconstruction: A meta-analysis of randomized controlled trials at 5-year minimum follow-up. *J Orthop Surg Res* 2018;13:50.
2. Belk JW, Kraeutler MJ, Houck DA, McCarty EC. Knee osteoarthritis after single-bundle versus double-bundle anterior cruciate ligament reconstruction: A systematic review of randomized controlled trials. *Arthroscopy* 2019;35:996-1003.
3. Musahl V, Getgood A, Neyret P, et al. Contributions of the anterolateral complex and the anterolateral ligament to rotatory knee stability in the setting of ACL injury: A roundtable discussion. *Knee Surg Sports Traumatol Arthrosc* 2017;25:997-1008.
4. Kittl C, El-Daou H, Athwal KK, et al. The role of the anterolateral structures and the ACL in controlling laxity of the intact and ACL-deficient knee. *Am J Sports Med* 2016;44:345-354.
5. Zhao J, Huangfu X. The biomechanical and clinical application of using the anterior half of the peroneus longus tendon as an autograft source. *Am J Sports Med* 2012;40:662-671.

6. Sonnery-Cottet B, Barbosa NC, Vieira TD, Saithna A. Clinical outcomes of extra-articular tenodesis/anterolateral reconstruction in the ACL injured knee. *Knee Surg Sports Traumatol Arthrosc* 2018;26:596-604.
7. Ariel de Lima D, Helito CP, Lacerda de Lima L, de Castro Silva D, Costa Cavalcante ML, Dias Leite JA. Anatomy of the anterolateral ligament of the knee: A systematic review. *Arthroscopy* 2019;35:670-681.
8. Getgood A, Brown C, Lording T, et al. The anterolateral complex of the knee: Results from the International ALC Consensus Group Meeting. *Knee Surg Sports Traumatol Arthrosc* 2019;27:166-176.