

Flexible ureteroscopic incision and drainage or laparoscopic unroofing for the parapelvic renal cysts: A systematic review and meta-analysis

JIANGUO GAO¹⁻³, MENG ZHANG^{1,2}, JIANER TANG¹⁻³, RONGJIANG WANG¹⁻³,
YU CHEN¹⁻³, ZHIHAI FANG^{1,2} and HUAN ZHONG^{1,2}

¹Department of Urology, The First Affiliated Hospital of Huzhou Normal College; ²Department of Urology, The First Hospital of Huzhou; ³Huzhou Key Laboratory of Precise Diagnosis and Treatment of Urinary Tumors, Huzhou, Zhejiang 313000, P.R. China

Received April 12, 2023; Accepted February 16, 2024

DOI: 10.3892/etm.2024.12636

Abstract. The aim of the present study was to compare flexible ureteroscopy and laparoscopy in the treatment of peripelvic renal cysts, so as to determine the best treatment method for patients with peripelvic renal cysts. A systematic search of the PubMed, EMBASE, Cochrane Library, CONAHL, Clinicaltrials.gov, Google Scholar, CNKI and WanFang DATA databases was conducted for articles published over 22 years (December 1980-December 2022) using the Preferred Reporting Items for Systematic Reviews and Meta-analyses guidelines. By searching the database, a total of 594 studies were found, of which eight were analyzed as evidence. A total of 394 patients were included in the present study. Of these, 193 were treated laparoscopically and 201 were treated by flexible ureteroscopy. In terms of analysis results, radiation reexamination after laparoscopic therapy had a higher success rate. Ureteroscopy has advantages in the time spent in the operation, the amount of blood lost during the operation, the time to recover the anal exhaust after the operation and the length of postoperative hospital stay. There were no significant difference in postoperative recurrence or complications between the two surgical methods. After comprehensive analysis, it was considered that flexible ureteroscopy has more advantages in the treatment of peripelvic renal cyst, which is mainly manifested in the duration of operation, the total amount of blood loss during operation, the interval of recovery of anal exhaust after operation and the total length of postoperative hospital stay. It is worth further exploration and promotion.

Introduction

Parapelvic renal cyst is a special type of renal cyst which originates from the renal parenchyma and extends to the renal sinuses. It is rare in clinical practice, with an incidence of 1-3%. Parapelvic renal cysts are cystic lesions of the kidney; the majority of patients with peripelvic cysts are asymptomatic and most are detected by physical examination. The anatomical location usually occurs near the renal collecting system, so when a small cyst is found, pressure can be formed on the renal collecting system or pedicle vessels, which can cause a series of clinical symptoms such as low back pain, urinary tract infection, hematuria. Prolonged effects can lead to other symptoms such as stones, hydronephrosis, renal hypertension, cyst rupture or hemorrhage (1). Clinically, the main treatment options for peripelvic cysts include continued observation, percutaneous renal cyst puncture and cure, ultrasound-guided percutaneous renal cyst drainage and laparoscopic renal cyst roof decompression. Considering the complexity of the cyst itself and its proximity to the hilar arteriovenous and collecting system, laparoscopic dermalization of peripelvic cysts requires advanced surgical techniques compared with simple renal cysts. With the progress of clinical instruments and other technologies, it has been reported that flexible ureteroscopy has become increasingly advantageous in the treatment of peripelvic cysts (2,3). Anatomically, parapelvic cysts are characterized by complexity and proximity to the hilar structure. Endoscopic surgery can reduce or avoid the risk of damage to the renal hilar structure and does not require complex surgical techniques by the surgeon to perform laparoscopic surgery. A recent technology called laser vaporization has been reported for prostatectomy (4). After reviewing a number of treatment guidelines, it was found that there is no definitive treatment for parapelvic cysts and that there is no definitive choice between flexible ureteroscopy incision and drainage and laparoscopic parapelvic decompression. To address this question, a systematic review and meta-analysis of eight studies was conducted to evaluate and compare the efficacy of flexible ureteroscopy compared with laparoscopic treatment of parapelvic renal cysts.

Correspondence to: Dr Meng Zhang, Department of Urology, The First Hospital of Huzhou, 158 Guangchanghou Road, Huzhou, Zhejiang 313000, P.R. China
E-mail: zhangmeng96333@163.com

Key words: flexible ureteroscopic, laparoscopic, parapelvic renal cyst, treatment, meta-analysis

Materials and methods

Search strategy. An overall systematic review was conducted in accordance with the Cochrane guidelines (5). This search strategy used the following databases to retrieve and identify the corresponding articles: PubMed <https://pubmed.ncbi.nlm.nih.gov/> (December 1980-December 2022), EMBASE <https://www.embase.com/> (December 1980-December 2022), Cochrane Central Register of Controlled Trials-CENTRAL <https://www.cochranelibrary.com/advanced-search>, CONAHL <https://www.ebsco.com/zh-cn/products/research-databases/cinahl-complete> (December 1980-December 2022), Clinicaltrials.gov <https://classic.clinicaltrials.gov/>, Google Scholar <https://scholar.google.com/> and CNKI <https://www.cnki.net/> (December 1980-December 2022), WanFANG DATA <https://www.wanfangdata.com.cn/index.html> (December 1980-December 2022).

Search terms used in conjunction with each other included: 'Cyst deroofing renal' and 'laparoscopic renal cyst unroofing' and 'ureteroscopic incision and draining'.

Medical Subject Headings (MeSH):

((ureteroscopic) AND (laparoscopic)) AND (parapelvic renal cysts) ('ureteroscope s'(All Fields) OR 'ureteroscopes'(MeSH Terms) OR 'ureteroscopes'(All Fields) OR 'ureteroscope'(All Fields) OR 'ureteroscopic'(All Fields) OR 'ureteroscopically'(All Fields) AND ('laparoscopes'(MeSH Terms) OR 'laparoscopes'(All Fields) OR 'laparoscope'(All Fields) OR 'laparoscopical'(All Fields) OR 'laparoscopically'(All Fields) OR 'laparoscopies'(All Fields) OR 'laparoscopy'(MeSH Terms) OR 'laparoscopy'(All Fields) OR 'laparoscopic'(All Fields)) AND ('parapelvic'(All Fields) AND ('renal'(All Fields) OR 'renals'(All Fields)) AND ('cyst s'(All Fields) OR 'cysts'(All Fields) OR 'cysts'(MeSH Terms) OR 'cysts'(All Fields)).

Inclusion and exclusion criteria. All study data were extracted independently by two researchers (Jianguo Gao and Meng Zhang) from the included studies. Data could be input only after the agreement of two people. Inclusion criteria were: i) Comparison of surgical methods, ureteroscopic fenestration and drainage and laparoscopic renal cyst decompression; ii) existing direct reports or computable sufficient data (such as length of hospital stay, duration of surgery and complications) in the study. The main exclusion criteria were: i) no analysis of the above two surgical techniques, operation time and complications; ii) case reports, abstracts of meetings, summaries, letters to the editor, comments, editorials and other articles from which sufficient data cannot be extracted; iii) a polycystic kidney or Bosniak classification of CT imaging grades III and IV; iv) renal mass or benign and malignant tumor; and v) data of republished papers.

Study selection. Data retrieval was in two languages (English and Chinese). The references of the retrieved papers were also evaluated and considered for inclusion following research. A total of three reviewers (Jianguo Gao, Meng Zhang and Huan Zhong) conducted a comprehensive review of all studies according to inclusion criteria. Each of the two

reviewers (Jianguo Gao and Meng Zhang) included eligible studies in the present review. Rongjiang Wang identified each of these studies individually. In the screening of this study, differences among several authors were reached through negotiation.

Next, two authors (Jianer Tang and Zhihai Fang) separately extracted data from the included studies. Huan Zhong reviewed the data extracted by the two authors to ensure the quality of the data and the consistency of the data extraction. The extracted data were analyzed by two authors (Gao Jianguo and Zhang Meng) and were grouped according to different treatment methods for meta-analysis. The data included demographic cohort (age and sex), cyst size, surgical method, intraoperative bleeding, postoperative recovery and postoperative complications in both groups.

Data extraction. Jianguo Gao and Meng Zhang extracted a great deal of data from the included studies: Study design, sample size, age, sex, cyst type, cyst diameter, intervention type, intraoperative bleeding, postoperative intestinal recovery, postoperative complications, radiological success and symptom success. Furthermore, the authors Jianguo Gao and Meng Zhang collected information on the incidence of postoperative complications, duration of intraoperative treatment and length of hospital stay after treatment. The differences among the authors Jianguo Gao and Meng Zhang were resolved through negotiation with the help of Yu Chen. Yu Chen played a facilitative role in the consultation and assisted in the judgment of disagreements arising from the data analysis of the two authors.

Evaluation of literature quality. The risk of bias was assessed according to the guidelines outlined in the Manual for Systematic Review of Cochrane Interventions (<https://training.cochrane.org/handbook>) Two reviewers carefully read the full text of the included study and rated it as 'high', 'low' or 'unclear'; whether participants and staff were double-blind; whether the sequence generation followed the random principle; whether there was hidden allocation made explicit in the article; whether the results were evaluated blind; whether the resulting data was complete; whether selective reporting existed; and whether there were other biases.

Statistical analysis. Review Manager 5.4.1 software was used for the statistical analysis. The data were analyzed following the overall statistics and the results outputted with the overall percentage. The Q statistic and I² index were used to test the heterogeneity among the studies. If no significant heterogeneity was identified, the fixed effect model was used. The meta-analyzed effect sizes were reported as the relative risk (RR) and 95% confidence interval (95% CI) of treatment failure in the flexible ureteroscopic group compared with laparoscopic resection. Alternatively, in case of significant heterogeneity existing between the studies (Q statistic <0.1 and I² >50%), then a random effects model using a reduced maximum likelihood (REML) approach was employed. The overall statistics of the data were analyzed, and the results were outputted in terms of the overall percentages. The results are shown either as the mean ± SD or as percentages of cumulative data.

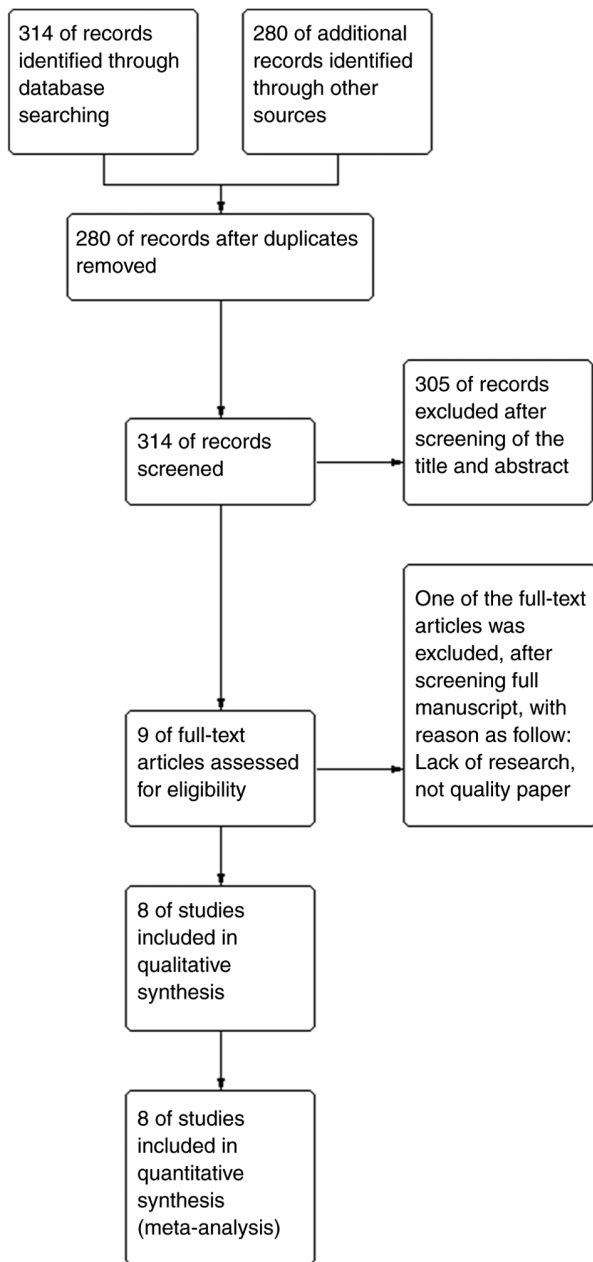


Figure 1. Flow diagram of the present study.

Results

Study selection and characteristics. A PRISMA flow chart was used to express the selection results in the present study (Fig. 1). Through literature search and database search, it was found that there were 594 possible related studies. After removing the duplicated studies, the remaining 314 studies needed to be analyzed in the next step. A total of 305 of the studies were excluded after screening the title of the paper and the content of the abstract, nine full-text articles were assessed as qualified and one article was excluded after screening the full manuscript for lack of research results. Finally, eight studies met the inclusion criteria and were included in the meta-analysis (Fig. 1) (6-13). All data in Table I are from eight studies, including not only the basic patient age and cyst size, but more importantly, the relevant surgical data

	Random sequence generation (selection bias)	Allocation concealment (selection bias)	Blinding of participants and personnel (performance bias)	Blinding of outcome assessment (detection bias)	Incomplete outcome data (attrition bias)	Selective reporting (reporting bias)	Other bias
Chen, 2021	+	+			-	+	-
Guo, 2021	+	+	+	+	+	+	+
He, 2016	+	+	-		+	+	+
Li, 2022	+	+	+	+	-		+
Meng, 2022	+	+		+		+	+
Sun, 2017	+		+	+	+	+	+
Tang, 2022	+	+	+	+	+	+	+
Zhu, 2014	+	+	+	+	+		+

Figure 2. Risk of bias summary. Green: low risk; yellow and blank: unclear risk; red: high risk.

and postoperative recovery results. All the selected studies date from 1980 onwards and 4 of them were non-randomized trials (7,9,10,13), the other 4 studies were randomized trials (6,8,11,12). After evaluation, the bias was acceptable; a risk of bias summary is in Fig. 2. The risk of publication bias assessment of the included studies showed that the majority of the studies had a low risk of bias from radiological success (Figs. 3 and 4). In the treatment of peripelvic cysts, holmium laser incision and internal drainage were used in most patients under ureteroscopy, while incision and drainage were used in most patients under laparoscopy. Of the patients 201 underwent ureteroscopy and 193 underwent laparoscopy. The outcome of meta-analysis showed us the cyst size of patients in the flexible ureteroscopy group had no statistical differences compared with that in the retroperitoneal laparoscopic group, with statistical significance [mean difference (MD)=0.03, 95%confidence interval (CI)-0.40,0.45; P=0.90; Fig. 5)]. Follow-up ranged from 6-35 months.

Operation time. Operation time were reported in eight studies (6-13). In a total of 394 patients flexible ureteroscopy were compared with retroperitoneal laparoscopy for the treatment of pelvic cyst in surgery time consumption. They were

Table I. Characteristic for included studies.

First author, year	Design	Age, years, mean (range)	Sample (male: female)	Cyst size, cm, mean (range)	Operation time (min)	Intra-operative bleeding, ml	Postoperative intestinal peristalsis time, h, mean	Postoperative hospital stay, days, mean (range)	Pelvis perforated during operation, n	Infect or fever, n	Recurrence occurring 6 months after operation (Refs)
He, 2016	Prospective randomized study	42 (32-62) 47 (29-65)	25 (19:6) 23 (15:8)	6.1±1.5 (4-5.8)	65.9±16.1 (70-95)	100.6±16.7		6.0±0.6			(8)
Chen, 2021	Retrospective study	58 (53-64) 54 (45-63)	11 (6:5) 22 (12:10)	6.8±1.9 (4-5.8) 5.6 (4.8-7)	40.9±14.6 (80-95)	18.3±7.2		5.0±1.4 (3-7)	1	1	(10)
Guo, 2021	Prospective randomized study	57.28±6.17 (45-63)	21 (12:9)	7.5±2.9 (4.8-7)	50.91±15.28 (28.8-56.3)	37.92±10.26	19.29±5.77	6.52±1.37	2	2	(12)
Tang, 2022	Prospective randomized study	56.85±6.3 (35-66) 57.65±5.12 (34-67)	21 (13:8) 41 (21:20)	7.4±2.8 (5-10.5) 4.86±0.79 (5.2-10)	40.88±14.37 (70-95)	30.19±11.68	15.38±4.15	5.79±1.18	1	1	(11)
Zhu, 2014	Prospective randomized study	52 (35-66) 53 (34-67)	23 (13:10) 25 (14:11)	6.2 (5-10.5) 6.5 (5.2-10)	69.48±14.21 (70-95)	49.35±12.18	31.43±6.99	6.04±1.29	1		(6)
Li, 2022	Retrospective study	43.24±8.46 (34-67)	18 (8:10)	4.08±0.35 (5.2-10)	37.53±14.32 (70-95)	10.24±3.38	13.24±2.39	2.45±0.62			(7)
Sun, 2017	Retrospective study	49.85±9.33 (35-66) 53.86±8.14 (34-67)	17 (8:9) 20 (10:10)	3.44±0.73 (5.2-10) 6.4±1.32 (5.2-10)	35.26±13.31 (70-95)	45.13±10.25	30.51±6.48	2.04±0.32		1	(9)
Meng, 2022	Retrospective study	54.52±8.66 (35-66) 46.8±7.8 (34-67)	21 (11:10) 34 (15:19)	6.34±1.24 (5.2-10) 5.1±0.9 (5.2-10)	27.16±5.24 (70-95)	12.41±3.66	12.54±2.52	3.36±1.38		1	(13)
		47.6±7.8 (34-67)	31 (15:16)	5.3±0.9 (5.2-10)	30.1±4.3 (70-95)	5.5±1.7		4.5±0.8			

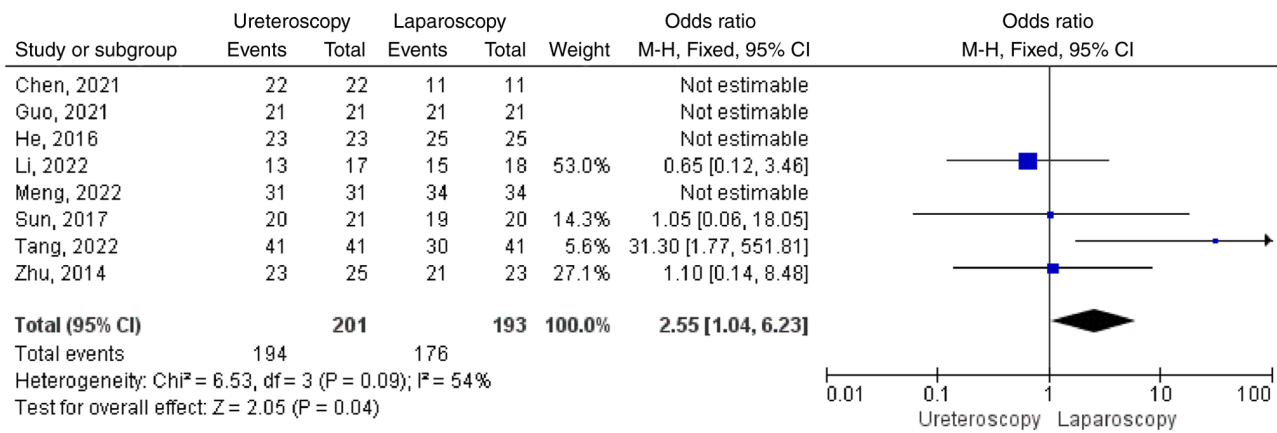


Figure 3. Radiological success. SD, standard deviation; CI, confidence interval.

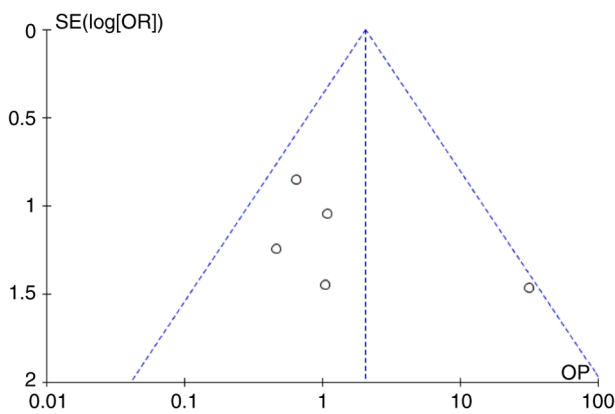


Figure 4. Funnel plot for Radiological success.

included in two groups; 201 cases in flexible ureteroscopy group, 193 cases of retroperitoneal laparoscopy group. The results showed that there was significant heterogeneity in the studies ($P < 0.00001$; $I^2 = 96\%$). Thus, a random effects model was applied. The results showed that the operative time in the flexible ureteroscopy group was shorter compared with that in the retroperitoneal laparoscopic group, with statistical significance (MD = -24.48; 95%CI -33.29, -15.67; $P < 0.00001$; Fig. 6).

Intraoperative blood loss. Intraoperative blood loss for treatment of parapelvic cysts was compared between ureteroscopy and laparoscopy in six studies (6,8,9,11-13). There were 326 patients, including 162 in ureteroscopy group and 164 in laparoscopy group. The results showed obvious heterogeneity in the studies ($P < 0.00001$; $I^2 = 98\%$). Meta-analysis showed that intraoperative blood loss of patients in ureteroscope group was significantly less than that in laparoscopic group, with statistical significance (MD = -43.32; 95%CI -62.22, -24.42; $P < 0.00001$; Fig. 7).

Postoperative anal exhaust time. Calculation of anal exhaust time (h) following surgery for parapelvic cysts compared ureteroscopy and laparoscopy in three studies (6,9,12). There were 132 patients, including 68 in the ureteroscopy group and 64 in laparoscopy group. The results showed obvious

heterogeneity in the studies ($P < 0.00001$; $I^2 = 96\%$) and that the anal exhaust time following surgery in ureteroscopy group was significantly less than that in laparoscopic group, with statistical significance (MD = -13.36; 95%CI -22.62, -4.09; $P = 0.005$; Fig. 8).

Postoperative hospital stay. In these eight studies, postoperative hospital stay (days) was compared in the treatment of parapelvic cysts by ureteroscopy or laparoscopy, including 394 patients, 201 in flexible ureteroscopy group and 193 in retroperitoneal laparoscopy. The results displayed significant heterogeneity among the studies ($P < 0.00001$; $I^2 = 93\%$). The random effects model was used. The results of meta-analysis showed that the postoperative hospital stay of patients in the ureteroscopy group was significantly shorter than that in the laparoscopic group and the difference was statistically significant (MD = -1.40; 95%CI -2.04, -0.76; $P < 0.0001$; Fig. 9).

Recurrence after 6 months. Postoperative follow-up as the complete treatment of parapelvic cysts by ureteroscopy and laparoscopy was searched for in eight studies (6-13) including 394 patients; 201 in the flexible ureteroscopy group and 193 in the retroperitoneal laparoscopy group. There was significant heterogeneity in the studies ($P = 0.05$; $I^2 = 75\%$). The results of meta-analysis showed that postoperative recurrence after 6 months in the ureteroscopy group was not significant compared with the laparoscopic group (MD = 0.20; 95%CI 0.01, 6.57; $P = 0.36$; Fig. 10).

Complications. The eight studies also reported complications by study and by group (see Table I). Specifically, Tang *et al* (11) documented 11 cases of recurrence in 41 patients with laparoscopic deroofting and zero recurrence in 41 patients in the ureteroscopy group. Zhu *et al* (6) recorded two cases of recurrence in the laparoscopic and ureteroscopic groups, respectively. Guo *et al* (12) reported that one case of infection occurred in the laparoscopic group following surgery. In two studies, Chen *et al* (10) and Tang *et al* (11) found that there was one patient with fever in the laparoscopic group respectively, while there were six patients with fever following ureteroscopy from Chen *et al* (10), Guo *et al* (12),

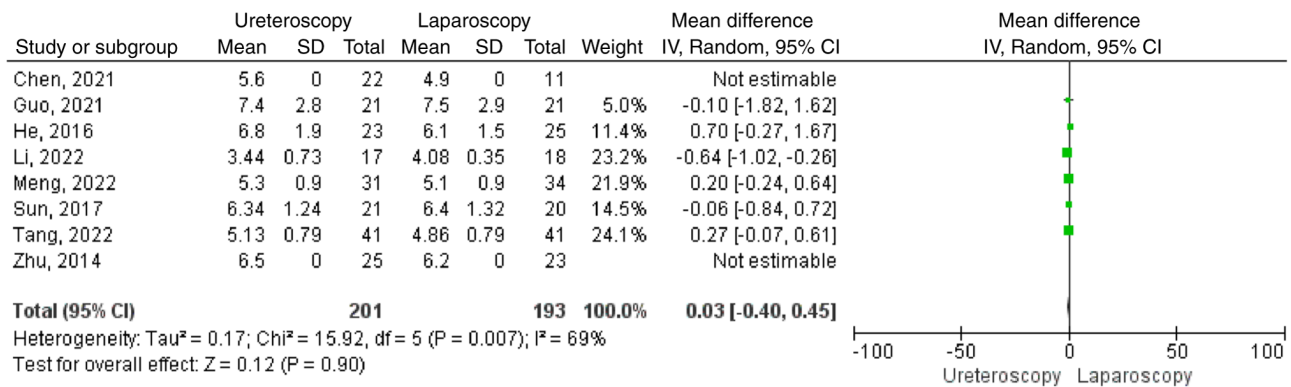


Figure 5. Sample size. SD, standard deviation; CI, confidence interval.

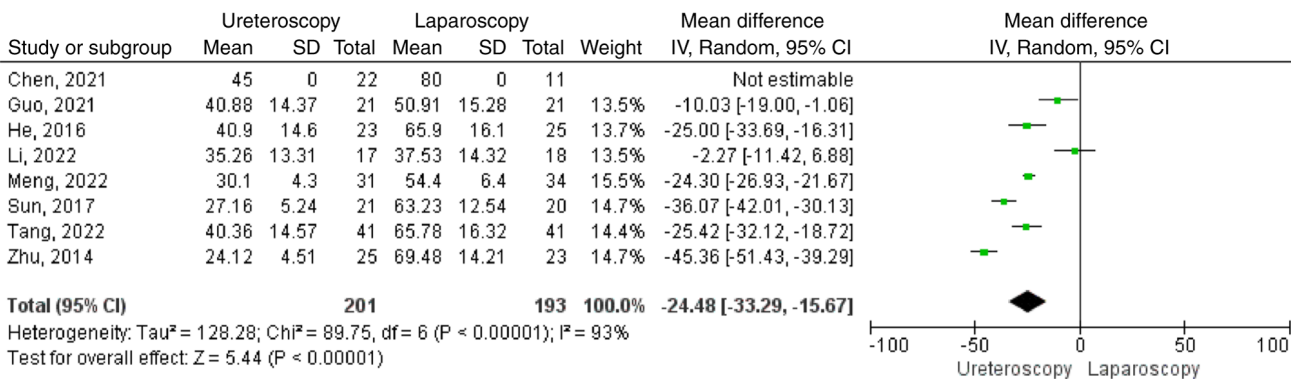


Figure 6. Operation time. SD, standard deviation; CI, confidence interval.

Li and Lin (7) and Sun *et al* (9), respectively (Fig. 11). In three studies, Chen *et al* (10), Zhu *et al* (6) and Sun *et al* (9) found that there was four patients with urine leakage after surgery in the laparoscopic group, compared with one in Zhu *et al* (6) in ureteroscopic group (Fig. 12).

Discussion

Parapelvic cysts are a common type in cystic lesions of the kidney (14). Due to the anatomical structure of parapelvic cysts close to the renal pedicle, cysts located in the pelvis have a greater effect on the patient than those in the parenchyma and on the surface of the kidney; patients with small cysts may have waist discomfort, hematuria, elevated blood pressure and other manifestations and further development may lead to renal insufficiency and in severe cases may lead to kidney failure (15). In general, parapelvic cysts with a diameter of <4 cm and no symptoms are considered medically and generally no special treatment is needed and only regular follow-up is required. For the cyst diameter of >4 cm and obvious lumbago, compression of renal parenchyma and other manifestations, the doctor will recommend surgical treatment measures. For the treatment of pararenal cysts, traditional open surgery leads to large incisions, a number of complications and long postoperative recovery time. Therefore, most clinicians now prefer minimally invasive surgical methods, such as laparoscopy and ureteroscopy, rather than open surgery with large incisions.

The treatment of renal cysts by laparoscopy was first reported in 1992 and laparoscopy for parapelvic cyst is a common treatment lasting a long time (16-19). Relatively speaking, retro-laparoscopy can effectively reduce the damage to abdominal organs, but the retroperitoneal space is small and intraoperative cysts are not easy to be exposed, which increases the difficulty of the operation. If the operation is not properly performed, it is easy to cause complications. At the same time, it should be noted that in patients undergoing laparoscopic treatment it should be determined whether the cyst is communicating with the renal pelvis and calices before and during the operation. The objective lens of the laparoscope can be used to explore the bottom of the cyst by using the magnification effect of laparoscopy before the operation. During the operation, methylene blue can be injected through the ureteral catheter after the cyst is uncapped and then the blue liquid can be observed at the bottom of the sac. Although Tang *et al* (11) documented 11 cases of recurrence in 41 patients with laparoscopic deroofing and zero recurrence in 41 patients in the ureteroscopy group. Tang *et al* (11) did not analyze the reasons why the recurrence rate was so high in the laparoscopic group. The reason for such high heterogeneity in his article may be the difference in surgical proficiency and experience of clinicians, or it may be that different surgeons performed laparoscopic surgery. For patients with intraoperative cysts connected to the collection system, 4-0 absorbable line was used for repair, fat backfilling was given in the cystic cavity and double J tubes were indwelled after surgery. The implementation of these measures in the operation will also directly lead

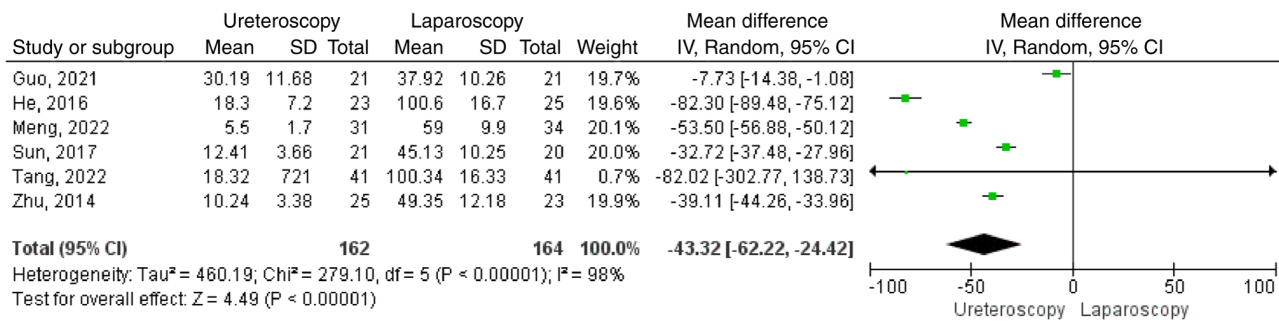


Figure 7. Intraoperative blood loss. SD, standard deviation; CI, confidence interval.

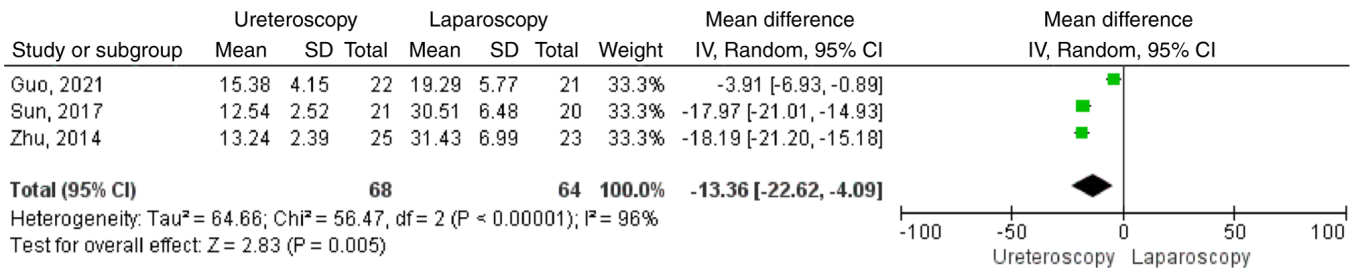


Figure 8. Postoperative anal exhaust time. SD, standard deviation; CI, confidence interval.

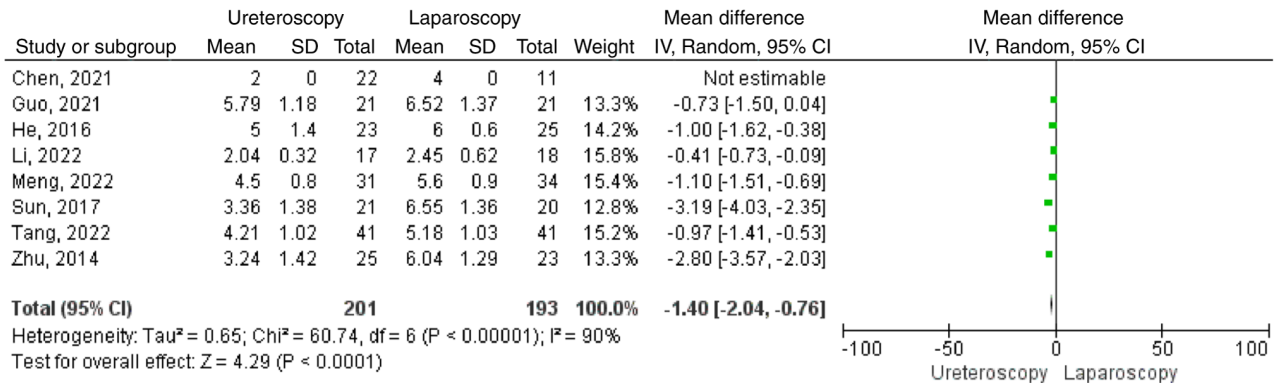


Figure 9. Postoperative hospital stay. SD, standard deviation; CI, confidence interval.

to the prolongation of the operation time. This meta-analysis found that there was no significant difference in the recurrence rate 6 months after operation between the ureteroscopy group and the laparoscopic group.

In terms of efficacy, laparoscopy has a higher success rate of cyst disappearance in postoperative imaging review. The advantage of ureteroscopy is that it can shorten the operation time, intraoperative blood loss, postoperative anal exhaust time, postoperative hospital stay and costs. There was no significant difference in postoperative recurrence and complications between the two surgical methods (Figs. 4-8). The flexible ureteroscopy is operated through the retrograde urinary tract path, which is more direct to the peripelvic renal cyst than laparoscopic surgery (20). Therefore, it is very important to obtain the exact location of the cyst during the incision and internal drainage of the peripelvic renal cyst using a flexible ureteroscope. A number of studies have found that computerized tomography (CT) urogram, CT plain scan, retrograde

urography, transvenous urography and Doppler ultrasound are recommended to determine accurate position of cysts before surgery (20-26).

Intraoperative localization of renal cysts. A randomized controlled trial study in China found that injection of methylene blue into pelvic para-renal cysts could significantly reduce the time to find and identify cysts under flexible ureteroscopy and shorten the operative time (27). Some studies (3,28) consider that preoperative multiplanar reconstruction-CT urogram and intraoperative ultrasound guidance can make the flexible ureteroscope easily to find the cyst wall, so as to obtain an improved therapeutic effect (accurate finding of cysts, reducing bleeding and urinary fistula), compared with the simple use of flexible ureteroscope technology. To the best of the authors' knowledge, Chen *et al* (29) attempted to treat peripelvic renal cysts using a 1,470 nm laser. This is a near-infrared laser and the wavelength of 1,470 nm can be absorbed by both water and hemoglobin at the same time. It has the advantages of

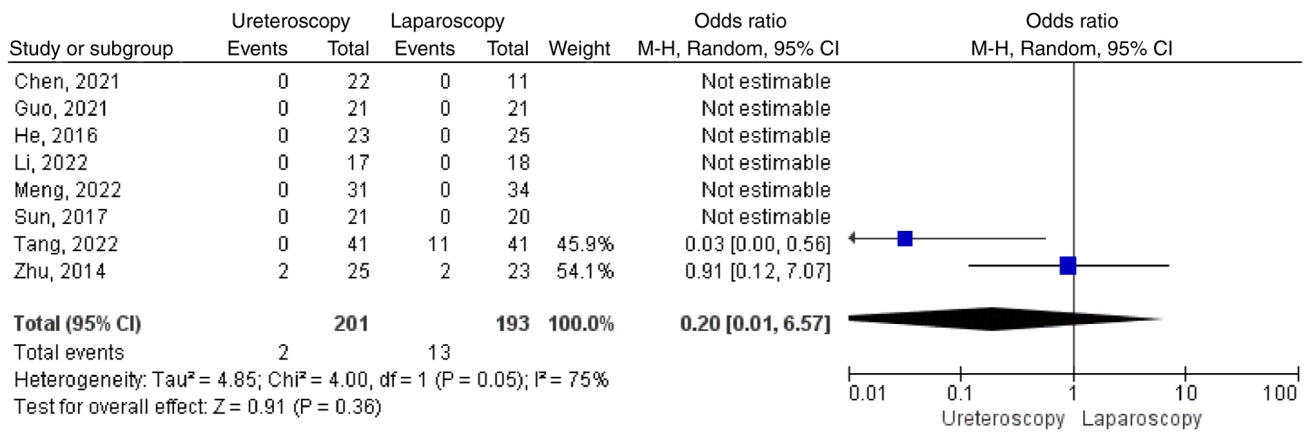


Figure 10. Recurrence after 6 months. SD, standard deviation; CI, confidence interval.

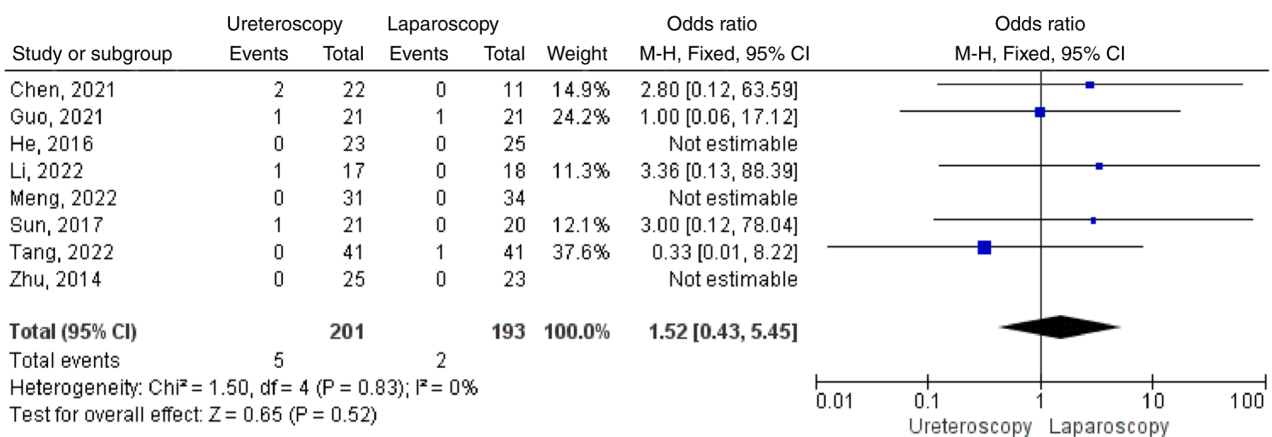


Figure 11. Postoperative fever. SD, standard deviation; CI, confidence interval.

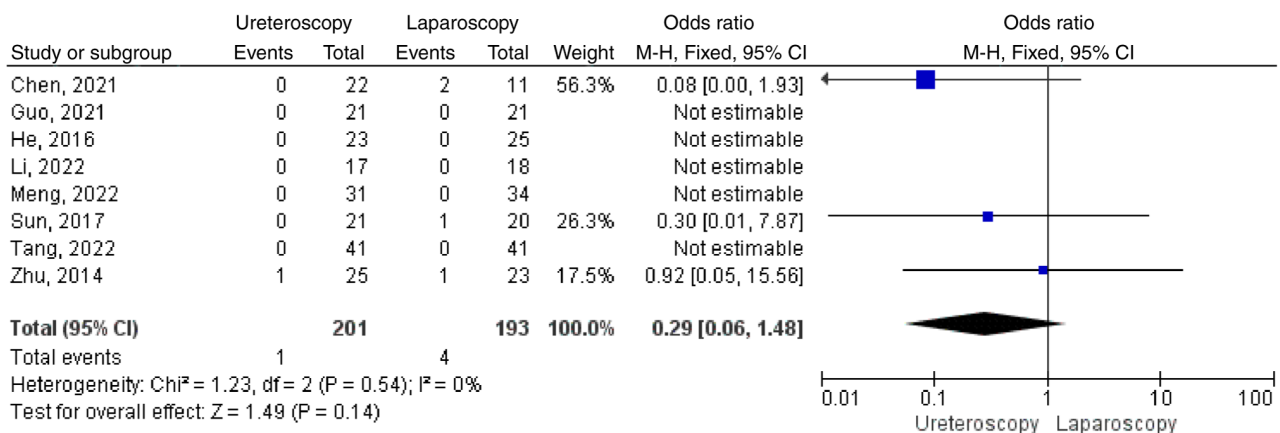


Figure 12. Postoperative urine leakage. SD, standard deviation; CI, confidence interval.

high cutting efficiency, complete hemostasis and little thermal damage to tissues, which meets the requirements of precision surgery. Compared with holmium laser treatment, the 1,470 nm laser showed more concentrated heat and tissue penetration of 2-3 mm (30). The 1,470 nm laser is able to reduce intraoperative bleeding, open the cyst opening and the outflow of cyst fluid, so as to achieve improved surgical results; a good development direction for flexible ureteroscopic surgery.

The present meta-analysis compared the two treatments for parapelvic cysts from different aspects. Each has its advantages and disadvantages (Table I). It is important for treatment decisions to focus on patient selection and the expertise of the surgeon. As most parapelvic cysts have a certain compression on the collection system and are separated from the collection system by only a thin wall, cysts can be found in the natural passages of the human body,

retrograde urinary system, incision and internal drainage of cysts by holmium laser through ureteroscope and there are generally fewer blood vessels in the cyst wall on the side of the collection system, so the blood loss during holmium laser incision is less and the damage to patients is mild. Gastrointestinal function recovered more quickly and hospital stay is shorter after surgery.

By analyzing these considerations, the present meta-analysis compared the advantages and disadvantages of two common surgical regimens for the treatment of parapelvic renal cysts. Of course, if more randomized studies can be added in the future to obtain larger sample sizes, more comprehensive information and more standardized protocols, we will get more in-depth comparison results.

Acknowledgements

Not applicable.

Funding

The present study was supported by Huzhou Science and Technology Bureau Project (grant no. 2022GYB36).

Availability of data and materials

Not applicable.

Authors' contributions

JG and MZ extracted the data from selected studies for inclusion. RW made substantial contribution to conception and design. JT and ZF analyzed and interpreted data. HZ conducted a strict audit of the extracted data to ensure its quality. JG and MZ extracted the information from all the included studies. YC collected and analyzed information and JG wrote the manuscript. All authors read and approved the final manuscript. Data authentication is not applicable.

Ethics approval and consent to participate

Not applicable.

Patient consent for publication

Not applicable.

Competing interests

The authors declare that they have no competing interests.

References

- Basiri A, Hosseini SR, Tousi VN and Sichani MM: Ureteroscopic management of symptomatic, simple parapelvic renal cyst. *J Endourol* 24: 537-540, 2010.
- Taguchi K, Harper JD, Stoller ML, Duty BD, Sorensen MD, Sur RL, Usawachintachit M, Tzou DT, Wenzler DL, Isaacson D, *et al*: Identifying factors associated with need for flexible ureteroscope repair: A Western Endourology STone (WEST) research consortium prospective cohort study. *Urolithiasis* 46: 559-566, 2018.
- Wang R, Wang N, Tang J, Chen Y and Gao J: The safety and efficacy of MPR-CTU combined with precise intraoperative ultrasonography guided flexible ureteroscope in the treatment of renal cystic disease. *Exp Ther Med* 15: 283-287, 2018.
- Liu Z, Zhao Y, Wang X, Song M and Shi B: Critical reviews of 1470-nm laser vaporization on benign prostatic hyperplasia. *Laser Med Sci* 33: 323-327, 2018.
- Higgins JPT and Green S: *Cochrane handbook for systematic review of interventions*. Version 5.1.0, The Cochrane Collaboration, 2011.
- Zhu W, Zhu Q, Zeng F, Gao X and He Y: Comparison of holmium laser ureteroscopic intrapelvic drainage vs. retroperitoneal laparoscopy for the treatment of peripelvic cyst. *Chin J Exp Surg* 31: 2, 2014 (In Chinese).
- Li X and Lin C: A comparative study of three different methods in the treatment of parapelvic cysts. *J Chin Phys*: 1726-1728, 2022 (In Chinese).
- He H, Li L, Tao Z and Wang W: Flexible ureteroscopy versus laparoscopy in treatment of parapelvic cyst. *J Mod Clin Med* 42: 417-419, 2016.
- Sun Y, Du D and Wu Y: To compare the effect of flexible ureteroscopy holmium laser incision and internal drainage and retroperitoneal laparoscopic cyst unroofing in the treatment of parapelvic cyst. *Henan Med Res* 26: 1570-1571, 2017 (In Chinese).
- Chen H, Chen G, Pan Y and Jin X: Minimally invasive surgeries in the management of renal parapelvic cysts: A retrospective comparative study. *Urol J* 18: 389-394, 2021.
- Tang R, Yang J, Wan L and Yang Z: Clinical effect of flexible ureteroscope and laparoscopy in the treatment of parapelvic cyst. *Biomed Res Int* 2022: 5718923, 2022.
- Guo H, Liu C, Sun J and Zhang X: Comparison of holmium laser incision and internal drainage under flexible ureteroscope and retroperitoneal laparoscopic decompression to stress response in patients with parapelvic cyst. *J Third Mil Med Univ* 43: 1258-1262, 2021.
- Meng X and Mi Q: Transurethral flexible ureteroscopic incision and drainage with holmium laser in the treatment of parapelvic renal cysts: A retrospective study. *INT BRAZ Journal of Urology* 48: 842-849, 2022.
- Meola M, Samoni S and Petrucci I: Clinical scenarios in chronic kidney disease: cystic renal diseases. *Contrib Nephrol* 188: 120-130, 2016.
- Ishida K, Yuhara K and Kanimoto Y: A case of acute renal failure due to parapelvic cyst in a solitary kidney. *Hinyokika Kyo* 51: 261-263, 2005 (In Japanese).
- Camargo AHLA, Cooperberg MR, Ershoff BD, Rubenstein JN, Meng MV and Stoller ML: *Laparoscopic management of peripelvic renal cysts: University of California, San Francisco, experience and review of literature*. *Urology* 65: 882-887, 2005.
- Hoenig DM, McDougall EM, Shalhav AL, Elbahnasy AM and Clayman RV: Laparoscopic ablation of peripelvic renal cysts. *J Urol* 158: 1345-1348, 1997.
- Yoder BM and Wolf JS Jr: Long-term outcome of laparoscopic decortication of peripheral and peripelvic renal and adrenal cysts. *J Urol* 171: 583-587, 2004.
- Morgan C Jr and Rader D: Laparoscopic unroofing of a renal cyst. *J Urol* 148: 1835-1836, 1992.
- Yu W, Zhang D, He X, Zhang Y, Liao G, Deng G and Jin B: Flexible ureteroscopic management of symptomatic renal cystic diseases. *J Surg Res* 196: 118-123, 2015.
- Mancini V, Cormio L, d'Altilia N, Benedetto G, Ferrarese P, Balzarro M, Defidio L and Carrieri G: Retrograde intrarenal surgery for symptomatic renal sinus cysts: Long-term results and literature review. *Urol Int* 101: 150-155, 2018.
- Zhao Q, Huang S, Li Q, Xu L, Wei X, Huang S, Li S and Liu Z: Treatment of parapelvic cyst by internal drainage technology using ureteroscope and holmium laser. *West Indian Med J* 64: 230-235, 2015.
- Li EC, Hou JQ, Yang LB, Yuan HX, Hang LH, Alagirisamy KK, Li DP and Wang XP: Pure natural orifice transluminal endoscopic surgery management of simple renal cysts: 2-Year follow-up results. *J Endourol* 25: 75-80, 2011.
- Liaconis H, Pautler SE and Razvi HA: Ureteroscopic decompression of an unusual uroepithelial cyst using the holmium: YAG laser. *J Endourol* 15: 295-297, 2001.
- Luo Q, Zhang X, Chen H, Liu Z, Chen X, Dai Y and Zhao Z: Treatment of renal parapelvic cysts with a flexible ureteroscope. *Int Urol Nephrol* 46: 1903-1908, 2014.
- Mao X, Xu G, Wu H and Xiao J: Ureteroscopic management of asymptomatic and symptomatic simple parapelvic renal cysts. *BMC Urol* 15: 48, 2015.

27. Wang Z, Zeng X, Chen C, Wang T, Chen R and Liu J: Methylene blue injection via percutaneous renal cyst puncture used in flexible ureteroscope for treatment of parapelvic cysts: A modified method for easily locating cystic wall. *Urology* 125: 243-247, 2019.
28. Shen J, Chen Y and Wang R: Efficacy and complication of flexible ureteroscopic holmium laser incision for simple renal cysts: A retrospective study. *J Endourol* 33: 881-886, 2019.
29. Chen Y, Wang R, Shen X, Tang J, Shen J, Fang Z, Shi Z and Jin X: Ultrasonography-assisted flexible ureteroscope for the treatment of parapelvic renal cysts: A comparison between the 1470-nm diode laser and the holmium laser. *Exp Ther Med* 21: 172, 2021.
30. Zhao Y, Liu C, Zhou G, Yu C, Zhang Y and Ouyang Y: A retrospective evaluation of benign prostatic hyperplasia treatment by transurethral vaporization using a 1470 nm laser. *Photomed Laser Surg* 31: 626-629, 2013.



Copyright © 2024 Gao et al. This work is licensed under a Creative Commons Attribution-NonCommercial-NoDerivatives 4.0 International (CC BY-NC-ND 4.0) License.